

WEB BOOK

Harmonized European Dermato-Venereology Undergraduate Blended-LEARNING Implementation and Training

2nd Edition

3rd Revision of the 1st Edition of a Harmonized Curriculum and Content
for Medical Undergraduate Training in Europe

December 2021 / April 2024



HEDULEARNIT

Harmonized European Dermato-Venereology Undergraduate blended LEARNing Implementation and Training

Editors and authors:

Harald Gollnick, Magdeburg (Germany); Martine Bagot, Paris (France); Günter Burg, Zurich (Switzerland); Andreas Altenburg, Dessau (Germany); Zrinka Bukvić Mokos, Zagreb (Croatia); Adele De Masson, Paris (France); Veronique del Marmol, Brussels (Belgium); Gabor Dobos, Paris (France); Evelyn Gaffal, Magdeburg (Germany); Ana Gimenez-Arnau, Barcelona (Spain); Giampiero Girolomoni, Verona (Italy); Paolo Gisondi, Verona (Italy); Katariina Hannula-Joupp, Helsinki (Finland); Eija Hiltunen-Back, Helsinki (Finland); Sarah Hobelsberger, Dresden (Germany)*; Michel Janier, Paris (France)*; Sari Koskenmies, Helsinki (Finland); Josep Malvehy, Barcelona (Spain)*; Branka Marinović, Zagreb (Croatia); Luisa Martos-Cabrera, Madrid (Spain)*; Martina Maurelli, Verona (Italy); P. Ortiz-Romero, Madrid (Spain)*; Paola Pasquali, Barcelona (Spain)*; Ramon M Pujol, Barcelona (Spain); Annamari Ranki, Helsinki (Finland); Franco Rongioletti, Milan (Italy)*; Alexander Salava, Helsinki (Finland); Sinikka Salmenkylä, Helsinki (Finland); Jonathan White, Brussels (Belgium); Christos C. Zoubulis, Dessau (Germany).

**contributed to 2nd edition*

Supported by:



Programming, design and technical realisation:

Anna Darzina, Vahid Djamei, Swiss4ward, Zurich and Alicante

Supported by an unrestricted grant of Mylan Ltd Europe



Foreword

This webbook placed on the Erasmus+ Project Results Platform represents the outcomes of the HEDU_LEARN_IT Erasmus Plus Project 2018-1-DE01-KA203-004278, which was performed between September 2018 to November 2021.

The project belongs to the Key Action 2: Innovation and good practices, which is designed to develop the education, training, and youth sectors through five main activities: Strategic partnerships to support innovation in the sector as well as joint initiatives to promote cooperation, peer- learning, and the sharing of experience. The aim of the project HEDU_LEARN_IT is the harmonization of Medical Undergraduate Training in Dermato-Venereology for Medical Students in Europe which will be based on a consensuated recommendation (European Harmonization Curriculum Dermato- Venereology (EHC-DV)).

Harmonization of the curriculum in Dermato-Venereology is necessary because across Europe a very wide disparity of catalogue, content and formats in teaching Dermato-Venereology according to recent surveys exists. The elaboration of an EHC-DV will provide (1) a new consensuated written catalogue, content and accordingly format, and (2) will follow on the digital agenda of the EU, having a high-innovative approach by establishing an electronic learning platform. In the phase beyond the project the results can stimulate also colleagues from other medical fields for implementing this type of learning platform. Several curricula from European countries were reviewed and in particular those from Switzerland, Netherlands and Germany served as a guide, framework and basis for the new contents, catalogue and formats for EHC-DV across Europe. Implementation on the medical students' level will be in particular supported and finally achieved by a blended learning platform offering flipped classroom methods and virtual teaching via the medical undergraduate training platform Dermatology Online with Interactive Technology (DOIT) - Cyberderm and the Erasmus+ Project Results Platform.

Having medical undergraduate students as main target group this project has been carried out by a European wide cooperation of experienced professors in Dermato-Venereology at university medical institutions who are long-term involved in academic teaching and international innovative research projects, IT specialists for blended learning and local stakeholders at the project partner sites within the medical faculties. Finally, undergraduate students in Europe will become best trained innovative graduates who can much easily follow the European mobility program. Furthermore, this way of advanced learning gives rise for being much better prepared to follow international Master programs and to raise the quality of future PhD students and Postdocs. This first harmonized curriculum content for medical undergraduate training is part of a vertical structuring of harmonization processes in education in Europe and is in line with the first harmonized residents training program in Dermato-Venereology promoted by the UEMS (Union European Medical Specialists).

Introduction

The blended learning approach combines classical teaching methods with self-guided E-learning. The typical setting of undergraduate training is teacher-centred, comprises front lectures without interactive communication or sufficient feedback. It does not consider the heterogeneous social, intellectual, linguistic and perceptual background of the students. In the new concept students will get the opportunity to gain additional knowledge by the innovative digital-assisting in advance before joining the regular lectures and courses. Implementing the newly EHC-DV as learning lessons in the format of an Erasmus Students Webbook and on the Cyberderm Platform will work as a digital assistant allowing personalized analysis of student's strengths and weaknesses regarding the curriculum. The lecturer can act as coach and mentor for the students, has more time for responsive to the individual knowledge profiles of the students. Due to this feedback the lecturer can customize the teaching activities according to the individual needs of the students realizing the inverted (flipped) classroom concept according to EU Digital Agenda.

How to use this WebBook (WB)

Access to this WebBook is free of charge.

Ten main chapters cover 180+ subchapters on diagnoses, signs and symptoms, which can be directly accessed through the corresponding link in the table of contents.

All chapters follow the same structure, giving ICD-11, Synonyms, Definition, Epidemiology, Aetiology & Pathogenesis, Signs & Symptoms, Localisation, Classification, Laboratory & other workups, Dermatopathology, Course, Complications, Diagnosis, Differential Diagnosis, Prevention & Therapy and Special. Besides title and authorship, the respective chapters give Grading & Level of importance:

A - Know and care: Corresponds to common diseases that the General Practitioner (GP) must be able to diagnose and to treat.

B- Know and care with guidance: Corresponds to diseases which should be referred to the dermatologist, but still within the capacity of the GP to evaluate the emergency and to make the first intervention/management step. The GP must be guided to follow the patient in cooperation with the Dermatovenerologist.

C- Know and refer: Corresponds to diseases which the GP must know just enough to recognize and understand and to refer to the Dermato-Venerologist.

Access to diagnoses related pictures is offered through the platform www.cyberderm.net, which needs free of charge registration through your university (to be chosen in the popup window or to be added). This multilingual -learning platform (DOIT; Dermatology Online with Interactive Technology) is a short Wikipedia-style version, presenting the same contents of Dermato-Venerology with additional interactive functionalities. Please use the image icon next to each diagnosis to switch to the respective chapter on Cyberderm.

Both, the short interactive version (DOIT) and the longer more elaborated content version (WebBook) are excellent guides to Dermato-Venerology for undergraduate students and postgraduate physicians. Teachers at the university have the chance to use the material and include, adapt or enlarge their lecture contents, accordingly. We welcome helpful suggestions and corrections anytime (anna.darzina@swiss4ward.com or harald.gollnick@med.ovgu.de).

Table of contents

Chapter 1 - Inflammatory dermatoses 14

1.1 Allergic/ Non-allergic and other immunologic reactions	14
1.1.1 Urticaria and Angioedema	14
1.1.1.1 Urticaria	14
1.1.1.2 Angioedema.....	18
1.1.2 Eczematous dermatoses	22
1.1.2.1 Atopic Dermatitis.....	22
1.1.2.2 Allergic contact dermatitis.....	26
1.1.2.3 Irritant Contact Dermatitis	29
1.1.2.4 Nummular Dermatitis.....	34
1.1.2.5 Seborrheic Dermatitis.....	36
1.1.2.6 Napkin Dermatitis (classical)	39
1.1.2.7 Dyshidrotic Dermatitis.....	42
1.1.3 Drug Related Dermatoses.....	46
1.1.3.1 Drug Reactions.....	46
1.1.3.2 Erythema Multiforme	51
1.1.3.3 Drug related rash with eosinophilia and systemic symptoms (DRESS).....	54
1.1.3.4 Stevens-Johnson Syndrome.....	57
1.1.3.5 Toxic Epidermal Necrolysis.....	60
1.1.4 Inflammatory and Postinfectious Immunologic Reactions	67
1.1.4.1 Erythema nodosum.....	67
1.1.4.2 Pyoderma gangrenosum	71
1.1.4.3 Sweet’s syndrome (acute neutrophilic dermatosis).....	78
1.2 Autoimmune and Bullous Dermatoses.....	83
1.2.1 Lupus Erythematosus.....	83
1.2.2 Systemic scleroderma (SSc)	89
1.2.3 Localized Scleroderma.....	95
1.2.4 Dermatomyositis	99
1.2.5 Pemphigus	103
1.2.6 Pemphigoid group.....	107
1.2.7 Dermatitis Herpetiformis.....	111

1.3 Physically Induced Dermatoses.....	113
1.3.1 Thermal Injury	113
1.3.2 Pernio and Congelatio	116
1.3.3 Sunburn.....	119
1.3.4 Photodermatoses	122
1.4 Granulomatus Dermatoses	129
1.4.1 Sarcoidosis	129
1.4.2 Granuloma annulare	132
1.5 Papulosquamous Disorders.....	135
1.5.1 Psoriasis	135
1.5.2 Pityriasis Lichenoides	141
1.5.3 Pityriasis rubra pilaris.....	145
1.5.4 Lichen planus	149
1.5.5 Pityriasis Rosea	152
1.5.6 Prurigo Simplex	154
Chapter 2 - Infectious Diseases	157
2.1 Viral Infections	157
2.1.1 Varicella and Herpes Zoster	157
2.1.2 Herpes Simplex	160
2.1.3 Eczema Herpeticum	163
2.1.4 Common Warts	165
2.1.5 Condylomata Acuminata.....	167
2.1.6 Molluscum Contagiosum	170
2.1.7 Ecthyma contagiosum (Orf)	172
2.1.8 Smallpox.....	175
2.1.9 Oral Hairy Leukoplakia.....	178
2.2 Bacterial Infections.....	180
2.2.1 Erythrasma.....	180
2.2.2 Impetigo Contagiosa.....	182
2.2.3 Erysipelas	185
2.2.4 Microbial Folliculitis	188
2.2.5 Furuncle/Carbuncle	192
2.2.6 Staphylococcal scalded skin syndrome (SSSS)	195
2.2.7 Staphylogenic/Streptogenic Toxin Shock-Syndrom (STSS).....	198

2.2.8 Erythema (Chronicum) Migrans	201
2.2.9 Lymphadenosis Cutis Benigna	204
2.2.10 Acrodermatitis Chronica Atrophicans.....	207
2.2.11 Leprosy.....	210
2.2.12 Skin Tuberculosis and atyp. Mycobacterioses (MOTT).....	214
2.3 Fungal Infections	217
2.3.1 Dermatophyte Infections	217
2.3.2 Candidiasis	222
2.3.3 Pityriasis Versicolor	225
2.4 Parasites and Arthropodes.....	228
2.4.1 Leishmaniasis	228
2.4.2 Scabies	231
2.4.3 Trombidiosis.....	233
2.4.4 Pediculosis Capitis	235
2.4.5 Pediculosis pubis	237
2.4.6 Demodicosis.....	239
2.4.7 Arthropod reactions.....	242
2.4.8 Bee and wasp stings	245
2.5 Sexually Transmitted Infections	248
2.5.1 Gonorrhoea.....	248
2.5.2 Chlamydial Urethritis	251
2.5.3 Lymphogranuloma venereum.....	255
2.5.4 Non-specific urethritis (NSU)	259
2.5.5 Trichomoniasis	262
2.5.6 Bacterial vaginosis.....	265
2.5.7 Syphilis	268
2.5.8 Chancroid	272
2.5.9 Granuloma inguinale.....	275
2.5.10 Genital herpes simplex.....	277
2.5.11 Skin manifestations of HIV-infection	281
Chapter 3 - Nevi, Tumours and Cysts	289
3.1 Naevi.....	289
3.1.1 Melanocytic Nevus.....	289
3.1.2 Congenital melanocytic nevus.....	292

3.1.3 Atypical melanocytic naevus and syndrom	295
3.1.4 Nevus Flammeus	298
3.1.5 Naevus sebaceous	301
3.2 Benign Tumours and Cysts	303
3.2.1 Seborrhoeic Keratosis	303
3.2.2 Keratoacanthoma	306
3.2.3 Dermatofibroma	310
3.2.4 Keloid	312
3.2.5 Lipoma	315
3.2.6 Haemangioma	318
3.2.7 Pyogenic granuloma (PG)	322
3.2.8 Cutaneous mastocytosis	324
3.2.9 Cutaneous Cysts	328
3.3 Premalignant and Malignant Tumours.....	331
3.3.1 Actinic Keratosis	331
3.3.2 Carcinoma in situ	334
3.3.3 Paget's Disease	336
3.3.4 Cutaneous Squamous Cell Carcinoma	339
3.3.5 Basal Cell Carcinoma	341
3.3.6 Lentigo Maligna	345
3.3.7 Malignant Melanoma.....	347
3.3.8 Kaposi's Sarcoma	354
3.3.9 Dermatofibrosarcoma protuberans.....	357
3.3.10 Cutaneous Metastases	360
3.3.11 Parapsoriasis-Group.....	362
3.3.12 Cutaneous Lymphomas	365
3.3.13 Lymphomatoide Papulose.....	370
3.3.14 Pseudolymphomas	373
3.3.15 Paraneoplastic Disorders	376

Chapter 4 - Diseases of the Appendages and of the Mucous Membranes 380

4.1 Diseases of Sebaceous and Apocrine Glands	380
4.1.1 Acne vulgaris and Subtypes	380
4.1.2 Rosacea	385
4.1.3 Periorificial Dermatitis	388

4.1.4 Hidradenitis Suppurativa	391
4.2 Diseases of Hair and Nails	394
4.2.1 Alopecia Areata	394
4.2.2 Androgenetic Alopecia	397
4.2.3 Hirsutism and Hypertrichosis.....	400
4.2.4 Nail Dystrophies	403
4.2.5 Nail Colour Changes	405
4.3 Diseases of Mucous Membranes	409
4.3.1 Oral Leukoplakia	409
4.3.2 Mucosal Aphthae	411
4.3.3 Balanitis.....	415

Chapter 5 - Diseases of Blood and Lymph Vessels, Ulcers and Panniculitis 424

5.1 Vascular Diseases	424
5.1.1 Allergic vasculitis	424
5.1.2 Varicose Veins and Chronic Venous Insufficiency	427
5.1.3 Lymphangitis.....	430
5.2 Ulcers	433
5.2.1 Venous leg ulcers.....	433
5.2.2 Arterial leg ulcers.....	437
5.2.3 Neuropathic Ulcers.....	440
5.2.4 Pressure sore	443
5.3 Panniculitis	446
5.3.1 Panniculitis	446

Chapter 6 - Genodermatoses, Metabolic Diseases and Pigmentary Disorders 450

6.1 Genodermatoses	450
6.1.1 Neurofibromatosis.....	450
6.1.2 Xeroderma Pigmentosum	454
6.1.3 Epidermolysis Bullosa	457
6.1.4 Ichthyoses	460

6.1.5 Palmoplantar Keratoderma	463
6.1.6 Dyskeratosis Follicularis Darier (DF)	467
6.1.7 Pseudoxanthoma elasticum (PXE)	471
6.2 Cutaneous Manifestations of Metabolic Diseases	474
6.2.1 Skin Changes in Diabetes Mellitus	474
6.2.2 Porphyria Cutanea Tarda	477
6.2.3 Erythropoietic Protoporphyrin (EPP)	480
6.2.4 Congenital Erythropoietic Porphyria (ERP).....	483
6.2.5 Xanthomas	486
6.3 Pigmentary Disorders	488
6.3.3 Melasma/Chloasma/PIH	488
6.3.4 Vitiligo	491
6.3.5 Oculo-cutaneous Albinism and Piebaldism	494

Chapter 7 - Proctologic Disorders and Psychodermatoses 497

7.1 Proctologic Diseases.....	497
7.1.1 Anal fissure	497
7.1.2 Haemorrhoids	500
7.2 Psychodermatoses.....	504
7.2.1 Trichotillomania	504
7.2.2 Dermatitis Artefacta	506
7.2.3 Psychogenic Pruritus.....	509
7.2.4 Obsessive-compulsive skin disorders (except 7.2.1./2.)	512
7.2.5 Body dysmorphic disorders	515

Chapter 8 - Special Conditions, Symptoms and Syndromes 519

8.1 The red face	519
8.2 Erythrodermas	524
8.3 Dry Skin.....	527
8.4 Itching	534
8.5 Urticarial syndromes.....	537
8.6 Pregnancy Dermatoses	541
8.7 Purpuric Rashes.....	548
8.8 Red swollen legs	553

8.9 Infantile skin	556
8.10 Aging skin	562
8.11 Progeria syndromes	565
8.12 Nutrition Disorders of the Skin	573
8.13 Disorders with primary and secondary deposition in the skin	578
8.14 Tropical dermatoses and travel medicine	581

Chapter 9 - General Dermatology 586

9.1 Basic Functions of the Skin	586
9.1.1 Cutaneous Anatomy and Physiology	586
9.1.2 Biochemistry	592
9.1.3 Cutaneous Immunology	599
9.1.4 Cutaneous Microbiology	602
9.2 Diagnostic Procedures.....	610
9.2.1 Bedside Tests	610
9.2.2 Non-invasive imaging methods in Dermatology	612
9.2.3 Basics in Dermatopathology	615
9.2.4 Non-invasive Methods in Dermatology:Functional Tests	624
9.3 Therapy.....	630
9.3.1 Principles of galenic formulations for topical drugs	630
9.3.2 Pharmacologic Basics of Systemic Therapy in Dermatology	634
9.3.3 Basics of Dermato-Surgery Techniques	638
9.3.4 Basics of ultraviolet radiation therapy and lasers	643

Chapter 10..... 647

10.1 Primary lesions.....	647
10.1.1 Macule	647
10.1.2 Urtica.....	648
10.1.3 Papule	650
10.1.4 Plaque	651
10.1.5 Nodule.....	652
10.1.6 Vesicle and bulla	653
10.1.7 Pustula (Pustule)	654
10.1.8 Cyst	656
10.2 Secondary lesions	657

10.2.1 Scales	657
10.2.2 Crust.....	658
10.2.3 Necrosis.....	659
10.2.4 Erosion	660
10.2.5 Excoriation	661
10.2.6 Ulcer.....	662
10.2.7 Fissure	663
10.2.8 Atrophy	664
10.8.9 Scar	665

Chapter 1 - Inflammatory dermatoses

Allergic/ Non-allergic and other immunologic reactions

1.1.1 Urticaria and Angioedema

1.1.1.1 Urticaria



Grading & Level of importance: A

M. Czarnecka-Operacz, Poznan; A. Giménez-Arnau, Barcelona; RM. Pujol, Barcelona

ICD-11

Chronic Spontaneous Urticaria EB00.1; Acute Urticaria: EB00.0; Inducible Chronic Urticaria: EB01

Synonyms

Hives, wheals, weals.

Definition

Urticaria is a group of diseases characterized by the development of wheals (hives), angioedema, or both. Urticaria needs to be differentiated from other medical conditions where wheals, angioedema, or both can occur, e.g., anaphylaxis, autoinflammatory syndromes, urticarial vasculitis, urticarial-like skin lesions, or bradykinin- mediated angioedema including hereditary angioedema (HAE).

Epidemiology

15 -20 % of the global population is estimated to have at least one episode of urticarial flare during their lifetime. Urticaria is associated in 33-67% with angioedema (see chapter 1.1.1.2). For non-acute urticaria, less information is available. **The current estimated point prevalence of chronic spontaneous urticaria (CSU) in worldwide surveys ranges from 0.5% to 1%.** The reason for the large variations between these figures is unclear. Possible explanations include differences in the methods employed as well as geographical and cultural characteristics.

Aetiology & Pathogenesis

Urticaria is a mast cell-driven disease. Histamine and other mediators, such as platelet-activating factor (PAF) and cytokines released from activated skin mast cells, result in sensory nerve activation, vasodilatation and plasma extravasation leading to the formation of urticarial hives. The mast cell-activating signals in urticaria are poorly defined and likely to be heterogeneous and diverse. The non-lesional (uninvolved) skin of chronic spontaneous urticaria (CSU) patients shows upregulation of adhesion molecules infiltrating eosinophils, and altered cytokine expression. Some authors have also reported a mild to moderate increase of mast cell number in the chronic type. Skin affected by wheals virtually always exhibits upregulation of endothelial cell adhesion molecules, neuropeptides and growth factors. These findings underline the complexity of the pathogenesis of urticaria, which is composed of the wide spectrum of different features in addition to the release of histamine and other mediators from dermal mast cells. Some of these features, characteristic for urticaria are also detected in the whole variety of different inflammatory conditions and are thus considered to be not specific or of any diagnostic value.

Signs & Symptoms

A sudden appearance of raised erythematous lesions (wheals, hives), developing within the time period ranging from minutes to a few hours. It is accompanied by **pruritus and/or burning sensation.** The lesion presents the tendency to enlarge to the margins and show a flattening in the middle often leading to a circular pattern until they flatten more and more and finally disappears. Angioedema often occurs simultaneously with the hives. If individual hives persist for more than 24 hours, the possibility of another pathology i.e., urticarial vasculitis must be considered (skin biopsy is very much useful at that stage).

Localisation

Hives may appear on any part of the skin (no specific skin region). They are of different sizes, as well as shapes and may aggregate into plaques. Hands and feet are prone to present with angioedema (rather than hives), and may significantly impair the normal mobility of the fingers and wrists. **Angioedema also tends to involve eyelids and lips.** Some special types of urticaria are of a papular morphology and follicular distribution as in e.g., cholinergic urticaria.

Classification

The spectrum of clinical manifestations of different urticaria subtypes is very wide. Additionally, two or more different subtypes of urticaria may coexist in case of one particular patient.

- Acute spontaneous urticaria is defined as the occurrence of spontaneous wheals, angioedema or both for < than 6 weeks.

- Chronic Spontaneous Urticaria is characterized by the appearance of wheals, angioedema or both for > 6 weeks due to known or unknown causes.
- Chronic Inducible Urticaria include: symptomatic dermographism, cold urticaria, delayed pressure urticaria, solar urticaria, heat urticaria, vibratory angioedema, cholinergic urticaria, contact urticaria and aquagenic urticaria.

Triggers or exacerbating factors affecting acute and chronic urticaria may vary. IgE-mediated allergic reaction (Type I Reaction) caused by hypersensitivity to specific foods, medications, venom allergens (bee or wasp and other stinging insects), foreign proteins and other exogenous materials such as latex or plant products (contact urticaria) are sometimes involved.

Chronic Urticaria is mostly an autoimmune-related process (e.g., autoantibodies against IgE or the FcE-receptor, IgE against autoantigens). Also, non-immunological factors (pseudoallergic) may be involved as direct mediator release from mast cells: caused by foods/food additives/medications i.e. NSAID (non-steroidal anti-inflammatory drugs). Other underlying diseases such as intestinal parasitic infestations, foci of infection, thyroid diseases, liver diseases (viral hepatitis), other viral infections, connective tissue autoimmune disorders may occasionally be present in acute and chronic urticaria.

Laboratory & other workups

Acute urticaria usually does not require a diagnostic workup, as it is usually self-limiting. The only exception is the suspicion of acute urticaria due to a type I food allergy in sensitized patients or the existence of other eliciting factors such as non-steroidal anti-inflammatory drugs (NSAIDs). In this case, allergy diagnostic tests as well as educational programs for patients are very useful and allow patients to avoid re-exposure to relevant causative factors. **In Chronic Spontaneous Urticaria, limited set of investigations is recommended.** Basic tests include differential blood count and CRP and/or ESR. In CSU, further diagnostic measures based on the patient history and examinations are recommended especially in patients with long-standing and/or uncontrolled disease. Standardized provocation testing to diagnose chronic inducible urticaria are required for an accurate diagnosis.

Dermatopathology

Histologically, wheals are characterized by edema of the upper and mid dermis, with dilatation and augmented permeability of the post-capillary venules, as well as lymphatic vessels of the upper dermis leading to leakage of serum into the tissue. In angioedema, similar changes occur primarily in the lower dermis and the subcutis. Usually, a minimal cellular infiltrate is observed. If a mixed inflammatory perivascular infiltrate of variable intensity, consisting of neutrophils with or without eosinophils, basophils, macrophages, and T-cells. Specific triggers such as drugs and autoimmune processes are often responsible for the development of inflammatory infiltration. Vessel-wall

necrosis, which is a hallmark of urticarial vasculitis or other types of vasculitis is not observed.

Course

Chronic spontaneous urticaria is a disease of long duration. Although the results of existing studies are inconsistent, there are four factors that seem to be associated with a long duration of urticaria:

1. Disease activity
2. Angioedema
3. Combination of chronic spontaneous urticaria with inducible urticaria
4. Autoreactivity (positivity in the autologous serum skin test).

Patients suffer significantly from the relapsing and chronic course of the disease.

Complications

Anaphylactic shock may occur in patients with the pre-existing urticaria, in such cases other diagnoses should be also considered such as acute urticaria of allergic origin, acquired cold urticaria or cholinergic urticaria. Anaphylaxis is not common in Chronic Spontaneous Urticaria. Of all diagnostic procedures, a thorough history is regarded as most important.

Differential Diagnosis

Urticaria should be differentiated from other medical conditions clinically presenting with wheals, angioedema, or both, e.g., anaphylaxis, autoinflammatory syndromes, urticarial vasculitis, or bradykinin-mediated angioedema including hereditary angioedema (HAE) and maculo-papular cutaneous mastocytosis (formerly called urticaria pigmentosa). **If individual hives persist for more than 24 hours, the possibility of urticarial vasculitis must be considered** (in such cases skin biopsy is recommended). Other diseases such as syndromes that can manifest with wheals and/or angioedema are not considered to be subtypes of urticaria, due to their distinctly different pathophysiologic mechanisms. An important differential diagnosis in this context is Sweet's Syndrome.

Prevention & Therapy

The first step in the management is the attempt **to identify and eliminate underlying cause(s) and/or eliciting trigger(s)**. A thorough case history is essential.

The second step consist in several therapeutic approaches aimed at providing symptoms relief. While

eliminating the cause is the most desirable option, this seems to be not applicable in many cases. Currently, an intensive diagnostic program is recommended, particularly for patients that suffer from long-standing and severe urticaria (S3 guidelines). The objective is to obtain complete control of the signs and symptoms as quickly as possible and treat the disease until it is completely controlled by the effective and safe management. **For Chronic Urticaria, the use of second generation anti H1 at licensed dose and at higher doses is recommended.** In case the high dosage anti H1 fails the recommendation is to add **anti-IgE therapy**, nowadays omalizumab. There now new even more effective drugs to come for prescriptions such as the Bruton Tyrosinase Inhibitors (BTK's fenbrutinib, remibrutinib) which are essential for FcεRI-mediated mast cell activation and essential for autoantibody production by B cells in chronic spontaneous urticaria (CSU).

Ciclosporin is also an effective drug for CSU, dedicated to patients with no response to omalizumab. A good number of alternative treatments may be considered e.g., methotrexate. Some special diets, which limit or eliminate certain allergens or pseudoallergens, can be considered. However, validated in vitro and in vivo test results must be verified before commencement of such treatment.

Special

International patient website for help to cope with disease: [Cruse Control App](#)

References

- [Antia C, Baquerizo K, Korman A, Bernstein JA, Alikhan A. Urticaria: A comprehensive review: Epidemiology, diagnosis, and work-up. J Am Acad Dermatol. 2018; 79:599-614.](#)
- [Maurer M, Fluhr JW, Khan DA. How to Approach Chronic Inducible Urticaria. J Allergy Clin Immunol Pract. 2018; 6:1119-1130.](#)
- [Kolkhir P, Giménez-Arnau AM, Kulthanan K, Peter J, Metz M, Maurer M. Urticaria. Nat Rev Dis Primers. 2022; 8:61.](#)
- [Lang DM. Chronic Urticaria. N Engl J Med. 2022; 387:824-831.](#)

1.1.1.2 Angioedema

Grading & Level of importance: B
H. Gollnick, Magdeburg



ICD-11

Idiopathic: 4A00.15; hereditary 4A0014; drug induced EH61.1; others 4A06.1Y

Synonyms

Quincke edema, angioneurotic edema, hereditary edema.

Definition

Angioedema presents as an acute or slowly progressing dermal and subdermal edema, persisting for several hours to days. This involves the subcutis, mucosal and submucosal tissue. It may occur either as a solitary finding which is localized, or in a disseminated pattern. It may appear following, or in parallel, with urticaria or is part of a hereditary form of angioedema.

Epidemiology

Angioedema is common. However statistical data depend on the subtype. No exact statistical data are available for spontaneous angioedema, which may be allergic or so called pseudoallergic. The prevalence of hereditary angioedemas is about 1:50,000 for type I (85%) and II. Type III is rare, almost always females are affected.

Aetiology & Pathogenesis

Most of the pathogenic causes of angioedemas are of histamine-related allergic or 'pseudoallergic' nature, following the course of different types of urticaria. **Hereditary forms HAE type I (INH-activity loss) and II (INH-activity partial deficient)** are observed where there is no primary urticaria. Subtype III has a normal INH-activity and is bradykinin driven. **C1-esterase inhibitor deficiency type I and II** may be induced by renin-angiotensin system-related drugs (ACE and dipeptidylpeptidase inhibitors). It may also be a paraneoplastic phenomenon. The gene defect is localized on chromosome 11 subregion q11.2–q13. Kallikrein and factor XIIa cannot be controlled in the acute attack and the bradykinin cascade is activated.

Signs & Symptoms

Subcutaneous and mucosal oedema (face, upper and lower airways, esophageal-gastro-intestinal and genital tract) with the sensation of tightness or swelling are the main symptoms. Sometimes it can be itchy or even painful. The velocity of lesion development varies from acute to slowly progressing.

Localisation

Sites of predilection are: **face (eyelids, lips), mucosal: tongue, larynx, genitalia.**

Classification

- Spontaneous and urticaria-related;
- acquired bradykinin driven without C1-INH deficiency;
- type I-II hereditary C1 –INH loss or deficiency or dysfunction, and
- type III bradykinin driven without C1-INH deficiency.

Laboratory & other workups

See urticaria for diagnostics. Allergic: IgE, specific IgE, histamine, diaminoxidase, tryptase.

In addition: C1-esterase inhibitor analysis and complement C4 (both concentration + activity). C1-INH autoantibodies and C1q.

Dermatopathology

Edema of the dermal, subcutaneous and submucosal and mucosal tissue without inflammatory infiltrate. Mast cell degranulation. In drug induced urticaria and angioedema eosinophils are sometimes seen.

Course

Acute onset or progressive development. In allergic and hereditary types chronic both relapsing courses exist.

Complications

Airway obstruction, laryngeal oedema, birth delivery complications (be aware of hereditary C1-esterase inhibitor deficiency). Death.

Diagnosis

Clinical, laboratory.

Differential Diagnosis

Depending on acute or slowly developing course. Physical urticaria (pressure, vibration), autoimmune diseases (Lupus erythematosus, dermatomyositis), acute lymphedema, acute phase of herpes zoster and erysipelas, trichinosis. Acute contact dermatitis. Melkersson-Rosenthal

syndrome, M.Morbihan. Traumatic edema in subcutaneous and muscular tissue.

Prevention & Therapy

Preventive: if origin and type of angioedema development in relapsing courses of already known underlying disease are explored, avoidance of trigger factors (histamine or bradykinin provoking agents) and in for example hereditary courses substitution of disease associated drugs.

Acute: depending on the localization and the acuity one would either give systemic antihistamines orally or by injection, systemic corticosteroids and adrenaline i.m. (autoinjector).

For C1-esterase inhibitor deficiency: replacement of C1-esterase inhibitor (if not available, fresh frozen plasma), concentrated C1-inhibitor infusion, Conestat alfa is a recombinant human (rh) C1-Inhibitor, bradykinin - B2 receptor antagonist infusion (icatibant, lanadelumab), recombinant C1 inhibitor. (Danazol or tranexamic acid for long-term prophylaxis only, however, less used currently). Suspicious drugs as trigger of acute attacks or maintaining symptoms have to be investigated fully and stopped. Before birth delivery prophylactic recombinant C1 inhibitor should be given or stand by procedure.

Special

In hereditary angioedema genetic counselling is recommended for family members. Postnatal investigation of gene defect presence.

References

- [Busse PJ, Christiansen SC. Hereditary Angioedema. N Engl J Med. 2020;382:1136-1148.](#)
- [Kazandjieva J, Christoff G. Angioedema as a systemic disease. Clin Dermatol. 2019; 37:636-643.](#)
- [Montañez MI, Mayorga C, Bogas G, Barrionuevo E, Fernandez-Santamaria R, Martin-Serrano A, Doña I \(2017\) Epidemiology, mechanisms, and diagnosis of drug-induced anaphylaxis. Front Immunol 8:614](#)
- [Velasco-Amador JP, Prados-Carmona A & Navarro-Trivino FJ. If not angioedema, what is it? Diagnostic approach to facial edema. JDDG \(2024\) 22: 501-512](#)

1.1.2 Eczematous dermatoses

1.1.2.1 Atopic Dermatitis



Grading & Level of importance: B

M. Czarnecka-Operacz, Poznan; G. Girolomoni, Verona; P. Gisondi, Verona; M. Maurelli, Verona

ICD-11

Code: EA80.

Synonyms

Atopic eczema, endogenous eczema, neurodermatitis.

Definition

Atopic dermatitis is a chronic-recurrent eczema typically occurring in patients with atopic diathesis, characterized by classical findings of **dry skin, pruritus, acute exudative flares, and scaly and thickened skin appearance in chronic phases.**

Epidemiology

Highly prevalent in infants and children (10-20%) and adults (2-4%).

Aetiology & Pathogenesis

- **Genetically determined or acquired epidermal barrier defects (structural and functional skin barrier impairment)**, in some parts of the population. **Mutations in profilaggrin** gene and other structural epidermal proteins (e.g., hornerin, claudin and alterations in the desquamation process (e.g., stratum corneum proteases), xerosis.
- **Genetically determined immune reaction pattern** (excessive IgE production possible, disturbance in helper T-cell balance with Th2 favoured over Th1).
- Common triggers: **environmental factors** (humidity, water hardness, pollution), house dust mites, psychological stimuli.

Signs & Symptoms

Eczema appearance with erythema and vesiculation in the acute phase and erythema, scaling and lichenification in the chronic phases. Skin may become thickened sometimes covered with scratch marks and even scars. Another clinical feature is prurigo. **Pruritus is always present**; it can be devastating and

usually interfere with sleeping and work productivity, significantly affecting the quality of life. The patients are prone to develop secondary skin infections, bacterial or viral. **Dry skin always present.** Other clinical features include: nummular eczema and excoriated nodules (prurigo). Therefore, the clinical picture may be heterogenous (different phenotypes of atopic dermatitis). Several atopy scores (e.g., SCORAD, EASI, POEMS) have been developed to quantify disease severity.

Localisation

- **Localisation may be age dependent**
 - Face and neck
 - Flexures (antecubital, popliteal, flexor aspect of wrist)
 - Hands, feet
 - The whole body surface may be affected, even extending to erythroderma.

Classification

Intrinsic and extrinsic atopic dermatitis.

- Extrinsic form, also defined as allergic type, accounts approximately for 80% of cases, characterized by high total serum IgE levels and the presence of specific IgE directed against the wide spectrum of environmental allergens; associated with asthma and/ or rhinoconjunctivitis.
- Intrinsic form, also defined as non-allergic, approximately 20%, normal total serum IgE levels and no serum specific IgE to be detected.

Laboratory & other workups

Total serum IgE >100 kU/l, sometimes blood eosinophils elevated serum eosinophilic cationic protein often multiple positive skin prick tests or serum, patch testing with airborne allergens after tape stripping of stratum corneum (atopic patch test).

Dermatopathology

In the acute phase, the histology is characterized by spongiosis, perivascular lymphohistiocytic infiltrates and some eosinophilia in upper dermis. In the chronic, parakeratosis, acanthosis, superficial perivascular lymphohistiocytic infiltrate.

Course

The course is chronic-relapsing. Cradle cap after 3 months of age, weeping dermatitis in childhood, dry, itchy skin in adolescents and adults. Atopic dermatitis has been associated with an increasing number of comorbidities, typically sharing some common pathological mechanism. In addition, there are cardiovascular, autoimmunological, neurological, psychological and other comorbidities which should be monitored in atopic dermatitis patients. The atopic march represents the natural progression of atopic diseases, is given by the deregulated epidermal barrier that facilitates allergic sensitization and starting with atopic dermatitis and followed by other atopic conditions, such as asthma, rhinoconjunctivitis. Many children outgrow the disease at school age or puberty. Early onset and severe cases persist into adulthood. About one third of adult cases is new onset disease (late and very late onset atopic dermatitis).

Complications

Tendency to superinfection by bacteria (*Staphylococcus aureus*: impetiginization) and viruses (eczema herpeticum/molluscum contagiosum). Eczema herpeticum may be complicated by visceral involvement (pneumonia).

Diagnosis

Typical personal and family history, characteristic clinical picture, relevant laboratory tests, often coexisting atopic disorders (allergic rhinitis, conjunctivitis, asthma or type 1 food allergies).

Differential Diagnosis

Differential diagnosis includes seborrhoeic dermatitis, psoriasis, allergic contact dermatitis, nummular eczema, tinea, scabies, early patch stage mycosis fungoides.

Prevention & Therapy

1. General measures:

- Counselling regarding skin care, avoidance of aggravating factors. Patient handouts and educational material or links are valuable.
- Moisturising, often with emollients containing urea, bacterial lysates (eg. *Vitroscilla filliformis*) and other factors.
- Gentle cleansing (use of soap substitutes).
- Elimination of triggering environmental factors

2. Mild forms:

- **Topical corticosteroids**, including combined products containing additional antimicrobial agents (short-term to avoid bacterial resistance).
- **Topical immune modulators** (tacrolimus, pimecrolimus, crisaborole).

3. Severe forms:

- **Cyclosporine A or other systemic immunosuppressants** (methotrexate, azathioprine, mycophenolate mofetil).
- Short-term systemic corticosteroids.
- **Biological therapy:** Dupilumab is a human monoclonal antibody directed against IL-4/IL-13 receptor- α chain and thus block both IL-13 and IL-4. Tralokinumab and lebrikizumab are monoclonal antibodies that block IL-13. They are not generally immunosuppressive and do not require laboratory screening and monitoring. Dupilumab licensed from age of 6 years and tralokinumab from age 12.
- **Janus kinase (JAK) inhibitors:** Abrocitinib and upadacitinib, JAK1 selective inhibitors; baricitinib, a JAK1 and JAK2 inhibitor. Abrocitinib and upadacitinib are a bit more rapidly efficacious than dupilumab but have some contraindications and require laboratory screening and monitoring. Upadacitinib licensed from age 12. Oral JAK inhibitors have a black box warning on increased risk of developing serious infections, major cardiovascular events, venous thromboembolism and malignancy.
- Other new treatments under development.

4. Prevention:

- Intensive and regular use of skin emollients and ointments, in every age. Prevention is important to minimize the occurrence of asthma and rhino-conjunctivitis (atopic march). Proactive use of topical drugs significantly reduces frequency of relapses.

Special

None.

References

- [Ständer S. \(2021\). Atopic Dermatitis. N Engl J Med. Mar; 384\(12\):1136-1143. doi: 10.1056/NEJMra2023911. PMID: 33761208.](#)
- [Frazier W, Bhardwaj N. \(2020\). Atopic Dermatitis: Diagnosis and Treatment. Am Fam Physician. May; 101\(10\):590-598. PMID: 32412211.](#)
- [Tokura Y, Hayano S. \(2022\). Subtypes of atopic dermatitis: From phenotype to endotype. Allergol Int Jan; 71\(1\):14-24. doi: 10.1016/j.alit.2021.07.003. Epub 2021 Jul 31. PMID: 34344611.](#)

- [Yew YW, Thyssen JP, Silverberg JI. \(2019\). A systematic review and meta-analysis of the regional and age- related differences in atopic dermatitis clinical characteristics. J Am Acad Dermatol. Feb; 80\(2\):390-401. doi: 10.1016/j.jaad.2018.09.035. Epub 2018](#)
- [Facheris P, Jeffery J, Del Duca E & Guttman-Yassky E \(2023\) The translational revolution in atopic dermatitis: the paradigm shift from pathogenesis to treatment Nature Cellular & Molecular Immunology \(2023\) 20:448–474](#)

1.1.2.2 Allergic contact dermatitis

Grading & Level of importance: B
M. Bagot, Paris; M. Czarnecka-Operacz, Poznan



ICD-11

Code: EK00

Synonyms

Allergic contact eczema, contact dermatitis.

Definition

Allergic contact dermatitis is a common type of dermatitis presenting with eczematous skin lesions, caused by **delayed hypersensitivity reaction (type IV) provoked by skin exposure to exogenous (contact-) allergens (haptens)**.

Epidemiology

An estimated 15–20% of the general population suffers from contact allergy.

Aetiology & Pathogenesis

Allergic contact dermatitis is mediated by allergen-specific sensitized T-cells and is a form of type IV reaction, according to Gell and Coombs. Immunological sensitization time is at least 5-10 days; clinical symptoms may first develop after months to years. The dermatitis appears in sensitised individuals after a latency period of 8-24 hours, occasionally longer. Individual allergens have varying degrees of allergic potential. Most frequent contact allergens are:

- **Metals** (e.g. nickel in ear jewelry, jeans buttons, coins)

- **Fragrances** (in cosmetics, hygiene products, industrial products),
- **Natural substances** (such as resin, balsam of Peru, compositae (aster, daisy, sunflower family),
- **Rubber ingredients** (rubber additives such as thiurams, carbamates),
- **Preservatives** (such as isothiazolinone, methyl-3-bromo-butyronitril, formaldehyde),
- **Occupational substances** (such as epoxies, chrome salts (cement and leather), p-phenylenediamine).
- **Aerogen / airborne delivered contact allergens**

Signs & Symptoms

The reaction starts at the site of allergen contact as an acute papulo-vesicular eruption which soon becomes eroded and weeping. It is accompanied by intense pruritus. The lesions present with irregular border, spreading outside area of the initial contact. In the next stage, scaling and crusting may develop. In chronic forms, lichenification and fissuring dominate. Sometimes, allergic contact dermatitis may present as a chronic disease without the acute phase.

Localisation

The localisation depends on the type of exposure. Extensive (haematogenous) contact dermatitis may be caused by systemic exposure (ingestion, inhalation) of contact allergens. **The affected site is a clue to the possible culprit allergen:**

- Face: cosmetics, airborne allergens (paint vapours or pollens)
- Ears: jewelry, glasses, hearing aids.
- Lips: cosmetics, herpes simplex medications.
- Forehead/neck: shampoos, hair dyes.
- Neck/fingers/wrist: jewelry.
- Hands: occupational and recreational contact allergens.
- Axillae: deodorants. Feet: shoes, antifungals.
- Mouth: dentures, other dental products.
- Lower leg: elastic stockings, medications for leg ulcers.

Classification

None.

Laboratory & other workups

The allergen causing contact dermatitis may be determined by patch testing. Several series of patch tests may be used: standard series of most frequent allergens, special series for selected occupational diseases, emollients or any other substances suspected to be a causative factor (delivered by the patients) may be also tested. ROAT (repeated open application test) may be useful for low allergenic substances and selected topical medications.

Dermatopathology

Cutaneous histology of the lesions shows parakeratosis, **spongiosis**, acanthosis, and an inflammatory lymphohistiocytic infiltrate with exocytosis of lymphocytes into epidermis. Intraepidermal vesicles can develop.

Course

The clinical features usually subside after 1-2 weeks of allergen avoidance; contact sensitivity usually persists lifelong via memory T-cells.

Complications

Allergic contact dermatitis can be complicated by impetiginization, the disease may become chronic (even after allergen avoidance). The lesions may disseminate and develop to an erythrodermic form of the disease.

Diagnosis

It is mandatory to characterize the causative allergen by performing a detective work (detailed history) - work, hobbies, habits), and patch testing oriented by the case history.

Differential Diagnosis

Allergic contact dermatitis must be differentiated from other inflammatory diseases such as psoriasis and dermatophyte infection in case of foot and hand involvement. It must also be differentiated from therapy-resistant localized dermatitis: Bowen's disease, Paget's disease of the nipple, lupus vulgaris. Reaction to Latex can cause an IgE-mediated immediate type allergy in addition to a type IV allergic reaction. A subtype is eczema in psoriatic in which psoriasis of palms and soles may provoked or maintained by contact allergens.

New allergens are constantly being registered as possible causative haptens in allergic contact dermatitis (update of the patch tests series, profession/occupation-related haptens containing series, etc.).


Prevention & Therapy

It is very important **to avoid contact with the causative allergens**, and also with additional irritating factors (for example, using soap substitutes). **Topical therapy consists of wet dressings or baths, and mainly corticosteroids as well as calcineurin inhibitors**. An appropriate vehicle (ointment, cream, lotion) should be selected according to the morphological characteristics of skin lesions. Phototherapy may be indicated in some cases. Oral alitretinoin (retinoid) may be effective in severe refractory hand dermatitis.

References

- [Nassau S, Fonacier L. Allergic Contact Dermatitis. \(2020\) Med Clin North Am.; 104:61-76.](#)
- [Kostner L, Anzengruber F, Guillod C, Recher M, Schmid-Grendelmeier P, Navarini AA. \(2017\) Allergic Contact Dermatitis. Immunol Allergy Clin North Am.37:141-152.](#)
- [Becker D. Allergic Contact Dermatitis. \(2013\) J Dtsch Dermatol Ges.11:607-19.](#)
- [Tramontana M, Hansel K, Bianchi L, Sensini Ch, Malatesta N & Stingeni L \(2023\) Advancing the understanding of allergic contact dermatitis: from pathophysiology to novel therapeutic approaches Frontiers in Medicine 10:1184289](#)

1.1.2.3 Irritant Contact Dermatitis

Grading & Level of importance: B. 

M. Czarnecka-Operacz, Poznan; A. Gimenez-Arnau, Barcelona; RM. Pujol, Barcelona

ICD-11

EK02

Synonyms

Irritant contact dermatitis. Irritant dermatitis. Irritant contact eczema.

Non immunologic contact dermatitis.

Cumulative toxic dermatitis, “wear and tear” dermatitis.

Definition

Irritant contact dermatitis (ICD) may be defined as a **non-allergic inflammatory reaction of the skin to an external agent, not requiring sensitization.**

Epidemiology

Point prevalence about 1- 2% in the healthy population.

Aetiology & Pathogenesis

ICD is caused by chemicals, which damage skin structures in a direct non-allergic way. It is a **dose dependent reaction** from exposure to irritants (chemical and/or physical). The most frequent chemical irritative factors are long lasting and repetitive contact with water (“wet work”), detergents and/or solvents. Skin barrier perturbation facilitates irritant substances to penetrate the stratum corneum causing cytotoxic effects on keratinocytes and release of cytokines and chemokines. The innate immune system is activated and ICD reaction is initiated, however, the immunological cascade of priming (for example T-cells of the helper cell type) does not occur.

For acute ICD, the reaction is often caused by a single exposure and usually resolves within days to weeks. Release of pro-inflammatory mediators, including cytokines (IFN- γ , IL-4 and IL-17), resulting in vasodilatation and cell infiltration. Spongiosis leads to vesicle formation, erythema, induration and edema. Chronic ICD is a multifactorial disorder involving exogenous and endogenous factors. Endogenous factors include variations in the skin barrier structure and composition, innate immunity reactivity variations and an atopic background. A history of atopic dermatitis quadruples the risk of hand eczema when skin is exposed to wet work. Some genetic risk factors have been detected.

Signs & Symptoms

The morphology of cutaneous irritation varies widely and depends on the type and intensity of the irritant(s). The following types can be described:

- Acute ICD
- Chronic ICD

Folliculitis, miliaria, pigmentary alterations, alopecia, contact urticaria or granulomatous reactions that may result from irritants are not considered ICD.

Chemical insults to the skin may develop after exposure to potent acidic or alkaline substances. Severe tissue damage may result even after a short contact. Initial painful cutaneous whitening and edema, followed by necrosis and scarring is usually observed.

An irritant reaction is often monomorphic (erythema, wheals, papules, pustules), but may vary according to the type of exposure, body region and individual susceptibility.

The clinical signs of acute ICD include erythema, edema, inflammation and vesiculation. ICD can be clinically indistinguishable from the allergic type. Symptoms may range from mild erythema through exudative cutaneous inflammation to ulcerative lesions and epidermal necrosis. Acute ICD usually exhibits an asymmetrical distribution and sharply demarcated borders. Some chemicals may produce delayed acute irritation (8-24 hours or more after exposure).

Chronic ICD shows erythema and increasing dryness (xerosis), followed by hyperkeratosis with frequent fissuring and occasional erythema. The lesions are usually localized but ill defined. Pruritus and pain due to fissures are symptoms of chronic ICD. Hand eczema is a common clinical presentation.

Localisation

ICD can involve any area of the body surface in contact with the irritant. **The hands are the most common location for chronic ICD** and many times show an occupational relevance.

Classification

Contact dermatitis is defined as inflammation of the skin involved as a result of exposure to an exogenous agent and is generally divided into irritant contact dermatitis (ICD) and allergic contact dermatitis (ACD).

Clinical classification of ICD is based in the clinical diversity according with both morphology and mode of onset. The various forms of ICD include: acute ICD, delayed contact ICD, irritant reaction, chronic ICD, traumatic ICD, acneiform ICD, non-erythematous irritation, subjective or sensory irritation, friction dermatitis and asteatotic irritant eczema.

Laboratory & other workups

Patch testing is mandatory if the ICD is present for more than 3 months. **Patch test results may help to differentiate an allergic from an irritative reaction.**

Less frequent ICD clinical manifestations include purpuric reactions caused by metallic salts (cobalt chloride), and pustular reactions with metals (chromium, cobalt, and nickel). Although in most cases a negative result excludes a contact dermatitis, in case of a high suspicion of sensitization, the possibility of a false negative result should be considered.

Several diagnostic tests to evaluate the individual susceptibility to irritants are not used in clinical practice. These are: alkali resistance (sodium hydroxide), ammonium hydroxide, dimethylsulfoxide, threshold response to various irritants (sodium lauryl sulphate, nonanoic acid, etc), lactic acid stinging, minimal erythema dose with UVB or measurement of transepidermal water loss (TEWL).

Dermatopathology

Irritants produce a variety of histopathological changes (epidermal single cell and complete necrosis,

spongiotic dermatitis). Irritants can induce necrosis of keratinocytes, which may become confluent, and the intraepidermal vesicles soon develop into vesiculo-pustules with dermal and epidermal inflammatory infiltrate mainly constitute by lymphocytes and also neutrophils. The pattern may be different according to concentration of the irritant, type, duration of exposure, and individual reactivity of the skin. ICD shows much greater histological pleomorphism than allergic contact dermatitis (ACD).

Course

The course can be acute or chronic depending on the concentration and length of exposure to the exogenous substance. High-risk professions are nursing, hairdressing, food processing, construction work, etc. **ICD can be occupationally relevant.**

The frequency, duration and form of contact to irritants can influence in the course of the disease. Decreasing the frequency of contact to an irritant is a crucial factor in individual measures of prevention and can be achieved by appropriate hand washing and hand protection at working place. An occlusive contact potentiates the irritant effect. Temperature is also a relevant factor and mechanical irritation promotes chemical irritation. The simultaneous action of different irritants may potentiate the intensity of irritation.

Complications

ICD favors the risk of contact sensitization and the development of a secondary allergic sensitisation. Eczematous skin also is prone to be infected (impetiginization).

Diagnosis

The diagnosis is based in the history, clinical features and localization usually limited to areas of contact. It is necessary to rule out contact sensitization using patch test.

Differential Diagnosis

Differentiation between ICD and ACD is frequently very difficult on the basis of clinical morphology only. The clinical picture in both conditions may include erythema, vesicles, lichenification, excoriations, scaling and hyperkeratosis. Distinguishing irritation from allergy is complicated, since many allergens have irritant effects and both types of contact agents act jointly. A careful history, thorough knowledge of the patient's chemical and physical factors environment, and patch testing will be helpful in differentiating between both disorders.

ICD should be differentiated from an immediate type of stinging (e.g., induced by alcohol). This develops after exposure and abates quickly within seconds or minutes. Delayed stinging builds up over a certain length of time, does not disappear after removal of the causative agent, occurs frequently in the face when sweating and is experienced primarily by predisposed individuals ("stingers"). These individuals can be

identified by a positive response to 5% lactic acid. They are often fair-skinned, have history of “sensitive” or “dry” skin and reveal an atopic background.

Other differential diagnoses in particular on palms and soles are chronic psoriasis, eczema in psoriatic and palmo-plantar keratodermas as well as cutaneous T-cell lymphoma.

Prevention & Therapy

The most important therapeutic approach in the treatment of ICD is the identification of the causative chemicals, climatic and mechanical factors. Mild forms may be controlled by the regular use of emollients/moisturizers. Severe relapsing forms require corticosteroids, topical calcineurin inhibitors, ultravioletlight treatment and close adherence to prevention strategies.


Special

Primary to tertiary preventive measures are necessary. For prevention, irritants do not always have to be avoided completely. A reduction of the duration and frequency of contact is sufficient. This reduction can mostly be achieved by correct use of individual skin products like gloves or protecting clothing but must be supported by correct education and continued motivation of employees. When ICD is of occupational relevance, cessation of the implicated activity may be required, particularly if the patient’s compliance is low. Preventive measures are necessary in and out of work.

References

- [Patel K, Nixon R. Irritant Contact Dermatitis - a Review. Curr Dermatol Rep. 2022; 11:41-51.](#)
- [Bains SN, Nash P, Fonacier L. Irritant contact dermatitis. Clin Rev Allergy Immunol 2019; 56:99–109.](#)
- [Dickel H, Kuss O, Schmidt A, Kretz J, Diepgen TL. Importance of irritant contact dermatitis in occupational skin disease. Am J Clin Dermatol. 2002; 3:283-9.](#)
- [Ale IS, Maibach HI. Irritant contact dermatitis. Rev Environ Health. 2014; 29:195-206.](#)

1.1.2.4 Nummular Dermatitis

Grading & Level of importance: B 

A. Gimenez-Arnau, Barcelona; RM. Pujol, Barcelona

ICD-11

EA82

Synonyms

Discoid eczema; Nummular eczema; Dermatits nummularis.

Definition

Acute to chronic eczema with sharply-bordered, coin-shaped patches or plaques.

Epidemiology

Prevalence is not clearly defined, around 1 - 9% in the elderly.

Aetiology & Pathogenesis

Not fully known. Microbial colonization and microtrauma as well as nickel contact allergy play a role. **Sometimes it is associated with dry skin (asteatotic eczema) and stasis dermatitis** due to chronic venous insufficiency and to cardiac or hepatic failure associated edema. In many cases (children) can manifest as a feature of atopic dermatitis (nummular type). Often a systemic focal infection can drive the disease such as tooth granulomas and chronic tonsillitis. In adults, varicose veins may trigger nummular dermatitis.

Signs & Symptoms

Nummular (= coin-shaped), exudative patches and plaques, often with crusts. Early lesions: confluence of papules or papulo-vesicles on an erythematous base to form circular or oval plaques. Progression to a more scaly stage with a central clearing and peripheral extension. Pruritus may be intense, sometimes with excoriations.

Localisation

Sites of predilection: upper and lower shins, hands, forearms, trunk. Occasionally in a symmetrical

distribution.

Classification

Different patterns: Discoid eczema of the hands and forearms (women often as a single plaque: dorsa of the hands and fingers).

Discoid eczema of the limbs and trunk (male patients: lower legs, limbs and trunk). "Dry" discoid eczema (non-itchy, persistent).

Laboratory & other workups

KOH examination to exclude tinea infection.

Dermatopathology

Typical histology for spongiotic dermatitis reflecting the acute/subacute or chronic nature of the lesion (see Atopic Dermatitis). The chronic type has to be differentiated from psoriatic plaques.

Course

Chronic, with occasional flares; may be somewhat resistant to therapy.

Complications

Secondary bacterial and mycotic infections.

Diagnosis

The clinical feature, histopathological evaluation and clinical examination.

Differential Diagnosis

The spectrum of differential diagnoses is quite large: **tinea corporis**, **psoriasis of chronic plaque type**, irritant and allergic contact dermatitis, stasis dermatitis, cutaneous T-cell lymphoma, secondary impetiginization of pre-existing lesions.

Prevention & Therapy

Prevention: the first step is hygiene measures, but avoiding over-washing of the skin. Emollients and avoidance of irritants are necessary.

The most often used topical treatments are corticosteroids of different strength or combinations of corticosteroids with antiseptics such as triclosan. Occasionally oral antibiotics can be necessary when a systemic focus has been detected. For acute lesions one should use local drying measures with antiseptics and astringent substances. In cases where the course is chronic, if the disease is very itchy or if the quality of life is markedly reduced, systemic corticosteroids and immunosuppressive agents maybe administered, if an infectious focus is ruled out or properly treated.

References

- [Leung AKC, Lam JM, Leong KF, Leung AAM, Wong AHC, Hon KL. Nummular Eczema: An Updated Review. Recent Pat Inflamm Allergy Drug Discov. 2020; 14:146-155.](#)
- [Aoyama H, Tanaka M, Hara M, Tabata N, Tagami H. Nummular eczema: An addition of senile xerosis and unique cutaneous reactivities to environmental aeroallergens. Dermatology. 1999; 199:135-9](#)

1.1.2.5 Seborrheic Dermatitis

Grading & Level of importance: B
H. Gollnick, Magdeburg



ICD-11

EA81

Synonyms

Malassezia folliculitis; seborrheic eczema; cradle cap (in infants).

Definition

Seborrheic dermatitis is a chronic recurrent inflammatory dermatitis with yellow-white fine to moderate scaling on an erythematous background which may involve the face, scalp and other seborrheic areas of the body.

Epidemiology

Seborrheic dermatitis is a very common disease in different ages. About 5% of the population needs

treatment. In infants, it starts during the first three months and may persist up to 12 months. It may be seen later in the 4th to 7th life decade. All ethnic groups are involved.

Aetiology & Pathogenesis

The exact aetiopathogenesis of seborrheic dermatitis is not fully known. A genetic background has yet not been found. **Seborrhoea** (oily skin) seems to play an important role and localisation in the areas rich in sebaceous glands is a predisposing factor. It is very important that an increased colonization of seborrheic areas by the commensal lipophilic yeast *Malassezia furfur and spp.* (formerly called *Pityrosporum ovale*) can be found. In newborn children, stimulation by a short temporary androgen availability is another cause. It may also be seen in patients who are **severely immunocompromised**, often as a HIV/AIDS-related dermatosis. Furthermore, it may be related to **nutritional deficiencies**, a subnormal or pathologic blood level of biotin (vitamin H), folic acid, selenium or zinc. Combination of these deficiencies can be found.

Signs & Symptoms

The main clinical feature is a pityriasiform scaling on an inflammatory, erythematous skin accompanied by itch. Often the patients scratch and irritation can be found. In infants, the so-called cradle cap is yellowish oily scales, which may be itchy and lead to scratching, depending of the age of the child.

Localisation

The main involved areas of the skin in adults are the seborrhoeic ones: scalp, glabella, eyebrows, submental, retroauricular, mid-face, presternal, nasolabial folds and rarely interscapular areas.

Classification

The two manifestations of seborrhoeic dermatitis are:

- The **Early type in infants usually appearing in the first 3 months of life** and involving scalp and sometimes intertriginous areas.
- The **Adult type which also involves the seborrhoeic areas**, however, the intertriginous areas are not involved and are an important differential diagnosis of intertriginous psoriasis.

More severe manifestations and courses can be seen with HIV /AIDS patients.

Laboratory & other workups

Sometimes a deficiency of folate, biotin, selenium or zinc in blood can be detected and should be substituted and the causes need to be followed up.

Dermatopathology

There is no specific dermatopathologic pattern of seborrheic dermatitis. Usually hyper- and parakeratosis of the interfollicular epidermis and the infundibulum of the hair- and sebaceous follicles can be seen. Crusts with serum influx in the stratum corneum and spongiosis in the spinous layers can be found. Typically, no Munro abscesses are associated with seborrheic dermatitis, and, if found, are a sign of overlap with psoriasis (so called seborrhiasis) or psoriasis itself.

Course

The course of the disease is variable in degree. It worsens with stress of different origin, can be provoked or even improved by UV light. Heavy colonisation may occur with *M. furfur*, the reservoir of which is in general the scalp (openings of sebaceous and hair follicles). In addition, excessive washing procedures, inappropriate local irritating topical ointments, alkaline pH, mechanic irritation and sweating all worsen the course of the disease, which in general is unpredictable.

Complications

The most important complication is an overlap with psoriasis. Sometimes a superinfection with *S. aureus* may occur, and, rarely either a toxic-irritant or an allergic contact dermatitis may develop.

Diagnosis

A diagnosis can easily be made by the presence of an oily skin, pityriasiform desquamation, typical clinical features and a distribution in the nasal folds, lateral fold of the mouth, glabella and sternal region.

Differential Diagnosis

The most important differential diagnosis in adults is a manifestation of psoriasis in the face and scalp. In childhood and in particular in infants, atopic dermatitis has to be excluded.

Prevention & Therapy

The reduction of *Pityrosporum spp* colonisation with topical imidazoles, mild keratolytic agents or topical zinc pyrithione is essential. Washing of the hair at least every other day with antimycotics in particular ketoconazol to avoid relapses is necessary. Topical zinc oil, especially in newborns, seems to be the most promising. Salicylic acid should be avoided in infants. **Short-term mild topical corticosteroids** combined with clotrimazole can be used.

Evidence for alcohol abuse in the history has to be considered (malnutrition).

Special

In case of nutritional failures, deficiencies by intestinal malabsorption of zinc, biotin, folic acid or selenium, special tests or a gastrointestinal examination have to be considered.

Parkinson`s disease severity may be linked with an increase of seborrhoea.

References

- [Karakadze MA et al. The genetic basis of seborrhoic dermatitis: a review. J Eur Acad Dermatol Venereol 2018 Apr;32\(4\):529-536.](#)
- [Jackson J.M, Andrew A, Zirwas M, & Taylor S \(2022\) Unmet needs for patients with seborrheic dermatitis J Am Acad Dermatol <https://doi.org/10.1016/j.jaad.2022.12.017>](#)

1.1.2.6 Napkin Dermatitis (classical)

Grading & Level of importance: B



RM. Pujol, Barcelona

ICD-11

EH40.10

Synonyms

Diaper dermatitis; nappy rash; diaper rash.

Definition

Acute inflammatory cutaneous reaction (irritant contact dermatitis) in areas covered by the diaper.

Disturbance of the epidermal barrier by lipases and proteases from urine and feces.

Epidemiology

Common cutaneous disorder of infancy and early childhood. Estimated incidence between 7-35%. Peak of incidence at 9-12 months of age.

Aetiology & Pathogenesis

Skin maceration through moisture and prolonged exposure to alkaline urine and feces underocclusion (diaper). Diaper dermatitis is usually observed in infants that constitutively have a poor (immature) skin barrier function. Diaper area is particularly prone to suffer disruption by damage (friction), irritation and secondary bacterial or fungal (*Candida*) infection.

Other potential incriminated factors include **excessive heat, sweat retention, warm local environment and local irritant factors** (soaps, detergents). Soaps can raise the skin pH which may also result in poor skin barrier function and an increased risk of percutaneous invasion by pathogens.

Secondary factors: Microorganisms, including bacteria (limited role) and *Candida albicans*, (identified in feces), as a causative fungal infection for severe napkin dermatitis (napkin candidiasis), and broad-spectrum antibiotics use.

Signs & Symptoms

Acute to subacute dermatitis. Well-demarcated, confluent erythema confined to the convex surfaces in contact with the napkin (upper thighs, genitalia, buttocks and lower abdomen). Skin folds often spared. Satellite lesions could be present. Chafing or frictional diaper dermatitis tends to involve the inner areas.

In the more severe form, **napkin candidiasis** may occur, where symptoms include intense erythema involving mostly the diaper area spreading into skin folds with scaling and a scalloped margin.

Localisation

Area covered by nappies (diapers), typically flexural areas. May involve the inner (frictional) or convex (irritant) surfaces or may be present as a diffuse red erythema on the thighs, genitalia, buttocks and lower abdomen.

Classification

Etiology: Frictional (chafing) dermatitis, irritant contact dermatitis, allergic contact dermatitis, and diaper candidiasis.

According to severity, napkin dermatitis has been classified as

- a. Mild: pink eruption, with scattered papules on the area covered by a diaper with or without scaling and/or dryness
- b. Moderate: Inflammation covering > 10% of the area covered by a diaper, with or without papules, edema or ulceration
- c. Severe napkin dermatitis secondary to bacterial or candida infection.

Laboratory & other workups

Clinical diagnosis. Usually not necessary in refractory cases, however, a culture may be useful in detecting a bacterial or fungal infection.

Course

Diaper dermatitis responds well to a variety of treatments. However, recurrence may be present if preventive measures are not undertaken in infants prone to this common dermatitis.

Complications

Superinfection (Candida), allergic contact dermatitis.

Diagnosis

History, clinical features. KOH examination to exclude candidiasis. Therapy-resistant and persistent cases may correspond to other disorders: streptococcal infection, dermatitis or Langerhans cell histiocytosis.

Differential Diagnosis

Atopic dermatitis, allergic contact dermatitis, seborrheic dermatitis, psoriasis, candidiasis, perianal streptococcal dermatitis should be considered; and rarely Langerhans cell histiocytosis and nutritional deficiency (acrodermatitis enteropathica).

Prevention & Therapy

- **Reduce the degree of occlusion and maceration** (change nappies [diapers] frequently, use highly-absorbent disposable ones)
- Protective agents, such as zinc oxide paste
- **Drying** disinfectant dye solutions
- **Treat secondary candidal infections** (topical antifungals [imidazoles])
- If complicated by bacterial infection, treat with oral antibiotics (cloxacillin)
- **Short-term mild topical corticosteroids** (for moderate napkin dermatitis)
- **Preventive measures** (parental advice on napkin care):
- Frequent diaper changes. Keep the skin under a diaper clean and dry.
- Protect Infant skin from irritants and prevent napkin dermatitis in the first year.

- Advise to wash with an emollient soap-free, fragrance-free liquid cleanser, or warm water.
- Avoid potential skin irritants (soaps, detergents perfumed products and alcohol/fragrance-containing products).

Use good-quality super absorbent napkins and frequent barrier preparations (cream, ointment or pastes) with ingredients that form a film and which protects skin from exposure to moisture.

References

- [Tüzün Y, Wolf R, Bağlam S, Engin B. Diaper \(napkin\) dermatitis: A fold \(intertriginous\) dermatosis.Clin Dermatol. 2015;33:477-82.](#)
- [Ravanfar P, Wallace JS, Pace NC. Diaper dermatitis: a review and update. Curr Opin Pediatr. 2012;24:472-9.](#)
- [Coughlin CC, Eichenfield LF, Frieden IJ. Diaper dermatitis: clinical characteristics and differentialdiagnosis. Pediatr Dermatol. 2014; 31 Suppl 1:19-24.](#)
- [Cohen B. Differential Diagnosis of Diaper Dermatitis. Clin Pediatr \(Phila\) 2017; 56\(5 suppl\):16S- 22S](#)
- [Adelaide A. Hebert, \(2021\) New therapeutic horizon in diaper dermatitis :novel agents with novel action.Int J Womens Dermatol 7\(4\): 466–470](#)

1.1.2.7 Dyshidrotic Dermatitis

Grading & Level of importance: B

A. Gimenez-Arnau, Barcelona; RM. Pujol, Barcelona



ICD11

EA85.0

Synonyms

Dyshidrosis; cheiro-podo-pompholyx; vesicular dermatitis of hands and feet.

Definition

It is a **vesicular sometimes even bullous eruption at palmo-plantar sites** and has characteristics of an eczema.

Epidemiology

There are no valid epidemiological studies published in the literature. However, statistics from Sweden show that 1 in 2000 of the population may be affected. In cases with allergic or non-allergic hand dermatitis of acute and subacute course, a prevalence of around 5 - 20 % of cases is given. Females and males in adult age are equally distributed.

Aetiology & Pathogenesis

It represents an eczematous vesicular reaction pattern involving the hands and/or feet and is mostly secondary to a variety of stimuli. **Idiopathic, allergic or non-allergic contact reactions, atopic dermatitis, eczematous reaction to distal infections** such as tinea (then known as an id reaction) or bacterial infections are common causes. Dyshidrotic eczema of the hands is more frequently observed in patients sensitized to nickel sulfate. Sometimes a nickel-rich diet could cause clinical flares via the systemic route.

No clear-cut connection with sweat gland activity or malfunction exists. Therefore, the (historical) term dyshidrosis may be misleading.

Signs & Symptoms

The **tiny pruritic, clear fluid-filled vesicles on palms and soles arise on the lateral and palmar surfaces of the fingers and the lateral sides of the toes**. Sometimes, the vesicles can remain very discrete and dry quickly (small yellowish-brown scales), with a centrifugal desquamation. In other cases, vesicles become confluent, multilocular, sometimes haemorrhagic, with bullae formation and oozing (bullous dyshidrosis or cheiro-podo pompholyx).

The appearance of vesicles is usually accompanied by strong pruritus, which leads to secondary scratching. Deep and painful fissures can accompany dyshidrotic eczema. Sometimes the eruption may evolve into a chronic hand eczema.

Localisation

Hands and feet, palmar and lateral areas of the fingers and toes, and also soles and palms. The lesions may spread to the back of the fingers, backs of hands, wrists, back of feet, ankles.

Classification

According to the course it may be **acute** or **subacute** or **chronic** with vesicular flares. Depending on the causes underlying one can further subtype into idiopathic subtypes or secondary forms to contact allergy, atopy, or reactions to infections such as tinea (then known as an "id" reaction).

Dyshidrosis lamellosa sicca, also known as keratolysis exfoliativa (KE), or focal palmar peeling syndrome

is considered a subtype of dyshidrotic eczema and characterized by superficial dry blister roofs and collarette desquamation manifesting as non-inflammatory irregular circumscribed annular or circinated patches on the palms and soles. It is typically observed in young patients sometimes with an atopic background that complain of recurrent asymptomatic peeling on the palms (and occasionally the soles).

Laboratory & other workups

Where distant mycological or bacterial infection is suspected, microbiological cultures may be useful. Patch test to rule out an associated allergic contact dermatitis. Measurement of IgE may also be helpful to rule out atopic dermatitis.

Dermatopathology

Intraepidermal spongiotic vesicles mostly close to the acrosyringial orifices. Congestion of the dermal sweat gland duct with secretion of sweat and sweat enriched inflammatory substances or specific IgE (atopics) in the surrounding dermis leading to severe itching. The image of the dyshidrotic vesicles is that of eczema with large spongiotic vesicles and discrete or severe dermal perivascular and periductal inflammatory infiltrate.

Course

The course depends on the cause. Idiopathic dyshidrosis is sometimes relapsing and seasonal (crisis of spring and autumn) and sometimes non-seasonal. **Idiopathic and atopic forms are often chronic and recurrent.**

Complications

When dyshidrosis becomes chronic, secondary infection may develop. It may lead to promotion of allergic contact dermatitis.

Diagnosis

The clinical features are typical and characteristic. To distinguish it from atopy-associated hand dermatitis one has to look for atopic stigmata. Patch testing is useful to exclude allergic contact dermatitis. A possible relationship between dyshidrotic eczema and a positive nickel test has to be ruled out. Dyshidrosis may be aggravated by oral nickel intake.

Clinical and mycological examination of the feet in the interdigital folds may be useful to determine an associated tinea pedis in cases of dyshidrotic eczema as an “id” reaction, i.e. eczematous vesicular eruptions secondary to distant bacterial or mycotic infections.

Differential Diagnosis

A variety of differential diagnoses include tinea pedis, early stages of palmoplantar pustulosis, pustular psoriasis, atopic dermatitis, allergic contact dermatitis and localized bullous pemphigoid. Hyperhidrosis associated to humidity and higher temperatures may produce hidrotic vesicles at the lateral finger sites.

Prevention & Therapy

Avoidance of working in humid areas and professions with constant washing of vegetables or glasses (kitchen, restaurant) and wearing of occlusive gloves. Avoid overwashing of hands because of barrier destruction and changes of microbiota.

Topical galenics: no ointment because of exaggerating occlusion, drying with solution or paste based galenics. **Wet dressings with antiseptic solutions** are essential. **Topical corticosteroids** in non-alcoholic galenic form (painful) such a milk/solution or paste are useful. **Topical calcineurin antagonists** in a lotion or cream may also be helpful. On occasions a **short course of systemic corticosteroids** can efficiently suppress the acute flare. Antihistamines are recommended in cases of intense pruritus.

First clinical trials with a biologic and YAK inhibitor with effects on the course and severity of disease with systemic dupilimumab or topical delgocitinib are promising.

References

- [Wollina U. Pompholyx: a review of clinical features, differential diagnosis, and management. Am J Clin Dermatol. 2010; 11:305-14.](#)
- [Veien NK. Acute and recurrent vesicular hand dermatitis. Dermatol Clin. 2009; 27:337-5.](#)
- [Nishizawa A. "Dyshidrotic eczema and its relationship to metal allergy." Curr Probl Dermatol. 2016;51:80-5.](#)
- [Waldman RA, DeWane ME, et al. "Dupilumab for the treatment of dyshidrotic eczema in 15 consecutive patients." J Am Acad Dermatol. 2020 May;82\(5\):1251-2](#)

1.1.3 Drug Related Dermatoses

1.1.3.1 Drug Reactions

Grading & Level of importance: A
RM. Pujol, Barcelona; F. Rongioletti, Milan



ICD-11

NE60

Synonyms

Drug rash, drug exanthem.

Definition

Undesirable (not pharmacological, not toxic) side effect of systemic medication affecting the skin.

Epidemiology

Cutaneous drug reactions are the most frequently occurring adverse reactions to drugs. Among hospitalized patients, their **incidence** ranges from 0.1 to 5%. **Predisposing factors** include advanced age, gender (more frequent in women), underlying diseases, viral infections, genetic factors and the use of multiple drugs.

Anti-infective, antipyretic/anti-inflammatory analgesics and anticonvulsant agents are among the drugs most commonly associated with muco-cutaneous adverse reactions.

Aetiology & Pathogenesis

Drug reactions may arise as a result of **immunological allergy** directed against the drug itself, or a reactive metabolite or by **non-immunological mechanisms** (pseudoallergic reactions) caused by non-immune-mediated degranulation of mast cells and basophils.

Immunologic mechanisms can involve type I (immunoglobulin E [IgE]-mediated), type II (cytotoxic), type III (immune complex), type IV (cell-mediated immunity), or a combination of multiple mechanisms.

Common causes:

- Antibiotics (sulphonamides, ampicillin, penicillins, cephalosporins).
- Anti-inflammatory drugs (NSAIDs).

- Anticonvulsant medications (phenytoin, barbiturates).
- Diuretics (thiazides).
- Allopurinol

Signs & Symptoms

An extensive number of clinicopathological presentations may develop secondary to drugs. Most (but not all) drug reactions appear 5–15 days after the drug administration. Several drugs may cause any particular reaction, although certain drugs are more likely than others to give a particular pattern.

The most common reactions produced by drugs are exanthematous/morbilliform rashes, followed by urticaria and angioedema.

Exanthematous drug reactions (80%):

Symmetrically distributed erythematous macules or papules appearing from 4 to 14 days after the onset of treatment. The lesions are often pruritic and appear first on the trunk and then spread to the extremities. The eruption usually lasts for 1-2 weeks and clears with cessation of the drug. Occasionally the exanthem may be urticarial or haemorrhagic.

Related drugs: Ampicillin and penicillin, Phenylbutazone (pyrazolones), barbiturates, sulphonamides, phenytoin, carbamazepine.

Urticarial eruptions, angioedema (5%): Rapid onset (first few hours after drug ingestion)

Evanescient, raised intensely itchy plaques (wheals). Generalized distribution. Angioedema is more persistent and may be observed as an isolated manifestation or in association with urticarial lesions.

Related drugs: Penicillins, sulphonamides, NSAIDs, aspirin, tartrazine, codeine, ACE inhibitors (angioedema).

Fixed drug eruption: Onset within 2 days of initiation of drug therapy. Limited number of lesions. Well-demarcated round or oval itchy/burning erythematous/edematous plaques becoming dusky violaceous or brown, and sometimes vesicular or bullous. Cutaneous and/or mucosal involvement. After re-exposure to the responsible drug the lesions recur at the same location, although new lesions in different areas may develop.

Related drugs: Antibiotics/antibacterials: Sulphonamides (co-trimoxazole), tetracyclines, penicillins, non-steroidal anti-inflammatory drugs (aspirin, oxyphenbutazone, phenazone/ antipyrine, metamizole), paracetamol, barbiturate derivatives, anticonvulsants.

Acute generalized exanthematous pustulosis (AGEP): Febrile drug reaction often seen within 1 - 2 days of starting offending drug. Multiple punctate non-follicular sterile pustules in a background of edematous erythema. Face or intertriginous areas and spread to trunk and upper extremities. Edema of

face and hands. Resolves within 1–2 weeks with desquamation.

Related drugs: Beta-lactam antibiotics, macrolides, calcium channel blockers, antimalarials, terbinafine, carbamazepine, paracetamol.

Other less common clinicopathological patterns: Purpura, photosensitivity eruptions, neutrophilic dermatoses, erythema nodosum, vasculitis, drug-induced pemphigus and pemphigoid, acneiform eruptions, lichenoid eruptions, sclerodermoid, pseudolymphomatous reactions, granulomatous eruptions, erythroderma, necrosis of the skin, hypertrichosis, alopecia, etc. Possible mucosal involvement.

The most severe drug reactions are Stevens-Johnson syndrome and toxic epidermal necrolysis (TEN), DRESS syndrome, exfoliative dermatitis and anaphylaxis (with or without angioedema). Severe cutaneous drug eruptions may be accompanied by fever, chills, lymphadenopathy, arthralgias and wheezing.

Stevens-Johnson syndrome and TEN: Life-threatening disorders. Fever and constitutional symptoms precede 1 to 3 days the onset of cutaneous lesions. Extensive symmetrical erythematous macular eruption upper trunk of the body and the face, that subsequently result in flaccid bullae or frank epidermal detachment due to necrosis of the epidermis, erythema with painful mucosal erosions/ulcerations, involving genital, buccal, and ocular mucosa. Stevens-Johnson syndrome affects less than 10% of the body while TEN causes large areas of peeling affecting over 30% of the body. Involvement of more than 10% to 30% is considered an overlap. (see chapter 1.1.3.4).

Related drugs: Anticonvulsants (carbamazepine, lamotrigine, phenytoin), penicillins, allopurinol, sulfonamides, antiretrovirals, barbiturates, NSAIDs.

Drug Rash with Eosinophilia and Systemic Symptoms (DRESS). “Hypersensitivity syndrome”; appearing 2 – 6 weeks after starting offending drug. Maculo-papular (morbilliform) generalized skin eruption. Edematous with occasional blisters and bullae. Upper trunk and extremities. Facial edema. Fever, lymph node enlargement. Eosinophilia, elevated liver enzymes, interstitial nephritis, etc.

Related drugs: Sulfonamides, phenobarbital, carbamazepine, phenytoin, lamotrigine, allopurinol, dapsone, abacavir.

Localisation

Varied. Depending on the clinicopathological picture.

Classification

A single drug may be associated with numerous forms of skin eruption. Drug eruptions may be classified in terms of both their clinical morphology and the presumed mechanism of action (Immediate-type and delayed-type Immune-mediated drug eruptions).

Common:

- Exanthematous maculopapular drug reaction.
- Urticarial drug reaction. Angioedema.
- Fixed drug reaction.

Less common:

- Vasculitis
- Erythema nodosum.
- Phototoxic/photoallergic dermatitis.
- Acute generalized exanthematous pustulosis
- Erythroderma
- DRESS
- Toxic epidermal necrolysis (TEN).
- Other types of lesions (acneiform, lichenoid, granulomatous).

Laboratory & other workups

Eosinophilia in a subset of patients. Hepatic and renal screening to exclude systemic involvement. After healing, try to identify causative agent with skin tests and in-vitro tests (only for selected medications with standardised tests, such as IgE-mediated penicillin allergy). (Rarely: Provocation test [but be careful: precipitation of severe skin reaction is possible with re-challenge]).

Dermatopathology

In general, the skin findings of one of the clinico-morphological patterns define the histological pattern.

Examples:

- Exanthematous drug reactions: Mild spongiosis, vacuolar changes involving the basal layer. Occasional apoptotic keratinocytes. Discrete perivascular lymphocytic infiltrate. Mild dermal edema. Some eosinophils

- Pustular drug reactions: epidermotropic non-follicular subcorneal neutrophilic and eosinophilic infiltration.
- Lichenoid drug eruptions: interface dermatitis with attack against basal cell layer of epidermis

Course

Eruption generally fades after drug discontinuation. Recurrences are common when the patient is re-challenged with the drug.

Complications

In severe muco-cutaneous drug reactions: Liver, renal and hematologic abnormalities may be present. Anaphylactic reaction.

Diagnosis

Careful history (time course fits with drug exposure), clinical features, associated symptoms, histology and laboratory studies, examples from drug bank literature. Cessation of the suspected drug (de-challenge).

If possible, identification of the responsible drug. Databases: Potential responsible drugs for particular clinicopathological patterns. No reliable specific confirmatory tests. In some drugs patch, or other skin, tests could be useful. Re-challenge (ethical considerations).

Differential Diagnosis

Depending on the observed clinical picture or clinicopathological pattern. In exanthematous drug reactions, other generalised exanthems, depending on lesion morphology, such as **viral exanthems, secondary syphilis and lupus erythematosus**. In pustular types subcorneal pustular dermatosis (Sneddon–Wilkinson disease), pustular vasculitis

Prevention & Therapy

Take care of multimедication and comorbidities promoting drug reactions.

Discontinue the suspected medication, antihistamines, topical and even systemic corticosteroids.

Antihistamines are sometimes helpful for pruritus.

References

- [Wilkerson RG. Drug Hypersensitivity Reactions. Emerg Med Clin North Am. 2022; 40:39-55. Nigen S, Knowles SR, Shear NH. Drug eruptions: approaching the diagnosis of drug-induced skin diseases. J Drugs Dermatol. 2003;2:278-99](#)
- [Mockenhaupt M. Severe drug-induced skin reactions: clinical pattern, diagnostics and therapy. J Dtsch Dermatol Ges. 2009; 7:142–162. .](#)

1.1.3.2 Erythema Multiforme

Grading & Level of importance: A

A. Gimenez-Arnau, Barcelona; RM. Pujol, Barcelona; F. Rongioletti, Milan



ICD-11

EB12

Synonyms

Erythema exsudativum multiforme.

Definition

It is an **acute, immune-mediated and self-limited disease** with typical skin lesions which show a target or iris-like form and is frequently associated with mucosal blisters and erosions.

Epidemiology

The exact annual incidence of EM is unknown. It occurs predominantly in young adults, is slightly more common in females, and the incidence is somewhere between 0.01% and 1% of the population.

Aetiology & Pathogenesis

Erythema multiforme mostly appears about 8 to 10 days after an infection or drug exposure. Many causes are to be considered. The most important are infections: mainly herpes simplex (HSV, but also Mycoplasma pneumoniae, streptococci and other viral or bacterial infections); less common are medications (antibiotics, anti-epileptics, protease inhibitors, pyrazolone, vaccination); physical stimuli (UV, irradiation). However, commonly (>50%) the cause is not found. A skin-directed **immune reaction inducing keratinocyte apoptosis** appears to play an important pathogenetic role.

Signs & Symptoms

EM most frequently occurs in **young adults between the ages of 20 and 40** and exhibits a slight female predominance. Children and older adults can also be affected. The eruption starts as an acral exanthem with formation of **typical non-evanescent target lesions with multiple concentric rings of varying color tones**. A central circular area with bulla and crust formation follows. Also, mucosal involvement (lips, mouth, genitalia) with erosions and crusts (lips) is common.

Localisation

Typically, it is **symmetrically distributed on the distal extremities**: backs of the hands and palms, fore arms as well as on knees, elbows, nape; on the mucosae, one can see vesiculo-bullous lesions that rapidly evolve to erosions involving the lips, mouth, eyes, nose, trachea and genitalia.

Classification

It is divided into a **minor (80%) and major type** (absence or presence of mucosal involvement and systemic symptoms). Actually, erythema multiforme is distinct from Stevens-Johnson syndrome and toxic epidermal necrolysis.

Laboratory & other workups

No specific laboratory tests are indicated. Case history may give rise for specific infectious agents to test (HSV or coxsackie virus).

Dermatopathology

Vacuolar alteration of the basal layer, apoptosis of individual keratinocytes. Edema of papillary dermis sometimes with blistering. Prominent superficial polymorphous inflammatory infiltrate with mononuclear cells and neutrophils, erythrocyte extravasation.

Course

There is an **abrupt onset (24-72 hours)** of clinical lesions after the triggering event. Resolution follows within 2-3 weeks. Frequent recurrences in cases associated with HSV infection can be seen.

Complications

No sequelae, except in cases with ocular involvement.

Diagnosis

Clinical features are characteristic. In clinically atypical lesions, histopathological examination may be useful.

No specific work-up is indicated. Only in cases with associated extracutaneous symptoms. Chest radiography may be useful in cases with respiratory symptoms.

Differential Diagnosis

Despite the fact that typical target lesions are diagnostic, different disorders that may show target-like lesions have to be considered. These include

- acute urticaria,
- fixed drug eruptions,
- subacute cutaneous lupus erythematosus,
- urticarial vasculitis, bullous diseases and
- erythema annulare centrifugum.
- The differential diagnostic possibilities for the mucosal lesions include Stevens-Johnson syndrome, lichen planus, autoimmune bullous diseases, lupus erythematosus, and viral diseases (especially herpes simplex).

Prevention & Therapy

Prevention: in cases with HSV-association with frequent recurrences, prophylactic oral antiviral treatment should be prescribed.

Treatment or elimination of underlying causes is essential. Corticosteroids topically and in severe cases systemically are indicated. In cases with mucosal disease, topical corticosteroids in an appropriate vehicle along with antimicrobial solutions to prevent superinfection. If an eye involvement is marked, one has to urgently to obtain an ophthalmologic consultation because of risk of permanent scarring and visual impairment.

References

- [Sokumbi O.&Wetter D.A. Clinical Features, Diagnosis, and Treatment of Erythema Multiforme: A Review for the Practicing Dermatologist. Int J Dermatol. 2012; 51:889–902.](#)
- [de Risi-Pugliese T et al. Interventions for erythema multiforme: a systematic review. J Eur Acad Dermatol Venereol 2019; 33:842-849.](#)

1.1.3.3 Drug related rash with eosinophilia and systemic symptoms (DRESS)

Grading & Level of importance: B
E. Gaffal, Magdeburg; F. Rongioletti, Milan



ICD-11

EH65

Synonyms

DRESS syndrome; drug-induced hypersensitivity syndrome; Drug induced delayed multiorgan hypersensitivity syndrome.

Definition

DRESS is defined as a drug induced rash with blood eosinophilia and involvement of internal organs. It is a T-cell mediated delayed-type hypersensitivity reaction like Stevens-Johnsons syndrome (SJS) or Toxic Epidermal Necrolysis (TEN).

Epidemiology

DRESS is a rare disease with an incidence of ten cases per million in one year. Due to the wide diversity of individual symptoms, many cases are not diagnosed correctly. The real incidence therefore might be higher. There has been reported a slight female prevalence (male/female ratio 0.8), the median age at diagnosis is 53 years.

Aetiology and Pathogenesis

Drugs frequently inducing DRESS are (selection)

Antiarrhythmic	Mexiletin
Anticonvulsants	Carbamazepine, Phenytoin, Lamotrigine, Pheno-barbital, Zonisamid
Anti-retroviral	Abacavir, Nevirapine
Antibacterial	Amoxicillin, Levofloxacin, Minocycline
Other	Dapsone, Sulfonamide, Allopurinol, Vemurafenib, Cobimetinib

Drugs with the highest risk of inducing DRESS are anticonvulsants and allopurinol.

DRESS is associated with the infection or reactivation of human herpesvirus 6/7, Epstein-Barr virus and cytomegalovirus. Viral replication has been detected during all phases of the drug hypersensitivity reaction. Viral replication and T-cell mediated responses against viruses are thought to contribute to the clinical symptoms and may even worsen the disease.

Risk genes from alleles of human leukocyte antigen (HLA) class I and II have been shown to be associated with a higher risk to develop DRESS.

Clinical presentation**An acute onset of symptoms for up to six weeks after taking the drug is characteristic for DRESS.**

Cutaneous lesions start as disseminated, symmetrical reddish macules on the trunk, arms and legs. Patients often show facial edema. Later a generalized maculopapular rash develops and in the course of disease, an exfoliative dermatitis or erythroderma may develop.

Mucosal involvement is very rare. In general, patients present feeling unwell with fever and lymphadenopathy. There is involvement of at least one internal organ (liver > kidney > lung, heart, pancreas).

To enable a quick diagnosis the following scoring system is proposed by the RegiSCAR group:

1. Acute rash
2. Reaction suspected drug-related
3. Hospitalization
4. Fever (>38°C)
5. Laboratory abnormalities (at least 1 present) <ul style="list-style-type: none"> a. Lymphocytes above or below normal b. Low platelets c. Eosinophilia
6. Involvement of >1 internal organ
7. Enlarged lymph nodes >2 sites

DRESS is diagnosed if 1-3 and three out of 4-7 apply.

After the culprit drug is withdrawn, symptoms may worsen after three or four days. If there are no sure signs for an infection, physicians should not treat the patient empirically with antibiotics to avoid cross-reactivity.

Laboratory & other workups

A transient blood eosinophilia ($>1500/\mu\text{l}$) and leukocytosis ($>11 \times 10^9/\text{L}$) with atypical lymphocytes appears in the early course of disease. Liver involvement is reported in about 70% of patients with a massive increase of liver enzymes. Signs of an acute hepatitis with jaundice may develop. Depending on the involvement of other organs, there is an increase of creatinine kinase, creatinine, amylase and lipase.

Dermatopathology

Histopathology reveals various patterns often coexisting in the same biopsy, including spongiosis, vacuolar interface dermatitis, apoptotic keratinocytes, a superficial perivascular lymphocytic infiltrate and few dermal eosinophils.

Complications

Permanent damage of involved organs. **Mortality up to 10%.**

Diagnosis

Clinical picture, blood tests, histology.

Differential Diagnosis

- Stevens-Johnson syndrome/toxic epidermal necrolysis (SJS/TEN)
- Acute generalized exanthematous pustulosis (AGEP)
- Hypereosinophilic syndromes
- Angioimmunoblastic T-cell lymphoma
- Acute cutaneous lupus erythematosus

Prevention & Therapy

The suspected drug has to be withdrawn immediately. Patients must be treated with systemic glucocorticoids 40-50 mg/d. Slowly reduce steroids over up to eight weeks to avoid relapse.

References

- [Abhishek De et al. Drug Reaction with Eosinophilia and Systemic Symptoms: An Update and Review of Recent Literature. Indian J Dermatol. 2018 Jan-Feb; 63\(1\): 30–40](#)

- [Sharma A N et al. Characterizing DRESS syndrome recurrence: a systematic review. Arch Dermatol Res. 2021 Sep 10. doi: 10.1007/s00403-021-02274-3.](#)
- [Schroeder JW et al. Unraveling the complexities of drug reaction with eosinophilia and systemic symptoms \(DRESS\): Insights into clinical, laboratory and histopathologic features of a case series from an Italian tertiary center. Clin Dermatol 2023;41\(6\):72](#)

1.1.3.4 Stevens-Johnson Syndrome

Grading & Level of importance: C
H. Gollnick, Magdeburg; F. Rongioletti, Milan



ICD-11

EB13

Synonyms

SJS

Definition

Stevens-Johnson syndrome, which is part of a spectrum of severe drug eruptions, affects **skin and the oro-genital mucous membranes and conjunctivae**. The body surface (BS) involvement ranges in SJS where <10% of BS is affected to toxic epidermal necrolysis (TEN) in which 30% of the BS shows loss of the epidermis. Involvement of 10 to 30% of the BS is referred to as SJS-TEN-overlap syndrome.

Epidemiology

Stevens-Johnson syndrome is a rare disease affecting around 1-2 persons per 1 million. There is a higher risk of development of this serious disease in HIV/AIDS patients and in elderly patients receiving multiple medications. 7–10% of cases in all groups have at least one autoimmune disease. There are new data showing that infections is highest among SJS cases (21.8 %) compared to TEN (17.1 %) and SJS_TEN overlap (11.8%).

Aetiology & Pathogenesis

Many causes may be implicated. Whereas in erythema exsudativum multiforme (minor and major type) infections such as viruses e.g., the herpes virus and mycoplasma play the important role, much more

often in **Stevens-Johnson syndrome and toxic epidermal necrolysis, drugs are the inducing agents.** Immunologically-induced apoptosis of keratinocytes cascading unchecked into massive epidermal destruction may be the pathogenic mechanism. Besides multidrug exposure in particular in the elderly population, hereditary disposition to severe cutaneous drug reactions is an additional risk. In Chinese and Thai patients, SJS induced by **carbamazepine** shows a high correlation to HLA-B*1502. This correlation is not found in the European population, but rather an association with HLA class I-allele HLA-A*3101. In all population, SJS is often induced by the very common drug **allopurinol**. An association with HLA-B*5801 can often be detected in that case. Necrolysis of keratinocytes by TNF alpha and gamma IFN are important mediators of the cell changes. Annexin A 1 promotes via the formyl-peptid-receptor apoptosis of keratinocytes and increased levels of miR-18 a-5p in the skin can be measured, which blocks anti-apoptotic action and therefore promotes cell death.

Drugs with high risk:

- allopurinol,
- carbamazepine,
- lamotrigine, phenytoin, sertraline, nevirapine,
- phenobarbital,
- piroxicam,
- sulfamethoxazole, sulfasalazine and other anti-bacterial sulfonamides.

Drugs with moderate risk: cephalosporins, quinolones, macrolides, NSAIDs (e.g.diclofenac) and tetracyclines.

Signs & Symptoms

SJS initially shows a macular exanthem, usually on the trunk. In contrast to erythema exudativum multiforme, the typical target lesions of cockades are not seen. Fever, conjunctivitis, sensitivity to daylight and artificial light and throat pain often precede the skin symptoms.

After skin symptoms have started on the trunk, the face, hands and feet follow. Lesions often become confluent, with formation of atypical target lesions, **without the classical erythema multiforme-like characteristics**. Erosions and even ulcerations may appear. Up to 10 % of body surface is involved. Generally, erosions are present around more than one mucosal orifice. Later, balanitis may develop and the upper respiratory and the gastrointestinal tract may become affected. Nikolsky I skin sign is positive.

Localisation

The **skin and mucosa** of mouth and genitalia are always involved.

Classification

SJS is part of the Erythema multiforme – SJS -TEN complex which can be seen as a clinical cascade, however, the course of erythema multiforme in general is milder

A prognostic scoring system should always be used. Every parameter positively answered is ranked with one scoring point:

Age > 40 years / malignant tumor(s) /skin ablation > 10% BSF / heart frequency > 120 pro min / bicarbonate < 20mmol per litre / urea > 10mmol per litre / hyperglycemia > 252 mg/dl.

Laboratory & other workups

Frequent monitoring of electrolytes, kidney and liver parameters, cardiac function is essential.

Dermatopathology

Cytotoxic T-lymphocytes attack the epidermal keratinocytes, but also mucous epithelia are involved. **Apoptosis and necrosis of keratinocytes** is the key feature. Disruption of the epidermal / dermal connection leads to formation of bullae. Capillaries in the upper dermal vessel complex are widened and a heavy lympho-mononuclear cell infiltrate is assembled in and around the interstitium.

Course

The course of disease depends on age, comorbidity, body function and body surface involvement, body functional status, earliest time of intervention. Intravenous electrolytes and bicarbonate need to be balanced and the patients should be monitored like burns patients of degree IIa and III.

Complications

The mortality of 1 – 5 % is quite high. Long-term sequelae such as scarring of the blepharon, development of an ectropion, phimosis and vaginal synechia are often seen. Superinfection with staphylococci, streptococci and other microbes should be avoided.

Diagnosis

Typical clinical features and histology. Scoring is recommended similar as in TEN, however, the SCORTEN is only a rough guide.

Differential Diagnosis

Disseminated herpes simplex (primary infection), drug reaction, pemphigus vulgaris, DRESS are the most important ones.

Prevention & Therapy

All suspicious drugs have to be excluded and discontinued. Drug half-life should be known because it will influence the response rate and time of treatment length to avoid immediate relapse. The systemic use of ciclosporin (3 mg/kg/day) is currently favored. Corticosteroids, intravenous immunoglobulins and TNF alpha blockers are alternative interventions. Symptomatic topical measures are essential to avoid superinfection and scarring, similar to burn patients. Skin-directed treatment is analogous to those in TEN, however, admission to an intensive care unit may not be necessary if less than 10% of BSA is involved.

Special

Any involvement of the eyes needs immediate consultation with an ophthalmologist.

References

- [Lerch M, Mainetti C, Terziroli Beretta-Piccoli B, Harr T. Current Perspectives on Stevens-Johnson Syndrome and Toxic Epidermal Necrolysis. Clin Rev Allergy Immunol. 2018 Feb;54\(1\):147-176.](#)
- [Frey N, Bodmer M, Bircher A, Jick SS, Meier CR, Spoenlin J. Stevens-Johnson Syndrome and Toxic Epidermal Necrolysis in Association with Commonly Prescribed Drugs in Outpatient Care Other than Anti-Epileptic Drugs and Antibiotics: A Population-Based Case-Control Study. Drug Saf. 2019 Jan;42\(1\):55-66.](#)
- [Wang L, Varghese Sh, Bassir F, Lo Y-Ch, Ortega CA, Shah S, Blumenthal KG, Phillips EJ & Zhou L \(2022\) Stevens-Johnson syndrome and toxic epidermal necrolysis: A systematic review of PubMed/MEDLINE case reports from 1980 to 2020. Frontiers in Medicine Volu](#)

1.1.3.5 Toxic Epidermal Necrolysis

Grading & Level of importance: C
H. Gollnick, Magdeburg; F. Rongioletti, Milan



ICD-11

EB13

Synonyms

Lyell syndrome

Definition

Toxic epidermal necrolysis (TEN) is a **severe drug-induced skin reaction** characterised by death of the epidermis (keratinocyte necrosis) and marked mucosal erosions. It is part of a spectrum of severe drug eruptions, affecting skin and the oro-genital mucous membranes and conjunctivae. The body surface (BS) involvement differs from SJS, where <10% of BS is affected to **toxic epidermal necrolysis (TEN) in which 30% of the BS shows loss of the epidermis**. Involvement of 10 to 30% of the BS is referred to as SJS-TEN-overlap syndrome.

Epidemiology

Toxic epidermal necrolysis (TEN) is a rare disease affecting around **1-2 persons per 1 million**. There is a higher risk of developing this serious disease in HIV/AIDS patients and in elderly patients receiving multiple medications. 7–10% of cases in all groups have at least one autoimmune disease. There are new data showing that infections is highest among SJS cases (21.8 %) compared to TEN (17.1 %) and SJS_TEN overlap (11.8%).

Aetiology & Pathogenesis

There are many causes of TEN. Whereas in Erythema exsudativum multiforme (minor and major type) infections such as viruses e.g. the herpes virus and mycoplasma are important aetiological factors, much more often **in Stevens-Johnson syndrome and in toxic epidermal necrolysis, drugs are the inducing agents**. Immunologically-induced apoptosis of keratinocytes cascading unchecked into massive epidermal destruction may be the pathogenic mechanism. Beside multi-drug exposure in particular in the elderly population, hereditary disposition to severe cutaneous drug reactions is an additional risk. In Chinese and Thai patients SJS/TEN induced by carbamazepine shows a high correlation with HLA-B*1502. This correlation is not found in the European population, but rather an association with HLA class I-allele HLA-A*3101. In all populations, TEN is often induced by the very common drug allopurinol (minimal daily dose 200 mg). An association with HLA-B*5801 can be detected in that case. Necrolysis by TNF alpha and gamma IFN are important mediators of the cell changes. Annexin A 1 promotes via the formyl-peptid- receptor apoptosis of keratinocytes and an increased level of miR-18 a-5p in the skin can be measured, which blocks antiapoptotic action and therefore promotes cell death. Current theories involve apoptosis due to FAS-mediated mechanisms, granulysin and reactive oxygen species.

Drugs with high risk:

- allopurinol,
- carbamazepine, lamotrigine, sertraline, phenytoin, nevirapine, phenobarbital,
- piroxicam,
- sulfamethoxazol, sulfasalazine and other anti-bacterial sulfonamides.

Drugs with moderate risk: cephalosporines, quinolones, macrolides, NSAIDs e.g. diclofenac and tetracyclines

> for further details see tables

Allergen ^a	Total (n = 1,059)	SJS (n = 381)	SJS-TEN Overlap (n = 76)	TEN (n = 602)	P-value ^b
Drug Allergen					
<i>Antibiotics</i>	285 (26.9)	84 (22.1)	20 (26.3)	181 (30.1)	0.022
Sulfonamides	108 (10.2)	26 (6.8)	5 (6.6)	77 (12.8)	–
Penicillins	60 (5.7)	21 (5.5)	6 (7.9)	33 (5.5)	–
Quinolones	35 (3.3)	6 (1.6)	4 (5.2)	25 (4.2)	–
Macrolides	25 (2.4)	12 (3.2)	1 (1.3)	12 (2.0)	–
Vancomycin	21 (2.0)	2 (0.5)	2 (2.6)	17 (2.8)	–
Tetracycline	11 (1.0)	4 (1.1)	1 (1.3)	6 (1.0)	–
Other antibiotics ^a	72 (6.8)	19 (5.0)	5 (6.6)	48 (8.0)	–
<i>Anticonvulsants</i>	196 (18.5)	60 (15.7)	19 (25.0)	117 (19.4)	0.111
Phenytoin	62 (5.7)	16 (4.2)	3 (3.9)	43 (7.1)	–
Carbamazepine	54 (5.1)	15 (3.9)	8 (10.5)	31 (5.1)	–
Lamotrigine	49 (4.6)	20 (5.2)	2 (2.6)	27 (4.5)	–
Valproate	16 (1.5)	8 (2.1)	2 (2.6)	6 (1.0)	–
Other anticonvulsants	32 (3.0)	10 (2.6)	5 (6.6)	17 (2.8)	–
<i>Analgesics/anesthetics</i>	126 (11.9)	34 (8.9)	14 (18.4)	78 (13.0)	0.031
NSAIDs	93 (8.8)	24 (6.3)	9 (11.8)	60 (10.0)	–
Ibuprofen	23 (2.2)	6 (1.6)	5 (6.6)	12 (2.0)	–
Acetaminophen	24 (2.3)	5 (1.3)	3 (3.9)	16 (2.7)	–
Analgesic/antipyretics, non-salicylate	37 (3.5)	10 (2.6)	6 (7.9)	21 (3.5)	–
Other	5 (0.3)	1 (0.3)	1 (1.3)	3 (0.5)	–
<i>Antineoplastics</i>	119 (11.2)	42 (11.0)	10 (13.2)	67 (11.1)	0.858
Systemic enzyme inhibitors (e.g., imatinib)	24 (2.3)	16 (4.2)	1 (1.3)	7 (1.2)	–
Antimetabolites (e.g., methotrexate)	19 (1.8)	3 (0.8)	3 (3.9)	13 (2.2)	–
Alkylating agents (e.g., cyclophosphamide)	15 (1.4)	3 (0.8)	1 (1.3)	11 (1.8)	–
Immunotherapy checkpoint inhibitor combination (nivolumab)	12 (1.1)	4 (1.0)	0 (0)	8 (1.3)	–
Immunomodulator agents (e.g., lenalidomide)	11 (1.0)	6 (1.6)	1 (1.3)	4 (0.7)	–
Other antineoplastics	50 (4.7)	12 (3.1)	4 (5.3)	34 (5.6)	–
<i>Antiarthritics</i>	48 (4.5)	14 (3.7)	6 (7.9)	28 (4.7)	0.265
Xanthine oxidase inhibitors (allopurinol)	45 (4.2)	14 (3.7)	6 (7.9)	25 (4.2)	–
<i>Antivirals</i>	34 (3.2)	14 (3.7)	3 (3.9)	17 (2.8)	0.71
HIV-specific antivirals (e.g., nevirapine)	25 (2.4)	12 (3.1)	0 (0)	13 (2.2)	–
<i>Gastrointestinal drugs (e.g., sulfasalazine)</i>	34 (3.2)	8 (2.1)	2 (2.6)	24 (4.0)	0.251
<i>Psychotherapeutic drugs</i>	25 (2.4)	12 (3.1)	1 (1.3)	12 (2.0)	0.419
Antidepressant	11 (1.0)	6 (1.6)	0 (0)	5 (0.8)	–
<i>Anti-Infectives</i>	24 (2.3)	12 (3.1)	0 (0)	12 (2.0)	0.191
Antimalarial drugs	20 (1.9)	11 (2.9)	0 (0)	9 (1.5)	–
<i>Antifungals</i>	20 (1.9)	7 (1.8)	0 (0)	13 (2.2)	0.426
<i>Cardiovascular drugs</i>	27 (2.5)	8 (2.1)	0 (0)	19 (3.2)	0.203
Diuretics	17 (1.6)	7 (1.8)	1 (1.3)	9 (1.5)	0.897
Vitamin/herb	15 (1.4)	8 (2.1)	0 (0)	7 (1.2)	0.267
<i>Hormones</i>	14 (1.3)	5 (1.3)	0 (0)	9 (1.5)	0.561
Glucocorticoids	11 (1.0)	3 (0.8)	0 (0)	8 (1.3)	–
<i>Biologicals/vaccine</i>	10 (0.9)	6 (1.6)	1 (1.3)	3 (0.5)	0.222
<i>Diagnostic (contrast medium)</i>	10 (0.9)	3 (0.8)	2 (2.6)	5 (0.8)	0.287
<i>Chemotherapy rescue/antidote agents</i>	8 (0.8)	3 (0.8)	0 (0)	5 (0.8)	0.73
<i>Antithrombotic agents</i>	8 (0.8)	2 (0.5)	0 (0)	6 (1.0)	0.518
<i>Cough/cold preparations</i>	6 (0.6)	2 (0.5)	0 (0)	4 (0.7)	0.761
<i>Immunosuppressants</i>	6 (0.6)	5 (1.3)	0 (0)	1 (0.2)	0.052
Non-drug Allergen					
Infection	68 (6.4)	51 (13.4)	2 (2.6)	15 (2.5)	<0.001
Mycoplasma pneumonia infection	44 (4.2)	38 (10.0)	2 (2.6)	4 (0.7)	–
Radiotherapy	27 (2.5)	11 (2.9)	2 (2.6)	14 (2.3)	0.861
Chemical substance	9 (0.8)	5 (1.3)	1 (1.3)	3 (0.5)	0.36
Others	25 (2.4)	4 (2.6)	1 (1.3)	20 (3.3)	–

NSAIDs, non-steroidal anti-inflammatory drugs; HIV, human immunodeficiency virus.

The number (percentage) in bold indicates a significant adjusted residual for that cell (meaning that there were significantly more or fewer cases than what would be expected by chance).

^aThe detailed allergen included in each category could be found in the Tables 5, 6.

^bP-values were provided based on Chi-square test for categorical variables.

From Wang et al (2022) FrontMedicine <https://doi.org/10.3389>

Non-Drug Allergen Category	Allergen Type	Specific Allergen (Number of SJS/TEN Cases) ^a
Infection	Mycoplasma pneumonia infection Other infection	<i>M. pneumoniae</i> (2), mycoplasma pneumonia infection (40), pneumonia infection (3), upper respiratory infection (2) Brucella melitensis (1), cytomegalovirus infection (1), dengue virus (1), enterovirus (1), Epstein-Barr virus infection (1), herpes simplex virus (4), influenza B infection (2), mucor infection (1), parvovirus infection (1), pneumonia infection (2), psittacosis (1), respiratory infection (2), staphylococcus septicemia (1), upper respiratory infection (1), varicella-zoster virus (1), varicella infection (1), viral hepatitis type a (1), viral illness (2), yersinia enterocolitica infection (1)
Radiotherapy		Brain radiotherapy (13), cranial radiotherapy (2), radiotherapy (14)
Chemical substance	Chemical compound	Gangliosides (1), s,s-dimethyl cyanocarbonimidodithioate (1), trichloroethylene (1), arsenic (2), Iodine (1), mercury (1), carbamate insecticide (2), organophosphate insecticide (1)
Others	Disease Others	HIV (1), Hodgkin's disease (cancer) (1), lupus (1), non-Hodgkin lymphoma (1) Acrylonitrile-butadiene-styrene (1), alpha-PVP (1), anhydrous caffeine (1), black widow spider bite (1), burn (1), caffeine (1), cellulose acetate (1), cologne (1), cosmetic cream (1), interleukin-2 (1), oil lamp (1), phototoxic allergy (1), polyvinyl chloride (1), printing inks (1), spirulina (1), sun exposure (1), tanning salon (1), UV-cured inks (1), pregnancy (2), pregnancy (2), bone marrow transplantation (2), stem cell transplantation (2)

SJS/TEN, Stevens-Johnson syndrome and/or toxic epidermal necrolysis; HIV, human immunodeficiency virus.

^aThe case count is reflecting the number of unique cases while some of the cases could have more than one allergen annotations.

From Wang et al (2022) FrontMedicine <https://doi.org/10.3389>

Signs & Symptoms

As in SJS, **initially a macular exanthem develops**, usually on the trunk. In contrast to erythema exudativum multiforme, the typical target lesions of cockades are not seen. Fever, conjunctivitis, sensitivity to daylight and artificial light and throat pain often precede the skin symptoms.

After skin symptoms have started on the trunk, the face and hands and feet follow, often becoming confluent, with formation of **atypical target lesions without the classical E.e.m.-like characteristics**. Erosions and even ulcerations may appear. **More than 30% of body surface is involved**. Erosions generally present around more than one mucosal orifice. Later balanitis may be seen and the upper respiratory and gastrointestinal tract are involved. The Nikolsky I skin sign is positive.

Localisation

Skin and mucosa including esophagus are both affected.

Classification

Toxic epidermal necrolysis is the worst part of the spectrum of the Erythema exudativum multiforme – SJS -TEN complex which can be seen as a clinical cascade, however, the course of Eem min general is

milder.

A prognostic scoring system (SCORETEN) should always be used. Every parameter which is positively answered is ranked with one scoring point:

Age > 40 years / malignant tumor(s) / skin ablation > 10% BSF / heart frequency > 120 pro min / bicarbonate < 20mmol per liter / urea > 10mmol per liter / hyperglycemia > 252 mg/dl.

More than 50% of TEN patients suffer from long-term sequelae.

Laboratory & other workups

Regular monitoring of electrolytes, kidney and liver parameters and cardiac function is essential.

Dermatopathology

Cytotoxic T-lymphocytes attack the epidermal keratinocytes, but also mucous epithelia are involved. Apoptosis and necrosis of keratinocytes is the key feature. Disruption of the epidermal/dermal connection leads to formation of large bullae. Capillaries in the upper dermal vessel complex are widened and a heavy lympho-mononuclear cell infiltrate is assembled.

Course

The course of disease depends on age, comorbidity, body function surface involvement, body functional status and how early treatment is commenced. Intravenous electrolytes and bicarbonate should be balanced and the patients should be monitored analogously to burn patients with a degree IIa and III.

The 30% mortality rate and > 40% complication rate is very high. Typically, sequelae may leave scarring areas of skin and mucosa.

Complications

Long-term sequelae such as scarring of the blepharon, development of an ectropion, phimosis and vaginal synechia are often seen. Scarring in esophagus and mouth mucosa are common. During the acute phase of the disease, electrolyte and fluid disturbances are very common.

Diagnosis

The clinical features and the histology show necrolysis throughout all epidermal layers, which confirms the diagnosis. Usually, inflammatory infiltrate in the dermis is mild.

Differential Diagnosis

- Staphylococcal scalded skin syndrome,
- generalized subcorneal pustulosis at the early stage,
- burns,
- disseminated erythema multiforme major type, disseminated fixed drug eruption, DRESS,
- pemphigus and pemphigoid variants and linear IgA disease.

Prevention & Therapy

All suspicious drugs have to be discontinued. Drug half-life should be known because it will influence the response rate and time of treatment length to avoid immediate relapse. The systemic use of **ciclosporin** (3 mg/kg/day) is currently favoured. Alternatively, **corticosteroids** in a pulse with 0.5 to 1.1 g/d, **TNF alpha blockers or intravenous immunoglobulins** in high dosages appear helpful if the disease continues to progress even after the triggering medication has been stopped. Although there is some debate in the literature, intravenous immunoglobulin has been shown to be effective when given early in the course of TEN. Symptomatic topical measures are essential to avoid superinfection and scarring similar to burn patients.

Early and aggressive interventions like those used for burns patients (fluid and electrolyte management, appropriate antibiotic coverage, warming measures) are standard. Special technical support (e.g., special bed, metalline bandages) are recommended. Patients are ideally treated on an intensive care unit. Regular ophthalmologic monitoring may help to avoid blepharon development.

Special

Genetic testing for susceptibility and entry on the European Register is recommended.

Demographics and clinical characteristics of Stevens-Johnson syndrome (SJS) and toxic epidermal necrolysis (TEN) cases from PubMed/MEDLINE.

Characteristics	Total (n = 1,059)	SJS (n = 381)	SJS-TEN Overlap (n = 76)	TEN (n = 602)	P-value ^a
Age of onset ^b (y), median (IQR)	38 (19.75–59)	32 (15–54)	39 (23–58)	41 (23–60.75)	<0.001
Gender, female ^b	557 (52.6)	176 (46.3)	43 (56.6)	338 (56.1)	0.007
Race ^b					0.832
White	105 (9.9)	34 (8.9)	8 (10.5)	63 (10.5)	
Asian	87 (8.2)	28 (7.3)	8 (10.5)	51 (8.5)	
Black	54 (5.1)	22 (5.8)	4 (5.3)	28 (4.7)	
Hispanic	11 (1.0)	5 (1.3)	2 (2.6)	4 (0.7)	
Others ^c	7 (0.7)	3 (0.8)	0 (0.0)	4 (0.7)	
Immunocompromised status					
Cancer	194 (18.3)	61 (16.0)	11 (14.5)	122 (20.3)	0.163
Cancer immunomodulatory therapy (PD-1, PD-L1, CTLA-4 inhibitor)	35 (3.3)	16 (4.2)	2 (2.6)	17 (2.8)	0.473
Autoimmune disease	97 (9.2)	28 (7.3)	8 (10.5)	61 (10.1)	0.31
HIV/AIDS	52 (4.9)	22 (5.8)	1 (1.3)	29 (4.8)	0.256
Pre-conditions					
Infections	201 (19.0)	83 (21.8)	9 (11.8)	103 (17.1)	0.056
Respiratory tract infections	102 (9.6)	48 (12.6)	4 (5.3)	50 (8.3)	0.034
Mycoplasma pneumoniae infections	23 (2.2)	20 (5.2)	1 (1.3)	2 (0.3)	<0.001
Epilepsy/seizure disorders	102 (9.6)	37 (9.7)	10 (13.2)	55 (9.1)	0.533
Hypertension	92 (8.7)	29 (7.6)	6 (7.9)	57 (9.5)	0.636
Cardiovascular/vascular conditions	54 (5.1)	15 (3.9)	7 (9.2)	32 (5.3)	0.149
Diabetes	54 (5.1)	17 (4.4)	4 (5.3)	33 (5.5)	0.814
Musculoskeletal conditions	52 (4.9)	18 (4.7)	2 (2.6)	32 (5.3)	0.693
Endocrine/hormonal conditions	50 (4.7)	20 (5.2)	3 (3.9)	27 (4.5)	0.849
Psychological conditions	38 (3.6)	13 (3.4)	4 (5.3)	21 (3.5)	0.656
Renal conditions	34 (3.2)	12 (3.1)	1 (1.3)	21 (3.5)	0.73
Substance use	28 (2.6)	9 (2.4)	2 (2.6)	17 (2.8)	0.954
Gastrointestinal conditions	22 (2.1)	3 (0.8)	1 (1.3)	18 (3.0)	0.053
Respiratory conditions (e.g., chronic obstructive pulmonary disease)	20 (1.9)	10 (2.6)	1 (1.3)	9 (1.5)	0.388
Other ^d	27 (2.5)	8 (2.1)	2 (2.6)	17 (2.8)	–
Clinical characteristics during the acute phase					
Involvement of mucous membrane	842 (79.5)	333 (87.4)	70 (92.1)	439 (72.9)	<0.001
Involvement of visceral organs	210 (19.8)	56 (14.7)	18 (23.7)	136 (22.6)	0.007
Mortality	187 (17.6)	24 (6.3)	16 (21.1)	147 (24.4)	<0.001
Medications listed as causative agents, No. (%)	956 (90.3)	319 (83.7)	74 (97.4)	563 (93.5)	<0.001
1 ^e	781 (73.7)	266 (69.8)	63 (82.9)	451 (74.9)	0.36
2	111 (10.5)	38 (10.0)	9 (11.8)	64 (10.6)	
3	39 (3.7)	9 (2.6)	1 (1.3)	29 (4.8)	
4	16 (1.5)	5 (1.3)	1 (1.3)	10 (1.7)	
5 or more	10 (0.9)	1 (0.3)	0 (0)	9 (1.5)	
Non-drug listed as causative agents, No. (%)	127 (12.0)	71 (18.6)	6 (7.9)	50 (8.3)	<0.001
Non-drug causative agents only	81 (7.6)	52 (13.6)	2 (2.6)	27 (4.5)	–
1	73 (6.9)	48 (12.6)	2 (2.6)	23 (3.8)	
2 or more	8 (0.8)	4 (1.0)	0 (0)	4 (0.7)	
Combined with drug causative agents	46 (4.3)	19 (5.0)	4 (5.3)	23 (3.8)	

IQR, interquartile range; HIV, human immunodeficiency virus; AIDS, acquired immunodeficiency syndrome.

For continuous variables, the number (percentage) in bold indicates a significant difference between the cells detected by Dunn's *post hoc* test. For categorical variables, the number (percentage) in bold indicates a significant adjusted residual for that cell (meaning that there were significantly more or fewer cases than what would be expected by chance).

^aP-values were provided based on Kruskal-Wallis test for the continuous variable (age of onset) and Chi-square test for categorical variables.

^bThe number of missing cases (age of onset = 7; gender = 3; race = 795).

^cIncludes native American, Pacific Islander, mixed race.

^dIncludes skin/cutaneous (n = 9), hereditary (n = 8), and neurological conditions (n = 10).

^eThe numbers were calculated based on the annotated medications. Due to the variation of medications, this numbers can be under-counted.

From Wang et al (2022) FrontMedicine doi.org/10.3389/fmed.2022.949520-citation

References

- [Lerch M, Mainetti C, Terziroli Beretta-Piccoli B, Harr T. \(2018\). Current Perspectives on Stevens-Johnson Syndrome and Toxic Epidermal Necrolysis. Clin Rev Allergy Immunol. Feb;54\(1\):147-176.](#)

- [Frey N, Bodmer M, Bircher A, Jick SS, Meier CR, Spoenlin J. \(2019\). Epidermal Necrolysis in Association with Commonly Prescribed Drugs in Outpatient Care Other than Anti-Epileptic Drugs and Antibiotics: A Population-Based Case-Control Study. Drug Saf. Jan;42\(1\):55-66.](#)
- [Wang L, Varghese Sh, Bassir F, Lo Y-Ch, Ortega CA, Shah S, Blumenthal KG, Phillips EJ & Zhou L \(2022\). Stevens-Johnson syndrome and toxic epidermal necrolysis: A systematic review of PubMed/MEDLINE case reports from 1980 to 2020 . Frontiers in Medicine Vol](#)
- [Schroeder JW et al. \(2023\). Stevens-Johnson syndrome and toxic epidermal necrolysis: 11-year retrospective experience in a high-complexity tertiary hospital. Clin Dermatol;41:712-20](#)

1.1.4 Inflammatory and Postinfectious Immunologic Reactions

1.1.4.1 Erythema nodosum



Grading & Level of importance: B

V. del Marmol, Brussels; P. Ortiz-Romero, Madrid; J. White, Brussels

ICD-11

EB31

Synonyms

Subacute nodular migratory panniculitis.

Definition

Erythema nodosum is a tissue-reaction pattern with many causes, characterised by painful subcutaneous nodules on the shins, most commonly in women.

Epidemiology

It is present in approximately **2.4/1000 population/year**, mostly in Spring and Autumn (due to streptococcal infections). The female: male ratio is 3-6: 1. Children may be typically affected and adults between 20 - 40 years.

Pathogenesis

- Not well-known. Erythema Nodosum (EN) has been considered a delayed hypersensitivity

response to a variety of antigenic stimuli. 30-50% of cases remain idiopathic.

- Common causes:
- Streptococcal infections
- Viral upper respiratory tract infections
- Sarcoidosis
- Bowel infections (e.g. Yersinia)
- Medications (e.g., penicillins, sulphonamides, oral contraceptives)
- Crohn's disease
- Tuberculosis
- others like, cat scratch disease, ornithosis

Numerous other causes should be considered.

Table 1 Etiologies of erythema nodosum [1, 9, 10, 93]

Etiology	
Primary	Idiopathic
Secondary	
Infections	
Bacterial	Beta-hemolytic <i>Streptococcus</i> , <i>Staphylococcus</i> , <i>Escherichia coli</i> , <i>Klebsiella pneumoniae</i> , <i>Pseudomonas aeruginosa</i> , <i>Mycobacterium tuberculosis</i> , atypical mycobacteria, yersiniosis, salmonellosis, shigellosis, brucellosis, rickettsiosis, leptospirosis, tularemia, <i>Bartonella henselae</i> , syphilis, leprosy, <i>Borrelia burgdorferi</i> , meningococemia, gonorrhea, chancroid, <i>Campylobacter</i> spp., <i>Chlamydia pisttaci</i> , <i>Corynebacterium diphtheriae</i> , <i>Cutibacterium acnes</i> , <i>Moraxella cataralis</i> , <i>Pasteurella pseudotuberculosis</i>
Viruses	Infectious mononucleosis, hepatitis B and C, cytomegalovirus, herpes simplex, parvovirus B19, HIV, measles, varicella, poxvirus (milker's nodule and Orf disease), Coronavirus Disease 2019
Fungal	Coccidioidomycosis, blastomycosis, histoplasmosis, sporotrichosis, nocardiosis, mucormycosis, aspergillosis, dermatophytosis (<i>Trichophyton</i> spp.)
Parasites	Amebiasis, giardiasis, toxoplasmosis, taeniasis, ascariasis, hydatidosis, trichomoniasis, sparganum larvae, hookworm infestation
Systemic diseases	Sarcoidosis, inflammatory bowel disease, celiac disease, colon diverticulosis, Behçet disease, Reiter syndrome, systemic lupus erythematosus, antiphospholipid syndrome, rheumatoid arthritis, ankylosing spondylitis, Takayasu arteritis, Berger disease, panarteritis nodosa, Wegener granulomatosis, Sweet syndrome, adult Still disease, acne fulminans, Sjögren syndrome, IgA nephropathy, chronic active hepatitis, granulomatous mastitis
Drugs	Penicillin, amoxicillin, ampicillin, cephalosporins, ciprofloxacin, sulfonamides, sulfonyleureas, cotrimoxazole, streptomycin, minocycline, nitrofurantoin, bromides and iodides, oral contraceptives, progesterone, gold salts, hydantoin, carbamazepine, ACE inhibitors, ARBs, proton pump inhibitors, leukotriene inhibitors, aromatase inhibitors, granulocytic colony-stimulating factors, fluoxetine, among others. Vaccines (tetanus, diphtheria, and acellular pertussis, BCG, hepatitis B, human papillomavirus, malaria, rabies, smallpox, typhoid, and cholera)
Malignancies	Hodgkin and non-Hodgkin lymphoma, leukemia, sarcoma, pelvic carcinoma, carcinoid tumor, renal, cervix, gastric, colorectal, pulmonary, hepatocellular, and pancreatic carcinoma
Pregnancy	

ACE angiotensin-converting enzyme, ARBs angiotensin II receptor blockers, HIV human immunodeficiency virus, IgA immunoglobulin A

From Daniela Michelle Perez-Garza et al. Erythema Nodosum: A Practical Approach and Diagnostic Algorithm. American Journal of Clinical Dermatology (2021) 22:367–378.

<https://doi.org/10.1007/s40257-021-00592-w>

Signs & Symptoms

There is often a **prodrome with malaise, fever, joint pain**. Then tender, poorly defined subcutaneous erythematous nodules appear (usually bilateral and symmetric), which are warm to the touch. Over time, the colour changes from bright red to dark red to contusifiform (bruise-like) to yellow-brownish and finally light grey.

Localisation

Shins are the most commonly affected area but occasionally the thighs may be affected and rarely buttocks or arms.

Classification

According to cause.

Laboratory & other workups

Blood tests with several serologic markers. Investigation is dictated by the patient's history and examination findings (rheumatism, streptococci, tuberculosis, yersiniosis, angioconverting enzyme - see pathogenesis) stool culture (in case of diarrhea) and radiographic studies may be considered to exclude some of the known causes. Investigation is dictated by the patient's history and examination findings.

Dermatopathology

The timing of any biopsy should be carefully planned (i.e., not too soon after the appearance of the lesions and not too late afterwards). Erythema nodosum is the prototypic of predominantly septal panniculitis. Characteristically, in the early phase, there is an inflammatory infiltrate of neutrophils in the subcutaneous fat septae, edema, macrophages and foam cells. In the later phase granulomatous reaction and finally fibrous septae and scarring of fat tissue occurs. It is in general a septal panniculitis. Miescher's granulomas can be present. They are highly characteristic, if not pathognomonic and consist of small collections of macrophages surrounding cleft-like spaces.

Course

The condition usually **heals spontaneously** without scarring, however, the eruption may sometimes be **longstanding, migrating and/or relapsing**. Rarely it may be recurrent depending on the pathogenetic cause. The process usually lasts 3 - 6 weeks.

Complications

Longstanding and migrating subtype.

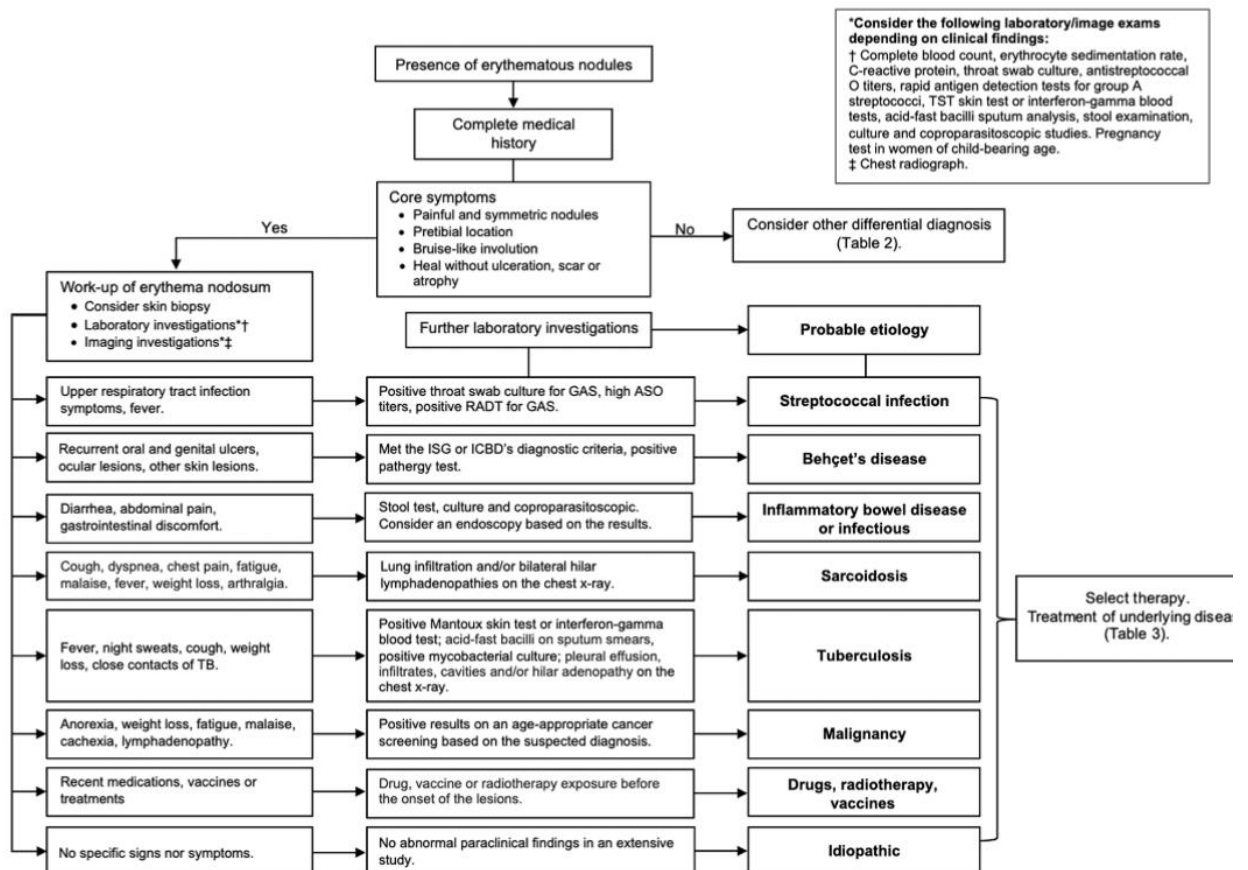
Diagnosis

Clinical features are usually diagnostic, but as clinical appearance can be undistinguishable from other panniculitis or even panniculitic-like lymphomas, biopsy is mandatory at least in the first flare of lesions. A careful search for the underlying disease is needed. Despite investigations, in 25-50% of cases no cause is identified.

Differential Diagnosis

Polyarteritis nodosa, nodular vasculitis, other forms of panniculitis e.g., trauma, cold.

Algorithm for clinical and laboratory approach to check diagnosis of erythema nodosum



From Daniela Michelle Perez-Garza et al. Erythema Nodosum: A Practical Approach and Diagnostic Algorithm. American Journal of Clinical Dermatology (2021) 22:367–378.

<https://doi.org/10.1007/s40257-021-00592-w>

Prevention & Therapy

Treat underlying disease and consider the administration of systemic NSAIDs. If the clinical manifestations of erythema nodosum are severe, short-term systemic corticosteroids may be given. Potassium iodide is sometimes used for idiopathic and/or recurrent cases. Supportive measures such as bed rest, heparinoid creams and compression stockings may also be helpful.

Special

None.

References

- [Daniela Michelle Perez-Garza et al. \(2021\) Erythema Nodosum: A Practical Approach and Diagnostic Algorithm. Am J Clin Dermatol. 2021 May;22\(3\):367-378. doi: 10.1007/s40257-021-00592-w. Epub 2021 Mar 8. PMID: 33683567.](#)
- [Requena L, Yus ES. Panniculitis. \(2001\). Part I. Mostly septal panniculitis. J Am Acad Dermatol. 2001 Aug;45\(2\):163-83; quiz 184-6. doi: 10.1067/mjd.2001.114736. PMID: 11464178.](#)
- [Requena L, Sanchez Yus E. Panniculitis. \(2001\). Part II. Mostly lobular panniculitis. J Am Acad Dermatol. Sep;45\(3\):325-61; quiz 362-4. doi: 10.1067/mjd.2001.114735. PMID: 11511831.](#)

1.1.4.2 Pyoderma gangrenosum

Grading & Level of importance: C

Gimenez-Arnau, Barcelona; P. Ortiz-Romero, Madrid; RM. Pujol, Barcelona



ICD-11

EB-21

Synonyms

Dermatitis ulcerosa, Phagedenic pyoderma, phagedenic ulcer.

Definition

Pyoderma gangrenosum (PG) is a rare, recurrent, chronic and painful neutrophilic dermatosis that presents with rapidly developing, painful skin ulcers presenting with violaceous, undermined borders

and peripheral erythema.

Epidemiology

General incidence: 3 -10 per million per year. Peak of incidence occurs between the ages of 20 to 50 years. Women slightly more often affected than men. Men are more commonly affected in malignancy-associated PG.

30-75% of patients with PG have a second underlying immune-mediated disease, most commonly inflammatory bowel disease (IBD) (17-20 %), rheumatoid arthritis (12%) and hematological malignancies (4-8 %).

Aetiology & Pathogenesis

More than **50% of patients with PG have an associated systemic disease**, including:

Inflammatory bowel diseases (Crohn's disease and ulcerative colitis) are the systemic diseases most frequently reported in association with PG. High relative risk (odds ratio) of a patient with IBD to develop PG (29.2), in contrast, only 0.75% of patients with inflammatory bowel diseases had PG. There is no association between the severity of inflammatory bowel diseases and the presence of PG.

Arthritis: Most frequently seronegative arthritis of a single, large joint. Classical forms of **RA and ankylosing spondylitis** are also associated.

Hematologic malignancies (7%). Most commonly acute **myelogenous leukemia**, but a broad spectrum of lymphoproliferative disorders including monoclonal gammopathies, leukemia, lymphoma, and myelodysplastic syndromes have been described in association with PG.

Drugs: Interferon- α 2b, G-CSF in patients with hematological disorders, propylthiouracil, and gefitinib.

Autoinflammatory diseases:

PAPA syndrome is an autosomal dominant inherited disease characterized by non-axial destructive polyarthritis, severe cystic acne and PG. PAPA syndrome caused by mutations in the PSTPIP1 gene involved in regulation of inflammatory response.

PASH syndrome (PG, acne and hidradenitis suppurativa) and

PAPASH syndrome (pyogenic arthritis, PG, acne and hidradenitis suppurativa) are other syndromic forms of PG.

Overlap between PG and Sweet's syndrome: Usually observed in patients with myeloproliferative disorders.

The pathogenesis of PG is unknown. Trauma (pathergy) may induce the development or worsen previous lesions PG lesions (e.g. biopsy).

Release of cytokines (IL-36, IL-8) and danger signals that can enhance innate immune responses.

Tissue damage can also release autoantigens especially in patients harboring pathogenic variants of several autoinflammatory genes (PTPN6, PSTPIP1, MEFV, NLRP3, NLRP12, LPIN2, and NOD2), some of them involved in the inflammasome pathway. Hyperactivation of the inflammasome cleaves inactive precursor forms of IL-1 β , IL-18 and IL-33 to generate their active pro-inflammatory counterparts. Patients with PAPA syndrome have increased activation and secretion of IL-1 β .

In PG, elevated levels of numerous pro-inflammatory cytokines have been detected including CCL3, CCL5, CXCL9, CXCL10, CXCL11, interferon- γ , TNF- α , IL-1 α , IL-8 (encoded by CXCL8), IL-15, aberrant integrin oscillations on neutrophils and aberrant neutrophil tracking.

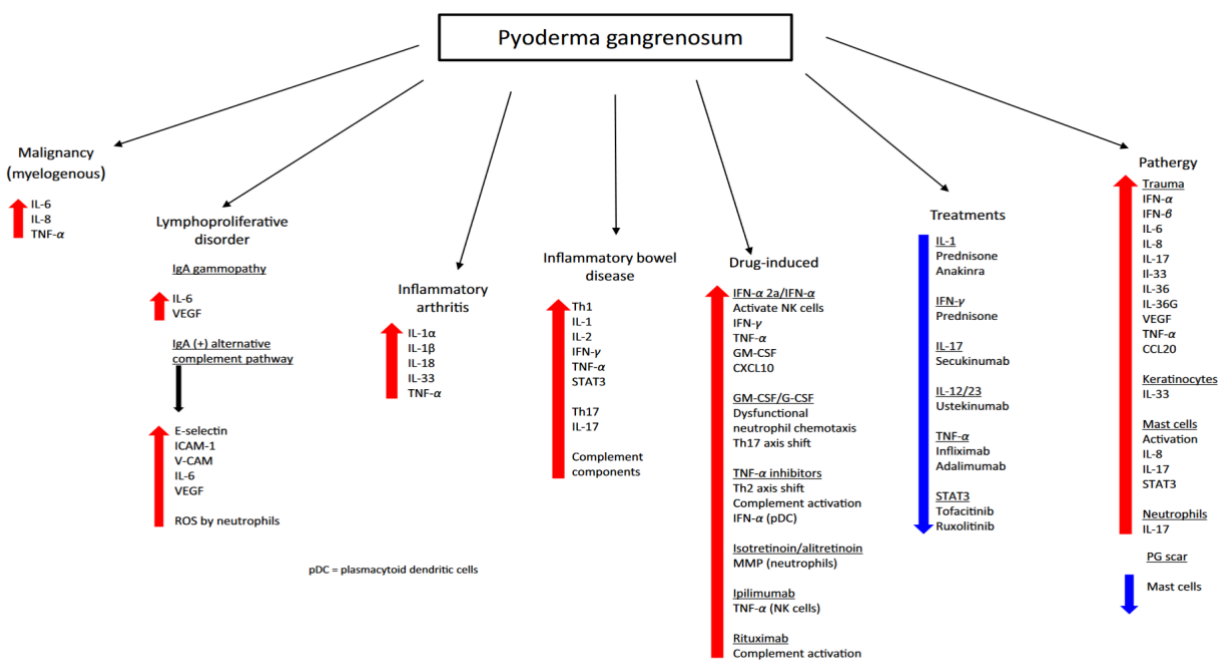


Figure 2 Pathophysiological aspects in pyoderma gangrenosum.

From Dissemond et al (2023). Pyoderma Gangrenosum: Treatment Options. *Drugs* 83:1255–1267 (2023)

<https://doi.org/10.1007/s40265-023-01931-3>

Signs & Symptoms

Lesions of PG presents with a tender nodule, plaque, or sterile pustule that enlarges, over a course of days, progressing to **sharply demarcated painful ulcers with central necrosis**. The lesions have undermined **violaceous borders and a surrounding zone of erythema**. Central necrotic areas with

hemorrhagic or purulent exudates develop. The ulcer usually increases in size and depth or extends through the appearance of new peripherally located pustules.

PG may be a solitary lesion but also may manifest as multiple simultaneously recurrent lesions. In 25-50% of cases, PG arises at areas of trauma (pathergy). As the lesions heal, cribiform or 'sieve-like' atrophic scars or wrinkled (cigarette paper-like) scars develop.

Extracutaneous sterile neutrophilic infiltrates can be observed in the bones, liver, lungs, pancreas, spleen, kidneys, and central nervous system of patients with PG.

Localisation

The lower legs (pretibial area) are most commonly affected but other parts of the skin and mucous membranes including breast, hand, trunk, head and neck and peristomal skin may also be involved.

Classification

Different clinical variants of PG have been defined:

1. **Ulcerative (classical) PG:** Most commonly occurs at sites of trauma, frequently on the anterior lower extremities. Associated disorders: IBD, hematological malignancies, rheumatoid arthritis, seronegative arthritis and monoclonal gammopathy.
2. **Bullous PG:** Painful bulla/e that can progress to erosions and/or ulcers. Increased incidence on the face and the dorsum of the hands. Overlap with Sweet's syndrome. Subcorneal, subepidermal and intra-epidermal bullae with dermal neutrophilic infiltrate and microabscess formation. Associations: Myeloproliferative disorders (70%) and IBD.
3. **Pustular PG:** Pustules with erythematous borders. Association: IBD.
4. **Vegetating (granulomatous superficial) PG:** Low-growing, non-purulent, superficial ulcer; borders are not undermined. Head and neck. Histologically: Palisading granulomatous reaction. No associated disorders.
5. **Peristomal PG:** Papules that erode into ulcers with undermined borders adjacent to the stoma. Dermal neutrophilic infiltrates with granulation tissue. Associations: IBD, gastrointestinal malignancy, connective tissue disease and monoclonal gammopathy.
6. **Postoperative PG:** Erythema at the surgical site, followed by wound dehiscence or painful ulcerations that coalesce. Commonly associated with abdominal and breast surgery.

Laboratory & other workups

Occasionally peripheral leukocytosis with neutrophilia and elevated markers of inflammation

(erythrocyte sedimentation rate and C-reactive protein).

Laboratory tests are performed to evaluate for associated disorders rather than to establish the diagnosis of pyoderma gangrenosum.

Dermatopathology

The histopathology of PG is nonspecific and changes with the stage of the lesion. Dermal edema, suppurative inflammation and sterile abscess formation. At the periphery of the lesion, perivascular or perifollicular lymphoid infiltrates may also be present. Additional staining of the biopsy sample is required in order to rule out bacterial and fungal infections.

The initial lesions show a **deep suppurative folliculitis with dense neutrophilic infiltrate**. Focal leukocytoclastic vasculitis changes may be present. PG with necrotizing granulomatous inflammation has been observed.

Course

Variable. Chronic, relapsing or self-remitting disease. From mild to aggressive with intense morbidity.

Complications

Secondary infection, tissue destruction, intractable pain. Impact on quality of life (depression). Complications secondary to long term immunosuppressive therapy.

Diagnosis

Diagnosis of PG is based on history of an underlying disease, typical clinical presentation, histopathology, and exclusion of other diseases that would lead to persistent painful ulcers. An infectious disease should be ruled out. An additional skin biopsy for microbiological studies (bacterial, fungal and mycobacterial cultures, viral or other micro-organism PCR amplification) should be obtained.

PG **diagnostic workup** includes a complete blood count with peripheral blood smear, biochemical survey, serum and urine protein electrophoresis, stool sampling for occult blood and parasites as well as syphilis serologic tests and immunological studies (rheumatoid factor, ANA, ENA, antiphospholipid antibodies, pANCA, cANCA) for autoimmune diseases.

Additional tests may be indicated in cases with concomitant joint or gastrointestinal symptoms including radiological imaging and/or a colonoscopy to rule out inflammatory arthritis and ulcerative colitis, respectively. Peripheral smear, and bone marrow aspiration or biopsy should be performed, if indicated,

to evaluate for hematologic malignancies. Age-appropriate cancer screening in selected cases.

Major criteria

1. Rapid progression of a painful, necrolytic cutaneous ulcer with an irregular, violaceous, and undermined border
2. Exclusion of other causes of cutaneous ulceration

Minor criteria

1. History suggestive of pathergy or clinical findings of cribriform scarring
2. Systemic diseases associated with PG
3. Histopathologic findings
4. Treatment response to systemic steroids

Recently, some new diagnostic criteria for PG have been proposed: PARCELSUS and Delphi diagnostic criteria.

Differential Diagnosis

The differential diagnosis should include a wide range of diseases manifested as chronic and persistent cutaneous ulcers:

- Vascular occlusive or venous disease (including calciphylaxis).
- Vasculitis (rheumatoid arthritis, ANCA-related vasculitis).
- Behcet's disease, etc.).
- Hypercoagulable states (anti-phospholipid syndrome).
- Malignant neoplasms (lymphomas, leukaemia).
- Infectious diseases (ecthyma, streptococcal synergistic gangrene, deep mycoses, atypical mycobacterial infections, late syphilis, deep viral herpetic infections, necrotizing cellulitis).
- Exogenous tissue injuries (faccial panniculitis), insect or spider bites, and
- Drug reactions (pustular drug reactions).
- Primary cutaneous lymphomas

Prevention & Therapy

A primary prevention is not possible.

Oral corticosteroids (0.5–1 mg/kg/day) are the mainstay of treatment for rapid control of the disease and, in other cases, cyclosporine A may be used as a steroid-sparing agent either alone or in combination with corticosteroids. In severe and recalcitrant cases, pulsed intravenous methylprednisolone should be considered.

Combinations of steroids with cytotoxic drugs are used in resistant cases. The combination of steroids with dapsone or different immunosuppressants or steroid-sparing agents such as colchicine, azathioprine, mycophenolate mofetil, methotrexate, cyclophosphamide, clofazimine, thalidomide, tacrolimus, sulfasalazine and minocycline has been proposed.

Anti-tumor necrosis alpha therapy (infliximab, etanercept, adalimumab, certolizumab pegol), could be prescribed in cases of PG associated with IBD. Other systemic treatments include high doses of intravenous immunoglobulin (IVIG), biologic drugs such as IL-1 and IL-23 inhibitors (ustekinumab), anti-IL-23 (tildrakizumab) anti-IL-17 (secukinumab) and IL-1 antagonists (anakinra, canakinumab, gevokizumab), and small molecules (JAK-STAT inhibitors) or complement Factor C5a inhibitor vilobelimumab (IFX-1) have been used with variable success.

Topical treatments including superpotent corticosteroids and calcineurin inhibitors (tacrolimus) and, intralesional therapy (triamcinolone, methotrexate) may be used as adjuvant therapies in conjunction with systemic agents. Topical therapy with wound dressings, skin transplants and the application of bio-engineered skin are useful in selected cases.

Prognosis

The clinical course of PG is unpredictable—from a precipitous onset with rapid spread to a more indolent pattern. Frequent relapses. Potentially life-threatening disease. In some series with a mortality rate of up to 30%.

Special

PG is included within the spectrum of neutrophilic dermatoses.

Neutrophilic dermatoses are a heterogeneous group of inflammatory skin disorders characterized histologically by a neutrophilic infiltrate with no evidence of underlying infection or vasculitis.

References

- [Ahn C, Negus D, Huang W. Pyoderma gangrenosum: a review of pathogenesis and treatment. Expert Rev Clin Immunol . 2018 Mar;14\(3\):225-233.](#)

- [Maverakis E, Marzano AV, Le ST, Callen JP, Brüggen MC, Guenova E, Dissemond J, Shinkai K, Langan SM. Pyoderma gangrenosum. Nat Rev Dis Primers. 2020; 6:81](#)
- [Dissemond, J., Marzano, A.V., Hampton, P.J. et al. Pyoderma Gangrenosum: Treatment Options. Drugs 83, 1255–1267 \(2023\). <https://doi.org/10.1007/s40265-023-01931-3>](#)

1.1.4.3 Sweet's syndrome (acute neutrophilic dermatosis)

Grading & Level of importance: C

A. Gimenez-Arnau, Barcelona; P. Ortiz-Romero, Madrid; RM. Pujol, Barcelona



ICD-11

EB20

Synonyms

Acute febrile neutrophilic dermatosis.

Gomm-Button disease.

Definition

Sweet's syndrome is a disorder characterized by a **variety of symptoms**, clinical and histological findings, which include **fever, neutrophilia, erythematous plaques or nodules, and a diffuse dermal neutrophilic infiltrate**. Additional criteria include absence of infection or histopathological changes of vasculitis and responsiveness to corticosteroids.

Epidemiology

Worldwide distribution. Usually presenting in middle age women (30-60 years) with a 4:1 female to male ratio. No racial predilection.

Aetiology & Pathogenesis

Pathogenesis is unknown. Possible hypersensitivity reaction to a variety of eliciting bacterial, viral, or tumor antigens that may trigger neutrophil activation and infiltration. Possible role of activating cytokines and chemokines such as IL-1, IL-3, IL-6, IL-8, G-CSF, GM-CSF, and interferon-gamma.

Most cases of Sweet's syndrome are considered to be idiopathic, but could also be associated with different disorders:

Malignancy (10-20%): Myeloproliferative disorders (myelodysplasia, acute myelogenous leukemia, chronic myelogenous leukemia, multiple myeloma, monoclonal gammopathy, lymphoma) and rarely with solid tumors.

Inflammatory and autoimmune disorders: Inflammatory bowel disease (ulcerative colitis or Crohn disease), rheumatoid arthritis, sarcoidosis, systemic lupus erythematosus, Sjogren syndrome, polychondritis, and thyroid disease (both Graves disease and Hashimoto thyroiditis), Behcet disease, dermatomyositis.

Infectious diseases: HIV, viral hepatitis, tuberculosis, upper respiratory tract infections (mostly Streptococcus) or Chlamydia infection.

Drugs: G-CSF, antibiotics (minocycline, nitrofurantoin, trimethoprim-sulfamethoxazole, norfloxacin, ofloxacin), antihypertensives (hydralazine, furosemide), NSAIDs (diclofenac, celecoxib), immunosuppressives (azathioprine), antiepileptics (carbamazepine, diazepam), anti-cancer (bortezomib, imatinib mesylate, ipilimumab, lenalidomide, topotecan, vemurafenib), tyrosine-kinase inhibitors, antipsychotics (clozapine), anti-thyroid (propylthiouracil).

Pregnancy

Some genetic factors such as HLA-B54, MEFV gene mutations in familial Mediterranean fever patients, and chromosome 3q abnormalities have been observed in patients with Sweet's syndrome.

Signs & Symptoms

Acute febrile episode associated with well-defined edematous, tender erythematous plaques or nodules accompanied by fever and constitutional symptoms (myalgia, fatigue, headache).

The lesions appear as **solitary or multiple** 0,5 to 12 cm red or purple-red, papules or nodules with a pseudovesicular appearance. Larger lesions may develop into plaques. Central clearing may lead to annular patterns. **The classical (idiopathic) form is often preceded by an upper respiratory or gastrointestinal tract infection.**

In patients with malignancy-associated Sweet's syndrome, the lesions may adopt atypical clinical patterns (bullous, ulcerated or mimicking pyoderma gangrenosum). Other clinical variants include

localized neutrophilic dermatosis of the dorsal hands, subcutaneous, cellulitic, and necrotizing Sweet's syndrome. Lesions on the legs can mimic erythema nodosum (in fact both conditions can be associated in the same biopsy).

Sweet's syndrome lesions can uncommonly be associated with extracutaneous systemic manifestations (especially in the setting of an underlying malignancy) including arthralgias and non-erosive inflammatory arthritis (30-60%), ocular inflammation, (conjunctivitis, episcleritis, uveitis), myocarditis, multifocal sterile osteomyelitis, alveolitis, hepatitis, pleural effusions, and aseptic meningitis.

Localisation

The eruption is often distributed asymmetrically. The most frequent lesion locations are the upper extremities, face and neck. They can also be present on the chest, back, and lower extremities.

Classification

Sweet's syndrome may occur in three clinical settings:

1. **Classical Sweet's syndrome (50%).** It may be associated with a previous infection (upper respiratory tract or gastrointestinal tract), inflammatory bowel disease, or pregnancy.
2. **Malignancy-associated Sweet's syndrome (< 35%)** can occur as a paraneoplastic syndrome in patients with an established cancer or in individuals with a previous diagnosis of a malignant hematological or solid neoplasm. Most commonly related to acute myelogenous leukemia. The dermatosis can precede, follow or appear concurrently with the diagnosis of the patient's malignant disease.
3. **Drug-induced Sweet's syndrome**

Laboratory & other workups

Peripheral leukocytosis (> 8000) with neutrophilia (> 70%). Elevated markers of inflammation (erythrocyte sedimentation rate and C-reactive protein).

Dermatopathology

Diffuse dense dermal neutrophilic infiltrates in the upper dermis and marked edema of the dermal papillae. Leukocytoclasia may be present. No vasculitic changes. No epidermal involvement although spongiosis and subcorneal pustule formation may be present. In rare instances, the inflammation may extend to involve the subcutis, usually mimicking erythema nodosum.

Histiocytoid Sweet's syndrome is a variant and includes immature myeloid cells (histiocytoid cells),

sometimes atypical monocuclear cells (in patients with an underlying myelodysplastic syndrome).

Course

The individual Sweet's syndrome **lesions enlarge and may coalesce to form irregular, sharply demarcated plaques over a period of days to weeks**. Subsequently, either spontaneously or after treatment, the lesions **usually resolve without scarring**. Some patients may present with recurrences of the dermatosis.

Complications

Depending on the presence of associated disorders or extracutaneous systemic manifestations.

Diagnosis

The diagnosis is established on the basis of characteristic clinical and histopathological findings. Histopathological features are a requirement for the diagnosis of Sweet's syndrome. An infectious disorder should be ruled out.

Diagnostic criteria for Sweet's syndrome have been proposed. Diagnosis may be based on fulfilling both major criteria and two of the four minor criteria.

Major criteria:

1. Sudden onset eruption of tender, painful plaques or nodules
2. Neutrophilic infiltrate in the dermis without vasculitis

Minor criteria:

1. Fever >38C
2. Illness preceded by an upper respiratory or gastrointestinal infection, or associated with an underlying typical inflammatory disorder, malignancy, or pregnancy
3. Elevated white cell count with neutrophil predominance and elevated inflammatory markers
4. Positive response to corticosteroids

Workup shall include determining the underlying cause if present, especially malignancies. Complete blood cell count with leukocyte differential and platelet counts. Evaluation of acute phase reactants

(including the erythrocyte sedimentation rate or C-reactive protein), biochemistry (hepatic and renal function tests), and urinalysis. Serologic evaluation for antistreptolysin-O antibody, rheumatoid factor, and thyroid function. Additional tests if extracutaneous involvement is clinically suspected.

Age-appropriate cancer screening, including colonoscopy, mammogram, and PAP smears, should be pursued.

Differential Diagnosis

- Febrile infectious disorders (bacterial, fungal, and mycobacterial).
- Cutaneous lesions of Sweet's syndrome may mimic cellulitis, allergic contact dermatitis, hypersensitivity drug reactions,
- Erythema multiforme, erythema nodosum, pyoderma gangrenosum, leukocytoclastic vasculitis or leukemia cutis

Prevention & Therapy

Systemic corticosteroids are the treatment of choice often achieving a rapid response. Other first-line oral systemic agents are potassium iodide, dapsone and colchicine. If corticosteroids are contraindicated or recurrence after tapering develops, steroid-sparing agents including methotrexate, doxycycline, indomethacin, chlorambucil, and cyclosporine could be prescribed. If an infectious condition is associated, specific treatment should be given.

Topical high potency or intralesional corticosteroids or corticosteroids may be used for localized lesions.

Prognosis

Sweet's syndrome typically **follows a benign course**, which, if untreated, can involute spontaneously without scarring in 5 –12 weeks.

Prognosis varies depending on the underlying associated disorder (if present).

Recurrences may occur usually in cases associated with an underlying inflammatory disease or hematologic malignancy.

Special

Sweet's syndrome is the most representative entity of febrile neutrophilic dermatoses.

Neutrophilic dermatoses are a heterogeneous group of inflammatory cutaneous disorders characterized histologically by a neutrophilic infiltrate with no evidence of underlying infection or vasculitis.

References

- [Joshi TP, Friske SK, Hsiou DA, Duvic M. New Practical Aspects of Sweet Syndrome. Am J Clin Dermatol. 2022;23:301-318.](#)
- [Villarreal-Villarreal CD, J Ocampo-Candiani, A Villarreal-Martínez. Sweet Syndrome: A Review and Update. Actas Dermosifiliogr . 2016; 107:369-78.](#)
- [Cohen PR. Sweet's syndrome--a comprehensive review of an acute febrile neutrophilic dermatosis.Orphanet J Rare Dis. 2007; 2:34.](#)

1.2 Autoimmune and Bullous Dermatoses

1.2.1 Lupus Erythematosus

Grading & Level of importance: C

G. Girolomoni, Verona; P. Gisondi, Verona; L. Martos-Cabrera, Madrid; M. Maurelli, Verona



ICD-11

4A40

Synonyms

None.

Definition

Lupus erythematosus (LE) with its different variants is a chronic and serious inflammatory **connective tissue autoimmune disease** of unknown cause with marked immunogenetic component, which involves the skin and/or other organs. It is associated with pathogenic antibodies directed against components of cell nuclei in various tissues in particular keratinocytes, other epithelia and endothelia and matrix cells as well.

Epidemiology

Usually, the disease affects young adults between 20-40 years of age with a female to male ratio of 7-15:1. Prevalence of systemic LE (SLE) ranges for 20 to 150 per 100,000 women. It is more prevalent in non-Caucasians.

Aetiology & Pathogenesis

LE is characterized by the production of autoantibodies and the deposition of immune complexes in tissues.

LE is the result of **genetic (HLA association), environmental and hormonal factors. Innate and adaptive immune responses** against self-antigen induce the production of autoantibodies and the deposition of immune complexes in tissues that leads to the activation of complement, and accumulation of inflammatory cells and self-reactive T lymphocytes. Autoantibodies cause autoimmune haemolytic anaemia (mediated by warm IgG anti-erythrocytes antibodies); circulating immune complexes are responsible for vasculitis and glomerulonephritis; and antibody-mediated cellular cytotoxicity is involved in skin lesions. The role of innate immune response in the pathogenesis of LE has been emphasized, especially the discovery of Toll-like receptors recognizing complexes of antimicrobial peptides and self- DNA on plasmacytoid dendritic cells, which produce IFN- α , a key cytokine in the induction of LE lesions.

The environmental triggers implicated in lupus are **ultraviolet (UV)-light**, drugs (hydralazine, procainamide, estrogens), infections (Epstein-Barr virus), trauma (Koebner phenomenon), silica, mercury, cigarette smoking, and possible stress.

The interplay between the genetic and environmental factors triggers a complex inflammatory cascade of cytokines, chemokines and inflammatory cells residing within and recruited to the skin. In particular, it consists in an activation of keratinocytes, endothelial cells, and skin dendritic cells with a production of type I IFN, followed by the recruitment of CD8+ cytotoxic T-cells. The result is a cytotoxic keratinocyte damage.

Clinical presentation

Skin involvement is usually distinguished in **acute cutaneous LE (ACLE), subacute cutaneous LE (SCLE), and chronic cutaneous LE (CCLE)**. Skin lesions are typically evoked or exacerbated by sun exposure.

- **ACLE** is characterized by the presence of erythema, localized at the nose and malar eminences, with a butterfly distribution. The erythema is often sudden in onset, accompanied by oedema and fine scale, and **correlates** with systemic involvement. Patients may have widespread involvement of the face as well as erythema and scaling in other sun-exposed area such as the extensor surfaces of the extremities and upper chest. Painful oral ulcerations are common. Acute cutaneous lupus and oral ulcers are the typical skin lesions of SLE.
- **SCLE** is characterized by non-scarring, polycyclic-papulosquamous annular lesions or psoriasiform plaques which usually involve the upper half of the body and are clearly light-provoked. Extracutaneous symptoms (malaise, fatigue, myalgias, arthralgias) may occur, but renal and

central nervous system involvement is generally absent. Lesions affects the back, upper chest, shoulders, extensor surfaces of the arms, and dorsum of the hands; lesions are uncommon on the central face and the flexor surfaces of the arms as well as below the waist. The lesions in SCLE are more widespread but have less tendency for scarring than lesions of CCLE. Lesions often results in hypopigmentation or even dyspigmentation, but without scarring nor atrophy as sequelae. A significant portion of SCLE is drug-induced (diuretics, calcium channel blockers, terbinafine, proton pump inhibitors) sometimes with a long latency (months) between drug introduction and the emerging of skin lesions. SCLE lesions may have a chronic and relapsing course.

- **Cutaneous discoid LE (CDLE)** is the most common type of CCLE. It is characterized by coin or disk-shaped erythematous papules or plaques with follicular hyperkeratosis, a thick and adherent scale that occludes hair follicles, and a tendency to heal with scarring, usually on light-exposed areas (face, upper chest) or the scalp (scarring alopecia). When the scale is removed, its underside shows small lesions that correlate with the openings of hair follicles, a finding which is characteristic. Discoid lesions have a characteristic tendency for scarring and a substantial proportion of patients may develop disfiguring scarring if not properly treated. Long-standing lesions develop central atrophy, scarring and hypopigmentation in the central area with hyperpigmentation at the periphery. Lesions persist for years and tend to expand slowly. Other variants of CCLE include hypertrophic, also called verrucous LE, disseminated discoid lupus erythematosus, chilblain lupus erythematosus (acral involvement), lupus profundus/lupus panniculitis (deeper involvement). Extracutaneous symptoms and involvement is usually absent or very mild and limited in CCLE.

In addition to these lupus-specific manifestations, there are **non-lupus-specific cutaneous manifestations**. These include **alopecia** (diffuse, 'lupus hair'), **periungual telangiectases**, **Raynaud's phenomenon**, **palmar erythema**, small vessel vasculitis presenting with urticarial lesions (urticarial vasculitis), hemorrhagic papules (palpable purpura) and skin necrosis. Cutaneous signs of antiphospholipid syndrome are livedo racemosa, acrocyanosis, skin necrosis, ulcerations, and stellate atrophic white lesions (livedoid vasculopathy).

Extracutaneous and systemic symptoms and involvement in SLE include malaise, asthenia, mild fever, oral ulcers, arthralgia/non-erosive arthritis serositis (pleuritis, pericarditis), neurologic disease with seizures and psychosis, renal disease, characterized by proteinuria $> 0.5\text{g/d}$, nephritis, and hematologic abnormalities with hemolytic anemia, leukopenia, lymphopenia, and thrombocytopenia. Most patients with SLE have intermittent polyarthrititis, characterized by soft tissue swelling and tenderness in joints and tendons of hand, wrists and knees. Joint deformity of hands and feet occurs in only 10% of cases. Erosions develop in almost 50% of cases. Myositis can occur, but myalgias without myositis are more common. Nephritis is the most frequent renal manifestation, and the most serious in SLE and a major cause of mortality in these patients. In person suspected to have SLE, it is very important the urinalysis, because of nephritis is asymptomatic. The next passage is to manage a renal biopsy. Patients with

dangerous proliferative forms of glomerular damage usually have microscopic haematuria and proteinuria; one half develop nephrotic syndrome, and most develop hypertension. The central nervous system and peripheral nervous system manifestations of SLE are an important cause of morbidity and mortality. The most common manifestations are: difficulties with memory and reasoning, and also headaches, seizures, psychosis; some patients develop myelopathy. Also, vascular occlusion occurs in patients with SLE, and consist in ischemic attacks, strokes, myocardial infarction. These patients usually have SLE with antiphospholipid antibodies, which are associated to hypercoagulability and thrombotic events. Atherosclerosis is more common in patients with chronic SLE. Pleuritis is the most common pulmonary manifestation of SLE. Pulmonary infiltrates are a manifestation of active SLE. Pericarditis is the most frequent cardiac manifestation of SLE, followed by myocarditis and fibrinous endocarditis of Libman-Sacks. Anemia (normochromic normocytic) is the most frequent hematologic manifestation; leukopenia is also common and is characterized by lymphopenia.

Laboratory & other workups

- Characteristics of **SLE** is the presence in the serum of auto-antibodies at high titers. These include ANA, and anti-extractable nuclear antigens (ENA), anti-dsDNA, anti-Sm, antiphospholipid antibodies and false positive syphilis serology. Active disease is associated with elevated erythrocyte sedimentation rate and low complement fraction levels. Anti-dsDNA correlates with active disease, renal involvement (nephritis), vasculitis, and have a prognostic value.
- **SCLE** is frequently associated with the presence of anti-ENA, anti-SSA (Ro) in 70-90% of cases, and anti SSB (anti-La) in 25-60% of cases. Anti-dsDNA is present in less than one third of patients. Anti-histone antibodies are common in drug induced SLE.
- **CDLE** is more rarely associated with low titers specific serum autoantibodies and normal complement factors.

Dermatopathology

A skin biopsy is very important in the diagnosis of LE.

- Most forms of **cutaneous LE** share similar histological findings such as interface dermatitis and perivascular and periadnexial mononuclear infiltrate. The epidermis shows atrophy and vacuolar degeneration of basal keratinocytes associated with an infiltrate of lymphocytes entering the epidermis. CDLE shows marked follicular and adnexal changes, follicular hyperkeratosis and thickened basement membrane zone. The dermis presents mucin deposition and a dense perivascular and periadnexial lymphocytic infiltrate with many plasmacytoid dendritic cells.
- **Direct immunofluorescence microscopy of lesional skin** frequently reveals deposits of immunoglobulins and complement in the epidermal basement membrane zone. In both sun-exposed and non-sun-exposed skin from SLE patients these deposits are also seen (lupus band test).

Complications/Course

- **Pure cutaneous disease** usually has a chronic fluctuating course with lesions culminating in hypopigmentation and scarring, especially when discoid.
- **Systemic disease** takes a very variable course, ranging from mild disease to life-threatening disease, especially with renal, cardiac or central nervous system involvement. Anti-dsDNA antibodies predict nephritis and hemolytic anemia. A poor prognosis, with a 50% of mortality in 10 years, is associated, at the time of the diagnosis, with high serum creatinine levels, hypertension, nephrotic syndrome, anemia, hypoalbuminemia, hypocomplementemia, antiphospholipid antibodies, male gender, ethnicity (African-American, Hispanic with mestizo heritage), and low socio-economic status.

Disability in patients with SLE is caused by chronic fatigue, arthritis, pain and renal disease.

The most common causes of death in patients with SLE include end organ involvement (renal, cardiac, central nervous system), infections (predisposed by the prolonged use of immune suppressive agents), and arterial thromboses.

Diagnosis

- The diagnosis of SLE is based on characteristic clinical features and serum markers.

The clinical criteria include the typical skin lesions (acute cutaneous lupus, chronic cutaneous lupus), oral or nasal ulcers, synovitis, serositis, proteinuria or red blood cell casts, neurologic manifestations, haemolytic anemia, leukopenia or lymphopenia, and thrombocytopenia.

The immunological criteria include the presence of antinuclear (ANA), anti- double strand DNA (dsDNA), anti-Smith (anti-Sm), and antiphospholipid antibodies, as well as hypocomplementemia, and direct Coombs test.

- Diagnosis of **cutaneous LE** is based on **clinical features**, on the **immune serology** (autoantibody profile) and requires skin biopsy for **histological examination**.

Differential Diagnosis

A key characteristic of **cutaneous LE** is the localization on sun exposed areas. Differential diagnoses of **CDLE** include

- psoriasis,
- tinea,
- skin cancer,

- granuloma faciale and sarcoidosis,
- lupus vulgaris,
- cutaneous leishmaniasis and leprosy.

Verrucous/hypertrophic discoid lupus may be confused with hypertrophic lichen planus, keratoacanthoma, squamous cell cancer, and prurigo nodularis.

SCLE enters in differential diagnosis with plaque psoriasis, tinea corporis, nummular eczema, dermatomyositis, cutaneous T-cell lymphoma, drug eruptions and other photodermatoses.

The butterfly rash of **ACLE** must be differentiated from other more common photosensitive rashes such as polymorphous light eruption, dermatomyositis and rosacea. Other causes of facial erythema include seborrheic dermatitis, contact dermatitis, erysipelas and flushing (idiopathic or associated with carcinoid syndrome, pheochromocytoma, or mastocytosis).

SLE may enter in differential diagnosis with many disorders depending on pattern of systemic involvement, including rheumatoid arthritis, dermatomyositis or mixed connective tissue diseases.

Prevention & Therapy

Treatment of LE is aimed at control of signs and symptoms. **Photoprotection** is very important in every form of LE.

- Treatment of **CDLE** and **SCLE** is based on antimalarials (hydroxychloroquine, chloroquine) combined with topical or intralesional or low-dose systemic corticosteroids. Topical therapy may be effective alone only in localized lesions. Occlusion may help further with the use of topical corticosteroids and topical calcineurin inhibitors, such as topical tacrolimus. Disseminated forms may require systemic immunosuppressants such as methotrexate or azathioprine. Anifrolumab, a monoclonal antibody targeting the type I interferon (IFN) receptor, has recently been approved for the treatment of patients with moderate to severe SLE, showing an apparent positive response in skin involvement.
- **SLE** requires high dose systemic corticosteroids and a multidisciplinary management may be important, adjusted to organ involvement. Antimalarials, immunosuppressive agents such as azathioprine and cyclophosphamide, as well as biologics such as anifrolumab, belimumab and ustekinumab (off label) are used.

References

- [Kiriakidou M, Ching CL. \(2020\). Systemic lupus erythematosus. Ann Intern Med. Jun 2; 172\(11\):ITC81-ITC96. .doi:10.7326/AITC202006020. PMID: 32479157.](#)

- [Aringer M, Petri M. \(2020\). New classification criteria for systemic lupus erythematosus. Curr Opin Rheumatol. Nov;32\(6\):590-596. doi: 10.1097/BOR.0000000000000740. PMID: 32925250; PMCID: PMC8020886.](#)
- [Fanouriakis A, Kostopoulou M, Andersen J, et al. \(2024\). EULAR recommendations for the management of systemic lupus erythematosus: 2023 update. Ann Rheum Dis. Jan; 83\(1\):15-29. doi: 10.1136/ard-2023-224762. PMID: 37827694.](#)

1.2.2 Systemic scleroderma (SSc)

Grading & Level of importance: C



G. Girolomoni, Verona; P. Gisondi, Verona; M. Maurelli, Verona; F. Rongioletti, Milan

ICD-11

4A42.1

Synonym

Diffuse systemic sclerosis.

Definition

Systemic scleroderma, also called systemic sclerosis (SSc), is an autoimmune, chronic and progressive multisystemic disease leading to aberrant deposition of collagen and extracellular matrix involving the skin, vessels and internal organs (lung, heart, gastrointestinal tract, kidney).

Epidemiology

Incidence varies between 0.1-4.3/100000; F:M = 4:1, the onset is typically from 35 to 50 years old.

Aetiology & Pathogenesis

SSc is a multifactorial disease, characterized by an immunogenetic predisposition (HLA association), an alteration of the vascular regulation, humoral and cellular immune activation with antibody production, and of tissue sclerosis with altered collagen and extracellular matrix proteins synthesis and deposition.

Early events in vascular dysregulation include impaired angiogenesis and endothelial cell injury with perivascular leak and edema. Activation of endothelial cells leads to an increased expression of adhesion molecules and binding of circulating inflammatory cells, with an elevation of vascular endothelial growth

factor and the receptors. Impairment of perivascular smooth muscle cells with dysregulation in vasoconstriction and vasodilatation. The result of this process is an intimal proliferation that conducts to a luminal occlusion, hypoxia and an augmented synthesis of profibrotic cytokines, fibroblast activation, and collagen production. Sclerosis is the final process in the tissue damage. The clinical presentation includes Raynaud's phenomenon and digital ulcers, caused by a reversible vasospasm and an irreversible arterial damage secondary to intimal proliferation and luminal obstruction. The immune dysregulation involves some specific autoantibodies (anti-centromere, anti-topoisomerase I, and anti-RNA polymerase III), which bind tissues involved in SSc. Lymphocytic infiltrates are composed of T and B cells. Oligoclonal T-cell expansion has been seen in lesional skin, indicating an antigen-driven response, and T-cells demonstrate a Th2 predominance with an augmented production of IL-4 and IL-13. Th17 and IL-17 are also implicated in the immune response and interferons type I and II have been observed in blood and skin. Extracellular matrix dysregulation has also been observed in SSc, in particular, sclerosis is the final process in the tissue damage. An excessive deposition of collagen, proteoglycans, fibronectin, fibrillins and adhesion molecules are the players of this process. Transforming growth factors β (TGF- β) and connective tissue growth factor are also involved, in particular TGF- β is responsible for maintenance of collagen synthesis.

Clinical presentation

- Patients with SSc can be grouped into diffuse and limited cutaneous subsets defined by the pattern of skin involvement, as well as clinical and laboratory features. SSc is considered diffuse when skin sclerosis involves the distal and proximal portions of the extremities, the trunk and the face; limited when involves the distal extremities and the face. Of the cutaneous manifestations, Raynaud's syndrome is very often the presenting feature.
- Skin changes in the hands include sclerodactyly, painful fingertip ulcers, fingers initially puffy, later atrophic with distal thinning (Madonna fingers); at the face: microstomia, perioral radial folds (purse string mouth) and telangiectasia.
- Gastrointestinal tract involvement manifests predominantly with esophageal symptoms (disturbed swallowing) and less commonly with constipation or diarrhea.
- Lung involvement is also common with pulmonary fibrosis, interstitial lung disease, and pulmonary artery hypertension.
- Kidney disease manifests with proteinuria, haematuria, and renal crisis due to nephrosclerosis.
- Heart disease with myocardial fibrosis and right heart failure secondary to pulmonary artery hypertension.
- Liver may be involved with primary biliary cirrhosis. Joint signs include arthralgias or less commonly arthritis.
- Bones may manifest osteolysis as well osteomyelitis possibly due to digital ulcerations.
- Myositis with muscle weakness.

1. Limited SSc, with a frequency of about 50%. This form is more indolent. Raynaud's phenomenon precedes skin changes by years and is present in 99% of cases. This form is a limited cutaneous sclerosis localized at the distal knees and elbows, and face. Many years after disease onset, patients can develop esophageal disease (90%), cutaneous telangiectasia, interstitial lung disease (35%) and pulmonary artery hypertension (15%). Anti-centromere antibodies are usually positive.
2. Diffuse SSc, with a frequency of about 35%. In 98% of cases, Raynaud's phenomenon usually appears shortly, weeks to months, and before the skin lesions. Diffuse cutaneous sclerosis starts on the trunk and spreads centrifugally. Soft tissue swelling, puffy fingers, and intense pruritus are signs of the early inflammatory 'edematous' phase. The fingers, distal limbs, and face are usually initially involved. Diffuse hyperpigmentation of the skin, carpal tunnel syndrome, arthralgias, muscle weakness, fatigue, and decreased joint mobility are common. During the ensuing weeks to months, the inflammatory edematous phase evolves into the 'fibrotic' phase, with skin induration, and decline in sweating capacity. Possible involvement of the gastrointestinal tract (80%), kidneys, and lungs with interstitial lung disease (65%), pulmonary fibrosis and pulmonary artery hypertension (15%). Anti Scl-70 antibodies usually positive.
3. Overlap syndrome, with a frequency of 10%. Patients simultaneously show typical signs of SSc and other rheumatologic diseases.
4. CREST syndrome: multisystem connective tissue disorder characterized by five main features: calcinosis, Raynaud's phenomenon, esophageal dysmotility, sclerodactyly and telangiectases. Patients with CREST syndrome may develop visceral complications, including PHA, pulmonary fibrosis and mid-gut disease.
5. Others forms are undifferentiated forms. SSc sine scleroderma may also occur.

Laboratory & other workups

Characteristic of SSc is the presence in the serum of auto-antibodies. These include anti-nuclear antibodies (ANA) with the nucleolar or speckled patterns, that are positive in 90-95% of cases.

- The anti-centromere antibodies are present in the limited SSc type, with a discrete speckled pattern (20-38%).
- Among the extractable nuclear antibodies (ENA), the anti-topoisomerase I antibodies (Scl70) in the diffuse type, with speckled pattern (15-42%). The anti-RNA polymerase III antibodies are present in the rapidly progressive, diffuse skin disease (5-31%), and are associated with renal involvement. The U3-RNP (fibrillarin) with a nucleolar pattern, are present in 4-10% of the diffuse form.

The Th/T0 and the U1-RNP with a speckled pattern in the localized form (4-10%). The anti-PM/Scl with a nucleolar pattern in the localized and overlap form (4-11%). The Ku and U11/U12 RNP antibodies with a speckled pattern with a positivity of less than 4%.

Dermatopathology

The early lesions are characterized by a dense superficial and deep perivascular and periadnexal lymphocytic infiltrate with plasma cells.

The late lesions show an increased collagen (sclerosis), generally in the absence of or with limited. Systemic scleroderma is histologically indistinguishable from morphea.

inflammation, with loss of adnexal structures (alopecia, decreased sweating). Indurated lesions are histologically characterized by an augmented deposition of collagen, atrophic eccrine and pilosebaceous glands, loss of subcutaneous fat, and a sparse dermal lymphocytic infiltrate. The adnexal glands are atrophic, trapped by the deposition of collagen.

Direct immunofluorescence is usually negative.

Complications

SSc has a chronic and progressive evolution. Patient with a diffuse form tend to have a more rapidly progressive course and worse prognosis than those with the localized form. In patients with diffuse SSc, 5- and 10-year survival rates are 70% and 55%, respectively, whereas in patients with the localized form, survival rates are 90% and 75%, respectively. The prognosis correlates with the extent of skin involvement, which itself is a surrogate for visceral organ involvement.

The complications are joint contractures, trophic ulcers, esophageal stenosis, Barrett esophagus, pulmonary fibrosis with pulmonary hypertension, renal failure with renal hypertension and renal crisis, cardiac failure, cardiac rhythm disorders and right heart overload. Major causes of death are pulmonary arterial hypertension, pulmonary fibrosis, gastrointestinal and cardiac disease, and scleroderma renal crisis.

Diagnosis

The diagnosis is based on the clinical features, the histology, and on the immune serology.

- The provocation testing for Raynaud's phenomenon consists in the immersion of the hands in ice water and measuring skin temperature normalization.
- Nail fold capillary microscopy is useful to document characteristic capillary abnormalities. In early stages shows ectasia of capillaries; in active stages, mega-capillaries and haemorrhages, whereas a reduced density and tufting of capillaries are observed in later stages.
- In the case of pulmonary involvement, it is important to perform pulmonary function tests, high-resolution CT scan, electrocardiography, echocardiogram, and a 6-minute walking test to assess right heart overload.

- In the case of gastrointestinal problems, a scintigraphy or high-resolution manometry of esophagus and pH testing, a gastroscopy for the diagnosis of dysphagia and reflux esophagitis should be performed.
- In the case of renal involvement, blood pressure monitoring, renal function tests, 24-hour urine collection analysis, kidney ultrasound; kidney biopsy is performed in selected cases.
- In the case of musculoskeletal symptoms, creatinine kinase (CK) and myositis-specific antibodies measurement, electromyography (EMG), magnetic resonance imaging (MRI), and in some cases a muscle biopsy may be necessary (overlap with dermatomyositis).
- Joint evaluation may rely on x-ray and ultrasounds, and is important to exclude overlapping with rheumatoid arthritis (rheumatoid factor, anti-citrullinated protein antibodies).

Differential Diagnosis

Differential diagnosis should be established with sclerodermoid disorders, particularly mucinoses such as scleredema and scleromyxedema. A full-thickness biopsy of the skin is required for establishing the differential diagnosis. Other disorders to be considered include eosinophilic fasciitis, chronic graft-vs-host-disease, generalized morphea, fibroblastic rheumatism, and overlap syndromes. Toxin-mediated sclerodermoid disease which may enter in differential diagnosis with SSc include nephrogenic systemic fibrosis, eosinophilia-myalgia syndrome, toxic oil syndrome, and silicosis. Drug-induced sclerosis has been associated with exposure to bleomycin, pentazocine, or L-tryptophan. Some genetic skin disorders may also present with SSc-like features including Werner syndrome, restrictive dermopathy, Hutchinson-Gilford progeria, Stiff skin syndrome, phenylketonuria, Weill-Marchesani syndrome, multicentric osteolysis-nodulosis-arthropathy, primary hypertrophic osteoarthropathy, ataxia-teleangiectasia, Huriez syndrome and H syndrome.

Prevention & Therapy

Therapy in SSc is focused to treat the organ involvement and may require a multidisciplinary approach. Multiple interventions are highly effective to minimize symptoms and to slow the progression on organ damage.

Treatment is primarily supportive, and based on protection from cold, physical therapy (to retain motility and circulation), skin protection and care.

When progressive and inflammatory, the treatment is based also on systemic immunosuppression. Glucocorticoids alleviate stiffness and aching in early inflammatory-stages, but their use is associated with an increased risk of scleroderma renal crisis. Cyclophosphamide reduces the progression of SSc associated with lung disease, with stabilization and, rarely, modest improvement of pulmonary function, high resolution computed tomography (HRCT) findings, respiratory symptoms, and skin induration. Methotrexate is useful for the skin involvement. Mycophenolate mofetil for the skin and lung

involvement. Tocilizumab (monoclonal antibody directed against the IL-6 receptor that blocks IL-6 signaling, rituximab (monoclonal antibody directed against the mature B cell marker CD20), abatacept (fusion protein that inhibits T-cell co-stimulation and function) and intravenous immunoglobulin are used in selected cases.

There is no effective anti-fibrotic treatment. Pirfenidone and nintedanib are used in patients with idiopathic pulmonary fibrosis.

Calcium antagonist (amlodipine, nifedipine and diltiazem), angiotensin II receptor blockers (losartan), α 1-adrenergic receptor blockers (prazosin), 5-phosphodiesterase inhibitors (sildenafil), topical nitroglycerine, and intermittent IV infusions of prostaglandins are useful for Raynaud's phenomenon, to control episodes, and prevent and enhance the healing of ischemic complications, and slow the progression of obliterative vasculopathy. Patients with Raynaud's phenomenon unresponsive to these therapies may require the addition of low-dose aspirin and dipyridamole to reduce platelet aggregation. In patients with ischemic digital tip ulcerations, the endothelin-1 receptor antagonist bosentan reduces the risk of new ulcers. Long-term therapy with statins and antioxidants may retard the progression of vascular damage and obliteration. Pulmonary arterial hypertension benefits from bosentan and sildenafil.

There is limited evidence-based information for the treatment of cardiac complications of SSc, which should be guided by specialists experienced in their diagnosis and management. While selective beta blockers such as metoprolol can precipitate vasospasm, non-dihydropyridine calcium channel blockers can be used for rate control in atrial arrhythmias, and non-selective alpha/beta blockers such as carvedilol for improving myocardial perfusion and left ventricular systolic function.

Monitoring: all patients require screening at routine intervals for the possibility of major organ involvement including interstitial lung disease, pulmonary hypertension, cardiac and kidney complications.

References

- [Knobler R., Moinzadeh P., Hunzelmann N., et al. \(2017\). European Dermatology Forum S1-guideline on the diagnosis and treatment of sclerosing diseases of the skin, Part 1: localized scleroderma, systemic sclerosis and overlap syndromes. J EADV Sep; 31\(9\):1401-1424. doi: 10.1111/jdv.14458. Epub 2017 Aug 9. PMID: 28792092.](#)
- [Jerjen R, Nikpour M, Krieg T, Denton CP, Saracino AM. \(2022\). Systemic sclerosis in adults. Part I: Clinical features and pathogenesis. J Am Acad Dermatol .Nov;87\(5\):937-954. doi:10.1016/j.jaad.2021.10.065. Epub 2022 Feb 4. PMID: 35131402.](#)

- [Jerjen R, Nikpour M, Krieg T, Denton CP, Saracino AM. \(2022\). Systemic sclerosis in adults. Part II: management and therapeutics. J Am Acad Dermatol. Nov;87\(5\):957-978. doi: 10.1016/j.jaad.2021.10.066. Epub 2022 Feb 4. PMID: 35131401.](#)

1.2.3 Localized Scleroderma

Grading & Level of importance: C



G. Girolomoni, Verona; P. Gisondi, Verona; L. Martos-Cabrera, Madrid; M. Maurelli, Verona

ICD-11

EB61.0

Synonym

Morphea; circumscribed scleroderma.

Definition

Localized inflammatory connective tissue disease of the skin and subcutaneous fat that leads to a scar-like sclerosis.

Epidemiology

Localized scleroderma is most common between 20-40 years, with a prevalence of 500 and 2200 per million at ages of 18 and 80 years. The F:M = 2.6:1.

Aetiology & Pathogenesis

Localized scleroderma is an idiopathic, inflammatory disorder that causes sclerotic changes in the skin. Although the etiopathogenesis of localized scleroderma is not fully understood, it is characterized by vascular damage, infiltration of activated T-cells, and by an altered production of connective tissue produced by fibroblasts. Vascular changes are characterized by a reduction of the number of capillaries and hypoxia caused by microvascular injury, and by the endothelial cell activation. T-cells, which are present in the perivascular sites, have the capacity to modify collagen synthesis by fibroblasts, so they contribute to develop sclerosis. Th2 cytokines such as IL-4 and IL-13 directly enhance TGF- β production, and this in turn enhances the production of the pathologic collagen by fibroblasts and induces the recruitment of eosinophils.

Triggering factors include mechanical trauma (including injections), infections (*Borrelia burgdoferi*),

drugs and irradiation by X-rays.

Clinical presentation

Localized scleroderma can be distinguished into subgroups: plaque-type morphea, linear morphea, generalized morphea, and the less common variants that include the deep, the guttate and the nodular forms.

- The plaque-type morphea is the most prevalent form, and is characterized by slightly edematous, erythematous plaques with a centrifugal expansion (lilac ring), usually localized asymmetrically at the trunk, 2-15 cm of diameter. The lesions can be solitary or multiple, are usually asymptomatic, but in some cases are itchy, usually in the case of sclerosis. At the early stages, the central area of the lesions takes a shiny white colour and shows a sclerotic and scar-like tissue appearance, becoming progressively indurated. The lilac ring is a sign of disease activity. A white sclerosis with a post-inflammatory brown hyperpigmentation characterizes the late lesions. The adnexal structures, such as hairs follicle and sweat glands are usually absent.
- Linear scleroderma is typically the 'en coup de sabre' form, with a longitudinal scar-like whitish band localized on the forehead and the frontal scalp. It usually starts either as a linear streak, which may at the early stages mimic a port-wine stain, or as a row of small plaques that tend to coalesce. It may begin as plaque-morphea but extends longitudinally and may involve the scalp (cicatricial alopecia), eyebrows, nose, and cheeks. Sclerosis is associated with a progressive loss of subcutaneous fat. The less frequent forms are hemifacial atrophy, called Parry-Romberg syndrome, which is a severe variant of linear morphea with involvement of subcutaneous fat and the underlying bone giving rise to facial disfiguration. The entire distribution at the trigeminal nerve can be affected. Linear morphea may also affect the extremities (arms or legs) presenting as linear sclerotic band with hyper- and hypo-pigmentation. This form tends to involve the underlying fascia, muscles, and tendons, and may be associated with hypoplasia and impaired mobility of the affected joints, and muscle weakness.
- The generalized forms of localized scleroderma include: generalized circumscribed scleroderma, disabling pansclerotic morphea, and the eosinophilic fasciitis. These forms are characterized by involvement of the trunk at the early stages, but the distinctive feature is that this form does not stop his expansion. Usually, the plaques tend to coalesce rapidly, resulting in a disabling thoracic constriction and inflammation of intercostal muscle with breathing difficulty.
- The variants include guttate morphea that presents as multiple, rather superficial, and nummular plaques. Usually, they are small and become deeply sclerotic. The atrophoderma of Pasini and Pierini is considered as a very superficial variant of plaque-type morphea and is also considered a separate entity in the differential diagnosis of 'burnt-out' morphea. The hyperpigmented patches are usually present at the posterior trunk, and occasionally they follow the lines of Blaschko. Deep morphea is characterized by a small number of hard and deep plaques with inflammation and sclerosis that involves primarily the deep dermis and subcutaneous fat, and sometimes the underlying structures. These plaques may impair the motility of the skin and tend to calcify,

leading to dystrophic calcinosis cutis. The nodular/keloidal morphea is characterized by inflammation within the dermis that leads to thick, keloid-like nodules or bands. Clinically is very similar to keloids. Bullous morphea is a form that usually develops latter with the presence of bullae. Generalized morphea and sclerodermoid/morpheiform GVHD are characterized by sclerosis of the skin with diffuse edema and stasis of lymphatic fluid. Morphea (in particular the guttate type) may coexist with lichen sclerosus et atrophicus.

Laboratory & other workups

In localized scleroderma, eosinophilia can occur, especially at early phases. High titers of antinuclear antibodies (ANA) or anti-single strand DNA (ssDNA) and anti-histone antibodies (AHA) are present in 40-80% of patients with linear and generalized morphea. Borrelia burgdoferi test can be performed in the case of the suspected infection.

Dermatopathology

The histopathology of localized scleroderma is identical to progressive systemic sclerosis. For a correct diagnosis, the specimen for biopsy must include the subcutaneous fat. At the inflammatory border, the vessel walls show edema and endothelial swelling. The capillaries and the small arterioles are surrounded by an infiltrate rich of CD4+ T-cells and sparse eosinophils, plasma cells and mast cells. At the later stages, the inflammatory infiltrate usually wanes or disappears, except in some areas of subcutaneous fat. The epidermis can show interface dermatitis in early phases, with flattening of the rete ridges in later phases. The capillaries and the small vessels are reduced in number. In the sclerotic phase collagen bundles are packed, with a hyalinised subcutis. In deep morphea, there is sclerosis of the underlying fascia.

Complications

The course of localized scleroderma is characterized by a progression in 3-5 years, with a subsequent arrest. Atrophy and the depigmentation persist. Linear scleroderma and chronic hemifacial atrophy may be associated with significant impairment. The complications depend on the localization (face and overlying joints) and degree (panmorphea). Generally, there is no systemic involvement. In patients with linear type 'en coup de sabre' or Parry-Romberg syndrome, cranial magnetic resonance imaging (MRI) and high-resolution CT scan should be performed to evaluate deep tissue involvement.

Diagnosis

The diagnosis is based on the clinical features and the histology.

Differential Diagnosis

The most important differential diagnoses are the other morpheiform and sclerodermoid conditions and systemic sclerosis. Other differential diagnoses are lichen sclerosus et atrophicus (which may coexist with morphea) keloids, dermatosclerosis (with severe chronic venous insufficiency). Also, Dupuytren and campodactyly (a benign ulnar deviation of the fourth and the fifth finger). Acrodermatitis chronica atrophicans can also be included within the differential diagnosis.

Prevention & Therapy

Treatment of localized scleroderma can be divided in topical, phototherapy, intralesional corticosteroids, systemic therapy, and physical therapy.

- Topical therapy is based on corticosteroids, usually of high potency, such as clobetasol propionate, and they are useful for reducing inflammation in the active and superficial lesions, and to prevent the progression. A useful alternative to topical corticosteroids is the intralesional injection of corticosteroids. Calcineurin inhibitors (pimecrolimus and tacrolimus) are also employed. In some cases, vitamin D derivatives, such as calcipotriol, and vitamin A derivatives are used.
- PUVA therapy or UVA1 phototherapy are successfully employed in localized scleroderma and may block its progression.
- Systemic therapies are based on immunosuppressive agents and hydroxychloroquine. Methotrexate is the most helpful immunosuppressive agent in the treatment of all forms of localized scleroderma. Sometimes, a combination therapy with methotrexate and pulse corticosteroids led to a marked improvement of lesions. Oral corticosteroids alone (methylprednisolone and prednisone) are helpful in the treatment of the inflammatory phases.
- Physiotherapy and lymphatic drainage are useful in cases of limb involvement associated with mobility impairment.

References

- [Snarskaya ES, Vasileva KD. \(2022\). Localized scleroderma: actual insights and new biomarkers. Int J Dermatol. Jun; 61\(6\):667-674. doi: 10.1111/ijd.15811. Epub 2021 Aug 4. PMID: 34347884.](#)
- [Zhao M, Wu J, Wu H, Sawalha AH, Lu Q. \(2022\). Clinical treatment options in scleroderma: recommendations and comprehensive review. Clin Rev Allergy Immunol. Apr;62\(2\):273-291. doi: 10.1007/s12016-020-08831-4. Epub 2021 Jan 15. PMID: 33449302.](#)
- [Papara C, De Luca DA, Bieber K, Vorobyev A, Ludwig RJ. \(2023\). Morphea: The 2023 update. Front Med \(Lausanne\). Feb;10:1108623. doi: 10.3389/fmed.2023.1108623. PMID: 36860340; PMCID: PMC9969991](#)

1.2.4 Dermatomyositis



Grading & Level of importance: C

G. Girolomoni, Verona; P. Gisondi, Verona; L. Martos-Cabrera, Madrid; M. Maurelli, Verona

ICD-11

4A41.0

Synonyms

None.

Definition

Dermatomyositis (DM) is a systemic inflammatory autoimmune disease classified among the idiopathic inflammatory myopathies. Dermatomyositis involves the skin with a characteristic eruption on the sun exposed areas, and muscles with a symmetric, proximal, extensor myopathy.

Epidemiology

The incidence of dermatomyositis ranges from 2-9 per million with a F:M = 3:1. It is characterized by a bimodal age distribution, with two peaks of incidence in <10 years and from 30 to 60 years.

Aetiology & Pathogenesis

DM is an autoimmune disease, resulting from of an immune-mediated process triggered by outside factors (malignancy, drugs, infections) in genetically predisposed individuals (HLA class II). In adults, 15% are paraneoplastic, particularly genitourinary, ovarian and colon cancers. DM, with either or both cutaneous and muscle involvement, has been associated with drugs, including statins, fenofibrates and IFN- α . The pathogenesis of DM, like other idiopathic inflammatory myopathies, involves both the innate and the adaptive immune systems, and it is attributed to an antibody-mediated attack on endothelial cells, followed by complement-mediated destruction of capillaries and watershed ischemia of muscle fibers. Skin and muscle damage are due to toxicity from type I IFN-mediated pathways, in particular IFN- β . SARS-CoV-2 infection and vaccination may lead to new-onset dermatomyositis via autoimmunity due to interferon signaling, hyperinflammation and autoantibody induction.

Clinical presentation

DM manifests with characteristics cutaneous signs (violaceous heliotrope rash with periorbital edema),

and pathognomonic signs (Gottron's sign and papules), typical periungual telangiectasias, as well as muscle weakness and pain mostly at the proximal muscle groups (hips, shoulders). The heliotrope rash is characterized by a pink-violet/purple-red macular erythema mainly of the upper eyelids and periorbital skin, sometimes associated with scaling, and periorbital edema. Erythema on the cheeks, nasolabial folds and nose in a 'butterfly' distribution is similar to the malar eruption seen in lupus erythematosus, but it may wax and wane in intensity. In addition, the upper anterior chest, posterior neck and scalp are usually affected. Erythema and scaling may be particularly prominent over the extensor surfaces, including elbows, knees, and dorsal interphalangeal and metacarpophalangeal joints, and both the proximal and distal interphalangeal joints (Gottron's sign). Approximately one-third of patients have violaceous, flat-topped papules over the knuckles that develop a secondary lichenoid quality, known as Gottron's papules, which are pathognomonic of dermatomyositis. The cutaneous lesions of dermatomyositis may be intensely pruritic. Periungual telangiectasias and edema may be prominent and similar to those of systemic lupus erythematosus. Additional cutaneous manifestations are the scaling of the scalp, often associated with non-scarring alopecia and centripetal flagellate erythema. Patients with long-standing disease develop characteristic skin areas of hypopigmentation, hyperpigmentation, mild atrophy and telangiectasia known as poikiloderma. Poikiloderma is rare in both lupus erythematosus and scleroderma and thus can serve as a clinical sign that distinguishes dermatomyositis from these two diseases. Photodistributed poikiloderma is very characteristic of dermatomyositis and is often localized on the upper chest (V-neck sign) and upper back (shawl sign). Cutaneous changes may be similar in dermatomyositis and various overlap syndromes where sclerodactyly as well as Raynaud's phenomenon can be seen (overlap with progressive systemic sclerosis).

Calcinosis cutis is more prevalent in juvenile dermatomyositis, affecting 25-70% of pediatric patients. In childhood dermatomyositis, vasculitic changes with ulcerations are also frequent.

The so-called "mechanic hands" are characterized by thickening, hyperkeratosis and cracking on the lateral and palmar surfaces of the fingers and thumbs have been observed in patients with DM. Initially associated with interstitial lung disease, arthritis, Raynaud's phenomenon and the presence of circulating anti-synthetase antibodies (anti-synthetase syndrome). However, these lesions are currently considered to be a non-specific skin marker of myositis.

Myopathy manifests most commonly with muscle weakness and pain mostly at the proximal muscle groups (hips, shoulders). The patients typically complain from progressive and increasingly difficulties to climbing stairs and standing from sitting, and lifting. Some patients have only skin disease (no muscle involvement after 2 years from the onset of cutaneous symptoms), called dermatomyositis sine myositis or amyopathic dermatomyositis, and others develop hypomyopathic dermatomyositis. Cutaneous signs of DM may precede or follow the development of myositis.

Other organ involvement includes dysphagia and gastroesophageal reflux disease. In the overlap with systemic sclerosis, pulmonary disease may be manifested as diffuse interstitial fibrosis, with dry cough and dyspnoea. Cardiac disease is usually asymptomatic, but in few cases may be manifested with arrhythmias and conduction defects. Adult patients with DM, have a mean range risk of malignancy of 15-25%. Most cases associated with malignancy are due to genitourinary, ovarian and colon cancers. Other associated cancers include breast, lung, stomach and pancreas malignancies or lymphomas. Malignancies may be pre-existing or can develop in the years after diagnosis. The association between dermatomyositis and cancer occurs only with the adult form, both classic and amyopathic, but not in the juvenile form.

Laboratory & other workups

Erythrocyte sedimentation rate and muscle enzymes, especially creatine kinase (CK), are elevated. Serum CK levels are elevated in 70-80% of patients; in 10% of those with normal CK, serum aldolase may be increased.

Anti-nuclear antibodies (ANA) can be positive but are a non-specific finding. In some cases, the anti-nuclear antibody test may be negative. Anti-extractable nuclear antigen antibodies (ENA) may indicate a severe course with pulmonary fibrosis. DM is associated with several myositis-specific antibodies. They include anti-aminoacyl-tRNA synthetase (anti-synthetase) antibodies (>20%): Anti-Jo-1, anti-PL-12, anti-PL 7, etc. and a heterogeneous group of antibodies: anti-SRP (5%), anti-Mi2 (15%), anti-TIF-1 γ (20- 40% in the classic form and in cases associated with malignancy), anti-NXP-2 (10-20%), anti-SAE (5%), anti-MDA5 (5-20%). The anti-Jo antibody is usually detected in patients with polymyositis (without skin lesions) and has been associated with a severe course and lung involvement. The titers of anti-Jo-, as well as those of anti-MDA5 and anti-SRP have been related to disease activity. MDA5 antibody has been associated with lung interstitial disease, skin ulcers, palmar papules and mechanic's hands. Patients with anti-synthetase antibodies often have overlap syndromes with scleroderma.

Electromyography (EMG) shows polyphasic potentials. EMG of weak muscles shows increased insertional and spontaneous activity in the form of positive sharp waves and fibrillation potentials, or complex repetitive discharges along with early recruitment of small amplitude, short duration, polyphasic motor units. These findings are non-specific and can be seen in other myopathies. Skeletal muscle magnetic resonance imaging (MRI) can detect muscle necrosis, degeneration, and inflammation, and is characterized by increased signal intensity on short-tau inversion recovery, and sometimes more specific findings of abnormalities of fascia suggesting fasciitis. MRI and ultrasound of muscles may be sensitive enough to avoid muscle biopsy, or can be used to identify the correct site where to perform a muscle biopsy.

The role of emerging imaging techniques like optical coherence tomography (OCT) and magnetic

resonance imaging (MRI) is being investigated to aid in accurately assessing of inflammation and muscle damage.

Dermatopathology

Skin biopsy of the erythematous, scaling lesions of DM may reveal cell-poor interface dermatitis with a scanty mononuclear cell infiltrate, similar to lupus erythematosus. Epidermal atrophy, hydropic degeneration of basal keratinocytes, and dermal changes consisting of edema of the upper dermis, and interstitial mucin deposition are present. Direct immunofluorescence microscopy of lesional skin is usually negative, although granular deposits of immunoglobulins and complement in the epidermal basement membrane zone have been described in some patients. The histopathology of muscle biopsy in DM is characterized by muscle fibre degeneration and necrosis with lymphocytic infiltrates and obliterative vasculopathy. The characteristic abnormality is perifascicular atrophy, but it is present in only 50% of patients.

Complications

The course of DM is chronic. Spontaneous remission may occur in cases drug-induced or when an associated malignant tumour is successfully treated. In the absence of malignancy, prognosis is generally favourable, with 5-year survival rates ranging from 70-93%. Poor prognostic features are increased age, associated interstitial lung disease, cardiac disease, and late or previous inadequate treatment. The complications are respiratory failure, progressive loss of muscle function, renal impairment secondary to muscle damage, calcinosis (in children), and vasculitis.

Diagnosis

The diagnosis is made on the clinical features. Laboratory investigations are aimed to document muscle damage and the autoimmune status. Adults should be evaluated for malignancy at diagnosis, followed by long-term surveillance.

Differential Diagnosis

Lupus erythematosus, mixed connective tissue disease (Sharp syndrome) and progressive systemic sclerosis may enter in differential diagnosis for the heliotrope rash or should be considered in case of overlap syndrome and/or lupus erythematosus. Gottron's papules can be easily misdiagnosed with psoriasis and eyelid erythema and edema with eczema. Phototoxic and photoallergic eruptions for the photodistribution. Cutaneous T-cell lymphoma for the poikiloderma. Myopathy needs differential diagnosis with polymyositis, other inflammatory myopathies, muscular dystrophy, motor neuron disease, congenital myopathy, metabolic myopathy, mitochondrial myopathy, myasthenia gravis, myotonic dystrophy, and inclusion body myositis.

Prevention & Therapy

Treatment should be directed at the systemic disease, with the use of systemic corticosteroids (prednisone 1 mg/kg/day); in the case of resistant disease, it is indicated to start intravenous pulse corticosteroids plus a low-dose of methotrexate or azathioprine. High-dose intravenous immunoglobulins are effectively used in cases where previous treatments are inappropriate. Immunosuppressant agents, such as cyclosporin A, mycophenolate mofetil and cyclophosphamide are considered in resistant cases. The ongoing research includes exploration of targeted therapies, like interferon pathway inhibitors, which aim to reduce inflammation and symptoms, as well as investigation into biological therapies, such as rituximab targeting B cells, in order to decrease disease activity. Topical glucocorticoids are sometimes useful. Patients should avoid exposure to ultraviolet irradiation and aggressively use photoprotective measures, including broad-spectrum sunscreens.

References

- [O'Connell KA, LaChance AH. \(2021\). Dermatomyositis. N Engl J Med. Jun 24;384\(25\):2437. doi:10.1056/NEJMicm2033425. PMID: 34161709.](#)
- [Tanboon J, Nishino I. \(2022\). Update on dermatomyositis. Curr Opin Neurol. Oct 1;35\(5\):611-621. doi: 10.1097/WCO.0000000000001091. Epub 2022 Aug 4. PMID: 35942671](#)
- [Cobos GA, Femia A, Vleugels RA. \(2020\). Dermatomyositis: An Update on Diagnosis and Treatment. Am J Clin Dermatol. ;Jun;21\(3\):339-353.doi:10.1007/s40257-020-00502-6. PMID: 32096127.](#)

1.2.5 Pemphigus

Grading & Level of importance: C

G. Girolomoni, Verona; P. Gisondi, Verona; M. Maurelli, Verona



ICD-11

EB40.0

Synonyms

None.

Definition

Autoimmune disease with intra-epidermal blister formation.

Epidemiology

F = M: 30-60 years. Incidence of 2-7 new cases per million per year. Ethnic variation with much higher incidence in Ashkenazi Jewish patients.

Aetiology & Pathogenesis

Loss of cell adhesions between keratinocytes (acantholysis) and subsequent blister formation through impairment of desmosome function, by circulating autoantibodies against desmosomal proteins (desmogleins 1 and 3).

Signs & Symptoms

- Pemphigus vulgaris: onset with oral painful erosions in more than 50% of cases, later superficial, fragile and flaccid blisters with rapid transition to crusted erosions. The lesions usually develop in non-inflamed skin. Nikolski's signs positive (Nikolski I: blisters induced by rubbing normal skin. Nikolski II: existing blisters extend with lateral pressure). Mucosal lesions clinically are painful erosions of different sized characterized by an irregular and ill-defined border, localized in the oral cavity, especially at the buccal and palatine mucosa. The primary skin lesions are flaccid, thin-walled, easily ruptured blisters. The fluid in the bullae is clear at the early stages, and then may become hemorrhagic, turbid, seropurulent. When the bullae are ruptured, they form painful erosions with oozing and bleeding, and they can be covered by crusts.
- Pemphigus vegetans: a rare variant of pemphigus vulgaris clinically characterized by flaccid blisters and/or pustules that become erosions, ultimately progressing to vegetating plaques, especially in the intertriginous areas.
- Pemphigus foliaceus: rare variant where blister levels so superficial that blisters are extremely unstable and rarely intact. It manifests with impetigo-like crusted erosions usually on an erythematous base, and usually starts in seborrheic areas. Mucosae are usually spared. Transition into exfoliative erythroderma.
- Pemphigus erythematosus: a localized variant of pemphigus foliaceus in the malar region of the face and in the other seborrheic areas.
- Pemphigus herpetiformis: clinically resembles dermatitis herpetiformis or linear immunoglobulin A bullous dermatosis.
- IgA pemphigus: Painful and pruritic vesiculopustular eruptions. Intraepidermal IgA deposits. Two distinct subtypes are subcorneal pustular dermatosis (anti-desmocollin 1 antibodies) and intraepidermal neutrophilic dermatosis (anti-desmoglein antibodies).
- Paraneoplastic pemphigus: very rare. Associated with an underlying neoplasm, most frequently non-Hodgkin lymphoma and chronic lymphocytic leukemia. Clinically is characterized by severe stomatitis with erosions and ulcerations in the oropharynx that extent to vermillion lip. In most

cases, a severe pseudomembranous conjunctivitis is present. Paraneoplastic autoimmune multi-organ syndrome (PAMS) has been coined to account for the variable non-bullous cutaneous manifestation and additional systemic findings, such as bronchiolitis obliterans. Serum autoantibodies against several desmosomal components (desmogleins, desmocollins, plakoglobin).

Localisation

Oral mucosae and entire skin surface, especially head, neck, and trunk.

Classification

- Pemphigus vulgaris: target antigens desmoglein 3 and desmoglein 1, suprabasal blister formation.
- Pemphigus foliaceus and erythematosus: target antigen desmoglein 1, subcorneal blister formation.
- Fogo selvagem (Brazilian pemphigus): endemic form of pemphigus foliaceus in Brazil, black flies (*Simulium*) may be vectors.
- Pemphigus herpetiformis: most cases target antigen desmoglein 1.
- IgA pemphigus.
- Paraneoplastic pemphigus.

Laboratory & other workups

Direct immunofluorescence (DIF): identification of in vivo bound intra-epidermal, intercellular IgG or IgA autoantibodies in the skin biopsy.

Indirect immunofluorescence (IIF): identification in patient's serum of circulating IgG autoantibodies against stratified squamous epithelium (monkey esophagus, rat or rabbit urinary bladder epithelium).

ELISA or immunoblot or detection of autoantibodies against desmosomal proteins in serum. Antinuclear antibodies may be detected in pemphigus erythematosus.

Dermatopathology

Intraepidermal clefts secondary to acantholysis. Eosinophilic spongiosis is characteristic.

Course

Chronic, progressive. If untreated, fatal in 95% of cases.

Complications

Before the introduction of systemic corticosteroids, high mortality rate (skin-related sepsis, marasmus secondary to fluid and protein loss, difficulty in eating). Currently complications secondary to high-dose corticosteroids and other immunosuppressive therapy.

Diagnosis

Tzanck test: direct identification of acantholytic cells in smear of blister content (smear, Giemsa stain). Histology to disclose the level of epidermal acantholysis. The demonstration of IgG or IgA autoantibodies directed against the cell surface of keratinocytes is the gold standard for the diagnosis. To demonstrate the autoantibodies, the methods are direct immunofluorescence (DIF), indirect immunofluorescence (IIF), immunoprecipitation, immunoblotting, and ELISA. Immunoblot/ ELISA: antibodies anti-desmoglein 1 and 3 autoantibodies in serum.

Differential Diagnosis

- Mucosal and erosive oral lesions: acute herpetic stomatitis, aphthous stomatitis, erosive lichen planus, erythema multiforme major or Stevens-Johnson syndrome, fixed drug reaction, systemic lupus erythematosus, mucous membrane pemphigoid.
- Skin lesions: other autoimmune bullous diseases, erythema multiforme, Hailey-Hailey disease, Grover disease, staphylococcal scalded skin syndrome (SSSS), toxic epidermal necrolysis (TEN).

Prevention & Therapy

Systemic: rituximab, long-term immunosuppressive therapy (corticosteroids and steroid sparing agents, such as azathioprine, methotrexate, cyclophosphamide). Rituximab, the current first line treatment, is a B-cell depleting monoclonal anti-CD20 antibody, and is administered usually by two separate intravenous infusions of 1 g. In general, a long-lasting beneficial effect is seen, and it can be repeated after months. A humanized affinity-matured IgG4-kappa monoclonal antibody with high affinity for the neonatal Fc and Bruton's tyrosine kinase (BTK) inhibitors receptor seem promising., Systemic corticosteroid therapy: prednisone or prednisolone, with an initial dosage of 1 mg/kg/day or high dose pulse corticosteroids (1 g/day for 3 days). Immunosuppressive agents (azathioprine), combined with corticosteroids, may results in a gaining early control of the disease. Therapy initially high-dose, then tapered over many months to years. In refractory cases: high dose intravenous immunoglobulins.

Topical: general wound care.

Special

None.

References

- [Schmidt E, Kasperkiewicz M, Joly P. \(2019\). Pemphigus. Lancet Sep 7;394\(10201\):882-894. doi: 10.1016/S0140-6736\(19\)31778-7. PMID: 31498102.](#)
- [Malik AM, Tupchong S, Huang S, Are A, Hsu S, Motaparathi K. \(2021\). An updated review of pemphigus diseases. Medicina \(Kaunas\) Oct; 57\(10\):1080. doi: 10.3390/medicina57101080. PMID: 34684117; PMCID: PMC8540565.](#)
- [Lim YL, Bohelay G, Hanakawa S, Musette Ph & Janela B \(2022\). Autoimmune Pemphigus: Latest Advances and Emerging Therapies. Frontiers in Mole Biosciences Feb 4;8:808536. doi: 10.3389/fmolb.2021.808536. PMID: 35187073; PMCID: PMC8855930](#)

1.2.6 Pemphigoid group

Grading & Level of importance: C



G. Girolomoni, Verona; P. Gisondi, Verona; M. Maurelli, Verona

IDC-11

EB41.0

Synonyms

None.

Definition

Autoimmune chronic diseases with subepidermal blister formation.

Epidemiology

Bullous pemphigoid (BP) is the most common. Typically presents in older adults (>60 -70 years). The clinical presentation can be polymorphic, especially in the early stages. The annual incidence has been

estimated to be at least 6-30 new cases per million population. The relative estimated risk in patients over 80 years of age is about 300-fold higher than in 60 years old patients. M = F.

Aetiology & Pathogenesis

BP is an immune-mediated disease associated with a humoral and cellular response directed against two hemidesmosomal adhesion proteins of the cutaneous basement membrane, BP antigen 180 (BP180) and BP230. Disrupted levels of several cytokines including CCL-2, CCL-17, IL-5, IL-6, IL-8 and IL-17 are found. Increased blister fluid levels of CCL11, eotaxin, and TNF- α . Autoantibodies in BP react with two structural components of the dermal-epidermal junction (DEJ): type XVII collagen (COL17, also called BP180 or BPAG2) and BP230 (also called dystonin or BPAG1) In some cases, drugs like gliptins and diuretics may be a trigger to the development of BP.

Signs & Symptoms

- BP: initially erythematous and urticarial patches and plaques and marked pruritus, followed by vesicles and tense blisters on a normal or erythematous skin. The blisters measure 0.5-4 cm in diameter, with a clear fluid inside, hesitating in ulcerate lesions and then in crusted lesions. Sometimes the fluid inside can become haemorrhagic. The lesions are usually symmetric in the distribution and are located in the flexural areas of extremities and in the abdomen and lower trunk. The residual lesions show hyper- and hypopigmentation. Mucosal involvement is uncommon; in 10-30% of patients, blister and erosions occurring the oral cavity.
- Pemphigoid gestationis: is a pemphigoid-like clinical picture but occurring in 2nd-3rd trimesters. Disease usually starts around the umbilicus and heals spontaneously after delivery.

Localisation

The skin is involved. Sometimes it is located also in the mucous membrane.

Classification

- BP
- Pemphigoid gestationis = pemphigoid of pregnancy (formerly herpes gestationis)
- Mucous membrane pemphigoid (formerly cicatricial pemphigoid)
- Linear IgA disease (chronic bullous dermatosis of childhood)
- Epidermolysis bullosa acquisita

Laboratory & other workups

The diagnosis of BP is based on the clinical presentation, histopathology, and especially on positive direct immunofluorescence (DIF). Direct and indirect (IIF) immunofluorescence: demonstration of antibodies directed against basement membrane zone (linear deposits of C3 and IgG). DIF microscopy of perilesional skin demonstrates the presence of fine, linear, continuous deposits of C3 and/ or IgG (IgG4 and IgG1) along the basement membrane. Regarding IIF, in 60-80% of patients the circulating anti-basement membrane autoantibodies of IgG, less frequently IgA and IgE, are detectable. Hypereosinophilia is common, ELISA for the detection of BP180 and BP230 specific auto-antibodies in serum.

Dermatopathology

Subepidermal blister with dermal infiltrate of eosinophils.

Course

Chronic and progressive, with spontaneous exacerbations. The majority of cases are not associated with a trigger. In some cases, drugs cause the lesions, such as diuretics (captopril, furosemide, spironolactone), anticonvulsants, psychotropics, analgesics, and gliptins (dipeptidyl-peptidase IV inhibitors, agents to treat type 2 diabetes mellitus). Linear IgA disease can be triggered by antibiotics (vancomycin, penicillin). Other agents linked to the exacerbations of pemphigoid are UV light, radiation, and infections (human herpes virus).

Complications

Skin-related sepsis, fluid and protein loss. Mortality among elderly patients. Permanent mucosal scars in mucous membrane pemphigoid.

Diagnosis

Tzanck test negative. Histology (subepidermal blister formation, tissue eosinophilia). Direct immunofluorescence: linear deposits of C3 and IgG along the dermoepidermal junction. Indirect immunofluorescence: circulating IgG which binds to the dermo-epidermal junction of normal skin and to the roof of human sodium chloride split skin. ELISA for the detection of BP180 and BP230 specific auto-antibodies in serum.

Differential Diagnosis

With other autoimmune bullous dermatoses, especially epidermolysis bullosa acquisita, which is caused by antibodies against collagen VII in the uppermost layer of the dermis, bullous arthropod bites, allergic

contact dermatitis, Steven-Johnson syndrome, bullous drug eruptions, eczema, porphyria cutanea tarda/pseudoporphyria. In split skin preparation, antibodies are to the floor of the blister compared to the roof in BP. Linear IgA dermatosis is characterised by linear deposits of IgA rather than IgG along the basement membrane zone (this is the most common autoimmune bullous disease in childhood).

Prevention & Therapy

The treatment can be different according of the severity of the disease and the co-morbidities. For the extensive form, defined by a number of lesions major of 10 new blisters/day or an involvement of a large body surface area, the first line treatment is systemic corticosteroids (0.5-1 mg/kg/day) for 1-2 weeks, then progressively tapered in the several months. Doxycycline may act as a steroid sparing agent. In severe, refractory cases: azathioprine, mycophenolate mofetil, methotrexate, dapsone, or cyclophosphamide; some cases may respond to rituximab or high dose intravenous immunoglobulins. For localized forms, potent topical corticosteroids may be sufficient.

Special

None.

References

- [Patel PM, Jones VA, Murray TN, Amber KT. \(2020\). A review comparing international guidelines for the management of bullous pemphigoid, pemphigoid gestationis, mucous membrane pemphigoid, and epidermolysis bullosa acquisita. Am J Clin Dermatol. Aug;21\(4\):557-565. doi: 10.1007/s40257-020-00513-3. PMID: 32180161.](#)
- [Pratasava V, Sahni VN, Suresh A, Huang S, Are A, Hsu S, Motaparathi K. \(2021\). Bullous pemphigoid and other pemphigoid dermatoses. Medicina \(Kaunas\) Oct 4;57\(10\):1061. doi: 10.3390/medicina57101061. PMID: 34684098; PMCID: PMC8539012.](#)
- [Hideyuki Ujiie \(2023\). What's new in the pathogeneses and triggering factors of bullous pemphigoid J Dermatology Feb;50\(2\):140-149. doi: 10.1111/1346-8138.16654. Epub 2022 Nov 22. PMID: 36412277; PMCID: PMC10098684.](#)

1.2.7 Dermatitis Herpetiformis

Grading & Level of importance: C

G. Girolomoni, Verona; P. Gisondi, Verona; M. Maurelli, Verona



ICD-11

EB44

Synonyms

Duhring disease.

Definition

Chronic recurrent polymorphic blistering dermatosis with intense pruritus, associated with gluten-sensitive enteropathy (autoantibodies against gliadin and tissue transglutaminase).

Epidemiology

The prevalence is 10.4 per 100,000 individuals. The annual incidence is 1.3 per 100,000 persons. M>F, 20-70 years.

Aetiology & Pathogenesis

Granular depositis of IgA antibodies directed against epidermal transglutaminase precipitate in the dermal papillae and lead to sub-epidermal blister formation. The IgA autoantibodies are most likely triggered by the enteropathy. Neutrophilic infiltration in the dermal papillae. On small bowel biopsy, more that 90% of patients have a gluten-sensitive enteropathy. The intestinal involvement may be like a minimal infiltration of the lamina propria by lymphocytes, to a minimal atrophy of the jejunum associated to an intraepithelial lymphocytic infiltrate, to a complete atrophy of the villi in the small intestine.

Signs & Symptoms

Marked burning and pruritus, usually small tense grouped (herpetiform) papulo-vesicles on an erythematous base, often with secondary excoriations and crusts.

Localisation

Shoulders, buttocks, with a symmetric distribution on the extensor surfaces of extremities with a

symmetrical distribution, especially knees and elbows.

Classification

None.

Laboratory & other workups

Direct immunofluorescence: granular IgA deposits in the tips of the dermal papillae.

Serum: IgA anti-transglutaminase antibodies.

Dermatopathology

Sub-epidermal blister formation with papillary abscesses of neutrophils and occasionally eosinophils.

Course

The course of dermatitis herpetiformis is chronic and recurrent.

Complications

A strong association exist between dermatitis herpetiformis and Hashimoto thyroiditis; also, an augmented incidence of enteropathy-associated T-cell lymphoma, but it is rare. It is important to perform investigations for the possibly complications related to malabsorption such as iron deficiency anemia, B12/folate levels, bone densitometry for osteoporosis, and a dental examination; ataxia, central and peripheral nervous system defects and myopathies may be potential neurologic sequelae.

Diagnosis

Histology and DIF, with the demonstration of IgA deposition in papillary dermis. IgA anti-transglutaminase antibodies in serum. Small bowel biopsy is optional and not mandatory for the diagnosis. Gluten-sensitive enteropathy confirmed in over 90% of patients but symptomatic in only 15%. Rapid symptom relief with dapsone.

Differential Diagnosis

Other autoimmune bullous dermatoses (bullous pemphigoid, pemphigus vulgaris), especially linear IgA disease (no gluten-sensitive enteropathy), arthropod bites, scabies, urticarial vasculitis.

Prevention & Therapy

Gluten-free diet, characterized by a wheat, rye and barley diet exclusion, and dapsone. Dapsone is important to relieve the itch and the lesions, but it has no effects on enteropathy. Prior to starting dapsone, it is recommended to measure glucose-6-phosphate dehydrogenase. The initial dose of dapsone is 25- 50 mg/daily, and then usually a dose of 100 mg/daily if needed. Whilst on dapsone monitor for side effects, such as agranulocytosis, anemia, methaemoglobinemia, hepatitis and peripheral neuropathy. Another drug used is sulfasalazine.

Special

None.

References

- [Nguyen CN, Kim SJ. \(2021\). Dermatitis Herpetiformis: An update on diagnosis, disease monitoring, and management. Medicina \(Kaunas\) Aug 20;57\(8\):843. doi: 10.3390/medicina57080843. PMID: 34441049; PMCID: PMC8400185.](#)
- [Reunala T, Hervonen K, Salmi T. \(2021\). Dermatitis herpetiformis: an update on diagnosis and management. Am J Clin Dermatol. May;22\(3\):329-338. doi: 10.1007/s40257-020-00584-2. PMID: 33432477; PMCID: PMC8068693.](#)

1.3 Physically Induced Dermatoses

1.3.1 Thermal Injury

Grading & Level of importance: A
H. Gollnick, Magdeburg



ICD-11

Site specific codes only.

Synonyms

Burns/scalds; Combustio & Ambustio.

Definition

Thermal injury induces physical damage to the skin with tissue destruction of varying degrees and is caused and dependent on the degree of thermal energy.

Epidemiology

Burns and scalds belong to the most frequent accidents in the environment of household and leisure. People of all ages are susceptible to minor burn injury. The highest incidence occurs during the first few years of life and in persons aged 20-29 years. The mechanism of minor burn injury varies considerably with the age of the victim. Minor burns in children younger than 4 years are caused primarily by contact with hot surfaces and by liquid scalds, with scalds accounting for approximately 75% of burns in children under age 5 years.

Aetiology & Pathogenesis

Thermal injury induces a direct tissue damage on the site of energy (> 65 °C) delivered from exogenous thermal energy of different origin (UVB, fire, gas explosion, hot water and other fluids, hot dump, hot metals, electric energy). The thermal injury is followed by denaturation of proteins and finally coagulation necrosis. Depending on the degree and depth of injury, capillaries are destroyed and plasma and electrolytes move to the interstitial tissue. The more tissue damage, the more the risk of hypovolemic shock (1 square meter body surface around 3 liters loss of volume/day) exist. Furthermore, within the following 72 hrs, the damage can continue and, therefore, has to be stopped as quickly as possible.

Signs & Symptoms

Thermal injury induces a cascade of symptoms which are characterized by erythema, blistering and necrosis depending on the degree of energy delivered to the skin and deeper tissues.

Localisation

In general, the area of exposure is the hot spot of energy delivered to the tissue with a decrease of damage moving away from the side of highest exposure.

Classification

- Burns (combustio) and scalding (ambustio) show a characteristic feature of the thermal injuries. The tissue damage is divided into three degrees:
- The 1st degree is characterised by: erythema and pain.

- The 2nd degree is characterised by: grade 2 a: superficial destruction with epidermal and dermal blistering, and 2 b: deep destruction with dermal blistering and destruction of hair and other skin adnexae.
- The 3rd degree is characterised by: involvement of all layers of the skin and all adnexae and with extension to the subcutis and muscles.

Laboratory & other workups

If burning and scalding have reached grade 2b and grade 3 constant monitoring of electrolyte and protein balance is necessary. Supervision at an intensive care unit is essential.

Dermatopathology

The tissue damage depends on the degree of thermal energy and followed by epidermal blistering, apoptosis and necrosis of all types of cells (see above).

Course

The course of thermal energy damage varies with the degree of severity and extent. More extensive burns/scalds have to be treated in specialized burn centres. Burns involving >40% of skin surface area are often fatal.

Complications

Shock in severe cases is a severe complication and often related to hypovolemia. Super-infections are very common. Children with > 5% and adults with > 10% body surface involvement have to be admitted to hospital.

Diagnosis

History of event and clinical features makes the diagnosis quite easy. The exact estimation of degree of burning /scalding, however, is essential for management decisions.

Differential Diagnosis

Usually the case history, the place and environment where the thermal energy has been delivered will enable a clear diagnosis. Unconscious patients, however, can show differential diagnoses of generalized or localized erythema caused by drugs, spider bites, jellyfish toxic fluids and other causes of erythroderma.

Prevention & Therapy

Therapy must be initiated as soon as possible, adjusted to the extent and severity of the thermal energy delivered. Minor burns should be cooled by local corticoid emulsions. Systemic NSAID plus LTB₄ inhibitors can reduce initial prostaglandin and leukotriene release. Therapeutic prevention of superinfection depends on the amount of involvement of body surface.

With more severe burns, temperature control is a problem. The management involves in general wound care, electrolyte and protein replacement, pain control and systemic antibiotics and referral to a regional burn centre the injury is of grade IIB and III. Skin transplantation can be considered at a later stage. Preservation of normal skin for in vitro growth / cell culture is done in specific burn centers providing the appropriate equipment.

Special

The critical body surface involvement >10% children and >20% adults make hospital admission necessary and care by specialists.

References

- [Wollina U \(2022\) Disorders Caused by Physical and Chemical Damage in Braun-Falco's Dermatology pp 775–793](#)
- [Johnson E, Maguire SA & Hollén LI \(2017\) Agents, mechanisms and clinical features of non-scald burns in children: A prospective UK study Burns 43\(6\) DOI:10.1016/j.burns.2017.01.036](#)

1.3.2 Pernio and Congelatio

Grading & Level of importance: A



H. Gollnick, Magdeburg

ICD-11

NF03.0

Synonyms

Chillblains; Perniosis; Dermatitis congelatio escharotica.

Definition

Pernio: mostly cold-induced blue-red indurated papules or nodules occur, usually manifesting at the site of legs or feet. F > M.

Congelatio: 1st to 3rd degree. In extreme cases, irreversible necrosis or death may occur.

Epidemiology

Pernio mostly appear in spring and autumn around 0°C, acold, damp conditions. In adolescents with acrocyanosis (horse riding, cycling for long periods, inappropriate shoes, wet socks) acral areas are affected.

The so called secondary pernio is associated with other conditions such as lupus erythematoses (SLE /- chilblain CHLE). Most pernio cases are idiopathic. Any cases of pernio should prompt the clinician to check for some secondary conditions known to trigger pernio.

Congelatio appears in the skin and deeper tissue mostly during winter sport activities, mountaineering, but also to be observed in those sleeping outdoors.

Aetiology & Pathogenesis

The appearance of congelatio depends on how much lower than 0°C the exposure is, as well as the length of exposure. In contrast, persistent exposure to cold and damp conditions predisposes to the development of pernio over days to weeks.

Signs & Symptoms

Classification of Perniones

No specific classification exists.

Classification of Congelatio

In congelatio of

- grade 1, erythematous lesions develop first, followed by,
- grade 2, bullous lesions, and,
- grade 3, necrosis with irreversible sequelae. Large body areas with long exposure time may lead to death. In perniones, blue-red oedematous papules or nodules develop, sometimes they are quite tender or even painful. Those appear at temperatures from 0°C to 4°C.

Localisation

Typically, the lesions occur at acral sites and in areas which are easily cooled (especially the shins,

fingers, toes and upper thighs in equestrians). Dampness is also important and some professions are at an increased risk, such as butchers and farmers. In congelatio the degree of severity depends on whether the coldness is localized or generalized.

Classification of Congelation

Grade I: dermatitis congelationis erythematosa: ischemia, narrowing of capillaries, pale skin. After rewarming, a burning erythema develops. Almost always, a restitutio ad integrum is the course of grade I.

Grade II: dermatitis congelation bullosa: after rewarming a subepidermal bullous eruption occurs, sometimes hemorrhagic.

Grade III: Dermatitis congelatio escharotica: the colour of the skin changes from pale to blue to black; by palpation it is tense or hard and lacking sensitivity. If localized, a demarcation later appears and rejection of necrotic tissue.

Dermatopathology

Pernio: in severe cases, blistering, edema, hyperemic vessels with heavy inflammatory cell infiltrate lymphocytic vasculitis and frequent involvement of the eccrine glands.

Congelatio: depending on the different degrees one observes vessel narrowing, blistering, apoptosis and necrosis.

Course

Pernio: they are recurrent, more common in spring and autumn (cool, moist climatic conditions).

Congelatio: depending on the length of injury, it may be in part reversible or irreversible. Long-term extensive body surface area involvement leads to death.

Complications

Perniones: Rarely ulceration.

Congelatio: prolonged cooling may lead to death.

Diagnosis

History, localization, clinical features.

Differential Diagnosis

Lupus pernio (sarcoidosis), chilblain lupus (lupus erythematosus). Diabetic and/or atherosclerotic necrosis or blue acral discoloration.

Prevention & Therapy

Perniones: warming up of body and local temperature at exposure site. Water-resistant protective clothing is recommended. Topical or systemic vasodilators (e.g. calcium channel blockers) can be used.

Congelatio: slow warming up of the central body temperature, no direct warming of involved lesions should be done. Hyperbaric oxygenation to avoid amputation in severe cases in special centers and immediate prostaglandin infusions should be given.

Special

Severe congelatio of grade III needs to be treated in special centers and intensive care units.

References

- [Cappel JA, Wetter DA \(2014\) . Clinical characteristics, etiologic associations, laboratory findings, treatment, and proposal of diagnostic criteria of pernio \(chilblains\) in a series of 104 patients at Mayo Clinic, 2000 to 2011. Mayo Clin Proc. 89\(2\):207](#)
- [Judy R Wilson JR, Migala A,Cianci P & Stone JA \(2018\) Frostbite: pathophysiology and treatment options .Trauma Emerg Care, 3\(4\): 1-4](#)
- [Scremin Souza SC & Haman F \(2020\) Cold Weather Injuries Review: Optimal Strategies to Mitigate and Treat Cold Weather Injuries. A Narrative Review. Defence Research and Development Canada.University of Ottawa.W7714-145967/001/SV](#)

1.3.3 Sunburn

Grading & Level of importance: A
H. Gollnick, Magdeburg



ICD-11

EJ40

Synonyms

Solar dermatitis.

Definition

Acute phototoxic dermatitis caused by electromagnetic radiation in the UVB range (280-315/320 nm). Unphysiologically high UVA doses can elicit an erythema too.

Epidemiology

Very often it can be observed during leisure time and vacations in sun-rich areas or during occupational work outside, e.g. when no or inappropriate sun protection is available or used.

Aetiology & Pathogenesis

It is an acute dermatitis caused by erythematogenic doses of UVB radiation, which is more common in fair-skinned subjects (Fitzpatrick skin types I-II). Highest erythematogenic dose is with 313 nm. More severe cases result in release of pro-inflammatory cytokines (IL-6), prostaglandins (PGE₂), isoprostans and leucotrienes (LTB₄) into systemic circulation and leading also to systemic symptoms incl. fever. Acute overdosing of UVA (315–400 nm) for example by artificial tanning studio exposure can stimulate release of free oxygen radicals and damage DNA.

Signs & Symptoms

Shortly after overexposure to UVB, prickling, itching and burning can be felt. Depending on the skin type, dose, exposure length, time of day and latitude, within 12 to 24 hours an erythema develops. In severe cases, edema, blistering and pain, fever and fatigue develop.

Localisation

In areas direct exposed to UVB light energy the erythema develops.

Classification

- 1st degree: burning, erythema, desquamation.
- 2nd degree: blisters, weeping, crusts.
- Rarely 3rd degree: necrosis.

Laboratory & other workups

Unremarkable. Increase of CRP or mild leucocytosis with involvement of large body surface areas.

Dermatopathology

Apoptosis and necrosis of epidermal keratinocytes is a remarkable sign. Langerhans cells show disfiguring in their cytology by immunostaining (dysfunction) and a decrease in numbers. Edema of the upper dermis and widening of capillaries is typical. Submicroscopically, mutations by cyclobutan dimers develop. Incomplete DNA repair can lead to mutations and persisting clones of keratinocytes which later may develop into actinic keratoses.

Course

It shows a highly variable clinical appearance (just as in acute contact dermatitis): erythema, vesicles or blisters, weeping, crusts, scales. When the exposure was high and the body surface involved large, fever and malaise are to be observed. Complete spontaneous healing is the regular course with some pityriasiform desquamation after a couple of days and hyperpigmentation. In more severe courses, small or large blisters may require special care.

Complications

Frequent sunburns and continuous suberythematogenic doses of UVB, especially in childhood, lead to increased numbers of melanocytic naevi and an increased risk of malignant melanoma and non-melanoma skin cancer later in life. After chronic repeated overexposure of natural or artificial UVB/UVA skin becomes mottled and shows atrophy, discolouring with hyper- and hypopigmentation, teleangiectasia and roughness as well as wrinkling.

Diagnosis

By case history and clinical picture.

Differential Diagnosis

- Acute contact dermatitis
- photoallergic or phototoxic reactions (several drugs, natural substances, i.e. Ammi majus and visnaga, Pastinaca sativa, Ruta graveolens)
- diseases provoked by light such as porphyrias
- all types of lupus erythematosus and dermatomyositis
- Erythroderma in psoriasis, atopic dermatitis, ichthyosis, pityriasis rubra pilaris

Prevention & Therapy

Prevention: Sun protection factor of > 25, UV protecting glasses, UV protecting dress, sunscreen and shadow, avoiding of exposure between 11 am to 15 pm. Consider light sensitization by drugs and natural substances taken orally or applied to the skin.

Therapy: Immediate removal from solar exposure is essential, shade alone is not enough. Within the first 12 hours, oral non-steroidal anti-inflammatory drugs and class 3 antihistamines with effects on the release of prostaglandines and leukotrienes should be combined. Cooling topical agents (lotions, cold creams) and wet dressings at the beginning, later after 12 to 24 hours topical corticosteroids should be applied. Sometimes a systemic corticosteroid dose single dose of 50 to 100 mg will be helpful. Systemic replacement of fluid loss is recommended.

Special

Overexposure to the unprotected head by solar energy in particular to infants and children with complications such as edema of the brain need immediate hospitalization.

References

- [Bowers JM, Hamilton JG, Lobel M, Kanetsky PA, Hay JL \(2021\) Sun Exposure, Tanning Behaviors, and Sunburn: Examining Activities Associated With Harmful Ultraviolet Radiation Exposures in College Students. J Prim Prev. 42\(5\):425-440.](#)
- [R. E. Neale et al \(2023\) The effects of exposure to solar radiation on human health. Photochemical & Photobiological Sciences \(2023\) 22:1011–1047](#)

1.3.4 Photodermatoses

Grading & Level of importance: A



RM. Pujol, Barcelona

ICD-11

EJ30

Synonyms

Photodermatitis.

Definition

Dermatoses caused by electromagnetic radiation in the ultraviolet (UV) or visible light spectrum.

Epidemiology

Polymorphous light eruption (PMLE) is the most common photodermatosis (prevalence 10% to 20%), followed in decreasing order of frequency by photoaggravated dermatoses, drug-induced photosensitivity, chronic actinic dermatitis (CAD) and solar urticaria (SU). Some photodermatoses are extremely rare, such as hydroa vacciniforme.

Aetiology & Pathogenesis

Photodermatoses represent a heterogenous group of skin disorders, caused or aggravated by UV radiation and/or visible light. The exact pathomechanism is not completely understood. UV light can cause dermatitis as a single agent (sunburn) or in combination with phototoxic (furocumarins such as psoralens) or photoallergic substances (medications such as sulphonamides, promethazine, etc).

Ultraviolet B (UVB) is the main spectrum responsible for skin erythema, whereas ultraviolet A (UVA) is mostly involved in the drug-induced photosensitivity reactions. In all instances, oxygen free radicals trigger the release of pro-inflammatory cytokines (acute dermatitis) or cause permanent skin damage (chronic actinic damage). In addition, some skin disorders are aggravated or provoked by light.

Signs & Symptoms

Depends on disorder. Skin eruptions usually or exacerbate in the UV exposed areas following sun or artificial light radiation. The severity of symptoms and signs and the sun exposure time can vary over time and relate to season and climate. The lesions may be manifested as - papules (PMLE, actinic prurigo, CAD), - blisters (PMLE, porphyrias, photoallergy or photo-toxicity), - urticarial lesions (SU, erythropoietic protoporphyria), - lichenified plaques or eczematous lesions (CAD, photoallergic contact dermatitis). Sometimes scars may be present (porphyria cutanea tarda, discoid lupus erythematosus, actinic prurigo, hydroa vacciniforme).

The eruption may develop within minutes as in solar urticaria (SU) or few hours or days after light exposure as in PMLE. "Hardening" phenomenon, defined as improvement of the eruption during the summer with increasing sun exposure may be observed in PMLE and SU. In photoaggravated dermatoses the evidence of characteristic lesions of the underlying dermatoses may be helpful for the diagnosis.

The most relevant idiopathic immune-mediated and drug-induced photodermatoses include:

Polymorphic light eruption (PMLE): Clinically polymorphous itchy rash that affects exposed skin (occasionally sparing the face) developing minutes to hours after sun exposure and tends to resolve in hours, days or rarely weeks. Macular, papular, papulovesicular, urticarial, multiforme- and plaque-like lesions. More prevalent in young women. Recurrent rash every spring/summer. Probable delayed-type hypersensitivity reaction against endogenous cutaneous photoantigen/s.

Actinic prurigo (AP) is a rare, sunlight induced, itchy papular or nodular eruption, often excoriated. More frequent in native North, Central and South Americans.

Hydroa vacciniforme (HV). Rare acquired photodermatosis, usually with onset in childhood, and characterized by vesicle, crust and scar formation that follows exposure to sunlight.

Possible association with latent Epstein–Barr virus (EBV) infection.

Chronic actinic dermatitis (CAD) is a rare, persistent chronic (UV- and rarely visible) light-induced dermatosis. CAD occurs most commonly in elderly men. Eczematous, itchy eruption, often lichenified. Tends to persist over many years.

Solar urticaria (SU) is a rare UVB, UVA and visible light chronic inducible urticaria. Wheals confined to sunlight-exposed skin appear a few minutes after visible radiation exposure. Sudden onset and the lesions resolve in one or two hours. 50% of cases of Idiopathic SU resolve spontaneously within 5 years.

Drug- and exogenous chemical-induced photosensitivity include:

Phototoxic and photoallergic skin reactions which can be triggered by a variety of topical and systemic medications (mainly due to UVA light).

Phototoxic (non-immunologically mediated) reactions are the result of direct tissue injury caused by a phototoxic agent and radiation. Clinically may resemble acute sunburn. It can occur in all individuals exposed to adequate doses of the agent and the activating wavelengths of radiation.

Topical medications inducing phototoxicity include NSAIDs, antibiotics, corticosteroids, dyes, coal tar, psoralens, benzocaine, etc.

Systemic drugs may include: Antimicrobials (tetracyclines, quinolones, voriconazole), diuretics (furosemide, hydrochlorothiazide), NSAIDs (ketoprofen, naproxen), antimalarials, psoralens, retinoids, UVB calcium channel blockers, etc.

Photoallergic reactions are type IV delayed hypersensitivity response that occur only in sensitized individuals, and requires only a minimal concentration of the photoallergen. Clinically develop within 24 h after exposure to the photosensitizer and sunlight and resembles eczematous dermatitis.

Systemic medications causing photoallergy include NSAIDs (piroxicam, celecoxib) sulphur- containing drugs (hydrochlorothiazide, sulfadiazine, sulphonamides, sulfonyleureas), antimalarials, antimicrobials (chloroamphenicol), phenotiazines, chlorpromazine, etc.

Localisation

Some disorders usually restricted to area(s) of light exposure (PMLE and SU), whereas others may spread to distant areas (photoallergic reactions) or may also affect non-exposed skin (CAD or actinic prurigo). The lesions are sharply-demarcated, symmetrically distributed in sun-exposed areas including forehead, cheeks, V-region of neck, nape of neck, dorsum of the hands, and extensor aspects of forearms.

Classification

Photosensitive cutaneous disorders can be classified into four main categories:

1. Idiopathic photodermatoses, immunologically mediated where light alone triggers the disease e.g. polymorphic light eruption, solar urticaria, hydroa vacciniforme.
2. Drug- and chemical-induced photosensitivity, including a subgroup of phototoxic or photoallergic dermatoses triggered by exogenous topical or systemic substances, and a second subgroup of metabolic disorders in which there is an endogenous accumulation of phototoxic substances because of enzymatic defects, e.g. cutaneous porphyrias.
3. Genodermatoses characterized by a defective DNA repair, in which there is increased sensitivity to light e.g. xeroderma pigmentosum secondary to a defect in DNA-repair enzymes.
4. Photoaggravated dermatoses. Include a heterogeneous group of disorders.

TABLE 1- PHOTODERMATOSES. CLASSIFICATION

I- IDIOPATHIC PHOTODERMATOSES (Immunologically mediated)

Polymorphous light eruption (PMLE)
Actinic prurigo (AP)
Hydroa vacciniforme (HV)
Solar urticaria (SU)
Chronic actinic dermatitis (CAD)

II- DRUG- AND CHEMICAL-INDUCED PHOTSENSITIVITY

Exogenous: Phototoxicity and Photoallergy
Endogenous: Cutaneous porphyrias (CP)

III- DEFECTIVE DNA REPAIR DISORDERS

Xeroderma pigmentosum	Cockayne syndrome
UV-sensitive syndrome	Trichothiodystrophy
Bloom syndrome	Kindler syndrome
Rothmund–Thomson syndrome	

IV- PHOTOAGGRAVATED DERMATOSES

Lupus erythematosus	Rosacea	Dermatomyositis
Acne vulgaris	Psoriasis	Reticular erythematous mucinosis
Lichen planus	Darier disease	Atopic eczema
Herpes simplex	Bullous pemphigoid	Pellagra
Pemphigus foliaceus (erythematosus)		

Laboratory & other workups

In cases of photodistributed eruption of unknown etiology a complete blood cell count, biochemical evaluation (liver function tests), autoantibody screening (ANA, anti-dsDNA, anti-Ro) to exclude connective tissue diseases, and porphyrins in blood, urine and stool may be useful for a definite diagnosis.

Dermatopathology

Histological changes are often non-specific, however, skin biopsy is helpful in the diagnosis of polymorphous light eruption and chronic actinic dermatitis. Immunophenotypic markers studies and gene rearrangement analyses are useful in differentiating chronic actinic dermatitis from cutaneous T-cell lymphoma, which may show sometimes clinical similarities.

Course

Variable in the different disorders. PMLE may persist indefinitely, but often gradually improves, and occasionally remits, SU often presents a fluctuating course, with periods of improvement and remission, whereas in phototoxic/photoallergic skin reactions a variable duration of photosensitivity is noted after stopping a photoactive drug (from hours to months).

Complications

In severe SU, anaphylactic shock may occur after whole-body exposure.

Diagnosis

A proper systematic evaluation, including a detailed clinical history are often most helpful. Neonatal lupus and genodermatoses presents in infancy, hydroa vacciniforme (HV) in children, PMLE in young adults, and phototoxicity and chronic actinic dermatitis (CAD) are more common in elderly. Questioning regarding possible exposure to various photosensitizers, such as topical and systemic medications, cosmetics, fragrances and plant extracts may suggest a diagnosis of phototoxicity or photoallergy. Any underlying illness, personal or family history of autoimmune or connective tissue diseases, could add towards making the correct diagnosis.

Photodiagnostic procedures are essential. Monochromatic UVA and UVB sensitivity testing, photo patch testing, provocative challenge with UV and/ or visible light. Assessment of cutaneous response consists either in the development of lesions and the minimal erythema dose (MED). Photopatch testing is performed when photoallergic contact dermatitis is suspected. In some cases, patch testing should be recommended to rule out associated allergic contact dermatitis.

Differential Diagnosis

Depending on the different entities.

- In PMLE the differential diagnosis should be established with photoallergic eczemas, solar urticaria, erythema multiforme and even lupus erythematosus (LE).
- Solar urticaria lesions should be distinguished from erythropoietic protoporphyria, urticarial phototoxic reactions, other forms of physical urticaria, and PMLE (urticarial lesions), whereas in patients with CAD, the diagnoses of a photoallergic reaction, airborne contact dermatitis, mycosis fungoides, and chronic atopic eczema should be ruled out.

Prevention & Therapy

Photoprotection is the mainstay of treatment in all photodermatoses. To recommend to use protective

clothing and sunscreen covering the action spectrum of the dermatoses (UVA in phototoxicity and visible light in solar urticaria (SPF 30 provides same protection as avoiding sunlight).

Recommend discontinuation of topical or systemic drugs. Topical steroids and antihistamines can be used for symptomatic relief. Any underlying primary illness (e.g. collagen vascular diseases) should be treated. Preventive UV phototherapy and/or psoralen plus UVA (PUVA) may be useful in some cases.

High-potency topical corticosteroids or even short courses of oral corticosteroids are helpful in symptomatic patients. Other possible systemic treatments for chronic, refractory cases: antimalarials or immunosuppressive drugs such azathioprine, ciclosporin, mycophenolate or thalidomide.

Special

None.

References

- [Yashar SS, Lim HW. Classification and evaluation of photodermatoses. Dermatol Ther. 2003; 16:1-7](#)
- [Gambichler T, Al-Muhammadi R, Boms S. Immunologically mediate photodermatoses: diagnosis and treatment. Am J Clin Dermatol. 2009;10:169-180.](#)
- [Choi D, Kannan S, Lim HW. Evaluation of patients with photodermatoses. Dermatol Clin 2014; 32:267-75.](#)
- [Burfield L, Rutter KJ, Bridie Thompson B, Marjanovic EJ, Neale RE & Rhodes LE \(2023\) Systematic review of the prevalence and incidence of the photodermatoses with meta-analysis of the prevalence of polymorphic light eruption. JEADV, 37:511–520.](#)

1.4 Granulomatus Dermatoses

1.4.1 Sarcoidosis

Grading & Level of importance: B

C.C. Zouboulis, Dessau



ICD-11

4B20

Synonyms

Boeck disease, Besnier-Boeck-Schaumann disease, benign lymphogranulomatosis.

Definition

Systemic granulomatous disease with skin involvement.

Epidemiology

Rare disease. Skin involvement in 20-35% of cases; in 11% skin as first manifestation.

The estimated prevalence in Europe is around 10/100,000 inhabitants, and is significantly higher in northern countries.

Aetiology & Pathogenesis

Still unclear, found worldwide, female > male. It occurs most commonly in young and middle-aged individuals of both genders and all races with Afro-Caribbeans and African-Americans more commonly involved. It is a primary Th1 cell driven disease, however, multiple other T-cell types including Th17, Th17.1 cells, and T regulatory cells are involved. In building up granulomas, maintaining or resolving those a pattern of different cytokines, i.e., transforming growth factor- β (TGF- β), IL-13 and IL-10 are involved.

Signs & Symptoms

Many possible skin findings: brown-violaceous dermal papules, plaques, nodules. Often associated with erythema nodosum. Systemic disease can involve lymph nodes (90%, mostly intrathoracic), lungs (90%), eyes (30%), kidneys, bones, neural system, liver and GI tract.

Localisation

All skin areas can be involved.

Classification

Two standardized outcome instruments—the Sarcoidosis Activity and Severity Index (SASI) and the Cutaneous Sarcoidosis Activity and Morphology Instrument (CSAMI).

Special forms:

- Löfgren's syndrome (acute onset of fever, bilateral hilar lymphadenopathy and erythema nodosum, 5%).
- Lupus pernio (centrofacial skin involvement).
- Scar and tattoo sarcoidosis.
- Rare forms, e.g. Heerfordt's syndrome (uveitis, parotid gland swelling, chronic fever, occasionally palsy of the facial nerve, 1%).

Laboratory & other workups

- Angiotensin converting enzyme (ACE; indicating cumulative involvement) and interleukin 2 receptor (IL2R; indicating disease activity) in serum sometimes elevated
- Hypercalcaemia
- Lymphopaenia
- ESR elevated
- Impaired delayed (type IV) hypersensitivity
- Tuberculin skin test (negative)
- Chest x-ray (may show bilateral hilar lymphadenopathy or interstitial changes)

Dermatopathology

Epithelioid cell granulomas without caseation, few CD4+ T lymphocytes (naked granulomas).

Course

Chronic, spontaneous remission (25%).

Complications

Restrictive lung disease, immune suppression (lymphopenia), osteoporosis (in corticosteroid-treated patients and avoidance of calcium supplementation), cutaneous calcification (calcinosis cutis).

Diagnosis

Clinical features, histology, laboratory findings.

Differential Diagnosis

Tuberculosis, leprosy, granuloma annulare, necrobiosis lipoidica, lymphoma, leishmaniasis, syphilis, rosacea (lupus pernio).

Prevention & Therapy

Prevention of occupational and individual chronic small particle inhalation

- Skin involvement: Corticosteroids (topical, intralesional, systemic; first line), methotrexate (secondline), chloroquine/hydroxychloroquine, (isotretinoin, allopurinol, thalidomide), PUVA
- Systemic involvement: Corticosteroids (systemic; first line), methotrexate (second line), azathioprine, (leflunomide, mycophenolate mofetil, cyclophosphamide), TNF antagonists. JAK inhibitors are one of the most important potential therapeutic agents for sarcoidosis currently under investigation. Some biologics may induce sarcoidosis.

Special

Sarcoidosis is probably one of the systemic diseases in which the environment has the greatest influence on the disease development (people with specific occupations).

References

- [Sarcoidosis. Sanchez M, Haimovic A, Prystowsky S. Dermatol Clin 2015 Jul;33\(3\); 389-416.](#)
- [Wu JH, Sotonye Imadojemu S & Avrom S. Caplan AS \(2022\) The Evolving Landscape of Cutaneous Sarcoidosis: Pathogenic Insight, Clinical Challenges, and New Frontiers in Therapy. American Journal of Clinical Dermatology 23 :499–514](#)

1.4.2 Granuloma annulare

Grading & Level of importance: C



M. Bagot, Paris; G. Dobos, Paris; A. de Masson, Paris, F. Rongioletti, Milan

ICD-11

EE80.0

Synonyms

None.

Definition

Granuloma annulare is a granulomatous dermal and / or subcutaneous disorder characterised by infiltrating mononuclear cells that presents with skin-coloured or reddish, annular or papular lesions related to different aetiologic background.

It is more common in children, young adults and people with diabetes mellitus.

Epidemiology

Granuloma annulare is a common skin disorder. Prevalence is 0.1% to 0.4%, annual incidences 0.1% to 0.4%, women more affected than men, and 2/3 of the patients are less than 30 years old.

Aetiology & Pathogenesis

The cause of granuloma annulare is unclear. It can be associated with autoimmune diseases or diabetes mellitus. Granuloma annulare can be caused by a large number of certain drugs. Disseminated forms have been described in association with HIV infection or cancer (solid cancers or haematological malignancies). Other comorbidities are significant associations with hyperlipidemia, rheumatoid arthritis (RA), and systemic lupus erythematosus (SLE).

Signs & Symptoms

Granuloma annulare consists of localized or disseminated firm, small, skin-coloured or reddish papules arranged in rings or arcs, or hard, mobile, dermal and subcutaneous nodules.

Generally, there are no associated symptoms and the size of the lesions is only a few centimeters. It may

be localized or generalized (disseminated).

Localisation

Granuloma annulare typically appears on the extensor surfaces of the extremities (especially fingers and dorsum of hands). In its disseminated form, the trunk is also often involved.

Classification

The lesions can present as localized, disseminated, subcutaneous, perforating types or patch-type.

Laboratory & other workups

In isolated granuloma annulare no laboratory testing is needed. In disseminated granuloma annulare, HIV serology, complete blood count, hyperglycemia and lipid profile may be tested. Autoimmune diseases and cancers can be looked for, depending on the clinical context. Unusual courses and clinical aspects of the disease need histological confirmation.

Dermatopathology

Granuloma annulare is characterized by bundles, degenerative collagen bundles (necrobiosis) with a peripheral cuff of lymphocytes and histiocytes and a palisadic organisation of the granuloma (palisading pattern). The interstitial pattern is characterized by histiocytes between collagen bundles with mucin deposition in the superficial and mid dermis.

Course

Granuloma annulare is skin-limited, it can disappear spontaneously without scarring but recurrences are possible. A chronic evolution is possible. The treatment of disseminated chronic forms is difficult.

Complications

There are no complications, except for granuloma annulare associated with an underlying disease. In rare subsets, a perforating course of the lesions can be seen.

Diagnosis

The diagnosis is obtained by clinicopathological correlation.

Differential Diagnosis

Sarcoidosis, necrobiosis lipoidica, foreign body granuloma, rheumatoid nodules, interstitial granulomatous dermatitis, tuberculoid leprosy, syphilis are the differential diagnoses of granuloma annulare.

Prevention & Therapy

Therapeutic abstention except detection of underlying disease or psychoreactive reactions, topical corticosteroids, topical calcineurin inhibitor or cryotherapy are possible in limited forms.

In disseminated forms, phototherapy, dapsone, retinoids, hydroxychloroquine and TNF alpha blockers can be considered. Recently, TNF alpha antagonist (adalimumab) have been reported to be very successful. In the disseminated and polyarthritis-associated types, treatment with biologics. The treatment of these disseminated forms is generally difficult. Strong regulation of diabetic metabolism is mandatory. Rheumatic diseases must be treated with appropriate medications.

Preventive measures are not possible.

Special

None.

References

- [Granuloma Annulare: An Updated Review of Epidemiology, Pathogenesis, and Treatment Options. Hwang E, Abdelghaffar M, Shields BE, Damsky W \(2023\) Molecularly Targeted](#)
- [Therapies for Inflammatory Cutaneous Granulomatous Disorders: A Review of the Evidence an;3\(5\):100220.](#)
- [Joshi TP, Duvic M. \(2022\) Granuloma Annulare: An Updated Review of Epidemiology, Pathogenesis, and Treatment Options. Am J Clin Dermatol. 23\(1\):37-50.](#)

1.5 Papulosquamous Disorders

1.5.1 Psoriasis

Grading & Level of importance: B

H. Gollnick, Magdeburg; F. Rongioletti, Milan



ICD-11

EA90

Synonyms

Psoriatic Disease (PsD).

Definition

Psoriasis is a common chronic auto-inflammatory and auto-immune skin disease with a different spectrum of clinical phenotypes. It results from the interplay of genetic, epigenetic, environmental, and immunological factors. Psoriasis is a systemic disease associated with co-morbidities from the psychological, metabolic, arthritic, and cardiovascular sites. Life expectancy is reduced as a consequence.

Epidemiology

Psoriasis affects about 125 million people worldwide. About 2-4% of the population in western countries are psoriatic patients with different degrees of clinical manifestation. The prevalence rates are influenced by genetic background, age and geographic as well as environmental factors. Prevalence is higher in adults (from 0.9% to 8.5%) as compared with children (from 0% to 2.1%) with a dual peak of incidence: 30–39 years (type I) and > 40 years of age (type II). In adults, the incidence of psoriasis varies from 30.3 per 100, 000 person years (95% CI 26.6 to 34.1) in Taiwan to 321.0 per 100, 000 person years in Italy. The prevalence of psoriasis varies from 0.14% in east Asia to 1.99% (0.64% to 6.60%) in Australasia. The prevalence of psoriasis is also high in Western Europe (1.92%, 1.07% to 3.46%), Central Europe (1.83%, 0.62% to 5.32%), North America (1.50%, 0.63% to 3.60%), and high income southern Latin America (1.10%, 0.36% to 2.96%). Age stratification within gender shows a higher incidence in females, 18 years old, and conversely a lower incidence in males 18 years old. About 20-30% of psoriatic patients develop sero-negative arthritis. In 2014 the World Health Organization recognised psoriasis as a serious non-communicable disease (WHO report 2016) belonging to the ten most important chronic diseases.

Aetiology & Pathogenesis

There is evidence from genetic studies that susceptibility to psoriasis involves both the adaptive and innate immune system. Activation of both is found in psoriatic skin. While adaptive immune responses predominate in chronic plaque psoriasis, innate and auto-inflammatory responses dominate in pustular forms of psoriasis.

- **Lesion course runs from initiation to propagation to resolution.**
- Psoriasis shows a **polygenic inheritance**. Genome-wide association studies report that the histocompatibility complex HLA-C*06:02 (previously known as HLA-Cw6) is associated with early-onset psoriasis and guttate psoriasis. This major histocompatibility complex is not associated with arthritis, nail dystrophy or late-onset type II psoriasis. PSORS1 in the HLA-C region is located at chromosome 6p21.3. There are 15 so-called PSORgenes.
- Genotype and exogenous factors (e.g. local effects like Köbner's phenomenon or systemic ones) are responsible for the phenotypic expression.
- **Psoriasis is multifactorial but a IL23/IL-17 axis centric disease with IL-36 feed forward amplification.** It is classified today as an **immune-mediated inflammatory disease (IMID)**. Pathomechanisms show that **Th17 cells play a key role**. Th17 development is under control and maintained by interleukin IL-23 mainly produced by dendritic cells. Null-Th17 cells, however, produce various cytokines, including IL-17A, IL-17F and IL-23, IL-22. IL-17A and IL-22 induce not only keratinocyte proliferation, but also tumor necrosis factor (TNF)- α . TNF- α accelerates the infiltration of inflammatory cells including lymphocytes, monocytes and neutrophils from the peripheral blood into skin followed by dendritic cell activation. The levels of Th1 cytokines, such as gamma-interferon (IFN- γ), tumor necrosis factor- α (TNF- α) and interleukin IL-12, are elevated in psoriatic lesions, while increased expression of Th2 cytokines (IL-4, IL-5 and IL-10) is not observed. IL-23p19 and IL-12p40 (IL-12/23p40) are overexpressed in psoriatic skin lesions. The more IL-36 is produced in the lesion course the more neutrophilic cells invade and pustular patterns develop. In addition, antimicrobial peptides are overexpressed in psoriatic skin lesions, and the antimicrobial peptide, LL-37, activates dendritic cells, which leads to the development of inflammation. Furthermore, activation of nuclear factor-kappa B signal induces the expression of keratins 6 and 16 in keratinocytes, which are associated with acanthosis and reduced turnover time in the epidermis.
- The interaction between the epidermis and immune system, specifically T-lymphocytes and cytokines (TNF- α , IL2, IL8) leads to epidermal hyperkeratosis with abnormal differentiation of the epidermis.
- Provocation factors are closely related to manifestation and course of the disease: physical, chemical and metabolic factors. Certain inflammatory diseases (dermatoses) and medications (lithium, chloroquine, beta-blockers, interferon- α), infections (streptococci, HIV) and stress provoke or maintain the disease.

Signs & Symptoms

- Common symptoms of psoriasis include intense itch, pain and scaly skin lesions that can crack and bleed. Predilections are often scalp, elbows and knees and rima ani as well. The following signs (so called Koebnerization effects) can help to confirm a psoriatic lesion:
- Candlesign: Production of candle-grease-like scale when scraping a plaque with curette.
- Auspitz sign: appearance of punctate bleeding when psoriasis scales are scraped away.

Certain features are mostly or often to be seen:

- Circumscribed erythematous plaques with silvery scales of different size and thickness ranging from guttate to large geographic like lesions.
- Pustules may appear on site of lesions or primarily (pustular psoriasis)
- Pitted nails or yellowish discolouring (oil patch) and / or dystrophic nails.
- Palmo-plantar hyperkeratosis
- Often gyrate pattern on the tongue

Localisation

Sites of predilection are: extensor surfaces (knees, elbows), scalp, retroauricular, sacral, gluteal cleft, umbilicus, genital, intertriginous areas (psoriasis inversa), palmo-plantar.

Classification

Historically, disease classification has been based on clinical appearance, mainly differentiating according to localization and morphology. The recent last classification proposed by the International Psoriasis Council identifies four main forms of psoriasis:

- a. plaque-type, b. guttate, c. general pustular psoriasis (GPP), and d. erythroderma. In addition, several further sub-phenotypes according to distribution (localized vs. widespread), anatomical localization (flexural, scalp, palms/soles/nail), size (large vs. small) and thickness (thick vs. thin) of plaques, onset (early vs. late), and disease activity (active vs. stable) are classified.

Another classification of clinical manifestations:

- Type I psoriasis <40 years, HLA system associated
- Type II psoriasis >40 years
- Clinical variants: guttate psoriasis (acute exanthematous), plaque-type psoriasis (chronic, unstable or static)

- Special forms:
 - Psoriatic erythroderma
 - Pustular psoriasis
 - Generalised pustular psoriasis, Zumbusch type
 - Psoriasis with acute pustules (sudden erupting pustules in pre-existing psoriasis vulgaris).
 - Acral pustular disorders: Palmoplantar pustulosis (PPP), Acrodermatitis continua, Hallopeaustype
 - Special type: Impetigo herpetiformis
 - Psoriatic arthritis (HLA-B27): different sub-phenotypes with localization at vertebrae, iliosacral joints, fingers

Laboratory & other workups

Currently, there is no specific blood test for psoriasis. However, according to co-morbidities, laboratory workup including differential CRP, blood count, kidney-, liver- and lipid values may be examined. Others include tests for hypertension, tachyarrhythmia, diabetes mellitus, gout and/or quality of life questionnaires. Association with inflammatory bowel disease should be ruled out. A skin biopsy should be taken if uncertain type of lesions occurs or other differential diagnoses have to be excluded.

Dermatopathology

At a first glance, confluent parakeratosis and hyperkeratosis with intracorneal neutrophils (Munro microabscesses) can be observed. Regular acanthosis is waving with thickening of the rete ridges or reduced layers above papilla. Elongation and widening of the papillary spiral like formed capillaries. A strong lympho-mononuclear inflammatory infiltrate mixed with neutrophilic granulocytes is underlying the epidermis.

Course

In general, the course is chronic-recurrent or chronic-persistent.

Acute eruptions such as the guttate forms sometimes clear with complete resolution (streptococcal infection, drug cessation). Chronic plaque like forms may suddenly show exacerbations with disseminated guttate lesions or becoming more inflammatory and growing in size. Certain drugs (i.e. β -blocker, ACE's, lithium, chloroquine) and infections (i.e. streptococci, HIV, syphilis, mycoses, yersinia) or contact allergens (nickel, chromate, epoxides) may trigger the lesions. Patients with psoriasis in general

have a higher incidence rate of serious infection compared with those without psoriasis. Both, drugs and infections may initiate, trigger, exacerbate or maintain psoriasis courses.

Complications

Because of co-morbidities psoriasis is associated with a reduced life span. In particular, chronic widespread courses and specific localisations such as face, hands, scalp and genitalia reduce the quality of life. Chronic scalp involvement may lead to hair loss and scarring. Nails can produce disabling features and may become infected with dermatophytes or with other mycotic types. Non-melanoma skin cancer can arise in patients long-term treated by natural or artificial UV-light (photochemotherapy) or cytotoxic agents. Systemic cancer incidence shows a small risk of increase and is associated with severe type and long-term courses and co-morbidities. Lung cancer and CTCL type of lymphoma are statistically relevant but not colon, breast or prostate cancer.

Diagnosis

Usually, the clinical features make a diagnosis possible. If not fully clear, histological examination is necessary.

Differential Diagnosis

The most difficult to differentiate are pityriasisiform or guttate like lesions such as in secondary syphilis, pityriasis rosea, in those of the parapsoriasis group, in pityriasis rubra pilaris and in cutaneous T-cell lymphoma. Chronic nummular eczema, hypertrophic lichen planus, tinea corporis, pemphigus foliaceus, glucagonoma syndrome, or chronic and subacute lupus erythematosus are a second group which can mimic psoriatic lesions. On the face, seborrhoeic dermatitis has often to be differentiated and an overlap of both called seborrhiasis.

Prevention & Therapy

Prevention

In general, there is no primary prevention. Secondary preventions are related to avoidance of infectious triggers, drug provocation, mechanical Koebnerization, daily moisturizing of the skin and avoiding of stress and reactive depressive mood swings. Diets are evidenced based. Patient associations can give help.

Therapy

In general, the type of psoriasis, acute or non-acute, localisation, age and profession, adherence and quality of life, co-morbidities and additional arthritis, all have to be considered individually in each patient.

Topical therapy

Topical therapy is indicated when less than 10% of body surface is involved or PASI score is <10.

However, certain localisations such as face, scalp, nails and hands may lead to combined topical and systemic modalities including UV light sources.

- Salicylic acid in varying concentrations depending on localisation and age (cave resorption in childhood)
- Dithranol 0.03-2% in vaseline or zinc paste (overnight or minute therapy)
- Topical corticosteroids, especially higher potency
- Vitamin D3 and its analogues (calcipotriol, tacalcitol)
- Combination of betamethasone and calcipotriol
- Vitamin-A acid derivatives (tazarotene gel)
- Crisaborole (PDE4 inhibitor)
- UV light therapy regimen such as photo bath therapy 15% NaCl + UVB; Phototherapy (UVA +) UVB/narrow band UVB 311 nm;

Photochemotherapy: 8-(5-) MOP + UVA (PUVA) via a topical cream, via full skin surface bathing (bath PUVA) or systemic oral intake.

A topical aryl-hydrocarbon inhibitor (topinarof) is already launched in the US market.

Systemic treatment:

To qualify for systemic therapy, patients must meet one or more of the following criteria according to the most recent recommendations of the International Psoriasis Council:

1. Psoriasis lesions on 10% or more of their body surface or
2. Psoriasis lesions on sensitive areas of the body (i.e. hands/feet, face, genitals, scalp) or
3. Topical therapy failed to control symptoms.

Scoring systems such as PASI score and QoL are additionally used.

1. Methotrexate oral or subcutaneous
2. Retinoids e.g. acitretin
3. Ciclosporin (A)
4. Fumarates
5. Biologics

anti-TNF alpha agents (adalimumab, etanercept, infliximab) and biologics directly target certain

important pathphysiologic molecules such as anti-IL-12/23p40 antibodies (ustekinumab), IL-23 tildrakizumab, guselkumab, risankizumab), IL-17A (brodalimumab, ixekizumab, secukinumab and bimekizumab against 17A and B). Other targets are the phosphodiesterase 4 (PDE 4) inhibited by apremilast. Aryl hydrocarbon receptor (AhR)-modulating topical agents (tapinarof) and topical phosphodiesterase-4 inhibitor (roflumilast) have been recently approved by FDA for the topical treatment of psoriasis. Furthermore, new classes of TYK-2/ JAK-inhibitors (1-3) such as abrocitinib, deucravacitinib, brepocitinib are becoming currently available.

Special

The clinical features of psoriasis have a large varying spectrum of manifestations and co-morbidities. Therefore, despite its nature as a predominantly skin-centred disease, an interdisciplinary approach is recommended. Psoriatic arthritis is not specifically described in this chapter.

References

- [CEM Griffiths, AW Armstrong, JE Gudjonsson, J NWN Barker. Psoriasis. Lancet April 3, 2021; 397: 1301-15.](#)
- [Keiichi Yamanaka, Osamu Yamamoto , Tetsuya Honda \(2021\) Pathophysiology of psoriasis: a review J Dermatol. 48 \(6\):722-731](#)
- [Wu W, Gao N, Han J, Zhang Y & Fang X \(2023\) Efficacy and Safety of Newer Topical Therapies in Psoriasis: A Systematic Review and Network Meta-Analysis. Dermatology ,doi.org/10.1159/000535056](#)

1.5.2 Pityriasis Lichenoides

Grading & Level of importance: B



H. Gollnick, Magdeburg

ICD-11

LB16

Pityriasis lichenoides chronica (PLC): LB161

Pityriasis lichenoides et varioliformis acuta (PLEVA): LB160

Synonyms

PLEVA: Mucha-Habermann disease.

PLC: Jadassohn Juliusberg disease.

Definition

Pityriasis lichenoides is a disease with acute, subacute and chronic course with primarily benign proliferation of helper- and cytotoxic T-cells (reactive and /or inflammatory proliferative disease).

Epidemiology

Around 29% show the subtype of pityriasis lichenoides chronica et varioliformis acuta (PLEVA), 67% the subtype pityriasis lichenoides chronica (PLC) and in 4% a mixed type. The prevalence is around 20:100,000 cases and there are two prevalence peaks in pre- and school-age and around the fifth life decade.

Aetiology & Pathogenesis

A clear pathogenesis of both subtypes of pityriasis lichenoides is not known. It shows a parainfectious course associated with upper respiratory or gastro-intestinal infections with preferentially Epstein-Barr, HIV-, CMV-, Parvo B19- and Varicella virus. Other infectious microbes reported are staphylococci and streptococci or Toxoplasma gondii. In more than 20% of cases in childhood, a post-infectious course can clearly be found. However, similarities with lymphomatoid papulosis have given evidence of a clonal and oligoclonal expansion of CD5/7/30 positive and CD4 dominated cell type in PL. Some evidence exists that in the acute type, the main driving cells are of the cytotoxic T-type. Furthermore, chimeric maternal keratinocytes could be found in biopsy material of the epidermis giving rise of a GVHD like pattern.

Signs & Symptoms

PLEVA: First at the trunk small or 5-10mm red macules, then papulosquamous and papulo-vesicular lesions develop and progress over weeks. Hemorrhagic lesions develop into necrotic ones. A varioliform-like scarring pattern can stay as a consequence. Often the disease is accompanied by pruritus, sometimes fever and arthralgias. In a very few number of cases, an ulcero-necrotic course of PLEVA (more in males) can be observed (UNMHD). This ulcero-necrotic course can become disastrous with high fever and involvement of mucous membranes in the oral, conjunctival and genital area with **bacterial or viral** superinfection. Splenomegaly, diarrhea, pneumonia, central-nervous symptoms, arthritis, sepsis and death can be observed.

PLC: Predominant are 2-10 mm round or oval, brownish-red papules with a small quite adherent squames at the center. During resolution of lesions, a leukoderma can persist.

Localisation

Both subtypes show a preference for trunk > extremities.

Classification

- PLEVA: acute and subacute pityriasis lichenoides and varioliformis acuta (Mucha- Habermann disease).
 - subtype ulcero-necrotic (UNMHD type).
- PLC: pityriasis lichenoides chronica (Jadassohn – Juliusberg disease).
- Mixed Type.

Laboratory & other workups

Laboratory investigations for infections (upper respiratory and gastro-intestinal tract), differential blood count, biopsy and depending on the severity of course, other organs to be examined.

Dermatopathology

Depending on acuity.

- PLEVA: Focal hyper- and parakeratosis sometimes including neutrophilic granulocytes; spongiosis in the epidermo- papillary zone and exocytosis of lymphocytes into the basal layer resulting in an interface dermatitis and vacuolated keratinocytes; apoptosis of single keratinocytes, but dominant and increasing with necrotic course of the disease; strong perivascular lymphocytic (wedge shaped) infiltrate in the dermis and extravasation of erythrocytes including into the epidermis.
- PLC: Like in PLEVA, but less prominent

Course

Both types of pityriasis lichenoides last several weeks and months and can even be observed up to two years. In childhood up to 80% relapses can be observed.

Very rare transformation to malignant T-cell lymphoma.

Complications

In the chronic PL type usually none. However, PLEVA often results with small hypopigmented macules or varioliform scars. The FUMHD type can have deep scar lesions left. In the worst course of disease without appropriate intervention, death may occur (mostly due to cardiac complications).

Diagnosis

The diagnosis in PL is clinical and can be substantiated by a biopsy. In PLEVA the diagnosis is also clinical, but due to differential diagnosis a biopsy should be performed.

Differential Diagnosis

- Psoriasis guttata
- Parapsoriasis
- secondary syphilis
- pityriasis rosea
- varicella
- vasculitis, Gianotti-Crosti-syndrome, drug reaction

Prevention & Therapy

No prevention.

Depending on course of disease, age and comorbidity.

Skin care, prevention of superinfection; erosive lesions may be treated topically with combined anti-microbial-glucocorticosteroid (class II-III) cream, pimecrolimus or tacrolimus. Phototherapy in PL can be considered. Severe courses with necrosis progress and fever and mucous membrane involvement should be treated immediately with methotrexate plus corticoid high dose pulse therapy. Other complicated courses should be treated in addition with erythromycin or azithromycin.

Special

None.

References

- [Bellinato et al. A systematic review of treatments for pityriasis lichenoides J Eur Acad Dermatol Venereol. 2019, 33\(11\):2039-2049](#)
- [Bowers S & Warshaw EM \(2006\) Pityriasis lichenoides and its subtypes J Am Acad Dermatol 2006 55\(4\):557-72](#)

1.5.3 Pityriasis rubra pilaris

Grading & Level of importance: C



H. Gollnick, Magdeburg

ICD-11

EA94; ORPHA:2897

Synonyms

Lichen acuminatus; M. Divergie.

Definition

Chronic inflammatory papulo-squamous skin disease with a spectrum of several clinical phenotypes.

Epidemiology

Rare papulo-squamous disease. 1:5000 of dermatologic cases in UK. Population based prevalence is unknown. Pityriasis rubra pilaris (PRP) may occur in any ethnic group; males and females are equally affected.

Aetiology & Pathogenesis

Susceptibility to PRP. No clear genetic background exists, however, the fact that type 5 occurs after birth suggests a genetic predisposition. The genetic basis for familial cases, most commonly categorized under the fifth subtype. It has been mapped to gain of function mutations in the caspase recruitment domain family, member 14 (CARD14) gene (chromosome 17q25.3). It is occasionally precipitated and aggravated or even maintained by infections or drugs such as sorafenib, insulin, imatinib, telaprevir, and vaccinations.

Signs & Symptoms

Pityriasis rubra pilaris usually presents with reddish-orange coloured tiny pinpoint elevated and to the follicular opening bound, small and large scaly patches with well-defined borders. Sometimes the involvement of palms and soles may be painful because of fissures. Lesions may cause a burning sensation.

Localisation

Lesions may cover the entire body including erythrodermic courses or may be localized such as at the elbows and knees, palms and soles. Often there are areas of uninvolved skin, particularly on the trunk and limbs, which are referred to as nappes claires. The palms and soles are usually involved and become diffusely thickened and yellowish and mimic psoriasis, chronic palmo-plantar eczema or keratodermas. The atypical adult type 5 may also show ichthyosis-like lesions, the circumscribed juvenile type shows involvement of knees and elbows exclusively.

Classification

The most recent classification identifies six main forms of pityriasis rubra pilaris:

- Type 1: classical adult-onset
- Type 2: atypical adult-onset
- Type 3: classical juvenile-onset
- Type 4: circumscribed juvenile
- Type 5: atypical juvenile-onset
- Type 6: HIV - associated

Laboratory & other workups

No specific blood tests are recommended. Biopsy may be required.

Dermatopathology

In the microscopic specimen one sees vertical and horizontal alternating areas with ortho- and parakeratosis (checker board pattern), waving hypergranulosis, thickened suprapapillary plates, broadened rete ridges and a circumscribed non-prominent, superficial perivascular infiltrate. A diagnostic clue is that of follicular hyperkeratotic plugs.

Course

Average disease course in about 57 % of patients was one year or less.

- Type 1 accounts for 50% of all cases and has a good prognosis with the majority of cases going into spontaneous remission within 2- 3 years. There is some evidence of association with underlying malignancy.
- Type 2 accounts for about 5% of all cases and shows long persistence of up to 20 years.
- Type 3 accounts for about 10% of all cases and shows early onset between 5 and 10 years old.

It can follow acute streptococcal or viral infections and often shows remission in the first year.

- Type 4 accounts for about 25% of all cases and occurs in prepubertal children with a specific pattern confined to palms, soles, knees and elbows. No clear time of course.
- Type 5 accounts for about 5% of all cases. Inheritance is discussed. Occurs already at birth or early in childhood and shows long-term persistence. CARD14 variants are seen as a predisposing factor to autoinflammatory keratinization in juvenile PRP.
- Type 6 is very rare. No predictable course and refractory to common treatments. May improve with HIV treatment.

Complications

None except erythrodermic courses and type 1 associated with an underlying malignancy disorder

Diagnosis

Clinical features and histopathology in unclear cases.

Differential Diagnosis

- In particular, juvenile and adult psoriasis and other types of erythroderma. Pityriasiform or guttate like lesions such as in secondary syphilis, pityriasis rosea, in those of the parapsoriasis group, and in cutaneous T-cell lymphoma.
- Chronic nummular eczema, hypertrophic lichen planus, chronic palmo-plantar eczema
- Phrynoderma, Keratosis follicularis, Darier's disease

Prevention & Therapy

Prevention

Avoidance of aggravating factors

Therapy

In general, depending on the PRP subtype. Topical therapy is not evidence-based by supporting trial data.

- Topical therapy is indicated depending on lesion type and amount of body surface area.
- Topical corticosteroids, especially mid to higher potency.

- Vitamin D3 and its analogues (calcipotriol, tacalcitol).
- Combination of betamethasone and calcipotriol.
- Vitamin-A acid derivatives (tazarotene gel).
- UV light therapy regimen such as photo bath therapy 15% NaCl + UVB.
- Phototherapy (UVA +) UVB/narrow band UVB 311 nm.
- Photochemotherapy: 8-(5-) MOP + UVA (PUVA) via local cream, via full skin

Systemic treatment:

To qualify for systemic therapy the PRP must be widespread. No evidenced based data are existing to support any of the following therapeutics, therefore off-label indications are common. If topical therapy fails to control symptoms consider:

1. Methotrexate oral or subcutaneous.
2. Azathioprine
3. Retinoids, i.e. acitretin, isotretinoin, alitretinoin
4. Ciclosporin
5. Fumarates
6. Biologics such as TNF alpha inhibitors, ustekinumab, secukinumab


Special

None.

References

- [D Wang, VCui-Lian Chong, WS Chong, HH Oon. \(2018\) A review on Pityriasis Rubra Pilaris. American Journal of Clinical Dermatology volume 19, pages 377–390](#)
- [Akiyama M, Takeichi T, McGrath JA, Sugiura K. Autoinflammatory keratinization diseases. J Allergy Clin Immunol. 2017;140\(6\):1545-1547.](#)

1.5.4 Lichen planus

Grading & Level of importance: B 
C.C. Zouboulis, Dessau; F.Rongioletti, Milan

ICD-11

EA91

Synonyms

None.

Definition

Idiopathic subacute to chronic inflammatory dermatosis involving the skin, mucosae, nails and/or hair.

Epidemiology

Prevalence between 0.1 to 4%, with most cases occurring between 30 to 60 years of age, and with a slight predominance in peri-menopausal women.

Aetiology & Pathogenesis

Very likely it is an autoimmune disorder, thus associations with collagen-vascular diseases, vitiligo and diabetes mellitus are not surprising. Graft-versus-host-disease (GvHD) has similar morphology. Hepatitis B and C, stress and various drugs may also play a role in its induction in some cases. T-cells accumulate in the upper dermis belonging to the CD4+ and CD8+ subtypes. Tcells, both CD4+ and CD8+, accumulate in the dermis. Via secretion of several cytokines apoptosis of basal epidermal cells appear. IFN γ drives the disorder, thus defining LP as a Th1 dominated disorder.

Signs & Symptoms

- Five P disease (Pruritic, purple, polygonal, planar papules),
- Skin: polygonal violaceous papules, white net-like superficial markings (Wickham's striae) marked pruritus.
- Mucosae: lips, tongue, cheeks, genital and anal areas (annular, bullous, erosive, atrophic), net-like white, non-removable pattern.

- Nails: non-specific changes (longitudinal stripes, trachyonychia) but also scarring (pterygium formation, atrophy, anonychia).
- Scalp: lichen planopilaris /lichen planus follicularis decalvans (atrophic scarring alopecia; pseudopelade).
- Palmoplantar: hyperkeratosis (fissured).

Localisation

Flexor aspects of wrists, nails, oral and genital mucosae.

Classification

Types:

- Lichen planus exanthematicus -> erythroderma (exfoliative dermatitis)
- Hypertrophic lichen planus (lichenification because of chronic rubbing, especially on shins)
- Annular or linear lichen planus
- Lichen planus pigmentosus
- Nodular lichen planus
- Atrophic lichen planus (confluent, widespread involvement)
- Lichen planus pemphigoides (with antibodies to basement membrane zone)
- Erosive lichen planus (bullous, without antibodies)
- Actinic lichen planus (hyperpigmentation in sun-exposed sites of individuals of colour).

Laboratory & other workups

Increased Interleukin-6 (IL-6) in serum (not tested on routine basis).

Dermatopathology

Irregular acanthosis, saw-toothed dermal-epidermal junction profile, hypergranulosis, apoptotic keratinocytes, subepidermal interface band-like infiltrate of T lymphocytes, pigment incontinence.

Course

Lichen planus of the skin often resolves after a few months or years, although it may recur. If caused by medication or fillings, lichen planus will clear after the treatment is stopped or the fillings removed. Lichen planus of the mucosa, nails, and scalp rarely clears by itself and can cause permanent scarring.

Complications

Erosive lichen planus of the mucosae can lead to squamous cell carcinoma, making follow-up essential.

Diagnosis

Clinical features, histology, Köbner phenomenon.

Differential Diagnosis

Lichenoid drug reactions: Skin eruptions caused by commonly used medications can resemble lichen planus. Histopathology shows parakeratosis and eosinophils. Quinine in tonic water and over-the-counter leg cramp medicines can cause a lichen planus–like condition. In the mouth, allergy to the metals in fillings and oral appliances can cause sores that look exactly like oral lichen planus.

Prevention & Therapy

Prevention: Control of predisposing factors.

- Topical: high potency corticosteroids, calcineurin inhibitors (mucosal disease; strong evidence), tazarotene, calcipotriol, UVA/B, PUVA, UVA1.
- Systemic: corticosteroids (moderate evidence), PUVA, dapsone, hydroxychloroquine, methotrexate, mycophenolate mofetil, acitretin, alitretinoin, ciclosporin, azathioprine, apremilast, sedatives, (enoxaparin, antimycotics).

Special

TNF blockers exhibit fairly controversial effects in lichen planus, since they can trigger pro-inflammatory reactions: TNF-alpha inhibitors may precipitate lichenoid reactions through disruption of a delicate balance between TNF-alpha and interferon-alpha in susceptible patients.

References

- [Lichen Planus. David L. Arnold, Karthik Krishnamurthy 1 In: Stat Pearls \[Internet\]. Treasure Island \(FL\): Stat Pearls Publishing; 2021 Jan.](#)
- [Solimani F, Forchhammer St, Schloegl A, Ghoreschi K, Meier K \(2021\) Lichen planus- a clinical guide. JDDG ,19\(6\):864-882](#)

1.5.5 Pityriasis Rosea

Grading & Level of importance: B
C.C. Zouboulis, Dessau



ICD-11

EA10

Synonyms

Pityriasis circinata; Gibert pityriasis; Pityriasis rosea Gibert.

Definition

Acute, disseminated, symmetrical papulo-squamous exanthem with typical collarette scale.

Epidemiology

It affects adolescents and young adults (aged 10 to 35 years). Incidence is 0.68/100 dermatology patients, prevalence 0.5-2% with a peak incidence in spring and autumn.

Aetiology & Pathogenesis

The disease was first described by Gibert in 1860. It probably arises as an “id”- reaction to some viral infections (human herpes virus 6 in adolescence or 7 in adults (HHV6/7). Thereafter long-life immunity exists. In HIV immunocompromised patients it can be seen more often and was reported during the corona epidemic quite more often, but more a pattern which was pityriasis rosea -like.

Signs & Symptoms

The initial lesion is a large erythematous (salmon coloured) patch (herald patch, medallion, tache-mère), up to 5 cm in diameter), followed by multiple smaller lesions frequently following skin lines (e.g. Christmas tree distribution around ribs) being thin with a typical collarette scale. Similar long axis orientation for individual patches. Pruritus can occur (50%) and is variable in intensity, especially when skin is irritated (intense washing, drying medications or with simultaneous concurrent dermatitis). In children sometimes a so-called inverse form can occur and manifests in the axillae and the groin region. Post-inflammatory hypopigmentation or hyperpigmentation (lighter or darker patches of skin) can occur. Prodromal symptoms (fever, headache, arthralgia, cough, vomiting, or lymphadenopathy) have been reported in 60% of the patients.

Localisation

Typically, on trunk (occasionally neck and proximal extremities).

Classification

Common disease. Atypical clinical variants can occur.

Laboratory & other workups

Not required, but syphilis should be ruled in adults.

Dermatopathology

Primarily not required. In case of unusual course or atypical pattern. No specific pattern with edema in the stratum papillary, mild epidermal spongiosis and some spotted parakeratosis.

Course

Self-limiting with spontaneous resolution after 4-8 weeks (possibly with hyperpigmentation but no scarring), but some cases can last longer.

Complications

High relapse rate (26% in 4 years).

Diagnosis

Clinical.

Criteria:

- herald patch
- peripheral collarette scales
- predominant truncal and proximal limb distribution of the lesions, and
- orientation of lesions along the lines of cleavage

Differential Diagnosis

Secondary syphilis, drug reactions, tinea, psoriasis, parapsoriasis, nummular eczema.

Prevention & Therapy

No evidence of any preventive measurements or effective treatment. Mild skin care and avoidance of irritating factors. If pruritic, topical anti-pruritic agents: mild corticosteroids or emollients. In selected cases UVB 311nm.

Statins and antihistaminics, which induce a sebostatic effect, may enhance the disease severity.

Special

Relapses can especially occur in pregnancy. If in the 15 first weeks, close follow-up is required due to reported miscarriages.

References

- [Veraldi S., Romagnuolo M, Benzecy V \(2020\) Pityriasis rosea-like eruption revealing COVID-19. Australas J Dermatol. 2020 Nov 20: 10.1111/ajd.13504.](#)
- [Pavel K \(2022\) Pityriasis Rosea Gibert - Disease History and New Findings. Pathology and Laboratory Medicine 6\(1\): 7-10.](#)

1.5.6 Prurigo Simplex

Grading & Level of importance: B

C.C. Zouboulis, Dessau



ICD-11

EC91

Synonyms

Prurigo simplex subacute. Subacute prurigo. Chronic papular dermatitis in adults. Itchy Red Bump disease.

Definition

Group of dermatoses with many causes, all featuring intense pruritus followed by reactive crusted papules (prurigo = itchy crust). Chronic prurigo (CPG) today defined as a neuroinflammatory, fibrotic dermatosis with presence of chronic pruritus (itch lasting longer than 6 weeks), scratch-associated pruriginous skin lesions and history of repeated scratching.

Epidemiology

Rather common disease in aged individuals.

Aetiology & Pathogenesis

Controversial discussed pruritic papular eruption. Prurigo seems to develop in individuals, who overreact to an existing pruritus (itching). Causes: systemic triggers of pruritus, idiopathic.

Signs & Symptoms

Pruritus, papules and excoriations with symmetrical distribution on the extensor surfaces of the extremities, neck, lower trunk, and buttocks. Middle-aged patients, especially women, are affected. Typically, patients present with widespread dome shaped papules, sometimes in a symmetrical distribution, which are intensely itchy.

Localisation

Extremities, trunk (interscapular area is usually spared!).

Classification

Acute, subacute and chronic forms /(intense) itch.

Chronic prurigo of nodular type (CNPG; synonym: prurigo nodularis)

Laboratory & other workups

Serum: glucose, HLA1C (diabetes mellitus in 25%), IgE, (DD: prurigo type of atopic dermatitis), epidermal transglutaminase (DD: dermatitis herpetiformis, rarely).

Blood: Eosinophils (DD: prurigo type of atopic dermatitis), differential blood examination, BSR (DD: haematological disorders, rarely).

PRICK-Test (54% positive).

Psychological/psychiatric examination (67% abnormal).

Dermatopathology

Intraepidermal sero-hemorrhagic vesicle with or without crust, infiltration of lymphocytes, with a few histiocytes and scattered eosinophils in the papillary dermis Proliferation of subepidermal nerve fibres that penetrate epidermis in the healing phase (pruritic).

Course

Chronic, symptoms often persist for months to years.

Complications

Superinfections of excoriated lesions, sleep deprivation. Development of nodules and nodes.

Diagnosis

Clinical features.

Differential Diagnosis

Atopic dermatitis (prurigo variant, late age form), dermatitis herpetiformis and **bullous pemphigoid** (prurigo variant).

Prevention & Therapy

Secondary prevention: Exclude underlying disorders and avoid scratching.

Therapy:

- Topical: corticosteroids, capsaicin cream, phototherapy.
- Systemic: antihistamines.
- Anti-IL31 receptor monoclonal antibodies (nemolizumab), dupilimumab, abrocitinib baricitinib (selective JAK1-and JAK2-inhibitor) and topical ruxolitinib crèmeopioid modulator nalbuphine.

Special

Prurigo simplex and prurigo nodularis seem to be different stages of a common disease.


References

- [HF Ständer, S Elmarhi, C Zeidler, M Spellman, S Ständer. Diagnostic and treatment algorithm for chronic nodular prurigo. J Am Acad Dermatol, 2020; 82\(2\):460-8.](#)
- [Wallengren J \(2021\) Prurigo Simplex or “Itchy Red Bump” Disease: Review and Case Series Acta Derm Venereol. 101\(9\): 235](#)
- [Pereira MP, Hoffmann V, Weisshaar E et al \(2020\) Chronic nodular prurigo: clinical profile and burden. A european cross-sectional study. JEADV 34 : 2373-2383](#)

Chapter 2 – Infectious Diseases

2.1 Viral Infections

2.1.1 Varicella and Herpes Zoster

Grading & Level of importance: A 
V. del Marmol, Brussels; J. White, Brussels

ICD-11

1E90

Synonyms

Chickenpox; shingles.

Definition

Varicella-zoster virus (VZV) causes a primary infection usually in childhood (varicella, commonly known as chickenpox) and may later reactivate in a nerve (herpes zoster, commonly known as shingles).

Epidemiology

Chickenpox is a highly contagious disease (by respiratory or direct contact). Usually affects children between 2 and 10 years of age. Endemic outbreaks in spring and autumn. The incubation period for varicella is between 10-21 days and it is highly contagious, via direct skin contact, or contact with aerosolized particles from the vesicles or respiratory secretions. It is a highly prevalent disease (90% of adults have suffered) and gives permanent immunity.

The incidence of herpes zoster ranges between 1.3 and 4 cases per 1000 individuals / year. More than two thirds of cases occur in individuals over 50 years. 10% of cases of shingles occur in individuals with risk factors (cancer, previous trauma, etc.). Its incidence in immunosuppressed subjects is much higher than the general population.

Aetiology and pathogenesis

VZV is transmitted by the airborne route via coughs, sneezes and sometimes direct contact with the skin of infected individuals. See below for the pathogenesis of herpes zoster.

Signs & Symptoms

The rash is a papulo-vesiculo-pustular exanthem. A helpful diagnostic feature is the presence of lesions in varying stages of development. The patient generally feels unwell, may be pyrexial and is typically itchy.

VZV may be harboured in the spinal and cranial ganglia (Gasserian ganglion, geniculate ganglion) and has a potential to reactivate, causing herpes zoster. Factors which may increase the chance of reactivation include immunosuppression, trauma, sunlight and other severe illnesses. Clinical features are usually typical, with a segmental lesion not crossing the midline. Clinical features may include burning sensations, pain, erythema, blisters, necrosis, scars and post-herpetic neuralgia. Herpes zoster haemorrhagicus, gangrenosus is a severe form with generalised disease resembling varicella with aberrant blisters. Often in the pre-eruptive phase depending on the localization it may mimic symptoms of cardiac infarction, gallbladder or renal attacks, colon pain including ileus symptoms or lumbago or migraine attacks.

Localisation

Varicella commonly affects the head and mouth (gums) with the palms and soles usually spared.

Zoster may potentially affect any dermatome.

Variants: Ophthalmic herpes zoster with reactivation in the 1st trigeminal branch (V1 nerve), sometimes with nasociliary branch. This requires urgent ophthalmology review due to potential keratitis. Aural herpes zoster (VIIIth nerve) affects the acoustic nerve and may cause a facial paralysis.

Classification

Nil.

Laboratory & other workups

Laboratory tests are only required if there is severe involvement or other relevant clinical question. Viral swabs may confirm the diagnosis days later. Immediate confirmation when required may be obtained via Tzanck smear, PCR of vesicle fluid or antigen test.

Dermatopathology

Skin biopsies are almost never required to make the diagnosis. Where taken, intraepithelial apoptosis, necrosis and vacuolated keratinocytes followed by blisters and destruction of sebaceous glands are indistinguishable from other viral infections.

Course

Varicella-zoster is usually a self-limiting disease. Varicella is commonly mild in young children but may be disseminated and severe in adults (especially in pregnancy), very rarely leading to multi-organ failure.

Complications

Varicella may rarely cause pneumonia. Scarring of the skin is common following infection, especially when lesions display secondary infection. Fetal malformations may occur after infection in the 1st trimester; neonatal varicella may occur when infection of the mother is in the 3rd trimester. Herpes zoster may disseminate showing the typical chicken pox lesions. Superadded infection may occur, especially after excoriation. Keratitis is relatively rare. Postherpetic neuralgia may cause long-lasting pain for months or years.

Diagnosis

The diagnosis is usually clinical, but clinical features of early herpes zoster can be misleading and the early features may be mistaken for insect bites or other skin disease.

Differential Diagnosis

The differential diagnosis for varicella includes insect bites, Coxsackie virus infection, generalized herpes zoster, eczema herpeticum, and other viral exanthems. For herpes zoster, the differential diagnosis includes insect bites, herpes simplex or pain from other causes. In the face initial erysipelas or acute phase of contact dermatitis has to be considered as well as on the lower leg.

Prevention & Therapy

Prevention of herpes zoster reactivation can be achieved with immunization but different European countries have different recommendations. Some recommend vaccination in the second year of life; some suggest vaccination only in those not having had chickenpox by the age of 12-14 and some only recommend vaccination in special circumstances. For treatment of active varicella, topical agents include astringents and antiseptics (e.g. chlorhexidine 1% lotion). Systemic treatment options should be considered in certain cases (2) and include antiviral agents (e.g. aciclovir and valaciclovir). Indications for systemic treatment are patients > 50 years, disease present less than 3 days, tendency towards generalization, eye involvement (1st branch of trigeminal nerve) or immunodeficiency. Analgesics or anti-pyretics should be administered as required (NSAIDs, but acetyl salicylic acid is contraindicated because it may be associated with Reyes syndrome) and, in special cases, corticosteroids.

Special

Ask about contacts of the index patient (pregnant individuals, children, immunocompromised).

References

- [Andrei G, Snoeck R. \(2021\). Advances and Perspectives in the Management of Varicella-Zoster Virus Infections. *Molecules*. Feb 20;26\(4\):1132. doi: 10.3390/molecules26041132. PMID: 33672709; PMCID: PMC7924330.](#)
- [Patil A, Goldust M & Wollina U. \(2022\). Herpes zoster: A Review of Clinical Manifestations and Management. *Viruses* 14, 192. <https://doi.org/10.3390/v14020192>. PMID: 35215786; PMCID: PMC8876683.](#)
- [JEADV 2017, 31, 9-19 © 2016 European Academy of Dermatology and Venereology](#)
- [JEADV 2017, 31, 20–29 © 2016 European Academy of Dermatology and Venereology](#)

2.1.2 Herpes Simplex

Grading & Level of importance: A

M. Janier, Paris; V. del Marmol, Brussels; J. White, Brussels



ICD-11

1F00.0

Synonyms

Cold sore; fever spot; herpes; (herpetic) whitlow; HSV.

Definition

Viral infection with herpes simplex virus (HSV) types 1 and 2.

Epidemiology

HSV infection is very common; about 50-90% of the adult population have evidence of previous infection.

Aetiology & Pathogenesis

Lesions on the skin arise from primary or secondary (re-activated) infection with the more common herpes simplex virus, Type 1 (H. labialis), or less frequently, Type 2 (H. genitalis). These DNA viruses are epidermotropic and neurotropic. Transmission is via contaminated surfaces or direct human to human contact. The incubation period is between 2-7 days.

Signs & Symptoms

Painful, grouped (herpetiform) vesicles on an erythematous base quickly evolve into erosions (less often into pustules) with local adenitis. Primary infections commonly affect the mouth (Herpetic gingivostomatitis), but also anogenital areas (Herpes genitalis, herpetic vulvovaginitis). Herpes neonatorum is rare. Recurrences mostly occur around the mouth (herpes simplex labialis, orofacial herpes, Type 1 HSV) or genitalis (Type 2). The eyes may also be affected (herpetic keratitis). Eczema herpeticum is a disseminated HSV infection due to impaired innate immunity because of barrier defects in those with atopic dermatitis. Recurrences usually occurs at the same site as the original lesion, possibly triggered by UV light, stress, hormonal changes or other factors.

Localisation

Any part of the skin, intermediate epithelium or mucous membrane may be infected. The commonest sites include the lips, mouth, fingers, ano-genital skin and buttocks.

Classification

Classification is according to the viral subtypes 1 and 2.

Laboratory & other workups

Tests are not usually required in typical orofacial herpes. Antigen test and Tzanck smear are no longer recommended. Nucleic Acid amplification tests (NAATs) (HSV DNA detection) is widely recommended in genital herpes (primary infection, genital ulceration) with typing HSV-1 /HSV-2. Serological tests (HSV-type specific serologies) are useless in most circumstances.

Dermatopathology

Although not usually required, histology may help to exclude other conditions. Balloon degeneration of keratinocytes in blister may be seen.

Course

The disease is typically self-limiting. However, reactivation may occur with variable periodicity.

Complications

Rare complications include persistent ulceration, eczema herpeticum, secondary bacterial infection, keratitis potentially leading to blindness, viral encephalitis and erythema multiforme.

Diagnosis

The diagnosis is usually clinical, but may be confirmed with laboratory tests in cases of diagnostic difficulty.

Differential Diagnosis

Impetigo, other sexually transmitted infections (STI) causing genital ulcers (syphilis, LGV), aphthous ulcers.

Prevention & Therapy

Therapeutic efficacy relies on prompt treatment. Options include topical agents such as astringents, antiseptics and antivirals. Systemic agents include antivirals (e.g. aciclovir or valaciclovir (500 mg / bid for 5 days). Treatment should be considered depending on symptomatology. Long-term prophylactic therapy can be helpful in those with frequent recurrence of disease.

Special

Beware disseminated infection in those with atopic dermatitis (eczema herpeticum) or those who are immunocompromised. All ano-genital HSV needs investigation for other sexually transmitted diseases.

References

- [Patel R., Kennedy OJ., Clarke E., Geretti, A., Nilsen A., Lautenschlager, S., Green, J., Donders, G., van der Meijden W., Gomberg, M., Moi H. Foley, E. \(2017\). 2017 European guidelines for the management of genital herpes. Int J STD AIDS. 2017;28\(14\):1366-1379. doi: 10.1177/0956462417727194. Epub 2017 Aug 24. PMID: 28836892.](#)
- [Yousuf W, Ibrahim H, Harfouche M, Abu Hijleh F, Abu- Raddad L \(2020\). Herpes simplex virus type 1 in Europe: systematic review, meta-analyses and meta-regressions BMJ Global Health 5: e002388. doi:10.1136/bmigh-2020-002388. PMID: 32675066; PMCID: PMC736Y.](#)

2.1.3 Eczema Herpeticum

Grading & Level of importance: C
E. Gaffal, Magdeburg; M. Janier, Paris



ICD-11

1F00.03

Synonyms

Disseminated virus herpes simplex infection, Kaposi Juliusberg varicelliform eruption, Eczema herpetiforme Kaposi, Pustulosis herpetica infantum, Pustulosis vacciniformis acuta.

Definition

Severe cutaneous infection mostly with herpes simplex virus Type I (HSV- 1). Infections with HSV-2, varizella zoster virus, vaccinia or coxsackie viruses have also been described.

Epidemiology

Eczema herpeticum affects patients at any age with no predilection for gender.

Aetiology & Pathogenesis

Due to their impaired skin barrier function, patients with atopic dermatitis are at highest risk of developing eczema herpeticum. Infection occurs either by autoinoculation (e.g. herpes labialis) or through contact with infected individuals. It may also appear in other diseases e.g. acantholytic diseases (pemphigus, Haile-Hailey and Darier diseases). Eczema herpeticum may also develop after skin burns or cosmetic interventions such as deep TCA peeling or needling.

Signs & Symptoms

Symmetric and generalized eruption of vesicles primarily in areas of severe dermatitis, later developing into pustules, erosions and crusts. Reduced general condition with high fever, headache, marked pruritus, sometimes pain and lymphadenopathy.

Localisation

Usually face, neck and flexures.

Classification

Localized and generalized.

Laboratory & other workups

Non-specific.

Dermatopathology

Intraepidermal vesicles containing ballooning cells, moderate dermal lymphocytic infiltration and edema.

Course

Massive eruption of vesicles and high fever in the beginning. Later vesicles become pustular and erosive. After 4-5 days general symptoms attenuate, mild scarring is possible. Without treatment generalized infection can be lethal.

Complications

Viraemia, superadded bacterial infections, pneumonia, herpetic encephalitis, ocular damage, sepsis.

Diagnosis

History of atopic dermatitis, identification of the virus by PCR.

Differential Diagnosis

Bacterial infection, pre-existing bullous disease, exacerbation of atopic dermatitis, eczema vaccinatum.

Prevention & Therapy

Limited disease can be treated with oral valaciclovir. Disseminated disease requires systemic aciclovir or famciclovir. Superadded infections should be treated with culture-directed antibiotic therapy. Topical therapy includes wet dressings and antiseptics.

Special

None.

References

- [Damour A, Garcia M, Seneschal J, Lévêque N, Bodet C. \(2020\). Eczema Herpeticum: Clinical and Pathophysiological Aspects. Clin Rev Allergy Immunol. Aug;59\(1\):1-18. doi: 10.1007/s12016-019-08768-3. PMID: 31836943.](#)
- [Traidl S, Heinrich L, Siegels D, et al; TREATgermany Study Group. \(2023\). High recurrence rate of eczema herpeticum in moderate/severe atopic dermatitis -TREATgermany registry analysis. J Dtsch Dermatol Ges. Dec;21\(12\):1490-1498. doi: 10.1111/ddg.15205. Epub 2023 Oct 9. PMID: 37814394.](#)

2.1.4 Common Warts

Grading & Level of importance: A
V. del Marmol, Brussels; J. White, Brussels



ICD-11

1E80

Synonyms

Common warts; verruca vulgaris; filiform warts; digitate warts; wart; verruca.

Definition

Warts are a manifestation of infection of skin cells (keratinocytes) caused by human papilloma viruses (HPV). These are karyotropic DNA viruses with more than 100 types. Transmission is from human to human, or animal to human. The incubation period lasts from weeks to months. Predisposing factors to infection include impaired skin barrier (e.g. atopic eczema), immunosuppression (e.g. HIV, those undergoing chemotherapy etc), hyperhidrosis, impaired peripheral circulation and occupation (e.g. jobs involving hands soaked for hours in water, butchers etc).

Epidemiology

Although almost certainly an under-estimate, common warts are reported to affect 7-10% of the population, most commonly in the first three decades of life.

Aetiology & Pathogenesis

The lesions form after a superficial keratinocyte infection by one of the many types of human papilloma

virus.

Signs & Symptoms

Clinically, dome-shaped, firm papules with a papillomatous, hyperkeratotic (verruciform) surface are seen, along with typical dark punctae (capillary thrombi). Plantar warts are flat (mosaic or thorn-like) with pressure-induced inward growth. Warts may be pigmented and/or painful.

Localisation

Any part of the body may be infected, depending on exposure. The hands and feet are most typically affected.

Classification

Classification is according to HPV subtype:

- verruca vulgaris: common wart (HPV 1, 2);
- v. plantaris: plantar, mosaic warts (HPV 2, 4);
- v. plana: (HPV 1, 3).

However, it is not possible to be completely reliable on differentiating different wart types on clinical grounds alone.

Laboratory & other workups

Usually no tests are required, as the diagnosis is clinical.

Dermatopathology

It is only rarely indicated to perform a skin biopsy. If performed, the epidermis is typically acanthotic with vacuolization of keratinocytes and parakeratotic plugs (church-spire feature).

Course

Most common warts resolve spontaneously, however this may take months or even years.

Complications

Warts have a tendency to persist and become disseminated in immunocompromised individuals. If there

are warts around the fingernail, sometimes a permanent nail dystrophy may occur. Some HPVsubtypes may lead to neoplasia including squamous cell carcinoma.

Diagnosis

The diagnosis is almost always made on the typical clinical appearance.

Differential Diagnosis

Corns, macrocomedones, lichen planus, Darier's disease, condylomata lata (Syphilis II), squamous cell carcinoma. Plantar localization includes also amelanotic malignant melanoma.

Prevention & Therapy

Spontaneous resolution is seen in 95% of patients within 2 years. Aggressive therapy should therefore be avoided, especially in small children. Beware scarring from over- treatment. Surgery is only very rarely indicated. Cryosurgery, keratolytics (e.g. salicylic acid), topical retinoids (for facial involvement), 5-fluorouracil (5-FU), diphenylcyclopropenone immunotherapy (DCP) and imiquimod should be considered as treatments where appropriate.

Special

Consider underlying immunosuppression in extensive or treatment-resistant warts.

2.1.5 Condylomata Acuminata

Grading & Level of importance: C



V del Marmol, Brussels; J. White, Brussels, M. Janier, Paris

ICD-11

1A95; anogenital warts; venereal warts; verrucae anogenitales.

Synonyms

Anogenital warts; venereal warts; verrucae anogenitales; genital warts; verruca acuminata.

Definition

Hyperplastic epidermal and mucosal lesions caused by HPV 6, 11 and oncogenic HPV subtypes and others.

Epidemiology

The incidence and prevalence of anogenital warts are probably under-reported as many studies have shown poor awareness of the presence of lesions by patients. There is a high annual incidence between 100-300 per 100,000 providing a large pool for onward infection. 2% of those infected have clinical lesions; 4% have sub-clinical infection and 10% have positive DNA tests. There is a much greater incidence in those with high numbers of sexual partners.

Aetiology & Pathogenesis

Sexual transmission of virus occurs via micro-trauma to the skin or mucous epithelia and 50% of partners are infected after 6 months. Non-sexual transmission is also possible. The incubation time from infection to visible lesion can take weeks to months. In children presenting with genital warts, the possibility of sexual abuse should be considered.

Signs & Symptoms

Pale to livid, sometimes hyperpigmented, narrow-based acuminate papules with a papillomatous surface in the ano-genital area. Lesions start as tiny papules, which are usually asymptomatic and which may be initially overlooked. Sometimes they develop into large "cauliflower" tumors.

Localisation

Condylomata acuminata may be present in any area of the anogenital area including peri/intra-anal area, glans penis, prepuce, labia, introitus vulvae, urethral meatus or oral cavity, depending on site of sexual exposure. Note: some other genital HPV types (16, 18, 31 and 33) cause bowenoid papulosis (clinically benign) as well as precancerous lesions and carcinomas of the cervix, vulva, penis and anus, sometimes in combination with co-factors such as HIV infection and immunosuppression.

Classification

Condylomata acuminata may be classified according to the individual HPV subtype(s).

Laboratory & other workups

A Pap smear test in females potentially including PCR for oncogenic subtypes should be considered. This

can be important if oncogenic subtypes are suspected.

Dermatopathology

Rarely, histology may be required to distinguish condylomata acuminata from other conditions such as squamous cell carcinomas. However, the features are not specific and may be indistinguishable from common warts. Immunostaining with specific antibodies against oncogenic subtypes can be performed.

Course

Most lesions will spontaneously resolve over time, however, some persist and some may evolve or rarely transform into a cancer.

Complications

Some oncogenic subtypes of HPV will result in the development of a carcinoma. Larger lesions may cause sexual dysfunction.

Diagnosis

This is usually straightforward from the clinical appearance. Occasionally a skin biopsy is required to exclude other conditions.

Differential Diagnosis

Condylomata lata, squamous cell carcinoma, aggregated molluscum contagiosum.

Prevention & Therapy

Prevention of lesions can be achieved by immunization before the first sexual contact in girls and boys and where a large proportion of those who are sexually active are immunized, herd immunity may even protect those not immunized. Although effective for most other sexually transmitted diseases, barrier methods of contraception do not always prevent infection with HPV.

Treatment of clinically evident lesions may be undertaken with cryotherapy or other treatments such as podophyllotoxin, imiquimod and trichloroacetic acid (TCA). Electro- or laser coagulation are second line options (however, the fumes from treatment may be infectious and the surgeon is advised to protect her/his airway). As with other sexually transmissible diseases, sexual contacts of the index case should be investigated and treated if possible. Beware over-treatment of exophytic lesions. Peri-meatal scarring may occur with (over)treatment in that area and may cause urological problems.

References

- [Gilson R, Nugent D, Werner RN, Ballesteros J, Ross J \(2020\). IUSTI-Europe guideline for the management of anogenital warts. J Eur Acad Dermatol Venereol. Aug;34\(8\):1644-1653. doi: 10.1111/jdv.16522. PMID: 32735077.](#)
- [Anic GM, Lee JH, Stockwell H, Rollison DE, Wu Y, Papenfuss MR et al \(2011\). Incidence and Human Papillomavirus \(HPV\) type distribution of genital warts in a multinational cohort of men: the HPV in men study. J Infect Dis 2011; 204:1886-1892 doi.org/10.1093/INFDIS/jir652. Epub 2011 Oct 19. PMID: 22013227; PMCID: PMC3209812.](#)

2.1.6 Molluscum Contagiosum

Grading & Level of importance: A
V del Marmol, Brussels; J. White, Brussels



ICD11

1E76

Synonyms

Water warts; molluscum verrucosum; dell wart.

Definition

Superficial viral infection of the skin.

Epidemiology

Common. 12-14 episodes per 1000 children per year in Europe. Likely to be similar world-wide. Peak infection between 1-4 years of age. Affects more frequently children with atopic dermatitis.

Aetiology & Pathogenesis

Molluscum contagiosum is caused by an epidermotropic pox virus, transferred between humans by direct skin contact, or contact with infected towels or bathwater. This usually occurs in children but may also be sexually transmitted in adults.

Signs & Symptoms

The disease is manifested by single or multiple dome-shaped papules with a central umbilication (dell). The lesions are usually skin-coloured, often translucent, but may be red or inflamed. The lesions are commonly not itchy or painful.

Localisation

The papules are normally clustered but may also be linear along excoriations. In children the distribution is usually extragenital. In adults, solitary lesions are more common and they are sometimes very large, mimicking other lesions.

Classification

Nil.

Laboratory & other workups

Laboratory tests are not usually required, as the lesions are so characteristic.

Dermatopathology

Skin biopsy is only required in cases of diagnostic difficulty. The findings are florid and characteristic with lobulated endophytic hyperplasia. Basophilic intracytoplasmic inclusions are seen in keratinocytes.

Course

The lesions may spread by skin to skin contact or sharing of towels or bathwater, particularly in the setting of atopic dermatitis or immunosuppression/HIV infection. Spontaneous resolution may occur within weeks to 18 months.

Complications

Complications are rare but may include secondary bacterial infection (frequently in the setting of excoriation) and scarring (usually from treatments rather than the disease itself). Conjunctivitis or keratitis are extremely rare complications.

Diagnosis

The diagnosis is clinical and usually straightforward. Expelling of molluscum bodies can be a helpful confirmation.

Differential Diagnosis

The differential diagnosis includes plane warts, sebaceous gland hyperplasia, condylomata accuminata in ano-genital area and basal cell carcinoma in solitary lesions in adults.

Prevention & Therapy

Despite spontaneous regression, therapeutic approaches may be considered such as 5% potassium hydroxide solution; destruction with curettage; cryosurgery for single or giant lesions and antiseptics if there is secondary infection. It is important not to over-treat lesions in small children.

2.1.7 Ecthyma contagiosum (Orf)

Grading & Level of importance: A
G. Burg, Zürich



ICD-11

1E75

Synonyms

Orf, bovine pustular stomatitis. Orf and milker's nodule are caused by two closely related parapox viruses; they are clinically very similar and transfer in both cases is from an infected animal to a human.

Definition

Zoonotic infection of the skin caused by the parapoxvirus, Orfviridae, contracted from sheep, lambs and goats.

Epidemiology

Worldwide. Prevalence of the disease in 15% of sheep, especially in young lambs. Persons at risk are farmers, veterinarians, shearers, sheepherders, and butchers. Poxviruses are endemic in large parts of Africa (Democratic Republic of the Congo).

Aetiology & Pathogenesis

By direct or indirect contact with diseased animals the highly contagious zoonotic virus parapoxvirus ovis is transmit. It stimulates angiogenesis by viral vascular endothelial growth factor E (VEGF-E). No human- to-human transfer.

Signs & Symptoms

Single lesion, developing through several stages after inoculation: erythematous macule, inflamed pustular lesion with central necrosis and peripheral red halo; regression after 4-6 weeks and healing, mostly without scar. In addition, there may be fever, malaise, and regional lymphadenopathy. In immunocompromised patients, autoinoculation and multiple “giant” lesions may occur.

Localisation

They occur most commonly on the fingers, hands or forearms but can appear on the face or mucous membranes as well.

Classification

Poxviruses

- Orthopoxviruses
 - Smallpox
 - Vaccinia
 - Cowpox
 - Monkey pox
- Parapoxviruses
 - Ecthyma contagiosum (orf)
 - Milker’s nodule
- Molluscum Contagiosum

Laboratory & other workups

The relatively large virus can be identified by electron microscopy, by special culture or by PCR.

Dermatopathology

- Prominent reticular degeneration and necrosis of the epidermis
- Ballooning, and necrosis of keratinocytes
- Blister formation may be minimal. Multinucleated giant cells usually are absent
- Accompanying papillary edema with erythrocyte extravasation and inflammatory infiltrate

Course

Spontaneous healing without scar within 6-8 weeks.

Complications

Secondary bacterial infection with lymphangitis and erysipelas. Development of erythema multiforme in 10-20% of patients 3-4 weeks after inoculation or of other immunological reactions like Stevens-Johnson syndrome or blistering disorders.

Diagnosis

History (animal contacts); typical clinical feature.

Differential Diagnosis

Poxvirus infections; variola vera; monkey pox; milker's nodule; pyogenic granuloma; bacillary angiomatosis; impetigo contagiosa; dermatitis due to mites; varicella; pustula maligna (anthrax).

Prevention & Therapy

Prevention of contacts with infected animals. The lesions are self-limiting in immunocompetent patients.

Topical: drying measures and topical antiseptics usually are sufficient. In immunocompromised patients topical cidofovir along with mechanical eradication (i.e., cryotherapy, surgical excision, imiquimod, etc.) may be applied.

Special

None.

References

- [Caravaglio J V, Khachemoune A. \(2017\). Orf Virus Infection in Humans: A Review With a Focus on Advances in Diagnosis and Treatment. J Drugs Dermatol 16\(7\):684-689.](#)
- [Kassa, T. \(2021\). A Review on Human Orf: A Neglected Viral Zoonosis. Res Rep Trop Med 12: 153-172.](#)

- [Rossi, L., G. Tiecco, M. Venturini, F. Castelli and E. Quiros-Roldan \(2023\). Human Orf with Immune-Mediated Reactions: A Systematic Review. Microorganisms 11\(5\).1138. doi: 10.3390/microorganisms11051138](#)
- [Pang, F. and Q. Long \(2023\). Recent advances in diagnostic approaches for orf virus. Appl Microbiol Biotechnol 107\(5-6\): 1515-1523.](#)

2.1.8 Smallpox

Grading & Level of importance: C
G. Burg, Zürich



ICD-11

1E70

Synonyms

Variola.

Definition

Smallpox is a member of the viral family poxvirus, genus orthopoxvirus, and species variola virus. Highly contagious pustular disease caused by Poxvirus variola. Overlap with monkey pox and cowpox/ catpox.

Epidemiology

Smallpox is a human disease without animal reservoirs.

According to the 1980 declaration of the World Health Organization (WHO), smallpox has been eradicated, mainly due to effective immunization (Edward Jenner, 18th century).

Major endemic areas were the Indian subcontinent and parts of Africa.

Aetiology & Pathogenesis

The DNA-Virus Poxvirus variolae is the largest (300 nm to 350 nm long) of the human viral pathogens and has a brick-shaped appearance on electron microscopy. The virus is highly contagious and spreads through direct contact, by droplets, contaminated fomites, or airborne over long distances. The virus enters through the oro- or nasopharynx and replicates in the regional lymph nodes. On day 3 to 4 viremia with further dissemination to the bone marrow, spleen, and additional lymph node chains occurs, followed by a secondary viremia between day 8 to 12 after infection and the start of fever and severe

illness. At this stage, the virus becomes localized in small blood vessels of the dermis, resulting in the appearance of rash.

Signs & Symptoms

The clinical course is severe. It begins with a non-specific febrile prodrome of general malaise, high fever, chills, vomiting, abdominal pain, headache. 1-3 days later, skin lesions appear, first at the forearms or face, scalp, palms and soles. Spread to the rest of the body with sparing of axillae and groins.

The lesions appear and mature simultaneously; in contrast to chicken pox, which present with lesions in different phases of development. Sequentially umbilicated papules, vesicles, pustules, crusts, finally leaving typical umbilicated “varioliform” scars with eschars, appear.

Localisation

Marked involvement of face, scalp, palms, and soles with sparing of axillae and groins. In contrast in chickenpox palms and soles are not involved.

Classification

Poxviruses

- Orthopoxviruses
 - Smallpox
 - Vaccinia
 - Cowpox
 - Monkey pox
- Parapoxviruses
 - Ecthyma contagiosum (orf)
 - Milker’s nodule
- Molluscum Contagiosum

Laboratory & other workups

The relatively large virus can be identified by electron microscopy, by special culture or by PCR.

Dermatopathology

- Prominent reticular degeneration and necrosis of the epidermis,

- Ballooning, and necrosis of keratinocytes
- Intracytoplasmic globular deposits of virus capsid
- Blister formation may be minimal. Multinucleated giant cells usually are absent
- Accompanying papillary edema with erythrocyte extravasation and inflammatory infiltrate

Course

Severe disease starting with general symptoms (fever, malaise). Skin lesions appear 3 days after infection, followed by generalized symptoms due to viremia.

Complications

Bacterial superinfection.

Diagnosis

Typical clinical picture and course; electronmicroscopy, PCR.

Differential Diagnosis

Chickenpox, eczema herpeticum, disseminated zoster, hand-foot-mouth disease, drug eruptions, Stevens-Johnson syndrome, toxic epidermal necrolysis, generalized vaccinia, cowpox, monkeypox.

Prevention & Therapy

In the pre-eradication era, supportive care was the primary treatment available. Tecovirimat was the first antiviral medicament for treatment of smallpox.

Finally, vaccination has been successful in the eradication of smallpox globally.

In 1798, Edward Jenner could demonstrate that cowpox protected against smallpox infection. By 1900 vaccinia virus, which is more closely related to horsepox, was globally used for vaccination. Today improved technology to develop tissue-culture-based live vaccines, live attenuated virus vaccines, and viral subunit vaccine products may be used to protect personnel at increased special risk of exposure such as researchers and some healthcare workers.

Special

Vaccinia is a distinct poxvirus, probably evolved from the smallpox or the cowpox virus, has been used for vaccination. Cowpox are more common in cats (catpox). Monkeypox are found in Zaire. They all may produce similar symptoms like smallpox.

References

- [Kari A. Simonsen; Jessica Snowden. Smallpox. StatPearls \[Internet\]. Last Update: August 8, 2022](#)
- [Breman J G & D.A. Henderson D A \(2002\). Diagnosis and Management of Smallpox N Engl J Med 2002; 346:1300-1308. doi: 10.1056/NEJMra020025. Epub 2002 Mar 28. PMID: 11923491.](#)
- [Spinney L. \(2020\). The Hidden History of ancient plagues Nature 584: 30-32 Khardori, N. \(2022\). Vaccines and vaccine resistance: Past, present and future. Indian J Med Microbiol 40\(2\): 187-192. doi: 10.1016/j.ijmmb.2021.12.008. Epub 2021 Dec 24. PMID: 34961641.](#)
- [Zewdie, G., G. Derese, B. Getachew, H. Belay and M. Akalu \(2021\). Review of sheep and goat pox disease: current updates on epidemiology, diagnosis, prevention and control measures in Ethiopia. Anim Dis 1\(1\): 28. doi: 10.1186/s44149-021-00028-2. Epub 2021 Nov 15. PMID: 34806086; PMCID: PMC8591591.](#)

2.1.9 Oral Hairy Leukoplakia

Grading & Level of importance: C
F. Bakr, Lwin; J. McGrath, London



Definition

Disease of the oral mucosal epithelium. Associated with Epstein-Barr virus (EBV), also known as human herpesvirus 4.

Epidemiology

Current incidence of cancers of the oral cavity is mainly consisting of squamous cell carcinomas. It varies worldwide from less than three to seven or eight per 100,000 population. It affects mainly middle-aged and elderly people. Prevalence of oral leukoplakia is approximately 0.1% with a huge variation in different parts of the world above the age of 30-40 years. Annual risk of malignant transformation of oral leukoplakia from 2 to 3% or even much higher. individuals who are not immunocompromised. It occurs also in immunocompetent patients having continuously inhaled topica or systemic corticosteroids for the long term.

The Centre for Disease Control and Prevention has classified this condition as a Category-B clinical marker of HIV disease since it has a clear prognostic value in the subsequent development of AIDS.

Aetiology & Pathogenesis

It is associated with Epstein-Barr virus (EBV), also known as human herpesvirus 4. It occurs most

commonly in people infected with HIV, although it can also be seen in people who do not have HIV. Such patients usually have had an organ or bone marrow transplant or some immunocompromised disease or hematological malignancy.

In hairy leukoplakia, the BZLF1 gene is restricted to the cells of the stratum spinosum and stratum granulosum, not to the basal cells.

Signs & Symptoms

White, hyperkeratotic, often thread-like deposits on the sides and under surface of the tongue which cannot be wiped away (in contrast to oral candidiasis).

Dermatopathology

Five Signs. Hyperkeratosis of the superficial layer of the epithelium and Hyperparakeratosis of the superficial layer of the epithelium. Acanthosis of the upper stratum spinosum. Absence of inflammation in the epithelium and minimal to zero inflammation in the lamina propria, and even absent inflammatory mononuclear cells infiltrate. Normal basal cells of the epithelium.

Differential diagnosis

Leukoplakia, lichen planus, candidiasis.

Therapy

Hairy leukoplakia is a benign condition with a low morbidity rate and a tendency to resolve spontaneously. Treatment options include anti-retroviral drugs. Highly active antiretroviral therapy drugs usually reduce hairy leukoplakia, relapses can occur despite when dosage is reduced.

A topical treatment with low concentration with podophyllin or tretinoin 0.1% can be done.

References

- [Aramadhan SA, Bhattacharyya I, Cohen DM, Islam MN. \(2021\). Oral Hairy Leukoplakia in Immunocompetent Patients Revisited with Literature Review. Head Neck Pathol. 2021;15\(3\):989-993. doi: 10.1007/s12105-021-01287-8.](#) Rathee, M & Jain P Hairy Leukoplakia StatPearls Publishing; 2024 Jan-.
- [Isaac van der Waal \(2019\) Oral Leukoplakia: Present Views on Diagnosis, Management, Communication with Patients, and Research \(2019\) Current Oral Health Reports 6:9–13](#)

2.2 Bacterial Infections

2.2.1 Erythrasma

Grading & Level of importance: A
E. Gaffal, Magdeburg



ICD-11

1C44

Synonyms

None.

Definition

Superficial infection with diptheroid bacteria mostly affecting intertriginous areas.

Epidemiology

Erythrasma mostly occurs in healthy adults, less often in children. Epidemiology is difficult to assess since many patients do not seek treatment or have subclinical infections.

Aetiology & Pathogenesis

Most infections are caused by porphyrin-producing *Corynebacterium minutissimum*. Predisposing factors are obesity, diabetes, immune suppression (e.g. HIV infection), extensive sweating and a warm humid climate.

Signs & Symptoms

Sharply bordered, red-brown, scaly patches, occasionally pruritic.

Localisation

Axillary, inguinal, toe clefts, genitals, inner aspect of the thigh, submammary areas.

Classification

Interdigital erythrasma, intertriginous erythrasma, generalized/disciform erythrasma.

Laboratory & other workups

None.

Dermatopathology

Mild hyperkeratosis, acanthosis or parakeratosis with a minimal perivascular infiltrate in H&E staining. Gram staining shows positive rods and filaments in the stratum corneum.

Course

Recurr frequently.

Complications

Chronification.

Diagnosis

Wood's light: coral red fluorescence (porphyrins from bacterial metabolism), culture (difficult).

Differential Diagnosis

Pityriasis versicolor, Tinea inguinalis, Lichen simplex chronicus, Candidosis, Psoriasis vulgaris.

Prevention & Therapy

Prevention: avoid skin to skin contact in intertriginous areas such as groins, submammary or folds at lower abdomen in obesitas. Obese and diabetics should dry properly and apply adstringens powder.

Treatment: Topical treatment including antiseptics, antimycotic therapy with azoles e.g. clotrimazole or ketoconazole or topical antibiotics e.g. erythromycin. Severe cases can be treated with oral antibiotics (tetracycline, clarithromycin). Disappearance of red fluorescence indicates therapeutic success; hyperpigmentation may persist.

Special

None.

References

- [Forouzan P. & PR Cohen \(2020\). Erythrasma Revisited: Diagnosis, Differential Diagnoses, and Comprehensive Review of Treatment. Cureus 12\(9\): e10733. DOI 10.7759/cureus.10733.](#)

2.2.2 Impetigo Contagiosa

Grading & Level of importance: A



H. Gollnick, Magdeburg

ICD-11

1B72

Synonyms

Superficial interfollicular pyoderma.

Definition

Superficial cutaneous bacterial infection of the interfollicular epidermis induced almost always by Staph.aureus or Strept.pyogenes (group A beta-hemolytic).

Epidemiology

Impetigo contagiosa has a worldwide distribution. It is found more common in infants and children, those with atopic dermatitis, and in warm, moist environments. Prevalence decreasing with adolescence. 20 cases/1000 population per year in Europe. Most cases and studies are from Asia, India and Africa. Excess of 162 million, predominantly in tropical, resource-poor contexts at one time is calculated. Pyoderma and impetigo often mixed which has led to conflicting reporting in statistics. Over a 45-year interval, the burden of impetigo has remained relatively unchanged.

Aetiology & Pathogenesis

Staphylococcal and streptococcal bacterial infection spread by fomites or direct contact, usually to predisposed skin (disturbed epidermal barrier; over-washing of children's skin with less immunocompetence; atopic dermatitis, angular stomatitis, rhinitis, herpes simplex, pruritus with scratching). Reservoir: nose. Causative agent usually 80% staphylococci, 10% β -hemolytic streptococci and 10% mixed infections (streptococci, less often staphylococci). In large bullous impetigo forms, one

detects *S.aureus* strain related exfoliative toxins (exfoliating A–D), which target desmoglein 1.

Signs & Symptoms

First one observes macular flat, then flaccid transparent and later honey-yellowish tiny vesicular or bullous lesions. The roof of the pustule is unstable, rupture occurs and strong secretion and pus is on top of the lesion and is further disseminated by scratching. Cracked hemorrhagic-red crusts mostly in a collarette pattern are left, finally the crusts desquamate and no scars are left. In widespread cases, fever may occur. Some streptococci-induced cases start often at the lower legs as a non-bullous impetigo but develops into a crateriforme pinched-out like ulcer with necrotic crusts that persist quite longer and leave scars: those lesions are called ecthyma and are to be differentiated from necrotizing vasculitis.

Localisation

It is most often localized to the face but can be observed anywhere.

Classification

In general, two types: non-bullous and small to large bullous. Streptogenic induced ones are more sero-crusted and red/inflammatory, staphylogenic ones are more honey-like yellowish with small to large blisters. Ecthyma is a deep located *S.pyogenes*-related ulcerating type of impetigo.

Laboratory & other workups

In widespread streptogenic and staphylogenic types, differential blood count, CRP, urine for exclusion of glomerulonephritis. Api-Staph or Api-20-Strep test.

Dermatopathology

Neutrophilic pustule within the stratum corneum and split beneath the stratum corneum in small bullous type, in large bullous type mid epidermis with little abscesses. Sometimes a few acantholytic keratinocytes appear which may resemble Pemphigus foliaceus.

Course

Usually self-limited, no scarring. Scratching leads to new lesions by autoinoculation. Rarely impetigo nephritis. Deep penetration of *S. pyogenes* leads to ecthyma with scarring, more chronic course.

Complications

Dangerous: SSSS and TSS may develop. Acute glomerulonephritis when infection is caused by certain strains of streptococci.

Diagnosis

Clinical features.

Differential Diagnosis

- Dermatoses in particular eczemas with secondary impetiginization; superficial folliculitis;
- localized and widespread HSV infection (herpes simplex, eczema herpeticum) or varicella and coxsackie virus exanthemas. In ecthyma like types, necrotizing vasculitis and Pityriasis lichenoides et varioliformis acuta.

Prevention & Therapy

Prevention

The first step is treating the carrier sites with application of antiseptic ointment, mostly to the nostrils. Antibacterial low acidic pH wash daily, sometimes bleach bath. Hands have to be kept clean and finger nails to be cut short. In parallel, identification of source for infection and treatment.

The second step is to reduce the chance of passing the infection to another person, one should avoid close body contact. Abstain from Kindergarten or children's playgrounds until crusts have fallen off after appropriate topical or systemic treatment. At home, the use of separate towels is recommended. Clothes have to be changed daily and to be washed at 60°C.

Therapy

Topical: disinfectants, dyes, ointments, wet-dry dressings if crusted.

Systemic: in widespread streptococcal types penicillinase resistant cephalosporins, erythromycin, culture-directed secondary antibiotics.

Special

None.

References

- [Bowen AC, Mahé A, Hay RJ, Andrews RM, Steer AC, Tong SY, Carapetis JR. \(2015\). The Global Epidemiology of Impetigo: A Systematic Review of the Population Prevalence of Impetigo and Pyoderma. PLoS One. Aug 28;10\(8\): e0136789. doi: 10.1371/journal.pone.0136789. PMID: 26317533; PMCID: PMC4552802.](#)
- [Pereira LB. \(2014\). Impetigo – review. An Bras Dermatol. Mar-Apr;89\(2\):293-9. Doi: 10.1590/abd1806-4841.20142283. PMID: 24770507; PMCID: PMC4008061.](#)
- [Gahlawat G., Tesfaye W., Bushel W. et al \(2021\). Emerging Treatment Strategies for Impetigo in Endemic and Non-endemic Settings: A Systematic Review. Clinical Therapeutics 43, 6, 986-1006. doi: 10.1016/j.clinthera.2021.04.013. Epub 2021 May 27. PMID: 34053699.](#)

2.2.3 Erysipelas

Grading & Level of importance: A
H. Gollnick, Magdeburg



ICD-11

1B70

Synonyms

Cellulitis.

Definition

Erysipelas is an acute cutaneous bacterial infection almost always induced by streptococci that involves first the superficial lymphatics with fast spreading in the upper dermis and, if not properly treated, penetrates depending on the virulence of the microbe and the susceptibility of the host into deeper layers including the adipose tissue, fascia and muscle (necrotizing fasciitis).

Epidemiology

Prevalence around 1100 /100,000 per year. Peak incidence around 60 to 80 years.

Aetiology & Pathogenesis

Erysipelas affects all ethnic groups without a gender specificity. The site of entry is often between toes, in skin folds or from superficial erosions. Trauma, lymphedema, varicose vein surgery and other surgical procedures at the leg site (bypass donor site), arteriosclerotic and diabetic ulcers on the lower leg also predispose.

Causative agents are about 90% beta-hemolytic group A streptococci (less B, C, G) or *Staphylococcus aureus* and sometimes gram-positive or - negative bacteria. However, the role of *Staphylococcus aureus*, and specifically methicillin-resistant *S. aureus* (MRSA), remains controversial. Some evidence exist that co-colonizing *S. aureus* exfoliative toxins contribute to the bullous subtype. 90% of cases are localized on the lower extremity, 2.5% on the face.

Signs & Symptoms

Erysipelas is an acute illness with high fever and chills (often missing in recurrent disease and in the elderly), sharply bordered, warm, tender, oedematous, erythematous plaques with flame-like peripheral spread.

Bullous, haemorrhagic or necrotic presentations are more severe variants. In immune-compromised patients, erysipelas saltans with very fast spreading may occur. The necrotic gangrenescens subtype is accompanied by danger of deeper localization with necrotizing fasciitis – an early surgical intervention is necessary to stop the severe course.

Localisation

Erysipelas can affect any site, although it has a predilection for the face and legs. Chronic edema of the leg is predisposing. In the face often spreading to the opposite site.

Classification

There are different courses of the disease but no classification. However, subtypes are:

- uncomplicated type
- vesicular
- bullous or
- hemorrhagic type
- saltans type and
- necrotic /gangrenescens type

Laboratory & other workups

Erythrocyte sedimentation rate (ESR) and C reactive protein (CRP) elevated, later ASL/AST titres rises with a leukocytosis.

Dermatopathology

Corium edema with dilation of upper and deep blood vessel plexus and lymph vessels. Masses of polymorphous neutrophils between collagen bundles, later with necrotic areas.

Course

The course of the disease is either short, preceded by chills and high fever and fast response to anti-streptococcal antibiotics, or it is complicated when in particular the streptococci penetrate more deeply and the host defence is low.

Complications

Thrombosis (if occurring on the face this can result in venous sinus thrombosis), myocarditis, pneumonia, chronic lymphoedema (especially with recurrent disease), glomerulonephritis. Sepsis < 5%.

Diagnosis

Clinical features (fever, erythema), culture of possible entry point (tinea pedis between the toes or nasal swab or wounds), inflammatory markers.

Differential Diagnosis

- acute contact dermatitis and stasis dermatitis,
- thrombophlebitis,
- erysipeloid and cellulitis,
- acrodermatitis chronica atrophicans (inflammatory stage),
- acute compartment syndrome.

Danger: be careful not to miss early stage of necrotising fasciitis.

Prevention & Therapy

Bed rest, involved region elevated, cool moist compresses, systemic antibiotics (penicillin 4-5 million

IU daily i.v. or 4 x 500 mg oral in uncomplicated cases, alternatively ampicillin/clavulanate.

Severe erysipelas need hospitalization and thrice or four times daily 5 to 10. Mill. units penicillin If resistant, cephalosporins) for 10 days. Clindamycin if penicillin allergy present.

Special

Necrotizing deep penetrating type with development into necrotizing fasciitis early intervention by surgery.

In severe lymphedema with relapsing erysipelas maintenance treatment (on/off). In patients can be treated with concomitant intermittent lymph compression during antibiotic infusion.

References

- [Knut Kröger , Andreas Schwarzkopf , Stephan Eder , Kerstin Protz , Christian Münter, Joachim Dissemond \(2021\) Diagnosis and therapy of erysipelas: A position paper of the Society Initiative Chronische Wunde Dtsch Med Wochenschr 46 \(12\) :822-830.](#)
- [Anna Bläckberg, Kristina Trell, and Magnus Rasmussen \(2015\) Erysipelas, a large retrospective study of aetiology and clinical presentation BMC Infect Dis. 2015; 15: 402](#)
- [Brindle RJ & Louise A. O’Neill LA & Williams OM \(2020\) Risk, Prevention, Diagnosis, and Management of Cellulitis and Erysipelas. Current Dermatology Reports 9:73–82](#)

2.2.4 Microbial Folliculitis

Grading & Level of importance: A
H. Gollnick, Magdeburg



ICD-11

1B74

Synonyms

Bacterial or mycotic folliculitis; Infundibulofolliculitis.

Definition

Intrafollicular pyoderma of microbial origin located in the hair follicles.

Epidemiology

Superficial folliculitis in general is very common, but because of its different etiological factors and presentation no clear statistics exist. Furthermore, it is often self-limited and patients rarely present to their doctor.

Aetiology & Pathogenesis

Usually *Staphylococcus aureus* (coagulase positive), but also gram-negative bacteria or *Malassezia* spp. and other mycotic species are in most cases to be discovered in the acro- and the infra- infundibulum of hair follicles. However, sebaceous gland follicles and vellus hair follicles are often also involved.

Predisposing factors are in particular: mechanical pressure, tight clothing, excoriations, increased humidity and sweating, occlusion by topical products or wound dressings, terminal hair shaving, local and systemic immunosuppression (topical and systemic corticosteroids; HIV, diabetes mellitus, ciclosporin) and finally inadequate hygiene, poverty and nutrition deficiency.

Signs & Symptoms

Papules and tiny or prominent pustules involving the follicular canal at the acroinfundibulum and infra-infundibulum including the surrounding tissue (perifolliculitis) of the follicles.

Localisation

Preferentially occluded skin of the chest and back, the intertriginous areas and buttocks are involved as well as the suprapubic area, in particular if terminal hair is shaved, belly folds due to obesity, greasy scalp and neck folds.

Classification

1. Ostiofolliculitis (Bockhart): pyoderma of the follicle ostia; often in intertriginous or occluded areas.
2. Folliculitis et perifolliculitis: deeper penetration of infection into the infrainfundibulum with stronger inflammatory reaction and marked perifolliculitis. Final stage with deeper penetration leads to furuncle and involvement of several follicles to carbuncle.
3. Folliculitis barbae: chronic ostiofolliculitis of terminal hair in the beard area, often further spread by shaving.
4. Folliculitis decalvans: late stage of chronic folliculitis of the scalp; uncommon chronic folliculitis with scarring alopecia (pseudopelade), bundles of hairs (tufting).
5. Perifolliculitis capitis abscedens et suffodiens: probably maximal variant of folliculitis decalvans

capilliti.

Laboratory & other workups

In patients with immunodeficiency, diabetes mellitus, kidney dialysis patients, long term topical and systemic antibiotic treatment and non-responders to standard treatments, a culture with classification and resistogram is essential.

Differential blood count, blood glucose, protein electrophoresis and immuno-deficiency markers including an HIV test should be performed. Individually chemotaxis and phagocytosis tests can be indicated.

Dermatopathology

In superficial folliculitis neutrophils invading the acroinfundibulum where gram positive and gram-negative cocci or hyphae and spores are colonizing. The deeper the infectious agent penetrating the follicle, the more perifollicular granulocytic neutrophils and mononuclear cells accumulate. Late stage of severe deep folliculitis with granulomatous reaction and scarring repair.

Course

Acute and chronic depending on environment, origin of microbe and immune status of patient.

Complications

Furuncle, carbuncle. Rarely sepsis. Scars.

Diagnosis

Usually, the clinical features make the diagnosis. A classification by culture of the microbial agent may help in addition to differentiate for example a bacterial or mycotic pustular eruption or mixed types or exclusion of gram-negative microbes. On the scalp a biopsy may also be helpful.

Differential Diagnosis

Other forms of folliculitis with sterile and non-sterile pustules and intra – or interfollicular localization:

Often:

- Pseudofolliculitis barbae: pili recurvati or incarnati with secondary foreign body reaction.

- Drug induced pustular eruption.
- Coxsackie, Varicella and Herpes disseminating vesiculopustules

Rare:

- eosinophilic folliculitis;
- pustular psoriasis;
- perforating folliculitis;
- acrosyringeal pustular eruption;
- Myeloid blast cell dissemination to the skin.

Prevention & Therapy

Depending on severity and location, first choice is always the application of antiseptics. One should avoid topical antibiotics because of inducing resistant strains and inducing spread of those strains (community). Identification of nasal carrier of gram-negative bacteria is necessary and according to testing, specific antibiotics are allowed (mupirocin).

Systemic antibiotics in case of deep disseminated folliculitis and perifolliculitis or developing of multiple furuncle/carbuncle should always be considered.

Topical antimycotics are to be used when positive in microscopy, culture or immunofluorescence / PCR. In deep penetrating and /or widespread mycotic infection, systemic azoles are essential.

Prevention by change and washing of clothing regularly in predisposed and in infected patients is mandatory. Patients should avoid humidity and be educated not to over-wash the skin (ph-neutral or acidic shower gels).

Special

In therapy-resistant cases, consider rare diseases with immune deficiencies, defects of micro-and macrophagocytosis, lack of IgA and certain cytokine activities.

References

- [Ramakrishnan K, Salinas RC & Higuaita A \(2015\) Skin and Soft Tissue Infections Am Fam Physician. 92\(6\):474-483](#)

- [Huang-Shen Lin, Pei-Tzu Lin, Yu-Shiun Tsai, Shu-Hui Wang, and Ching-Chi \(2018\) Interventions for bacterial folliculitis and boils \(furuncles and carbuncles\) Cochrane Database Syst Rev. ;\(8\):CD013099](#)

2.2.5 Furuncle/Carbuncle

Grading & Level of importance: B
H. Gollnick, Magdeburg



ICD-11

1B75.0

Synonyms

Boil.

Definition

1. Furuncle: it is a deep follicular infection with abscess formation almost always caused by *Staphylococcus aureus* or mixed infection including streptococci and gram-negative bacteria.
2. Carbuncle: this is a conglomerate of multiple confluent deep follicular infections (furuncles), sometimes with multiple fistula openings.

Epidemiology

10–20% of the population are staphylococcal carriers.

Aetiology & Pathogenesis

The bacterial skin infection either spreads via autoinoculation (from nose or throat) or via exogenous transfer. The site of entry is the follicle ostium of the terminal hair-, the sebaceous gland- or vellus hair follicle. The transfer of bacteria mostly occurs from the nostrils, armpits, inguinal areas and rima ani. It may be smeared to other sites from the nostrils via the finger nails. Specific strains can produce furuncle / carbuncle out of an impetigo such as *staph.aureus* having the panton-valentine- leukozidine gene (about 60% of cases). Relapses of *staph.aureus* in skin infections are three times more frequent.

Signs & Symptoms

Initially a firm painful nodule appears, then it turns into a fluctuant abscess with central necrotic plug and is accompanied often by a surrounding edema, a lymphangitis and lymphadenitis. It usually ends in a spontaneous rupture and drainage of the pus. It remains first an ulceration followed later by a yellow-brown crusts. The carbuncle is an even stronger infection with more pain, often starting with shivering, then fever and the danger of bacteremia. If present on or around the nose, sinusoidal thrombosis or sepsis can occur.

Localisation

All hair-bearing regions, often neck, face, axillae, or buttocks or back of upper shins, in skin folds and obesity.

Classification

None.

Laboratory & other workups

In case of carbuncle: leucocytes, CRP, glucose, electrophoresis.

Dermatopathology

The histological pictures show severe inflammation with accumulation of neutrophils and macrophages within and in the surrounding the follicular canal with destruction of follicle and dermal collagen and other adnexal structures. In case of a carbuncle, fistular structures on serial sections can be detected. Massive macrophages in organizing the surrounding tissue and later scarring.

Course

In most cases a painful and highly inflammatory course with spontaneous rupture of central follicular opening with masses of pus is observed.

Complications

A septic course with hematogenous spread and bacterial involvement of heart valves, joints or kidneys possible is a severe unwanted complication. In case of mid-face localisation, the risk of cavernous sinus thrombosis has to be considered.

Diagnosis

Clinical feature and course.

Differential Diagnosis

- Deep trichophyton infections (beard)
- hidradenitis suppurativa (axillae)
- necrotising herpes simplex
- isolated panniculitis
- drunculosis

Prevention & Therapy

Prevention is associated with skin care, not overwashing with changing the skin microbiota into dysbiosis, avoiding autoinoculation and considering underlying diseases, diabetes mellitus, obesitas, immuno-incompetence.

Therapy is usually

- Incision when fluctuation starts and continuous drainage with tamponade. Bed rest depending on localisation, elevation of involved area (face: talking, chewing forbidden).
- Systemic antibiotics for carbuncle and all furuncles in case of mid-face lesions and high-risk patients: penicillinase-resistant penicillins (oxacillin), alternatively erythromycin. Culture and sensitivity, since resistance is common and adjustments are needed.
- Topical: mechanical manipulation should be avoided. Wet antimicrobial dressings (clioquinol, povidone-iodine) can be applied, no topical antimicrobials except mupirocin. An incision should be in most cases be considered. There is evidence that body wash with chlorhexidine or octenidine together with mupirocin for the nose can prevent relapses. Polividoiodine highest antimicrobial action and most safe agent.

Special

None.

References

- [Ramakrishnan K, Salinas RC & Higuera A \(2015\) Skin and Soft Tissue Infections Am Fam Physician. 92\(6\):474-483](#)

- [Huang-Shen Lin, Pei-Tzu Lin, Yu-Shiun Tsai, Shu-Hui Wang, and Ching-Chi \(2021\) Interventions for bacterial folliculitis and boils \(furuncles and carbuncles\) Cochrane Database Syst Rev. 2021 Feb 26; 2\(2\):CD013099.](#)

2.2.6 Staphylococcal scalded skin syndrome (SSSS)

Grading & Level of importance: C
H. Gollnick, Magdeburg



ICD-11

EA50.2

Synonyms

Ritter von Rittershain disease (1878), Staphylogenic Lyell Syndrome (1956); Ritter's disease; staphylogenic pemphigus neonatorum; Dermatitis exfoliativa neonatorum.

Definition

SSSS: the acute exfoliative dermatitis is primarily seen in small children following staphylogenic infections with lysophage group II exfoliative toxins ETA A and B. STSS: the acute *S. aureus* toxin.

Epidemiology

SSSS: affects up to 56 children out of 100,000, elderly are rarely involved.

Aetiology & Pathogenesis

Staphylococcal Scalded Skin Syndrome (SSSS) is a toxin-mediated epidermolytic dermatosis and characterized by erythema and widespread loss of the superficial epidermal layers, resembling a burn. Mostly *Staphylococcus aureus* isolates of the lyso (phage) group II are responsible. Products are ETA-A, -B and -D, which show hematogenous spread. The split in the epidermis is beneath the stratum corneum within the stratum granulosum followed by an acantholysis similar to pemphigus. The split takes place at this precise point because the exfoliative toxins act as serin proteases and damage desmoglein 1.

Signs & Symptoms

Following a staphylococcal infection in SSSS, initially a widespread erythema resembling scarlet fever appears followed within 24 to 48 hours by small unstable blisters which quickly become eroded and lead

to widespread skin loss similar to grade II burns. In the acute course, the children are systemically ill. Nikolski sign is positive. Re-epithelisation takes place a week after desquamation. No scarring.

Localisation

All areas of the body skin may be involved.

Classification

There are two clinical subtypes in SSSS,

- one in the first three months of life is called staphylogenic pemphigoid of the newborn, and,
- the other in older infants appearing as a staphylogenic Lyell-syndrome. Often an otitis, a pharyngitis or a conjunctivitis are preceding the skin manifestations. In the elderly often renal insufficiency or immune deficiency predispose to the disease.

Laboratory & other workups

Intensive care laboratory data regarding kidney, liver and blood, minerals, albumin and thorough investigations of bacterial strains are necessary.

Dermatopathology

Subcorneal blisters and bullae and acantholysis are the hallmarks of SSSS. An acantholytic cleft in the upper Stratum granulosum and a blister roof which only contains stratum corneum can be seen. (This is in contrast to TEN, in which one sees full-thickness epidermal damage).

Course

Rapid onset within hours to two days course. In the elderly the mortality is high (up to 40%).

Complications

Sepsis, pneumonia, acute pulmonary distress syndrome. The high mortality in the elderly up to 40%, in children about 3-5 %.

Diagnosis

History, clinical feature, histology (frozen section of blister roof), microbiology.

Differential Diagnosis

- TSST
- TEN (medication-induced)
- epidermolysis bullosa
- scarlatina
- chronic bullous disease of childhood (linear IgA disease)
- Kawasaki syndrome

Prevention & Therapy

Children and adults should be admitted immediately to an intensive care unit. Antibiotics covering penicillinase resistant staphylococci according to resistogram are mostly cefotaxime, flucloxacillin and clindamycin; immunoglobulins are recommended. Fluid replacement as in burn patients, elimination of staphylococcal foci; other antimicrobial disinfectant therapy (baths, compresses). Paracetamol, no NSAIDs; the most important means of controlling STSS / GAS disease and its sequelae is prompt identification and treatment of infections. Intravenous antibiotics like clindamycin or azithromycin may be first choice of systemic antibiotic treatment.

Special

Immediate biopsy for cryosection to visualize the location of blister for differential diagnosis.

References

- [Handler MZ, Schwartz RA \(2014\) Staphylococcal scalded skin syndrome: diagnosis and management in children and adults. J Eur Acad Dermatol Venereol. 2014 Nov;28\(11\):1418-23.](#)
- [Carmen Liy-Wong , Elena Pope , Miriam Weinstein , Irene Lara-Corrales \(2021\) Staphylococcal scalded skin syndrome: An epidemiological and clinical review of 84 cases. Pediatr Dermatol 38; 21:1490–1499](#)

2.2.7 Staphylogenic/Streptogenic Toxin Shock-Syndrom (STSS)

Grading & Level of importance: C
H. Gollnick, Magdeburg



ICD-11

EA50.2

Synonyms

Menstrual and non-menstrual STSS.

Definition

Staphylococcal TSS: the acute *S.aureus* toxin TSST-1 and several enterotoxins causes disease which gives high fever, myalgia, nausea, headache, vomiting, pulmonary distress and diffuse macular erythema followed by erythroderma and later exfoliation.

Streptococcal TSS is related to pyrogenic group A streptococci.

Epidemiology

StaphTSS: Epidemiological studies conducted in the UK and Ireland reported an incidence rate for STSS of 0.38 per 100,000 children. Both children and adults cases of varying severity and death rates of up to 50-60% in septic shock forms, are described in the literature.

Around 50 cases per year of StreptTSS are reported in the US. The number of menstrual STSS cases in the USA is becoming lower, data for the non-menstrual subtype show a female: male ratio of 3:1.

Aetiology & Pathogenesis

In Staphylogenic Toxin Shock Syndrome (STSS) the causative agent is the Toxic Shock Syndrome-Toxin-1 and the enterotoxins SEA to SEO. STSS was confirmed according to 2011 CDC criteria, and blood cultures positive for Methicillin-sensitive *Staphylococcus aureus* (MSSA). In cases of streptococcal origin (Streptococcal Toxin Shock-Syndrome), the pyrogenic exotoxins (SPE) A, B and C are responsible. They act via unrestricted MHC-II binding as superantigens activating specific T-cells which lead then to TNF alpha, IL 1 β and IL-6 release. One differentiates two subtypes. STSS menstrual type related to toxin TSST-1 is linked to the use of tampons with accumulation of staphylococci during menstruation. The STSS non-menstrual type is related to toxins produced by specific *S.aureus* colonies appearing in infections

such as bursitis, after intra-articular injections or infected arthropod stings / bites.

Signs & Symptoms

In STSS of staphylogenic or streptogenic origin the symptoms are systemic with high fever, vomiting and nausea, myalgia and myositis, headache, strawberry tongue and a widespread macular erythema extending to an erythroderma and followed by body skin desquamation, particularly at first on the palms and soles, also affecting mucous membranes in the mouth and vagina. Nail and hair loss may occur. Periportal hepatic inflammation, acute tubular necrosis, and the abnormal pulmonary findings of acute respiratory distress syndrome (ARDS) are life threatening symptoms. Cases of streptococcal TSS can be associated with necrotizing fasciitis.

Localisation

All areas of the body skin may be involved.

Classification

There are two clinical subtypes in StaphTSS, one in the first three months of life is called staphylogenic pemphigoid of the newborn, and, the second in older infants as a staphylogenic Lyell-syndrome. Often an otitis, a pharyngitis or a conjunctivitis precede. In the elderly, renal insufficiency or immune deficiency often predispose to the disease.

Menstrual STSS is related to tampon use and staphylococcal toxin and non-menstrual STSS is related to staphylococcal and streptococcal infections of various origin.

Laboratory & other workups

Intensive care laboratory data regarding kidney, liver and blood, minerals, albumin and thorough investigations of bacterial strains are necessary.

Dermatopathology

Subcorneal blisters and bullae and acantholysis are the hallmarks of SSSS. An acantholytic cleft in the upper Stratum granulosum and a blister roof which only contains stratum corneum can be seen. (In contrast to TEN in which one sees full-thickness epidermal damage.) In STSS damage is seen in the whole epidermis and intraepidermal and subepidermal clefts, necrotic cells and apoptosis appear. Microthrombi of the capillaries occur. This is sometimes difficult to distinguish from TEN.

Course

Rapid onset within hours to two days [7]. Both children and adults cases of varying severity and death rates of up to 50-60% in septic shock forms, are described in the literature.

Mortality 10-20% in the streptogenic type, menstrual STSS 2-5%, non-menstrual 8-11%.

Complications

Sepsis, pneumonia, acute pulmonary distress syndrome.

Diagnosis

History, clinical feature, histology (frozen section of blister roof), microbiology.

Differential Diagnosis

- TEN (medication-induced);
- epidermolysis bullosa,
- scarlatina,
- chronic bullous disease of childhood (linear IgA disease);
- Kawasaki syndrome.

Prevention & Therapy

Children and adults should be admitted immediately to an intensive care unit. Antibiotics covering penicillinase resistant staphylococci according to resistogram are mostly cefotaxime, flucloxacillin and clindamycin; immunoglobulins are recommended. Fluid replacement as in burn patients, elimination of staphylococcal foci; other antimicrobial disinfectant therapy (baths, compresses). Paracetamol, no NSAIDs. The most important means of controlling STSS disease and its sequelae is prompt identification and treatment of infections. Intravenous antibiotics like clindamycin or azithromycin may be first choice of systemic antibiotic treatment. Whereas penicillin is very effective in mild *Streptococcus pyogenes* infection, it is less effective in severe infections because of its short postantibiotic effect, inoculum effect, and reduced activity against persisting-phase organisms. Emerging treatments for strep TSS include furthermore intravenous gamma-globulin.

Special

Immediate biopsy for cryosection to visualize the location of blister for differential diagnosis.

References

- [Michael Gottlieb, Brit Long , Alex Koyfman \(2018\) The Evaluation and Management of Toxic Shock Syndrome in the Emergency Department: A Review of the Literature J Emerg Med \(6\):807-814.](#)

2.2.8 Erythema (Chronicum) Migrans

Grading & Level of importance: A



E. Gaffal, Magdeburg; H. Gollnick, Magdeburg

ICD-11

1C1G.0

Synonyms

Stage 1 Lyme disease; early cutaneous Lyme borreliosis; Erythema migrans.

Definition

Early target like and annular, then centrifugally spreading erythema with a prominent margin either local or disseminated.

Epidemiology

In endemic areas in northern, middle and east Europe up to 20% of *Ixodes ricinus* are infected by *B. afzelii*, *B. garinii*, *B. spielmanii*, *B. bavariensis* and *B. burgdorferi* sensu strictu as well. In the USA *B. burgdorferi* sensu strictu is most common. After a tick bite from an infected *Ixodes*, in 5%, a local infection appears and in up to 2% if not treated a manifestation of a borreliosis take place. About 100-200 cases / 100,000 people per year in Germany, in Austria or Slovenia even higher up to 400 cases. Individuals at special risk: farmers, joggers, hikers, dog owners, forest worker, gardener.

Aetiology & Pathogenesis

The transfer of *Borrelia spp* occurs mostly via the tick sting from *Ixodes ricinus*. The most prominent reservoirs are birds, mice, hedgehogs and foxes. Patients report a history of a sting in less than 10% of cases. After an *Ixodes* nymph or adult arthropod has inserted (not a bite!) its hypostoma into the upper dermis it releases some factors to help stabilizing its position and to open vessels and avoiding blood clotting when starting to suck. Because of osmotic balance, saliva with borrelia is first deposited in the skin. The reservoir of borrelia is almost entirely in the intestinal fluid of the *Ixodes* which is released into the skin

in parallel or later. *Borrelia* organisms are 20µm long and 3µm thick. They have multiple antigenic structures (853) to which the innate immune system reacts. The most important are the flagellin (endoflagellins up to 12 different structures) and outer surface lipoproteins OspA - G. The innate immune system reacts i.p. on the local site and the regional lymph node with a strong B-cell production of antibodies. Serological detection usually occurs by the third week after exposure.

Signs & Symptoms

- Incubation period: 1-4 weeks.
- Skin: sharply bordered erythematous ring with prominent border (sometimes with central hemorrhagic area), spreads peripherally and clears centrally, mostly 10 - 30 cm depending on body site.
- Center variable: pale, erythematous, hemorrhagic, vesicular. Multiple annular erythemas possible due to multiple stings, then more symptomatic. Sting from the nymphae in early spring often overlooked and no symptoms, later in summer adult Ixodes stings can make pain, the organism is much bigger.
- Systemic symptoms can also occur: headache, neck pain, arthralgias, fever depending on persisting infection and dissemination of organism and immune response.

Localisation

Preferentially: knee, lower leg, inguinal and buttocks, lumbar area, axilla, shoulder, chest, neck, auricle.

Classification

- Stage 1 early localized
- Stage 2 early disseminated
- Stage 3 late disseminated

In Stages 1, 2 and 3 an overlap can occur. (See also Chapter 2.2.9)

Laboratory & other workups

Serology with IgM and IgG specific antibodies and additional early antigen markers in the immunoblot (p41 flagellin, OspE, Osp C) after about 3 weeks. Late stage (Osp 17, A, B, p43).

Dermatopathology

A biopsy is taken from the margin. Superficial dermal perivascular lymphocytic infiltrate. The longer the infection persists the more perineural and periglandular infiltrates and plasma cells appear. Initially some eosinophils. Warthin-Starry stain and immunohistochemistry can help to detect the microbe in tissue.

Course

See classification. If not treated, dissemination may occur and manifestations in other organ systems take place: joints, muscles, peripheral and central nervous system, heart.

Complications

Meningoradiculitis, Guillain Barré syndrome, arthritis, myocarditis (conduction disturbances), encephalopathy.

Diagnosis

History, clinical features, PCR from lesion: borrelia DNA; borrelia serology initially negative.

Differential Diagnosis

- Other arthropods (spider) bites
- urticaria, erythema and granuloma annulare
- other figurate erythemas including fixed drug eruption
- tinea, erysipelas and erysipeloid

Prevention & Therapy

Prevention: After outdoor activities in garden, walking in the forest and lying at a meadow skin body check and early removal of Ixodes. No squeezing, use of special scissors. Parents should check their children's skin every evening when playing in areas where Ixodes is present.

Dogs should be inspected too.

Therapy: Doxycycline 100 mg b.i.d. for 14 days. Alternatively, Amoxicillin 3 x 500 to 1000 mg/d 2 weeks. Azithomycin 2 x 250 mg/d for 10 days.

Special

None.

References

- [Egberts F, Möller M, Proksch E, Schwarz T. \(2008\) Multiple erythema migrans--manifestation of systemic cutaneous borreliosis. J Dtsch Dermatol Gesell6\(5\):350-3.](#)
- [Eriksson P, Schröder MT, Niiranen K, Nevanlinna A, Panelius J, Ranki A. \(2013\) The many faces of solitary and multiple erythema migrans Acta Derm Venereol. \(6\):693-700](#)
- [Marques AR, Strle F, Wormser GP. Comparison of Lyme Disease in the United States and Europe. Emerg Infect Dis. 2021;27\(8\):2017-2024. <https://doi.org/10.3201/eid2708.204763>](#)

2.2.9 Lymphadenosis Cutis Benigna

Grading & Level of importance: B



H. Gollnick, Magdeburg

ICD-11

EE91 / 1C1G.14

Synonyms

Pseudolymphoma. Borrelia lymphocytoma, Spiegler-Fendt-Sarcoid, Lymphocytic infiltration, reactive lymphoid hyperplasia.

Definition

Reactive pseudolymphomatous infiltrate with hyperplasia of lymphatic cells in the early phase after borrelia infection, but sometimes after viral or parasitic infections.

Epidemiology

Clear epidemiological data on Borrelia lymphocytoma are lacking. Around 2% of cases are reported. In a German survey from 2003, 189 out of 3935 borrelia infected patients (4.8%) developed lymphadenosis cutis benigna.

Aetiology & Pathogenesis

Lymphadenosis cutis benigna is a process that can simulate a cutaneous B-cell-lymphoma, but it behaves in a harmless manner. It is a reactive process. In this type of pseudolymphoma, B – lymphocytes and other inflammatory cells accumulate in the dermis and subcutis as a reaction to stimuli of borrelia antigens.

This specific subset of B- cell type pseudolymphoma, borrelial lymphocytoma, primarily occurs in Europe in areas endemic for the tick *Ixodes ricinus*. Borrelial lymphocytoma is a tick bite response to infection by *Borrelia burgdorferi* subsp *afzelii* and *garrinii*. Causative agents: *Borrelia garrinii* and *Borrelia afzelii* (both in Europe), not *Borrelia burgdorferi* sensu strictu.

There are rare reports linking this type of pseudolymphomas to post-viral infections, in particular herpes zoster (post-zoster scar lymphocytoma cutis). Another established subtype is due to persisting reactions to the scabies mite without active but probably mite remnant involvement (persistent nodular arthropod-bite reactions).

Signs & Symptoms

In *Borrelia* lymphocytoma lesions are often indolent soft blue-red nodules up to 5 cm. Postscabies lymphocytomas are localized or often disseminated.

Localisation

Sites of predilection: In borrelia lymphocytoma the sites of predilection are: loose skin (ear, nipple, scrotum); red-blue lupoid infiltrate (diascopy).

Classification

No international classification as compared with malignant cutaneous lymphomas.

Laboratory & other workups

Borrelia IgG and IgM titers raised in *Borrelia* lymphocytoma. No specific antigen subtype in serology to be detected. Dermatopathology specimen with immunohistochemistry necessary.

Dermatopathology

Most important to differentiate the subtypes of pseudolymphomas (see chapter 3.3.14 Pseudolymphomas) and to exclude malignant B-or T-cell infiltrates from skin or systemic lymphomas.

Epidermis not involved. Dermis with V-pattern top down mature relatively sharp demarcated nodular infiltrates of lymphocytes, plasma cells, follicle center cells, macrophages and sometimes eosinophils. Characteristic is an infiltrate-free zone beneath the epidermis. Expression of B-cell-epitopes (CD20, CD79a). No monoclonal rearrangement of immunoglobulins of heavy or light chains. Sometimes it will show a picture of mature lymph node tissue.

Course

Depends on subtype. In borrelia lymphocytoma after adequate 2nd stage oral doxycycline over 3 weeks, slow fading of lesion(s). In post-scabies pseudolymphoma after adequate internal antiparasitic drugs and additional change of topical agent, complete but slow healing. Post herpes scar lymphocytoma up to 1-2 months healing.

Complications

None.

Diagnosis

Clinical features, serology, histology, PCR.

Differential Diagnosis

- Malignant B- / T- cell lymphomas,
- disseminated cutaneous sarcoidosis,
- stage II syphilis.

Prevention & Therapy

Depending on subtype. Antibiotics (doxycycline 100 mg b.i.d. for 3 weeks) in borrelia lymphocytoma. Ivermectin orally for post scabies manifestation. Post herpes zoster scar pseudolymphoma topical corticosteroids are recommended.

Special

None.

References

- [Martin Glatz 1 , Astrid Resinger, Kristina Semmelweis, Christina M Ambros-Rudolph \(2015\) Clinical spectrum of skin manifestations of Lyme borreliosis in 204 children in Austria. Acta Derm Venereol. 95\(5\):565-71.](#)
- [Borrelial lymphocytoma. Wien Klin Wochenschr. doi:.1007/s00508-022-02064-5.](#)
- [Rezazadegan R et al. \(2022\) Borrelial Lymphocytoma. Dtsch Arztebl Int. 2022 119\(20\):369. doi: 10.3238/arztebl.m2022.0015](#)

2.2.10 Acrodermatitis Chronica Atrophicans

Grading & Level of importance: B
H. Gollnick, Magdeburg



ICD-11

1C1G.14

Synonyms

Lyme borreliosis; Late stage cutaneous Lyme borreliosis; Herxheimer's disease.

Definition

Cutaneous manifestation of chronic *Borrelia burgdorferi* sensu latu infection leading in a first step to inflammatory edematous changes and in a later step to irreversible atrophy. Concurrent neurological, and/or musculo-skeletal and /or cardiac involvement is common.

Epidemiology

In the general European population Lyme borreliosis is > 10: 100,000 per year. In France 9.4, in Poland and Austria up to 130, in Slovenia up to 150 / 100,000. In South Sweden in a population study 63 /100000. All ages can be involved, but adults preferred. Data from Central Europe show that after a tick bite in 2.6 up to 5.6% of subjects develop antibodies against *Borrelia* sensu latu (seroconversion). The seroprevalence in the younger age is around 7%, in the elderly in males around 24% and in females 16%. In total 0,3 to 1,4% of subjects develop a clinical manifestation of the disease after a tick bite. The manifestation of stage II and III ACA is around 1% (- 3%) and other organ involvement around 3% for neuro-borreliosis, 3% for Lyme arthritis and < 1% for cardiac complications. The overall prevalence of ACA in all European patients with LB is about 1–10%, depending on the region. For example, in Bulgaria, both BL and ACA account for 0.3% of LB cases. In Norway, ACA accounts for 5% of all clinical cases of LB,

and in northern Italy about 2.5%.

Aetiology & Pathogenesis

Acrodermatitis chronica atrophicans is a late manifestation of a chronic infection with the spirochaetes of the species *Borrelia afzelii* almost exclusively. The transfer of borrelia spp occurs mostly via the tick sting from *Ixodes ricinus*. The most prominent reservoirs are birds, mice, hedgehogs and foxes. Less than 10% of patients report a history of a sting. After an *Ixodes* nymph or adult arthropod has inserted (no bite!) its hypostoma into the upper dermis it releases some factors to help stabilizing its position and to open vessels and avoiding blood clotting when starting to suck. Because of osmotic balance, saliva with borrelia is first deposited in the skin. The reservoir of borrelia is the intestinal fluid of the *Ixodes* which is released into the skin in parallel or later. *Borrelia* organisms are 20µm long and 3µm thick. They have multiple antigenic structures (853) to which the innate immune system reacts. The most important are the flagellin (endoflagellins up to 12 different structures) and outer surface lipoproteins OspA - G. The innate immune system reacts i.p. on the local site and the regional lymph node with a strong B-cell production of antibodies. Serological detection is detectable at the 3rd to 4th week. In acrodermatitis, late antigens are responsible for maintaining the manifestation: OSP 17, Osp A and B, p30,43,45,58 and p837100. They are detected by immunoblotting for classification and follow-up after therapy. Strong B-cell activation and accumulation of plasma cells in situ occur. A persistence of microbes over decades is possible. The organisms are able to invade endothelial cells, fibroblasts, and Langerhans cells and to survive in collagenous tissue. Antigenic mimicry appears. Whereas in erythema migrans IFN gamma is produced for spirochete killing, in ACA it is missing. Destruction of dermal tissue and its adnexae, nerves and epidermal atrophy is the result.

Signs & Symptoms

- ACA stage I: inflammatory-edematous stage with livid doughy swelling.
- ACA stage II: atrophic stage (cigarette paper skin, telangiectases, pigmentary changes). Sclerosis (scleroderma-like collagen changes, ulnar and tibial bands) and fibrous nodules (up to several cm hard, cartilage-like nodules about joints) are slowly developing. Associated may be an allodynia and an axonal peripheral neuropathy (Guillain-Bujadoux-Bannwarth syndrome).

Localisation

Very often the hands and feet, elbows, knees are involved. Initially the manifestation is unilateral, later symmetrical. Unusual localizations are possible, for example on the breast, which may mimic a cancer.

Classification

Early inflammatory edematous and late atrophic stage.

Laboratory & other workups

The sedimentation rate is elevated. The first serological step is the ELISA test: borrelia IgG titer raised, sometimes IgM persisting. In the immunoblot as a second step one can see a typical pattern without surface proteins (Osp 17 (p21), Osp A and B) and other persisting antigens (p 30,43,45,58 83,100). If neurological symptoms are present, lumbar puncture for liquor serology is necessary.

Dermatopathology

The epidermis and dermis are smaller and adnexal structures with follicles and sweat glands are missing. An infiltrate mostly rich in plasma cells and additionally lymphomononuclear cells is prominent. No neutrophils or eosinophils in this stage of LB. Collagen and elastic fiber destruction are a rule. Sometimes plasma cells accumulate around nerve bundles. In difficult situations of making a clear diagnosis, immunohistochemistry against the microbe can detect the organism in the tissue or a PCR is helpful to detect the infection but negative DNA results are also seen.

Course

A slow development is typical and the course very chronic.

Complications

In addition to the soft tissue, muscle atrophy may be seen. Polyneuropathy is detected in 50% of cases. Increased vulnerability of atrophic skin with wounding. Development of plasmacytic B cell lymphomas is reported.

Diagnosis

Clinical features, histology, PCR, borrelia serology positive with antigen subtype profiling necessary.

Differential Diagnosis

- Thrombophlebitis, thrombosis,
- acrocyanosis, perniones,
- erysipelas, in stage I.
- Varicose veins in stage II.
- Sudeck's atrophy in both stages.
- Advanced aging of the skin with dermatoporosis incl. overlap.

Prevention & Therapy

Prevention of re-infection by tick stings.

Treatment according to stage related guideline. First choice systemic antibiotic is doxycycline orally 3 weeks 200 mg / day. Infusions with ceftriaxone are an alternative. Multiple cycles of antibiotic therapy can become necessary. However, no treatment following serological persisting markers should be performed. Lyme borreliosis has a different laboratory profile as compared to a clear cut serological follow-up in syphilis.

Special

Often patients consider suffering from chronic borreliosis of different organ manifestations. Huge amount of misleading web information existing.

References

- [Hofmann H, Fingerle V, Hunfeld KP, Huppertz HI, Krause A, Rauer S, Ruf B., Consensus group. Cutaneous Lyme borreliosis: Guideline of the German Dermatology Society \(2017\) Ger Med Sci. 15:Doc14.](#)
- [Glatz M, Resinger A, Semmelweis K, Ambros-Rudolph CM, Müllegger RR. Clinical spectrum of skin manifestations of Lyme borreliosis in 204 children in Austria. Acta Derm Venereol. 2015 May;95\(5\):565-71.](#)
- [Moniuszko-Malinowska A, Czupryna P, Dunaj J, Pancewicz S, Garkowski A, Kondrusik M, Grygorczuk S, Zajkowska J. Acrodermatitis chronica atrophicans: various faces of the late form of Lyme borreliosis. Postepy Dermatol Alergol. 2018 Oct;35\(5\):490-494. doi: 10.5114/ada.2018.77240. Epub 2018 Jul 19. PMID: 30429707; PMCID: PMC6232541.](#)

2.2.11 Leprosy

Grading & Level of importance: A



M. Bagot, Paris; G. Dobos, Paris; A. De Masson, Paris

ICD-11

1B20

Synonyms

Hansen's disease.

Definition

Leprosy is a chronic, minimally contagious infection with *Mycobacterium leprae*, developing after an incubation period of 3 to 20 years, mainly affecting the skin and peripheral nerves. Clinical course depends on the immune status of the patient.

Epidemiology

Leprosy is exceptional in industrialized countries and globally located between latitudes 40 degrees north and south. Malnutrition, poverty are major risk factors for acquiring leprosy. Worldwide around 200,000 new cases are registered every year (predominantly in India, Brazil, Indonesia, Nepal, Congo, Mozambique, and the Philippines).

Aetiology & Pathogenesis

Leprosy is caused by *Mycobacterium leprae*, an intracellular gram-positive acid-fast bacillus.

Signs & Symptoms

- Skin involvement includes: solitary or multiple hypo-pigmented, anhidrotic and hypo-esthetic macules or plaques, nodules (leproma), red macules with peripheral papular spread, solitary or multiple hypo-pigmented areas with reduced sensation. A leonine face may be seen.
- Neurological features: palpable thickening of nerves (e.g. ulnar), impaired sensation, motor and sensory problems (muscle atrophy), trophic ulcers.
- Mucosal involvement includes: chronic rhinitis and epistaxis.
- Eye involvement includes: lagophthalmia, uveitis, cataract, corneal involvement, optic neuropathy, diffuse involvement (panophthalmia leprosa), which can lead to loss of vision and blindness.
- Other organ involvement: kidneys, testis, lymph nodes.
- Spectrum from
 - lepromatous leprosy (weak immune response, many bacilli, also known as multibacillary leprosy)
 - tuberculoid leprosy (strong immune response, few bacilli, also known as paucibacillary leprosy).

Localisation

Hypo-pigmented macules with sensitivity loss can occur anywhere on the body. Leproma nodules are frequently located on the face, ears or hands.

Classification

Leprosy can be classified by clinical manifestations, which span from

- indeterminate leprosy (I, potential initial stage)
- tuberculoid leprosy (TT), lepromatous leprosy (LL) and
- borderline leprosy (spectrum of transient forms, BT, BL, BB)

This disease also can be classified by the number of bacilli; paucibacillary leprosy (corresponding to tuberculoid leprosy) and multibacillary leprosy (corresponding to lepromatous leprosy). Immune reactions associated with the presence of *M. leprae* are known as leprosy reactions:

Type 1: type IV reaction flare-up of old skin lesions and neuritis. It occurs during therapy.

Type 2: type III reaction in lepromatous or borderline leprosy. Skin changes are known as erythema nodosum leprosum.

Laboratory & other workups

A polymerase chain reaction in skin can be used to identify *Mycobacterium leprae* but can be negative in tuberculoid forms without ruling out the diagnosis.

Dermatopathology

Tuberculoid leprosy manifests as granuloma with epithelioid histiocytes surrounding small cutaneous nerves, giant cells may be seen. Bacilli are usually scarce but can be found by immunohistochemistry.

In lepromatous leprosy, macrophages (Virchow cells) can be found in poorly circumscribed nodules in the dermis, numerous bacilli are present especially in cutaneous nerves and in the vessels. Bacilli can be visualized by Ziehl-Neelsen staining.

Course

The course can evolve in any direction between lepromatous, tuberculoid and borderline forms.

Complications

The anesthesia can lead to secondary injuries, mutilations and amputation. Neural and ocular involvement can lead to motor deficiency and loss of vision. Destruction of oral and nasal mucosa, and, testicular atrophy may occur. Without treatment, leprosy can cause persistent disability.

Diagnosis

The diagnosis is suspected when clinically evocative skin lesions +/- palpable nerves or neurological defects are observed. The diagnosis is confirmed by the existence of a specific leproid granuloma histologically, and/or by the identification of *M. leprae* (by Ziehl-Neelsen or Fite, and immunohistochemistry staining and/or PCR on skin biopsy, fluid and skin snips from nose, ear lobe) especially in lepromatous form.

Differential Diagnosis

Hypopigmented lesions may be mistaken for eczema, psoriasis, dermatophyte infection, seborrheic dermatitis, mycosis fungoides, vitiligo, pityriasis versicolor, pityriasis rosea.

Nodules in lepromatous leprosy can mimic sarcoidosis, cutaneous lymphoma, leishmaniasis, syphilis.

Prevention & Therapy

Prevention: persons in the same household have to be examined or treated when symptoms are diagnosed. Some protection is given by BCG vaccine. Early diagnosis can help to avoid spread.

Treatment is a combination of antibiotics (rifampicin, dapsone and clofazimine) and the duration of the treatment depends on the form of disease. Dapsone may induce flare ups. Paucibacillary leprosy is treated for 6 months. Multibacillary leprosy is treated for at least 12 months.

Special

Care often in special leprosy centers.

References

- [Chen KH, Lin CY, Su SB, Chen KT. \(2022\) Leprosy: A Review of Epidemiology, Clinical Diagnosis, and Management. J Trop Med. Jul 4;2022:8652062.](#)
- [Froes LAR Junior, Sotto MN, Trindade MAB. An Bras Dermatol. \(2022\) Leprosy: clinical and immunopathological characteristics. May-Jun;97\(3\):338-347.](#)

2.2.12 Skin Tuberculosis and atyp. Mycobacterioses (MOTT)



Grading & Level of importance: B

M. Bagot, Paris; G. Dobos, Paris; A. De Masson, Paris

ICD-11

1B12.8

Synonyms

Skin Koch disease, Lupus vulgaris, Tuberculosis cutis, MOTT (Mycobacteria other than tuberculosis).

Definition

Skin infection with *Mycobacterium tuberculosis* complex and MOTT complex.

Epidemiology

Tuberculosis (TB) is a world-wide frequent infection with around 10 million new cases each year. It affects frequently the lungs, the mediastinal or peripheral lymph nodes, urogenital tract, bone, nervous system or the skin. Immune suppression is a risk factor of developing tuberculosis (malnutrition, AIDS). This disease occurs more frequently in developing countries.

Atypical mycobacterial skin infections include fish tank (or swimming pool) granuloma caused by *Mycobacterium marinum* (typically papulonodules or ulcers of the hands/limbs), Buruli ulcer caused by *Mycobacterium ulcerans* (cutaneous nodule or ulcer), present in tropical countries, and infections with *M. chelonae*, *M. abscessus*, or *M. fortuitum*, present worldwide, and most frequently found after skin injections, tattoos, skin trauma or surgery.

Aetiology & Pathogenesis

Classical tuberculosis by *Mycobacterium tuberculosis* is transmitted by droplets. Infectious droplets are generated when persons with pulmonary or laryngeal TB disease cough, sneeze, shout or sing. MOTT of the lungs may be transmitted via droplets (*M. avium* or *kansasii*) or on the skin by contact with defective skin barrier.

Signs & Symptoms

Cutaneous tuberculosis can appear in three different forms depending on immune status.

Lupus vulgaris is the most frequent form. The red-brown papules show an apple-jelly color on glass diascopy. Slow growth can eventually lead to ulceration, mutilation and scarring.

Tuberculosis cutis verrucosa or 'prosector's wart' are verrucous plaque-like lesions, frequently found on the hands or face.

Tuberculids result from the systematic spread of the infection and include erythema induratum of Bazin, lichen scrofulosorum and papulonecrotic tuberculids.

Erythema induratum of Bazin presents typically as inflammatory nodules of the limbs in elderly women.

Localisation

Lupus vulgaris and tuberculids can appear anywhere on the body. Tuberculosis cutis verrucosa is frequently found on the hands or face. Erythema induratum of Bazin presents on lower limbs. Specific localisations of *Mycobacterium marinum* are on the hands and lower arms.

Classification

Skin tuberculosis results from direct inoculation or systemic spread of *Mycobacterium tuberculosis* complex.

Cutaneous atypical mycobacterial infection are non-tuberculous mycobacterial infections of the skin, excluding leprosy.

Laboratory & other workups

Mantoux-test can be conducted by local inoculation with tuberculin toxin. After two or three days, the diameter of the induration is measured and is used to define positivity. A positive test indicates a previous contact with the *Mycobacterium tuberculosis* complex and can be evocative of active tuberculosis.

Quantiferon-TB-Gold-test (interferon-gamma release assay) is another indirect, highly sensitive and specific laboratory test that detects the presence of a cellular immune response against *M. tuberculosis*.

Bacterial culture has a slow growth. From biopsies PCR tests can be used to prove the presence of different types of mycobacteria. PCR from biopsy allows faster discrimination.

Dermatopathology

Tuberculosis is characterized by a granulomatous infiltrate with caseating necrosis. Bacilli can be visualised by Ziehl-Neelsen, Fite Faraco and by immunohistochemical staining.

Course

Tuberculosis is a chronic disease and if untreated, the infection can spread to other organs.

Complications

Lupus vulgaris may progress to ulcerations, scarring, mutilation or systemic spread. Squamous cell carcinoma may occur on the scar tissue.

Diagnosis

The diagnosis of different types of mycobacterial infections is based on the detection of the mycobacteria by Ziehl-Neelsen and immunohistochemistry staining, PCR or mycobacterial direct examination and culture, associated with a consistent clinical context.

Differential Diagnosis

Early lupus vulgaris may mimic psoriasis vulgaris or discoid lupus erythematosus.

MOTT can mimic different skin infections such as ulcers, deep impetigo, nodular vasculitis and leprosy.

Prevention & Therapy

Prevention: early diagnosis, avoiding risk factors undernutrition, low hygiene in poor countries, HIV and other immuno-incompetence.

Treatment of TB is becoming more complicated today because of high worldwide distribution of resistance. In small, circumscribed lesions, an excision can be indicated prior to systemic treatment. The treatment of TB typically relies on quadruple antibiotic treatment for two months and subsequent double antibiotic treatment for additional six months, according to the WHO recommendations (isoniazid, rifampicin for six months, together with ethambutol and pyrazinamide in the first two months). Bacterial culture should be initiated prior to treatment to evaluate resistance.

Treatment of MOTT is different to classical tuberculosis and is based on antibiotics such as [tetracyclines](#), fluoroquinolones, macrolides (eg, amikacin, clarithromycin), [rifampicin](#) and sulfonamides (cotrimoxazole). Deep surgical debridement is often essential.

Special

Prior to the introduction of immunosuppressive or immunomodulatory therapy (e.g. TNF-alpha inhibitors) a latent underlying mycobacterial infection has to be excluded to avoid a risk of re-activation.

References

- [Nogueira BMF, Krishnan S, Barreto-Duarte B, Araújo-Pereira M, Queiroz ATL, Ellner JJ, Salgame P, Scriba TJ, Sterling TR, Gupta A, Andrade BB.\(2022\) Diagnostic biomarkers for active tuberculosis: progress and challenges. EMBO Mol MedOct 31:e14088.](#)
- [Olmo-Fontánez AM, Turner J.Pathogens. \(2022\) Tuberculosis in an Aging World. Sep 26;11\(10\):1101.](#)
- [Fujishima C, Tahara J, Munemoto S, Hioki C, Sasaki H, Yoshida H, Matsuo H, Miyamoto Y, Ishii N, Kudo H. \(2022\) Cutaneous nontuberculous mycobacterial infections in Japan: Review of the Japanese literature. J Dermatol. Nov;49\(11\):1075-1084.](#)
- [Gardini G, Gregori N, Matteelli A, Castelli F. \(2022\) Mycobacterial skin infection. Mycobacterial skin infection. Curr Opin Infect Dis.](#)

2.3 Fungal Infections

2.3.1 Dermatophyte Infections

Grading & Level of importance: A
Z. Bukvić Mokos, Zagreb; B. Marinović, Zagreb



ICD-11

1F28.Y

Synonyms

Tinea, the term is usually followed by the Latin name for the involved anatomic site, such as Tinea corporis (body), Tinea capitis (scalp), Tinea faciei (face) and for other.

Definition

Infections caused by dermatophytes of the species *Microsporum*, *Trichophyton* and *Epidermophyton*.

Epidemiology

Tinea corporis is more common in children and adolescents than in adults. Tinea capitis is most commonly found in children aged 3-14 years old. The incidence of favus has dramatically declined, although it may be endemic in some geographic areas. Tinea barbae is found exclusively in males, most commonly among farmers. Tinea pedis is one of the most common dermatological diseases, showing 20% prevalence among adults. Tinea manuum almost always occurs following tinea pedis. Onychomycosis is found in about 20% of adults; more than 80% of all nail infections are caused by dermatophytes.

Aetiology & Pathogenesis

Dermatophytes are keratinophilic fungi which infect the stratum corneum, hair follicles and nails, and include three genera (Table I):

- *Microsporum*
- *Trichophyton*
- *Epidermophyton*

Anthropophilic dermatophytes *Trichophyton (T.) rubrum*, *T. interdigitale* are adapted to humans and cause chronic infections with minimal inflammation.

Zoophilic dermatophytes (*Microsporum (M.) canis*, *T. mentagrophytes*) are found on warm-blooded animals; these are highly transmissible through contact into humans and usually cause intense inflammation. The animals (e.g. pets) are often asymptomatic carriers.

Geophilic dermatophytes (*M. gypseum*) are found in the ground; these rarely cause mycoses in humans. Transmission is usually human to human and animal to human; rarely soil to human or animal. In addition to agent-dependent factors, the host response influences the clinical manifestations of the disease. The host factors which encourage dermatophyte invasion include decreased sebum production, immunosuppression, macerated skin and minor skin trauma.

Signs & Symptoms

- Tinea corporis

Tinea corporis usually presents with annular, erythematous, circumscribed plaques with peripheral scale

(caused by the spread of the fungus within the stratum corneum) and occasionally pustules. The plaques tend to heal centrally as the periphery advances, giving the lesions a typical ring shape. Itching is variable. Any dermatophyte can cause tinea corporis, but the most common pathogen is *T. rubrum*, followed by *T. mentagrophytes* and *M. canis*.

- Tinea capitis

Tinea capitis is a dermatophyte infection of the scalp caused by members of two genera: *Trichophyton* and *Microsporum*. *Trichophyton* spp. produce both ectothrix and endothrix infections, while *Microsporum* spp. always cause ectothrix infections. In an ectothrix infection the fungi affect the follicle until they reach the zone of keratinization, without invading non-keratinized parts of the hairs; whereas in an endothrix pattern the fungi reproduce within the hair shaft, which results with its destruction.

Clinically, one should distinguish between classic tinea capitis (scalp ringworm), kerion and favus.

Classic tinea capitis is the most common dermatophyte infection in childhood. In anthropophilic endothrix infections (*T. tonsurans*), the hair is filled with spores, visible as small black dots in the follicle opening ("black dot ringworm"). *Microsporum* infections caused by anthropophilic *M. audouinii* or by zoophilic *M. canis* often lead to bland deep folliculitis without abscess formation. Hairs break off shortly after emerging above the scalp surface. These hairs fluoresce yellow-green on Wood's light examination. However, when *M. canis* is responsible, transitions to inflammatory tinea capitis may be expected.

Zoophilic dermatophytes (*T. verrucosum*, *T. mentagrophytes*, *M. canis*) extend deep into the follicles and induce an intense inflammation, pustules and abscesses with massive purulent secretion ("kerion").

Favus is caused by *T. schoenleinii*. Typical clinical findings are exuberant masses of fungal elements, scales and secretions producing scutula (Latin for small shield). They heal with scarring (cicatrical alopecia or pseudopelade).

- Tinea barbae

Tinea barbae affects men and presents as a deep abscess-forming folliculitis of the beard hair. It is most often acquired from animals and is typically caused by *T. mentagrophytes* or *T. verrucosum* (common dermatophyte in cows).

- Tinea pedis

Tinea pedis is one of the most common dermatological diseases. The most common causative dermatophytes are *T. rubrum*, *T. interdigitale*, *T. mentagrophytes* and *Epidemophyton (E.) floccosum*. There are 3 clinical forms: interdigital, hyperkeratotic and vesicular/dyshidrotic. The interdigital form is characterized by maceration and coarse scaling, most commonly between closely approximated 3rd and 4th toes. Shedding of the macerated skin produces erosions and fissures. The hyperkeratotic form presents as non-inflammatory diffuse scaling of the entire plantar surface of soles and is often mistaken for dry skin. Vesicular/dyshidrotic form is most often present on the arch of the foot, as well as the tips of the small and great toes. Typical lesions are scattered, intensely pruritic vesicles which may be cloudy.

- Tinea manuum

Tinea manuum usually affects only one hand, but in chronic cases may be bilateral (tinea manuum). It is most often caused by *T. rubrum* and *T. interdigitale*. Clinically, there may be fine collarette scaling on the cup of the palm, especially along the palmar creases. Dyshidrosiform type is characterized by itchy vesicles on palm and sides of fingers. A special type is “one-hand/two-feet mycosis” which always affects both soles as well as one palm. It is usually caused by *T. rubrum*.

- Tinea cruris

Tinea cruris (tinea inguinalis; “jock itch”) is a dermatophyte infection involving the groin. It is most commonly caused by *E. floccosum*, *T. rubrum* and *T. interdigitale*. Men are more commonly affected than women. Tinea cruris is commonly seen in patients with tinea pedis. It is clinically presented as ring-shaped erythematous lesion with scaly borders on the groins.

- Onychomycosis

Onychomycosis (tinea unguium) is a dermatophyte infection of the nail unit. More than 80% of all nail infections are caused by dermatophytes (usually *T. rubrum* and *T. interdigitale*). Impaired nail growth is a predisposing factor. More frequently affects the feet (starting from tinea pedis) rather than the hands. Several forms of fungal nail infection can be clinically distinguished: a) distal subungual onychomycosis is the most common form; b) white superficial onychomycosis (whitish surface of the nail; most often caused by *T. interdigitale*); c) proximal subungual onychomycosis (the least common type), d) complete dystrophic onychomycosis with marked destruction of the nail plate as final state of the first three forms.

Laboratory & other workups

Dermatophytoses are diagnosed via KOH examination and fungal culture. Hyphae are identified by KOH examination from scales of the skin lesion or nail. The type of dermatophyte can be identified only with cultivation using Sabouraud agar as media. Cultivation often takes 3 weeks. PCR studies allow detection of dermatophytes at species level within 24 hours.

Dermatopathology

PAS or silver stains make the dermatophytes more visible in histology. Hyphae are seen within the stratum corneum or acroinfundibulum.

Complications

A fungal id reaction represents an allergic reaction to fungus or its metabolites. It develops in patients with severe, inflamed tinea (most often tinea pedis and kerion). Erythema, papules and vesicles occur in areas distant from the site of tinea lesions. Characteristically, KOH examination and culture from such distant lesions are negative.

Diagnosis

Diagnosis is based on clinical and histological features, KOH examination, fungal culture and PCR.

Differential diagnosis

Differential diagnosis includes pyodermas, dermatitis, psoriasis, pityriasis rosea, discoid or subacute cutaneous lupus erythematosus. "If a lesion is scaly, a fungal infection should be excluded".

Prevention & Therapy

General measures include correction of predisposing factors (sweating, improper shoes) and treatment of (asymptomatic) carriers. The choice of treatment depends on the location and severity of infection. Topical antifungals are the first-line treatment for the treatment of localized dermatophyte infections such as tinea corporis, tinea pedis and tinea cruris. There is a wide spectrum of topical antifungals, including azoles, amorolfine, ciclopirox olamine and terbinafine. Polyenes (amphotericin B, nystatin) are ineffective against dermatophytes. For hyperkeratotic forms of dermatophytoses (e.g. tinea pedis) adjunctive topical products such as urea and salicylic acid may be used. Systemic antifungal treatment is required for tinea capitis, for the hairy sites other than the scalp such as tinea barbae, for widespread disease and for most cases of tinea unguium. Namely, for distal subungual onychomycosis involving less than 50% of nail plate, topical treatment may be employed, but with less effectiveness than with systemic treatment. Oral antifungals for the treatment of dermatophytosis include terbinafine as the

gold standard; alternatively, triazoles such as itraconazole and fluconazole can be used. Griseofulvin is restricted to *Microsporum* infections in childhood.

References

- [Degreef H. Clinical forms of dermatophytosis \(ringworm infection\). Mycopathologia. 2008; 166:257-65.](#)
- [Noble SL, Forbes RC, Stamm PL. Diagnosis and management of common tinea infections. Am Fam Physician. 1998; 58:163-74, 177-8.](#)
- [Gupta AK, Stec N, Summerbell RC, Shear NH, Piguet V, Tosti A, Piraccini BM. Onychomycosis: a review. J Eur Acad Dermatol Venereol. 2020; 34:1972-1990.](#)

2.3.2 Candidiasis

Grading & Level of importance: B



Z. Bukvić Mokos, Zagreb; B. Marinović, Zagreb

ICD-11

1F23.Z

Synonyms

Moniliasis; candidosis; yeast infection; thrush.

Definition

Candidiasis is a harmless commensal colonisation with yeast of the genus *Candida* (normal flora of the gastrointestinal tract, upper respiratory tract, female genitalia) which in the presence of predisposing factors can develop into an infection. Main species is *Candida albicans*; other less common *Candida* (C.) species are: *C. tropicalis*, *C. stellatoidea*, *C. parapsilosis* and *C. glabrata*.

Epidemiology

Candidiasis is very common disease worldwide; it has been estimated that it occurs at least once during the lifetime of every individual. Nearly a billion people are estimated to have skin, nail and hair fungal infections, many 10's of millions have mucosal candidiasis and more than 150 million people have serious fungal diseases, which have a major impact on their lives or are fatal. However, severity ranges from asymptomatic-mild mucocutaneous infections to potentially life-threatening systemic infections (J

fungi 2017).

Aetiology & Pathogenesis

Predisposing factors in generating infection are: pre-existing diseases of skin and mucous membranes, use of topical corticosteroids, chronic maceration, intertrigo, increased sweating, indwelling plastic lines or implants that can serve as entry sites; diabetes mellitus, obesity, pregnancy, severe illness, malnutrition, antibiotic therapy and immunosuppression (including HIV). The disease is caused by the growth of sporophytic yeasts (skin, GI tract) or by infection (birth canal, sexual contact).

Signs & Symptoms

Candida infections can involve skin and mucous membranes, but in immunocompromised patients can be also systemic. They can manifest as intertriginous and anogenital candidiasis, onychomycosis, paronychia, oral candidiasis, intestinal candidiasis, systemic candidiasis, mucocutaneous candidiasis.

Most common clinical finding in acute oral candidiasis are easily removed white pseudomembranes (thrush). In chronic disease lesions can be erythematous, atrophic or hyperkeratotic and firmly adherent. In cases of angular stomatitis (perleche) white patches occur in the corner of the mouth. Median rhomboid glossitis is another manifestation of candidal infection and it manifests with atrophic patch on the mid central dorsal aspect of the tongue.

Vulvovaginal candidiasis is manifested with whitish discharge forming a removable coat on the vaginal wall. Other features are redness of the vulva and the inguinal region. In candida balanitis, there may be circumscribed redness, grey-whitish coating or erosions with overlying exudate on the foreskin (balanoposthitis), predisposing factors are: wet-warm environments in the prepuce space, bad hygiene, specifically insufficient drying after washing or sexual intercourse with a partner that has candida vulvovaginitis. There is a risk of phimosis due to inflammation.

Candida usually do not grow on normal glabrous skin, but when the area is moist and macerated, growth is promoted. Candidal intertrigo is the most common complication of intertrigo, manifesting as macerations with fissures and scattered outbreaks (satellite lesions) in the surrounding area. Often pustules are present.

Candida folliculitis can lead to small follicular pustules, particularly in the beard area of adult males. It is most common in immunocompromised patients.

Candidal paronychia usually develop in persons who have damaged cuticle. It is characterised by painful swelling with purulent discharge. Secondary to paronychia, a candidal onychomycosis can develop. In

the beginning of the infection, candidal onychomycosis is characterised by ridges but in later stages can develop to crumbly destruction of the entire nail.

Chronic mucocutaneous candidiasis refers to etiologically unrelated diseases with immune and barrier defects that predispose chronic candidal infections.

Localisation

Mainly in moist areas (intertriginous regions, mucosa).

Laboratory & other workups

KOH examination of mycology scrapings. Culture over the course of 1 to 4 days; white or cream colonies with a dull surface and without air mycelium; differentiation by means of micromorphology on rice agar (chlamydo spores in *C. albicans*) or biochemical/PCR.

Course

Generally good if diagnosed and treated correctly. Outlook poor in candidal sepsis, depending on underlying disease.

Diagnosis

Clinical features, laboratory findings.

Differential Diagnosis

Depends on location: lichen planus, leukoplakia, food remnants, secondary syphilis, flexural psoriasis, bacterial infections, other fungi.

Prevention & Therapy

Stop predisposing factors (often opportunistic infections). In persons with predisposing factors, it is useful to apply drying measures (i.e. blow drying after bathing, use of powders).

Topical and, where appropriate, systemic antifungal therapy. Polyenes (nystatin, amphotericin B) and azoles are effective in treating these fungal infections. Depending on localization: creams and ointments (trunk and extremities), pastes (intertriginous), lacquer paint (nails), suppositories/vaginal tablets (vaginal), lozenges and suspensions (oral mucosa). Systemic therapy of a severe local candidiasis (fluconazole, itraconazole, posaconazole). For invasive candidiasis: amphotericin, echinocandine and intravenous flucytosine.

References

- [Taudorf EH, Jemec GBE, Hay RJ, Saunte DML. Cutaneous candidiasis - an evidence-based review of topical and systemic treatments to inform clinical practice. J Eur Acad Dermatol Venereol. 2019; 33:1863-1873.](#)
- [Millsop JW, Fazel N. Oral candidiasis. Clin Dermatol. 2016; 34:487-94.](#)
- [Chew SY, Than LT. Vulvovaginal candidosis: contemporary challenges and the future of prophylactic and therapeutic approaches. Mycoses. 2016; 59:262-73](#)

2.3.3 Pityriasis Versicolor

Grading & Level of importance: B
Z. Bukvić Mokos, Zagreb; B. Marinović, Zagreb



ICD-11

1F2D.0

Synonyms

Tinea versicolor.

Definition

Pityriasis versicolor is a superficial cutaneous mycosis caused by lipophilic *Malassezia* yeasts (primarily *M. globosa*) characterized by hypo- and hyperpigmented macules with pityriasiform scales, most commonly located on the trunk.

Epidemiology

The disease is most frequently found in young adults and commonly occurs in spring and summer seasons, particularly in humid climates.

Aetiology & Pathogenesis

Causative lipophilic *Malassezia* yeasts belong to the resident flora of human skin. Predisposing factors that trigger hyphal growth stage include sweating, humid climate, and immunosuppression.

Malassezia species produce substances that block melanin synthesis, which may contribute to the development of hypopigmented macules.

Signs & Symptoms

The clinical features are variable and include several clinical types:

- Hyperpigmented type: disseminated, yellow-brown macules of 1-3 centimeters in diameter with pityriasiform scales and sometimes modest pruritus.
- Depigmented type (pityriasis versicolor alba): small white macules in dark-skinned or tanned individuals.
- Erythematous type: erythematous macules with infiltrate and only minimal scale.
- Atypical forms: solitary or few lesions, often in atypical sites.

Localisation

The favoured site is the upper trunk, as it is rich in sebaceous and eccrine glands. The lower trunk and proximal extremities are less often affected.

Classification

Non applicable.

Laboratory & other workups

KOH examination of a specimen taken from the scale shows grouped spores and pseudohyphae which has been described as “spaghetti and meatballs pattern”. Wood’s light (365 nm) examination reveals yellow-orange fluorescence of the affected areas.

Dermatopathology

Histology is generally not required, but if it is performed, hyphae and spores can be found in the stratum corneum.

Course

The disease is usually recurrent, but sometimes it clears spontaneously. Pigmentary changes may remain for weeks or months after the treatment.

Complications

None.

Diagnosis

The diagnosis is based on typical clinical features and microscopic examination of scales. Additional diagnostic tool is Wood's light (365 nm) examination.

Differential Diagnosis

Vitiligo can be excluded clinically by the absence of scales. KOH and Wood's light examination may help to exclude pityriasis alba, pityriasis rosea and seborrheic dermatitis. Another diagnostic consideration may be tinea corporis.

Prevention & Therapy

Patients should be advised about preventive measures that include wearing breathable fabrics, such as cotton, to decrease sweating, and avoidance of tight clothing as well as the use of oily skin products. Topical treatment of the entire body is usually effective. It includes the use of antifungal shampoos containing imidazoles (ketoconazole, econazole), selenium sulfide or zinc pyrithione; twice weekly for 2-4 weeks. In cases with frequent recurrences or widespread involvement systemic anti-fungals such as itraconazole (200 mg per os daily for 5-7 days) can be recommended.

Special

None.

References

- [Gupta AK, Lyons DC. Pityriasis versicolor: an update on pharmacological treatment options. Expert Opin Pharmacother. 2014; 15:1707-13.](#)
- [Prohic A, Jovovic Sadikovic T, Krupalija-Fazlic M, Kuskunovic-Vlahovljak S. Malassezia species in healthy skin and in dermatological conditions. Int J Dermatol. 2016; 55:494-504.](#)

2.4 Parasites and Arthropodes

2.4.1 Leishmaniasis

Grading & Level of importance: B

Z. Bukvić Mokos, Zagreb; S. Hobelsberger, Dresden; B. Marinović, Zagreb



ICD-11

1F54.1

Synonyms

Old World cutaneous leishmaniasis: oriental sore, Baghdad boil, Delhi boil; New World cutaneous leishmaniasis: chiclero ulcer, uta, jungle yaws; Mucocutaneous leishmaniasis: espundia; Visceral leishmaniasis: kala-azar, dumdum fever.

Definition

Leishmaniasis is a parasitic infection caused by *Leishmania* (L.); a protozoan. There are four typical clinical forms (see Classification).

Epidemiology

There are approximately 2 million new cases of leishmaniasis worldwide. Cutaneous leishmaniasis (CL) predominantly occurs in the Middle East and South America. Mucocutaneous leishmaniasis (MCL) is usually found in Central and South America. Visceral leishmaniasis (VL) is most frequently seen in Africa and Asia.

Aetiology & Pathogenesis

The main reservoir of *Leishmania* are dogs and rodents, and the parasites are transmitted by female phlebotomus sandflies only. Depending on species, different animal reservoirs (for example wild rabbits and dogs for *L. infantum*), and host's immune status, different clinical patterns occur (see Classification).

- CL species:
 - the Old World: *L. major*, *L. tropica*, *L. aethiopica*, *L. infantum*.
 - the New World: *L. mexicana* and *L. brasiliensis*.
- MCL species: *L. braziliensis*
- VL species: *L. donovani*, *L. infantum*, *L. chagasi*

Signs & Symptoms

- CL: After an incubation period of 2-4 weeks, an erythematous papule develops at the site of the bite and slowly progresses to an ulcerated hyperkeratotic plaque or nodule. Occasional satellite papules are present. Usually, the lesion heals spontaneously over a period of months with scarring.
- MCL: For several months or even decades after the infection, ulcerations of the skin and mucosa occur, involving the nose, lips, oral cavity and pharynx.
- VL: Systemic signs and symptoms include fever, cough, weight loss, lymphadenopathy, hepatosplenomegaly, anaemia. Specific skin lesions are grey macules, that gave rise to the name kala-azar (black fever).

Localisation

Most commonly affected sites are face, forearms, and legs.

Classification

There are three main clinical forms: cutaneous leishmaniasis, mucocutaneous leishmaniasis and visceral leishmaniasis.

Laboratory & other workups

Giemsa-stained smears (tissue impression smears, dermal scrapping or needle aspiration) or biopsy specimens demonstrate the presence of amastigote parasites. Culture is performed on Novy-McNeal-Nicolle (NNN) medium. Serology (ELISA or indirect immunofluorescent studies) is helpful in MCL. PCR assay is a highly sensitive and high specific method which makes it the diagnostic method of choice if available.

Dermatopathology

In early lesions amastigote parasites may be seen in dermal macrophages. The chronic lesions are characterized by granulomatous inflammation (tuberculoid granulomas).

Course

CL, particularly the Old World subtypes, may resolve spontaneously. MCL has a progressive course and may be lethal due to secondary infections and aspiration pneumonia. VL is a serious and progressive disease which is lethal in 75-95% of patients if untreated.

Complications

Complications include diffuse cutaneous leishmaniasis, persistence of the infection, relapses, involvement of mucous membranes (*L. braziliensis*) and systemic spread (*L. donovani*, *L. infantum*).

Diagnosis

It is based on travel history and clinical features. Diagnosis is confirmed by identification of a parasite in a smear preparation or skin biopsy, culture, PCR assay, or serology.

Differential Diagnosis

Ulcers, infiltrates due to other causes, ecthyma in travelers.

Prevention & Therapy

Prevention measures include vector control, use of insect repellents, protective clothing, and fine-mesh screens.

Therapy includes cryosurgery, local heat therapy, excision, topical paromomycin, intralesional or systemic application of antimony compounds (sodium stibogluconate i.v. or i.m., meglumine antimonite i.m.) and oral itraconazole. The recommended daily dose for systemic antimony compounds is 20 mg/kg for 14-20 days.

Special

None.

References

- [de Vries HJC, Schallig HD. Cutaneous Leishmaniasis: A 2022 Updated Narrative Review into Diagnosis and Management Developments. Am J Clin Dermatol. 2022 Nov;23\(6\):823-840. doi: 10.1007/s40257-022-00726-8. Epub 2022 Sep 14. PMID: 36103050; PMCID: PMC9472198.](https://doi.org/10.1007/s40257-022-00726-8)

2.4.2 Scabies

Grading & Level of importance: A
Z. Bukvić Mokos, Zagreb; B. Marinović, Zagreb



ICD-11

1G04

Synonyms

Sarcoptic itch; Seven-year itch.

Definition

Scabies is an intensely pruritic skin infestation caused by the mite *Sarcoptes scabiei* var. *hominis*.

Epidemiology

Approximately 300 million individuals are affected worldwide each year. Overcrowding (due to poverty, wars, or natural disasters) promotes the spread of the disease. The infestation commonly spreads among family members.

Aetiology & Pathogenesis

Sarcoptes scabiei var. *hominis* is a human ectoparasite with marked host specificity. Human-to-human transmission occurs with close personal contact, sometimes via clothing or bedding. Female mites (0.3-0.5 mm long) dig a burrow in the stratum corneum of the epidermis to lay their eggs and its feces (scybala). Sexually mature mites develop in 3 weeks. In immunocompetent adults, the number of mites that live on skin surface is usually limited to 10-12 in total. Immunologic reaction to mite antigens causes inflammation and pruritus.

Signs & Symptoms

Symptoms usually develop 3-6 weeks after first infestation, or within 24 hours after re-infestation. Severe pruritus, especially at night, is present. Initially the mites burrow and develop elongated inflamed papules; in infants there can be evidence of vesicles. An exanthema with tiny papules and fine crusts may be found symmetrically over the flanks and proximal extremities, indicating a cellular immunologic reaction against scabies antigens. Face and interscapular regions are spared. Later complications are excoriations, eczematization and impetiginisation. Occasionally there are minimal findings on examination, secondary to fastidious habits or use of topical corticosteroids (scabies incognito).

Localisation

The predilection sites for burrows include interdigital areas, anterior axillary folds, nipples, umbilicus, groin, penis, wrists and dorsal aspects of the feet. In children the face, scalp, palms and soles can be affected. The secondary exanthem affects the flanks and proximal extremities.

Classification

A special form of scabies is Norwegian (crusted) scabies, which results from massive infestation in immunosuppressed individuals. It clinically presents with generalized hyperkeratotic papules and/or plaques with thick scales. Norwegian scabies is highly contagious.

Laboratory & other workups

Microscopic examination demonstrates the mite, its eggs, or scybala (feces). Dermatoscopy can also help prediagnosing and guiding the site of scraping (see Chapter 9.2.1).

Dermatopathology

Histology is usually not necessary, except in cases when other dermatoses should be ruled out.

Course

Recurrences occur in considerable number of patients, especially immunosuppressed ones.

Complications

Complications include impetiginisation, eczematization, post scabietic papules (nodular scabies) and persistent inflammatory reaction without presence of mites. Itching often persists after successful eradication of the mites.

Diagnosis

Diagnosis is based on characteristic clinical features, including severe pruritus worsening at night and a history of contact with a person with pruritus. Microscopic examination demonstrates mites, its eggs or scybala (feces) from specimen obtained by skin scraping or de-roofing burrow with scalpel blade.

Differential Diagnosis

Differential diagnosis includes pruritic dermatoses, prurigo, dermatitis herpetiformis, urticaria, and psoriasis (in crusted scabies). Scabies burrows are useful for differentiation.

Prevention & Therapy

The treatment of choice is topical permethrin cream (5%) applied once for 8-12 hours. If there are still signs of active scabies after 14 days, the treatment should be repeated. Second line treatments include benzyl benzoate used on 3 consecutive days or crotamiton. Lindane (gamma-hexachlorocyclohexane) is comparatively toxic and in some countries no longer on the market. Ivermectin orally (single 400 mg dose for adults) is used in crusted scabies or if topical treatment is difficult.

Additional general measures should be taken to prevent reinfections. All family members and other contact persons should be treated. Clothing and bedding should be changed and washed. All non-washable items should be aired for 4 days (mites can live for 2-3 days at room temperature).

Special

None.

References

- [Arora P, Rudnicka L, Sar-Pomian M et al \(2020\) Scabies: A comprehensive review and current perspectives. Dermatol Ther 33\(4\): e13746.](#)
- [Scabies. Rachel L. Gilson, Jonathan S. Crane. In: Stat Pearls \[Internet\]. Treasure Island \(FL\): Stat Pearls Publishing; 2021 Jan. 2021 Aug 9.](#)
- [Sunderkötter C, Wohlrab J, Hamm H: Scabies: epidemiology, diagnosis, and treatment. Dtsch Arztebl Int 2021; 118: 695–704. DOI: 10.3238/arztebl.m2021.0296Dtsch Arztebl Int 2021; 118: 695–704](#)

2.4.3 Trombidiosis

Grading & Level of importance: B.
Z. Bukvić Mokos, Zagreb; B. Marinović, Zagreb



ICD-11

None.

Synonyms

Harvest itch, chigger itch.

Definition

Trombidiosis is an epizoonosis characterized by pruritic skin lesions caused by mite larvae (chiggers) of the Trombiculidae family.

Epidemiology

Larvae are most prevalent in forests and long and overgrown grass in fields and gardens in late summer and fall. In tropical areas, the infection may occur at any time of the year. The natural hosts are small rodents.

Aetiology & Pathogenesis

The skin reaction is caused by the larval form of *Trombicula*, a small plant mite (about 0.3 mm). It is sometimes known as harvest mites because they often infect grains, but they are also acquired in gardens and forests. Mites attach to passers-by and using enzymes to create a hole in the epidermis through which they can receive nutrients. The chemicals they release during this process cause intensive pruritus.

Signs & Symptoms

Usually, it starts with a small macule or wheal, which after 1-2 days develop to pruritic papules and /or papulo-vesicles. The lesions can last several weeks, during which they become excoriated. Secondary infection is possible.

Localisation

Lesions are located at the areas of constrictions of clothing. Common locations are on the neck above the shirt collar, on the legs just above the sock line or on the trunk just above the belt line.

Diagnosis

History and clinical findings. Almost impossible to find larva in human.

Differential Diagnosis

Other arthropod bites.

Prevention & Therapy

In general, a symptomatic therapy with topical corticosteroids or antipruritic agents is the first line.

Systemic antihistamines can be given. Regular use of repellents is effective. They should be applied about the clothing lines. Prophylaxis: avoidance of risk areas (gardens, parks, compost piles), insect repellents for garden work.

2.4.4 Pediculosis Capitis

Grading & Level of importance: B.



Z. Bukvić Mokos, Zagreb; B. Marinović, Zagreb

ICD-11

1G00.0

Synonyms

Head louse infestation; head lice; infestation by *Pediculus capitis*.

Definition

Pediculosis capitis is an infestation of scalp caused by the head louse, most commonly found in children.

Epidemiology

The disease occurs worldwide with various prevalence. Children and individuals with long hair are more often affected. Predominance among females has been estimated.

Aetiology & Pathogenesis

Head louse (*Pediculus capitis*, 2.25-4 mm) is a strictly human-specific ectoparasite (animal lice cannot grow and reproduce in humans). Head lice cannot live more than 1 week at room temperature without a host. The larvae hatch from eggs after 7 days and after a total of 2-3 weeks, the adult louse is sexually mature. Transmission is from human-to-human by direct contact or by shared fomites such as combs, brushes, hats, and bedding, especially under close living conditions. Headlice are often endemic in kindergartens and schools.

Signs & Symptoms

Markedly pruritic erythematous papules are found on the scalp, especially on the retroauricular and occipital areas and the nape of the neck. Nits (eggs) are firmly attached to hair shafts, whereas adult lice move freely. Scratching may produce dermatitis (louse eczema).

Localisation

Usually scalp is affected, especially retroauricular and occipital.

Classification

Not applicable.

Laboratory & other workups

Microscopic examination of the hair shaft may show the lice and the nits attached to the hair.

Dermatopathology

Not necessary.

Course

Recurrences are common.

Complications

Impetiginisation may occur with associated occipital and/or cervical lymphadenopathy. Hairs can become matted with pus and crust.

Diagnosis

Diagnosis is based on clinical features and identification of nits or lice.

Differential Diagnosis

Seborrheic dermatitis (nits are more tightly adherent to the hair shaft than dandruff), folliculitis, impetigo, atopic dermatitis.

Prevention & Therapy

Prevention measures: Combs, brushes and hats should not be exchanged.

Prevention of reinfection: Contact persons should be examined and treated as required. It is important to wash clothing, bedding and towels at 52°C minimum and dry well. Place items which cannot be washed in airtight plastic bags for 14 days and clean combs and hairbrushes in hot soapy water. Vacuum carpets, rugs, furniture and mattresses.

Therapy: Permethrin cream rinse or lotion, pyrethrins in various formulations, malathion lotion or shampoo, ivermectin lotion. General measures: both lice and nits must be killed.

Special

None.

References

- [Leung AKC, Lam JM, Leong KF, et al. \(2021\) Paediatrics: how to manage pediculosis capitis. Drugs Context. 11:11-3. https://doi.org/10.7573/dic.2021-11-3](https://doi.org/10.7573/dic.2021-11-3)

2.4.5 Pediculosis pubis

Grading & Level of importance: B.

Z. Bukvić Mokos, Zagreb; M. Janier, Paris; B. Marinović, Zagreb



ICD-11

1G03

Synonyms

Phthiriasis; infestation by crab lice; crabs.

Definition

Pediculosis pubis is a pruritic skin condition affecting the pubic, perianal and axillary regions, caused by bites from the pubic louse.

Epidemiology

Pediculosis pubis is found worldwide in all socioeconomic groups. The incidence rate is slightly higher in men. Among STD (sexually transmitted disease) clinic attendees, the estimated prevalence is approximately 2%. Other STDs commonly accompany this infestation.

Aetiology & Pathogenesis

Pubic louse (*Phthirus pubis*) is 1.3-1.6mm long. Pubic lice live for only two days at room temperature

without a host. Transmission occurs by close personal contact, particularly by sexual contact.

Signs & Symptoms

There is modest pruritus in pubic or other hairy regions. Distinctive (but not common finding) are maculae coeruleae (slate grey to blue-grey macules as a result of haemosiderin degradation products at the bite site). Nits attached to hair shafts and adult lice are tightly attached to the hairs near the skin surface.

Localisation

Hair bearing regions, especially pubic and perianal regions, are most commonly affected. Occasionally, the axillae, chest, abdomen, thighs and beard region may be infested. In children, eyelashes, eyebrows and rarely scalp can also be involved.

Classification

Not applicable.

Laboratory & other workups

The lice and nits can be identified by microscopic examination.

Dermatopathology

Generally not necessary.

Course

Recurrences may occur.

Complications

Impetiginisation may occur.

Diagnosis

It is based on clinical features (the lice and nits found at the affected areas, maculae coeruleae). Microscopic identification of nits and lice can confirm the diagnosis.

Differential Diagnosis

Scabies, arthropod bites.

Prevention & Therapy

Prevention: Sexual contact should be avoided until both sexual partners have been successfully treated.

Therapy: It is similar to pediculosis capitis. Topical treatment with permethrin cream or pyrethrins is the first line treatment. Consider repeating treatment after 10 days. It is very important to treat sexual contacts. Oral ivermectin may be used in resistant cases. Shaving is a simple option.

Special

The patient should be examined for other sexually transmitted diseases.

References

- [Salavastru CM, Chosidow O, Janier M, Tiplica GS \(2017\) European guideline for the management of pediculosis pubis. JEADV ,31,1425–1428](#)

2.4.6 Demodicosis

Grading & Level of importance: B
H. Gollnick, Magdeburg



ICD-11

1G07.0

Synonyms

Pityriasis folliculorum.

Definition

Demodex mites are living in the follicular canal of the skin. In case of an infectious course with inflammation and a high density of demodex mites (> 5/cm²) it is called Demodicosis.

Epidemiology

Around 90% of the world population have some demodex mites on the body surface, but around 5 to 10% only suffer from a demodex infection.

Aetiology & Pathogenesis

Most infections are caused when demodex mites are overpopulating, penetrating the follicular wall, colonizing the follicular opening and interfollicular epidermal surface. Two types have to be differentiated: *Demodex folliculorum* and *Demodex brevis*. They have eight legs. Larva stage takes 7 days, adult life time around two to three weeks. Whereas *D. brevis* (0.15-0.2 mm) is mostly found in the follicles of the eye lashes, *D. folliculorum* (0.2-0.4 mm) is found in the sebaceous follicles. Usually, the mites are not found in infants. Aged skin with wider follicular openings predisposes the growth. Other predisposing factors include aged skin with actinic elastosis, immunodeficiency such as HIV infection or under chemotherapy, alcoholism and diabetes. In rosacea it is an important factor in driving the inflammatory course and leading to granulomatous courses because mites invade the sebaceous duct which ruptures and they enter the papillary and deeper dermis. Demodex mites harbour *Bacillus oleronius* which may contribute to additional inflammation.

Signs & Symptoms

Demodex mites move in the night 8-16mm /h over the skin, deposit eggs and can produce itch and tickling. Light makes them moving back to the follicle to hide. Skin feels sensitive and sometimes more scaly, may produce tiny rough feeling by striking over the surface (spinula like pattern) and shows some redness. Rarely an eczematous pattern is observed. The appearance of papules and pustules mimick an acneiform feature. The lesions are mostly not symmetrically located. Sometimes small abscesses develop. In particular the eye lashes are prone to have strong irritating feeling when blinking and hordeolum like lesions can appear. Severe conjunctivitis and loss of eye lashes can follow. At the external ear canal an increased scaling and itching is recognized.

Localisation

Demodex mites are preferentially found on the facial skin. The forehead with high density of sebaceous gland follicles are predisposed followed by the nose cheeks, chin, eye lashes and outer ear canal. In males with long standing alopecia demodex mites are also found on the naked scalp.

Classification

No specific.

- *Demodex folliculorum* (spinulate demodicosis or pityriasis folliculorum)
- papulopustular/nodulocystic or conglobate demodicosis

- ocular demodicosis

Laboratory & other workups

Dermatoscopy can make the spinula visible. A cyanoacrylate tape stripe can help to visualize the mites under the microscope and numbers can be counted for therapy success (in clinical trials).

Dermatopathology

Not necessary for a normal diagnosis, but in granulomatous diseases of the face and in rosacea recommended. The mites are in masses populating the follicular canal with folliculitis and perifolliculitis. In case of penetrating the wall, foreign body reaction appears in the dermis.

Course

Chronic or recurs frequently.

Complications

Scratching with secondary infection with other microbes. Furuncle.

Diagnosis

Dermatoscopy, KOH preparation, cyanoacrylate stripe and clinical picture.

Differential Diagnosis

Seborrheic dermatitis, periorificial dermatitis, acne, folliculitis, superficial granulomatous sarcoidosis.

Others: follicular T-cell-lymphoma, spinula follicular pattern in plasmocytoma, P-type of atopic dermatitis, tinea follicularis and candida.

Prevention & Therapy

Prevention: regular use of facial cleansers, avoiding UV light as promoter of actinic elastosis. Hands off from the face. In immunodeficient status an accompanying application of permethrin / ivermectincream can be considered.

Therapy: Topical treatment is the mainstay. Life span with production of new larvae has to be considered.

Weekly application of 5% permethrin ointment including antiseptics in case of papulo-pustular pattern over 4 weeks. Other options are 1.0% ivermectin creme daily long-term. In granulomatous and absceding courses an oral ivermectin treatment is necessary. In rosacea with demodex provocation ivermectin crème 1% long-term is essential.

Special

None.

References

- [Human demodicosis: revisit and a proposed classification W. Chen and G. Plewig. British Journal of Dermatology \(2014\)170, pp1219–1225.](#)
- [Jacob Sh, VanDaele MA & Brown JN \(2019\) Treatment of Demodex-associated inflammatory skin conditions: A systematic review. Dermatologic Therapy 32: e13103.](#)

2.4.7 Arthropod reactions

Grading & Level of importance: B 

Z. Bukvić Mokos, Zagreb; B. Marinović, Zagreb

ICD-11

EK50.0

Synonyms

Ticks, stings, arthropod reaction.

Definition

It is necessary to distinguish between: 1) reactions to toxins from insect bites; and 2) reactions to bites of parasitic insects.

- Permanent ectoparasites are parasitic insects (or arachnids; mites or ticks) that live on humans. They are highly adapted and can be found on human hosts.
- Temporary-accidental ectoparasites bite humans by chance. The bite reaction varies greatly, and the parasite is rarely found on patients.

Epidemiology

Prevalence is hard to estimate because most cases do not require medical intervention. Insect bites are more common in tropical climates.

Aetiology & Pathogenesis

Human ectoparasites:

Permanent ectoparasites insects: head louse, clothing louse, pubic louse. Arachnids: *Demodex* and *Sarcoptes scabiei*.

Accidental parasitic insects: bed bugs, fleas, mosquitoes, sandflies, gnats, flies and horse flies. Accidental parasitic arachnids: ticks, *Neotrombicula* (see Trombiculosis), bite mites (*Dermanyssus*), non-burrowing animal mites (*Cheyletiellidae* = walking mange), animal forms of scabies (*Sarcoptidae* and others).

Signs & Symptoms

- Immediate reaction at site of sting is characterized by macules, erythema, or wheals.
- Delayed reaction develops after 24-48h and may present as papules, macules, erythema, or wheals.

The nature of the reaction depends more on the sensitisation of the victim than the nature of the stinging insect.

Localisation

The lesions are localized on exposed skin areas, i.e. head, neck, extremities.

Classification

See Aetiology and Pathogenesis.

Laboratory & other workups

None specific.

Dermatopathology

Not necessary.

Course

Varies from self-limited mild local reaction to life threatening anaphylactic reaction.

Complications

Persistent arthropod reaction with other complications: pseudolymphomatous reactions, persistent prurigo nodularis-like lesions, secondary bacterial infection. Arthropod borne systemic infections.

Diagnosis

Clinical features are diagnostic (grouped or linearly arranged pruritic papules, sometimes with central haemorrhagic punctae (purpura pulicans).

Differential Diagnosis

Insect bite reactions should be differentiated from folliculitis, impetigo, furuncle, carbuncle, prurigo, dermatitis herpetiformis, erysipelas, and blistering diseases.

Prevention & Therapy

Topical antipruritic agents (zinc oxide lotion, antipruritic cream, corticosteroid lotions).

Antihistamines inspecial situations of IgE mediated reactions (e.g. mosquitoes).

Preventive measures include wearing protective clothing, sleep under fine-mesh nets, and the use of repellents.

Special

None.

References

- [Montag A \(2021\) Diseases Caused by Arthropods. In: Plewig, G., French, L., Ruzicka, T., Kaufmann, R., Hertl, M. \(eds\) Braun-Falco's Dermatology. Springer, Berlin, Heidelberg. https://doi.org/10.1007/978-3-662-58713-3_23-1](https://doi.org/10.1007/978-3-662-58713-3_23-1)

2.4.8 Bee and wasp stings

Grading & Level of importance: B

Z.Bukvić Mokos, Zagreb; B. Marinović, Zagreb



ICD-11

XM7930

Synonyms

Hymenoptera stings.

Definition

Reactions to stings of bees and wasps.

Epidemiology

Prevalence is hard to estimate because most cases do not require medical intervention. Approximately 25% of anaphylactic reaction develop due to stings of Hymenoptera insects.

Aetiology & Pathogenesis

Bees and wasps.

Signs & Symptoms

Local reactions may occur as macules, papules, erythema, or wheals. Systemic reactions are classified in stages (see Complications). First sign is usually pruritus. Complete picture includes flushing, angioedema, hypotension, bronchospasm, nausea, abdominal colic, cramping, incontinence of urine and stool. 50% of symptoms appear with 5 minutes, another 40% within 30 minutes.

Localisation

The lesions are localized on exposed skin areas, i.e. head, neck, extremities.

Classification

See Aetiology and Pathogenesis.

Laboratory & other workups

In cases of Hymenoptera allergy identification of specific IgE in serum (RAST) should be done.

Dermatopathology

Not necessary.

Course

Varies from self-limited mild local reaction to life threatening anaphylactic reaction.

Complications

Grading of allergic reactions to Hymenoptera:

- Grade 0: increased local reaction (>10 cm, >24 h).
- Grade 1 (mild generalized reaction): widespread urticaria, pruritus, malaise, anxiety.
- Grade 2 (moderate generalized reaction): the above symptoms and two or more of the following: angioedema (Grade 2 even if solitary), tightening of chest, nausea, vomiting, diarrhoea.
- Grade 3 (severe generalised reaction): any of the above and two or more of the following: dyspnoea (Grade 3 even if solitary), stridor, dysphagia, dysarthria, excitement, confusion, fear of death.
- Grade 4 (shock reaction): any of the above and two or more of the following: cyanosis, hypotension, collapse, incontinence of urine or stool, loss of consciousness.

Diagnosis

Diagnosis is based on clinical features (local reaction, general features), intracutaneous testing to identify threshold of reactivity (titration with aqueous solutions of wasp and bee toxins), and specific IgE.

Differential Diagnosis

Bee and wasp stings should be differentiated from bites from other insects, particularly other Hymenoptera (hornets and bumblebees), hives, and angioedema.

Prevention & Therapy

Therapy:

1. Local reaction: topical steroids or antipruritic agents, ice packs, oral antihistamines in cases of intense pruritus.
2. Hymenoptera allergy: Mild generalized reaction: antihistamines i.v., perhaps corticosteroids p.o. or i.v. (100 mg prednisone or equivalent); bronchospasm: beta-sympathomimetic metered aerosol inhaler, observe for 1 h. Severe generalized reaction: epinephrine s.c. or i.m. or diluted i.v. (1-3 ml of a mixture of 1 mg epinephrine in 10-20 ml NaCl solution), corticosteroids i.v. (250 mg prednisone or equivalent), antihistamines i.v., fluid replacement; laryngeal oedema: epinephrine aerosol metered inhaler, with bronchospasm, perhaps theophylline. Patient with the history of previous allergic reaction should carry an emergency set (2 tablets prednisone 50 mg, 2 tablets of a rapid-acting antihistamine, epinephrine self-injector (Epipen) or metered aerosol inhaler). Hyposensitization (always with Grade 3-4 reactions).

Preventive measures include wearing protective clothing, sleep under fine-mesh nets, and the use of repellents.

Special

None.

References

- [Sahiner UM, Durham SR. Hymenoptera Venom Allergy: How Does Venom Immunotherapy Prevent Anaphylaxis From Bee and Wasp Stings? Front Immunol. 2019 Aug 21;10:1959. doi: 10.3389/fimmu.2019.01959. PMID: 31497015; PMCID: PMC6712168.](#)
- [Adib-Tezer H, Bayerl C. Honeybee and wasp venom allergy: Sensitization and immunotherapy. J Dtsch Dermatol Ges. 2018 Oct;16\(10\):1228-1247. doi: 10.1111/ddg.13670. PMID: 30300499.](#)

2.5 Sexually Transmitted Infections

2.5.1 Gonorrhea



Grading & Level of importance: A

E. Hiltunen-Back, Helsinki; M. Janier, Paris; A. Ranki, Helsinki; A. Salava, Helsinki

ICD-11

1A7Z

Synonyms

Blenorrhagia; gonococcal infection.

Definition

Urogenital, anorectal or oral infection by *Neisseria gonorrhoeae*; rarely systemic infection (disseminated gonorrhea).

Epidemiology

After chlamydial urethritis, gonorrhea is the second most common bacterial sexually transmitted infection. The World Health Organization estimates that in 2020, 82 million new cases occurred among adolescents and adults aged 15-49 years worldwide. In Europe in 2017, 89,000 gonorrhea cases were reported in 27 countries. The notification rate was 22.2 cases per 100,000 population. In many European countries, the incidence of gonorrhea is increasing especially among young adults and men having sex with men.

Aetiology & Pathogenesis

Gonorrhea is caused by the Gram-negative diplococcus bacterium *Neisseria gonorrhoeae*. The incubation period is usually 2-7 days, but may be as short as 24 hours. Transmission happens by infected secretions during genital, anorectal or oral sex. Autoinoculation from the anogenital area can cause conjunctivitis. Mothers with gonococcal infection can infect the infant at delivery causing neonatal conjunctivitis with purulent ocular discharge and swollen eyelids (ophthalmia neonatorum). Co-infection with *Chlamydia trachomatis* is detected in 10-40% of the cases.

Signs & Symptoms

Gonorrhea infection involves the columnar epithelium of urethra, endocervix, rectum, pharynx and conjunctivae.

- Typical manifestations of gonococcal infection in men include acute urethritis with symptoms of urethral discharge, pain on urination and dysuria. The clinical signs are mucopurulent urethral discharge, meatal edema and balanoposthitis.
- Gonorrhoea is generally asymptomatic in women. The typical complaints include abnormal vaginal discharge, dysuria, and lower abdominal pain. In clinical examination vaginal discharge and mucopurulent cervicitis can be detected.
- Rectal infections in men and women are often asymptomatic, but can cause rectal and anal pain or discharge.
- Pharyngeal gonorrhoea is mainly asymptomatic, but patient might complain of a sore throat and pharyngitis.

Localisation

See symptoms.

Classification

Classification is usually based on either the disease course (acute and chronic) or disease localization (localized, i.e. urogenital, anorectal or oral infection; or disseminated infection).

Dermatopathology

Not necessary.

Course

The symptoms may occur acutely or the infection may follow a chronic (in women often asymptomatic) chronic course. *N. gonorrhoeae* has shown a notable capacity to develop resistances to multiple classes of antibiotics. Be aware of resistant strains.

Complications

- Untreated infection can ascend in women to the upper genital tract causing serious complications and sequelae such as pelvic inflammatory disease (PID), including endometritis, salpingitis and tubo-ovarian abscess, which can lead to ectopic pregnancy and infertility.
- In men it can cause epididymo-orchitis and prostatitis.
- Gonorrhoea can rarely disseminate as bacteremia with fever, arthritis, perihepatitis (Fitz-Hugh-Curtis syndrome), tenosynovitis and skin lesions (disseminated gonococcal infection, DGI).

Diagnosis

The diagnosis is based on clinical features and on microbiological confirmation of the infection.

Laboratory & other workups

N. gonorrhoeae can be detected by nucleic acid amplification tests (NAATs) and/or culture.

NAATs are highly sensitive and specific tests that can detect *N. gonorrhoeae* in first void urine and urethral, vulval, cervical, pharyngeal and rectal swab. Tests should be taken as directed by sexual practices.

Samples can be either clinician-collected or self-collected. NAATs are less demanding in transport and storage than culture. In diagnosing genital gonorrhea, first-void urine is an optimal specimen type for men, but in women a swab from the vagina (self-collected vulvo-vaginal specimen) or endocervix is more sensitive. Current commercial NAATs cannot provide information on antimicrobial susceptibility. Thus, specimens should be collected also for culture and antimicrobial susceptibility testing.

In symptomatic men with urethritis, diplococci within polymorphonuclear leukocytes can be detected in Gram-stained smears of discharge in microscopy.

Differential diagnosis

Gonorrhea cannot be distinguished clinically from chlamydia or other possible causes of urethritis and cervicitis like *Mycoplasma genitalium*, or *Trichomonas vaginalis*. Herpes simplex virus infection can cause dysuria and meatitis.

Prevention & Therapy

Transmission can be prevented by barrier contraception.

The treatment of gonococcal infections is challenging due to the rapidly changing antimicrobial susceptibility patterns of *N. gonorrhoeae*. There are concerns worldwide about the eventual development of untreatable gonococcal infections. In the past, *N. gonorrhoeae* has developed resistance to several antibiotics (penicillins, tetracyclins, macrolides and fluoroquinolones). Current European guidelines recommend empirical first-line dual therapy with ceftriaxone 1 g intramuscularly (i.m.) together with azithromycin 2 g as a single oral dose. Fluoroquinolones (ciprofloxacin 500 mg as a single oral dose) can be used only if the resistance is excluded by susceptibility testing. Patients with penicillin anaphylaxis or cephalosporin allergy can be treated with spectinomycin 2 g i.m. together with

azithromycin 2 g orally.

Patients are advised to abstain from all sexual contact for seven days after the completion of their treatment. All sex partners within the preceding 60 days should be evaluated. The test of cure (TOC) is recommended to identify persisting infection and emerging resistance >2 weeks after the treatment.

Special

Tests for other STIs, like chlamydial urethritis, syphilis and HIV should be strongly recommended. Written information about the gonorrhoea infection should be provided. Test-of-cure > 2 weeks after completion of treatment is recommended routinely for all patients. In order to control the spread of the infection, it is important to evaluate the sex partners of the patient within the preceding two months and offer them testing and treatment.

All gonorrhoea cases should be reported according to the local communicable disease legislation.

References

- [Van Ommen CE, Malleson S, Grennan T. \(2023\). A practical approach to the diagnosis and management of chlamydia and gonorrhoea. CMAJ. 2023 Jun 19;195\(24\): E844-E849. doi: 10.1503/cmaj.221849. PMID: 37336564](#)
- [mbrowski JC. \(2021\). Chlamydia and Gonorrhoea. Ann Intern Med. Oct;174\(10\): ITC145-ITC160. doi: 10.7326/AITC202110190. Epub 2021 Oct 12. PMID: 34633834.](#)
- [Unemo M, Ross J, Serwin AB, Gomberg M, Cusini M, <https://pubmed.ncbi.nlm.nih.gov/33121366/> diagnosis and treatment of gonorrhoea in adults. Int J STD AIDS. Oct 29;956462420949126. doi: 10.1177/0956462420949126. PMID: 33121366.](#)

2.5.2 Chlamydial Urethritis

Grading & Level of importance: B



E. Hiltunen-Back, Helsinki; M. Janier, Paris; A. Ranki, Helsinki; A. Salava, Helsinki

ICD-11

1A81.0

Synonyms

None.

Definition

Chlamydial urethritis is a urogenital infection caused by *Chlamydia trachomatis*. It is the most common sexually transmitted infection in Europe and may cause considerable morbidity and long-term reproductive health problems, particularly in young people. Infections are often asymptomatic causing delay of diagnosis and uninterrupted transmission. Chlamydia was previously known as non-gonococcal urethritis (NGU). Some 30-50% of non-gonococcal urethritis is believed to be due to chlamydia. Chlamydia infection is predominantly transmitted sexually but may be transmitted during delivery from mother to a newborn.

Epidemiology

Worldwide it was estimated that 127 million adults aged 15-49 years encountered a new chlamydia infection in 2020. For 2017, 26 EU/EEA Member States reported 409 646 cases of chlamydia infection, with the crude notification rate 146 cases per 100,000 population. Sexually active young people are at the greatest risk of getting chlamydia, and women below 24 years of age have the highest number of infections in Europe. Sexual risk behavior is an important risk factor and reinfection rates of 10-30% have been documented among young adolescents with multiple sex partners.

Aetiology & Pathogenesis

Urogenital chlamydia infection is caused by strains D-K of the *Chlamydia trachomatis* bacterium. *C. trachomatis* is an intracellular Gram-negative bacterium which can cause acute eye infections, trachoma (genotypes A, B and C), genital infections and lymphogranuloma venereum (LGV) (genotypes L). The incubation period is usually 1-3 weeks.

Signs & Symptoms

Chlamydia infection is often asymptomatic. It is estimated that 70% of genital *C. trachomatis* infections in women and 50% in men are asymptomatic at the time of diagnosis. Spontaneous resolution of asymptomatic infections is possible, but many patients will at some point develop symptoms and clinical disease. Acute urethral syndrome, a condition with symptoms suggestive of lower urinary tract infection in the absence of significant bacteriuria, can be caused by *C. trachomatis*.

- In men symptoms like mild meatal irritation, burning sensation, dysuria, urgency and frequency of urination may appear. Mild mucoid or mucopurulent urethral discharge in the morning is less profuse than in gonorrhoea. Males may complain of testicular pain and epididymitis.
- In women, chlamydial urethritis can similarly cause dysuria, urgency and frequency of urination. In women, chlamydial cervicitis can cause vaginal discharge, postcoital bleeding and abdominal pain.

- Proctitis and pharyngitis are often asymptomatic. Anorectal infection can cause anal discharge and discomfort and pharyngeal chlamydia mild sore throat. Conjunctivitis can be the result of contact with contaminated hands, or direct exposure to semen and vaginal fluids.

Localisation

See symptoms.

Classification

Usually, classification is made based on the localisation of the infection.

Dermatopathology

Not required.

Complications

Also, asymptomatic *C. trachomatis* infections can cause long-term complications. Urogenital chlamydial infection might be mild in clinical picture, but the complications in men include epididymitis, epididymo-orchitis and rarely sexually acquired arthritis (SARA). In women chronic pelvic pain and infertility can be the sequelae from pelvic inflammatory disease (PID) followed by untreated *C. trachomatis* infection. There is no strong evidence that *C. trachomatis* causes infertility in men.

Diagnosis

The diagnosis is based on clinical features and microbiological confirmation of the infection.

Laboratory & other workups

Nucleic acid amplification tests (NAATs) are the most sensitive and the most widely used tests for the detection of genital chlamydia. Positive NAAT result can be observed within a few days of exposure but at the latest 2 weeks later. NAATs can detect *C. trachomatis* in first void urine and urethral, vulvo-vaginal, cervical, pharyngeal and rectal swabs. For men, the first-void urine sample is reliable, but the patients should be instructed how to collect the sample. Point of Care Tests cannot be used for self-collected swabs and allows for self-testing outside of the clinic. Serology is not recommended for screening of anogenital *C. trachomatis* infections. Only invasive infections will lead to detectable levels of antibodies which might remain positive for years.

Differential Diagnosis

Chlamydia cannot be distinguished clinically from gonorrhoea or other possible causes of urethritis like *Mycoplasma genitalium*, *Trichomonas vaginalis*. Urethral Herpes simplex virus infection can also cause dysuria and meatitis.

Prevention & Therapy

Transmission of the infection can be prevented by barrier contraception.

Chlamydia is effectively treated with antibiotics, of which doxycycline and azithromycin have cure rates of 95%.

The European guidelines recommend for uncomplicated urogenital *C. trachomatis* infections as the first-line treatment doxycycline 100 mg twice a day for seven days (contraindicated in pregnancy) or azithromycin 1 g as a single dose.

Patients are advised to abstain from all sexual contacts for seven days after the completion of their treatment. Tests for other STIs, like gonorrhoea, syphilis and HIV should be strongly recommended. Written information about the chlamydia infection should be provided.

Special

Test-of-cure 4 weeks after completion of therapy is not recommended routinely in patients treated with the recommended first-line regimens. However, this test should be performed in pregnant women, in patients with complicated or persisting clinical findings, with second-line treatment, and if there is a suspicion of non-compliance or re-exposure of infection. In order to control the spread of the chlamydia infection, it is important to evaluate the patient's sex partners from a period of the preceding six months and to offer them testing and treatment.

References

- [Dombrowski JC. \(2021\) Chlamydia and Gonorrhoea. Ann Intern Med. Oct;174\(10\): ITC145-ITC160. doi: 10.7326/AITC202110190. Epub 2021 Oct 12. PMID: 34633834.](#)
- [Sell J, Nasir M, Courchesne C. \(2021\). Urethritis: Rapid Evidence Review. Am Fam Physician. 2021 May 1;103\(9\):553-558. PMID: 33929174.](#)
- [Horner PJ, Blee K, Falk L, van der Meijden W, Moi H. \(2016\). 2016 European guideline on the management of non-gonococcal urethritis. Int J STD AIDS. Oct;27\(11\):928-37. doi: 10.1177/0956462416648585. Epub 2016 May 4. PMID: 27147267.](#)

2.5.3 Lymphogranuloma venereum

Grading & Level of importance: C



E. Hiltunen-Back, Helsinki; M. Janier, Paris; A. Ranki, Helsinki; A. Salava, Helsinki

ICD-11

1A80

Synonyms

Chlamydial lymphogranuloma; Frei disease; Nicolas-Favre disease; climatic bubo.

Definition

Lymphogranuloma venereum is an uro- and anogenital infection caused by *C. trachomatis*, serovars L1-3.

Epidemiology

In India and Africa LGV is estimated to account for less than 10% of genital ulcer disease (GUD). In Europe the current LGV epidemic has been detected among MSM and causing mainly proctitis. Some cases of heterosexual LGV have been seen in Europe, most of them were imported from endemic countries. In 2019, a total of 3112 cases were reported in 23 European countries, almost all among men who have sex with men (MSM) and most of the cases (87%) reported in France, Spain, the Netherlands and the United Kingdom. In many parts of Europe, surveillance for LGV is not well developed due to limited diagnostic capacity. Most of these patients are HIV-infected.

Aetiology & Pathogenesis

Chlamydia trachomatis is an intracellular Gram-negative bacterium which can cause ocular infections, trachoma, genital infections and the sexually transmitted lymphogranuloma venereum (LGV).

C. trachomatis isolates are classified serologically with 15 serovariants, based on the major outer membrane protein. LGV is caused by the invasive L1-3 strains (serovars) of *C. trachomatis* that disseminate via underlying connective tissue and spread to regional lymph nodes. In Europe, the majority of LGV cases are caused by the *C. trachomatis* biovar L2b, thought to be imported from the United States by the end of the previous century. Most cases have been detected among MSM. *C. trachomatis* serovars D–K cause cervicitis in women and urogenital infections in men.

Signs & Symptoms

The clinical picture of LGV depends on the site of transmission. Transmission to the genital area can cause inguinal disease while to the rectal canal an anorectal syndrome. LGV is divided to three stages.

- The first stage of LGV develops after an incubation period of one to four weeks. In the current LGV epidemic among MSM, proctitis is the primary manifestation of infection. Patients complain severe anorectal pain, purulent discharge and bleeding from the rectum, tenesmus and constipation. In proctoscopy oedema, a distal haemorrhagic proctitis with purulent exudate, ulceration and tumorous masses can be detected. LGV proctitis mimics chronic inflammatory bowel diseases like Crohn's disease. Radiological imaging may demonstrate pelvic node involvement. LGV proctitis can be asymptomatic, too. In traditional LGV the primary lesion is often an unnoticed small painless papule or pustule that erodes to an ulcer and heals within one week. Mucopurulent discharge can occur in the urethra, the cervix or the rectum depending on the inoculation site.
- The second or inguinal stage begins 2 to 6 weeks after the onset of primary lesion. There is painful inflammation of the inguinal and/or femoral lymph nodes causing unilateral enlargement, inflammation, and abscesses (buboes) that may rupture. Inguinofemoral lymphadenopathy is mainly seen when the inoculation site is located on the external genitals, often in males. Women often have primary involvement of the rectum, vagina or cervix. These regions drain to the deep iliac or perirectal nodes, causing intra-abdominal or retroperitoneal lymphadenopathy with lower abdominal or back pain. Constitutional symptoms like low-grade fever, chills, malaise, myalgia and arthralgias may occur.
- The third stage of LGV is called anogenitoretal syndrome and is more often present in women and MSM. Patients develop proctocolitis followed by perirectal abscesses, fistulas, strictures and stenosis of the rectum.

Localisation

See symptoms.

Classification

Lymphogranuloma venereum is usually classified by recognized stages of the infections. See symptoms.

Dermatopathology

Usually not necessary.

Course

See symptoms.

Diagnosis

The diagnosis of Lymphogranuloma inguinale is based on clinical features and confirmed by microbiological tests.

Laboratory & other workups

Microbiological diagnosis is usually two-step. The commercially available *C. trachomatis* NAAT test is used for screening and if positive, the diagnosis is confirmed by the detection of LGV biovar-specific *C. trachomatis* DNA from the same specimen. The material for testing can be from ulcers of the primary lesions, anorectal specimens or aspirates of inguinal nodes.

As most LGV cases are detected among MSM, it is recommended to screen all men with anorectal samples positive for *C. trachomatis* also for LGV, irrespective of symptoms. Also those who are eligible for HIV pre-exposure prophylaxis (PrEP) should be considered for testing. Those who are positive are then screened for LGV proctitis. Many LGV positive men are also HIV-positive, so screening for other STIs including HIV, hepatitis B and hepatitis C should be offered.

Complications

Most complications are preventable if treatment is initiated in the early stages.

- Anogenitoretal syndrome with chronic progressive lymphangitis can lead to chronic oedema and sclerosing fibrosis, resulting in strictures and fistulas of the involved region, which can ultimately lead to elephantiasis, esthiomene (the chronic ulcerative disease of the external female genitalia) and the frozen pelvis syndrome.
- LGV proctitis can lead to rectal stricture, with subsequent sequelae of soiling, pain, constipation and the possible development of mega colon, proctocolitis followed by perirectal abscess, fistulas, strictures and stenosis of the rectum, possibly leading to haemorrhoid-like swellings of obstructed rectal lymphatic tissue.
- Systemic spread of *C. trachomatis* occasionally results in arthritis, pneumonitis or (peri) hepatitis. Rare systemic complications include cardiac involvement, aseptic meningitis and ocular inflammatory disease.

Differential diagnosis

LGV proctitis mimics chronic inflammatory bowel diseases like Crohn's disease both clinically and histopathologically. Tumor masses and bleeding can be reminiscent of malignancies.

Prevention & Therapy

First line treatment is doxycycline 100 mg twice a day orally for 21 days and second line erythromycin 500 mg four times a day orally for 21 days. Doxycycline is contraindicated in pregnancy and breastfeeding. Fluctuant buboes should be aspirated promptly through healthy adjacent skin.

Patients should be informed that LGV is an invasive bacterial infection that is sexually transmitted but curable with antibiotics. Symptoms should resolve within 1-2 weeks of commencing antibiotic therapy. Patients should abstain from any sexual contact until they have completed therapy. Patients with LGV should be followed up at the end of treatment to ensure resolution of symptoms and signs of infection, to check that adequate partner notification has been complete and to re-screen for syphilis, hepatitis B, C and HIV 3 months after the LGV diagnosis. A test of cure for LGV is not considered necessary if the recommended 21-day course of doxycycline is completed.

Special

Sexual partners within the last 6 months should be strongly recommended for testing for Chlamydia/LGV and epidemiological treatment with antibiotic therapy commenced until Chlamydia/LGV has been excluded in the partner. All LGV cases should be reported according to the national legislation of communicable diseases.

References

- [Buder S, Schöfer H, Meyer T, Bremer V, Kohl PK, Skaletz-Rorowski A, Brockmeyer N. \(2019\). Bacterial sexually transmitted infections. J Dtsch Dermatol Ges. Mar;17\(3\):287-315. doi: 10.1111/ddg.13804. PMID: 30920748.](#)
- [de Vries HJC, de Barbeyrac B, de Vrieze NHN, Viset JD, White JA, Vall-Mayans M, Unemo M. \(2019\). 2019 European guideline on the management of lymphogranuloma venereum. J Eur Acad Dermatol Venereol. Oct;33\(10\):1821-1828. doi: 10.1111/jdv.15729. Epub 2019 Jun 26. PMID: 31243838.](#)

2.5.4 Non-specific urethritis (NSU)

Grading & Level of importance: C

E. Hiltunen-Back, Helsinki; M. Janier, Paris; A. Ranki, Helsinki; A. Salava, Helsinki



ICD-11

GC02.1

Synonyms

Non-venereal urethritis; non-gonococcal-non-chlamydial urethritis (NGNCU).

Definition

The most prevalent pathogens causing urethritis are *Neisseria gonorrhoea* and *Chlamydia trachomatis*. The term non-specific urethritis (NSU) applies to non-gonococcal, non-chlamydial urethritis (NGNCU). Urethritis is the inflammation of the urethra. Patients complain of discharge, dysuria and urethral discomfort, but can be asymptomatic. Most of the cases are sexually acquired.

Epidemiology

Unspecific urethritis is probably underreported or not correctly diagnosed and thus there is no consistent epidemiologic data available.

Aetiology & Pathogenesis

In many men with acute urethritis, a known pathogen is not detected.

- The most common organism detected is *Mycoplasma genitalium*, which accounts for approximately 15-40% of cases and there is a high concordance of infection in sexual partners.
- *Ureaplasma urealyticum* or *Ureaplasma parvum* can also cause urethritis in some men. However, detection of the pathogen by nucleic acid amplification tests (NAATs) cannot distinguish between asymptomatic carriage and possible causality.
- The isolation of *Trichomonas vaginalis* is dependent on the prevalence of the organism in the community.
- *Adenoviruses* or *herpes simplex virus types 1 and 2 (HSV1-2)* may account for 2–4% of symptomatic patients.
- There is also evidence that bacterial vaginosis (BV)-associated bacteria may cause urethritis.
- *Neisseria meningitidis*, *Haemophilus* sp., *Candida* sp., and other bacteria (staphylococci,

streptococci, enterococci, E.coli) probably account for a small proportion of urethritis.

The etiology of persistent urethritis is multifactorial, with an infectious agent being identified only in less than half of the cases.

Signs & Symptoms

Patients complain of urethral discharge, dysuria, penile tip irritation, urethral discomfort or itch, but can be asymptomatic, too. Clinical signs are often modest or missing, the presence of a mucopurulent or purulent urethral discharge or penile tip erythema can be detected on examination. Herpes simplex infection can cause dysuria without signs outside the urethra.

Localisation

Usually, the lower urethral duct is involved.

Classification

Classification is usually based on the causative agent.

Dermatopathology

Not necessary.

Course

Unspecific urethritis may spontaneously resolve, but may be persistent or have recurrent relapses.

Complications

Rare complications are epididymo-orchitis and sexually acquired reactive arthritis.

Diagnosis

Diagnosis is based on clinical features, and exclusion of gonococcal and chlamydial urethritis.

Laboratory & other workups

- The diagnosis of urethritis can be confirmed by demonstrating ≥ 5 polymorphonuclear leukocytes (PMNLs) per high power microscopic field from the urethral smear. After taking the sample from the meatus with a cotton tip swab it can be Gram- or methylene blue-stained.

- A leukocyte esterase dipstick of the first-voided urine (FVU) specimen can also be used in detecting urethritis in symptomatic men with a negative urethral smear. The sensitivity and specificity of other methods for diagnosing urethritis are imperfect compared with a urethral smear.
- Patients with urethritis should be tested using NAATs for *C. trachomatis*, *N. gonorrhoeae* and *M. genitalium* (with screening for macrolide resistance).
- *Trichomonas vaginalis* testing should be considered if it is prevalent (>2% in symptomatic women) in the local population. Urological investigation is usually normal and is not recommended.
- In men with symptoms suggestive of a urinary tract infection (severe dysuria, haematuria, urinary frequency or urgency) a urine analysis should be considered. If urinary tract infection is found, young men should be investigated for urinary tract abnormalities. Symptomatic patients should be reassured and advised to re-attend the clinic for an early morning smear if his symptoms do not settle.

Differential diagnosis

Chlamydia, gonorrhoea. The chronic pelvic pain syndrome should be considered in the differential diagnosis. Urethral stricture and foreign bodies.

Prevention & Therapy

Infection should be treated according to the etiological findings.

- Azithromycin for five days (500 mg stat then 250 mg od for four days) in eradicating macrolide-susceptible *M. genitalium* infection. Macrolide antimicrobial resistance in *M. genitalium* is <40% in the majority of countries.

If macrolide-resistant *M. genitalium* is detected, moxifloxacin 400 mg orally once daily for 7-14 days is recommended.

Sex partners should be tested and offered treatment. The patient shall be advised not to be sexually active until all parties have completed the treatment. A test of cure >3 weeks after treatment should be performed.

- Empirical treatment of symptomatic urethritis patients with a negative urethral smear is not recommended according to the European guidelines. For those with positive smear, a recommended regimen is doxycycline 100 mg twice daily (bd) or 200 mg once daily (od) orally for seven days, which is effective (70-80%) in men who are *U. urealyticum*-positive. Second line regimens include azithromycin 500 mg single dose (stat), then 250 mg od for four days or lymecycline 300 mg bd for 10 days or tetracycline hydrochloride 500 mg bd for 10 days. All sexual partners of the last 4 weeks the patient had before the symptoms started should be assessed and offered epidemiological treatment. Current partners should be tested and treated and the patient advised not to be sexually active until all parties have completed treatment.

- Persistent urethritis can result from both treatment failure and re-infection. Recurrent urethritis is defined as the recurrence of symptomatic urethritis occurring 30-90 days following treatment of acute urethritis and occurs in 10-20% of patients. Any treatment of persistent/ recurrent urethritis should cover *M. genitalium*, *T. vaginalis* and probably BV-associated bacteria (metronidazole 400 mg twice daily for five days). Re-treatment of the sexual partner will be beneficial.

Special

Not applicable.

References

- [Sell J, Nasir M, Courchesne C. \(2021\). Urethritis: Rapid Evidence Review. Am Fam Physician. May 1;103\(9\):553-558. PMID: 33929174.](#)
- [Jensen JS, Cusini M, Gomberg M, Moi H, Wilson J, Unemo M. \(2022\). 2021 European guideline on the management of Mycoplasma genitalium infections. J Eur Acad Dermatol Venereol. May;36\(5\):641-650](#)

2.5.5 Trichomoniasis

Grading & Level of importance: B

E. Hiltunen-Back, Helsinki; M. Janier, Paris; A. Ranki, Helsinki; A. Salava, Helsinki



ICD-11

1A92

Synonyms

“Trich”.

Definition

Trichomoniasis is a sexually transmitted infection (STI) caused by the protozoan parasite *Trichomonas vaginalis* and may cause urogenital symptoms. Asymptomatic carriers or infections with mild and unspecific symptoms are frequent.

Epidemiology

Epidemiologic data is limited because the infection is in most countries not a reportable STI and may be underdiagnosed. Around 3% of women of reproductive age in the United States are infected, with an estimated rate of asymptomatic cases as high as 50%. The WHO estimates that there are 180 million new infections acquired worldwide annually.

Aetiology & Pathogenesis

The causative agent *T. vaginalis* is a flagellated protozoan parasite transmitted during sexual intercourse. Transmission usually occurs via direct, skin or mucosal contact with an infected individual, most often through vaginal intercourse. Females can acquire the disease from infected males or females, but males usually acquire it only from infected females.

Signs & Symptoms

The incubation time is usually 1-2 weeks, but up to half of infected females have no symptoms and can be asymptomatic carriers for years. Most symptomatic females have vaginal discharge with an offensive odour. The classic symptom is a yellow-green, frothy discharge, which is present in less than 10% of symptomatic females. Other symptoms include pruritus vulvae and vaginal burning sensation. There can also be dysuria and pain or bleeding during sexual intercourse. The cervix may have a punctate or strawberry-like appearance.

T. vaginalis is present in 30-70% of the male partners of infected females, but most infected males have no symptoms. If there are symptoms, they are usually a result of urethritis (urethral discharge, meatal irritation, and dysuria). Symptoms in males may disappear within a few weeks without treatment.

However, infected and asymptomatic males can continue to infect female sexual partners. Up to 10% of the cases of non-gonococcal urethritis in males are caused by *T. vaginalis*.

Localisation

See symptoms.

Classification

No classification applicable.

Dermatopathology

Not necessary.

Course

The infection may cause acute symptoms, but the majority of patients have no symptoms and can be asymptomatic carriers for years.

Complications

None.

Diagnosis

Usually, the diagnosis is based on typical clinical features and microbiological confirmation.

Laboratory & other workups

In women, a vaginal or cervical smear can be investigated by direct microscopy. In men a urethral swab and in women a high vaginal or cervical swab can be sent to the laboratory for culture of the organism. Nucleic acid amplification test and tests detecting *Trichomonas* antigens in urethral or cervical smears are also available. It is harder to detect *T. vaginalis* in men and false negative results are common. Therefore, it is usually recommended that male sexual partners of infected females receive empiric treatment (without microbiological confirmation). Trichomoniasis increases the risk of HIV-transmission, so HIV testing and screening for other STIs should be undertaken as well.

Differential Diagnosis

Vulvovaginitis due to other causes (candida, bacterial vaginosis, aerobic vaginitis) can cause similar symptoms. Other relevant differential diagnoses include chlamydial urethritis, gonorrhoea, mycoplasma urethritis and genital herpes simplex.

Prevention & Therapy

Barrier contraception (condoms) do not fully protect from *Trichomonas*, since this parasite can infect areas that are not covered by a condom.

First-line treatment consists of metronidazole p.o. 400–500 mg × 2–3 for 5-7 days or as a single dose of 2 g and is usually effective. The alternative is tinidazole as a 2 g single dose p.o. It is important also to treat the sexual partner of the patient. Sexual activity should not take place until the symptoms have cleared.

Special

Not applicable.

References

- [Van Gerwen OT, Opsteen SA, Graves KJ, Muzny CA. \(2023\). Trichomoniasis. Infect Dis Clin North Am. Jun;37\(2\):245-265. doi: 10.1016/j.idc.2023.02.001. Epub 2023 Mar 31. PMID: 37005163](#)
- [Sherrard J, Wilson J, Donders G, Mendling W, Jensen JS. \(2018\). 2018 European \(IUSTI/WHO\) International Union against sexually transmitted infections \(IUSTI\) World Health Organisation \(WHO\) guideline on the management of vaginal discharge. Int J STD AIDS. Nov;29\(13\):1258-1272. doi: 10.1177/0956462418785451. Epub 2018 Jul 27. PMID: 30049258.](#)

2.5.6 Bacterial vaginosis

Grading & Level of importance: A



E. Hiltunen-Back, Helsinki; M. Janier, Paris; A. Ranki, Helsinki; A. Salava, Helsinki

ICD-11

MF3A

Synonyms

Nonspecific vaginitis, Gardnerella vaginitis, Bacterial vaginitis.

Definition

Bacterial vaginosis is a common cause of vulvovaginal symptoms in women of the reproductive age with the main symptom of malodorous vaginal discharge. It is not contagious and not a sexually transmitted infection, but can start after frequent sexual intercourse or intercourse with a new partner.

Epidemiology

There is no consistent epidemiologic data available, but bacterial vaginosis is regarded as a very common cause of vaginal symptoms in women of the reproductive age. The lifelong prevalence of women in Europe is estimated to be as high as 15-20%.

Aetiology & Pathogenesis

The pathogenesis of bacterial vaginosis is not completely understood, but disturbances of normal vaginal microbes (*Lactobacillus* spp. are normally the most abundant) are suspected. There is a detectable

overgrowth of anaerobic bacteria (e.g. Gardnerella and Bacteroides species) with an elevation of the vaginal pH. Predisposing factors for bacterial vaginosis are a recent use of broad-spectrum antibiotics, use of an intrauterine device and a high number of sexual partners.

Signs & Symptoms

Main symptom is a malodorous, milky or grey-white homogeneous vaginal discharge. The discharge can cause irritation of the vulvar skin. The odour of the discharge has a fishy smell and is a common complaint.

Localisation

Usually localized to vulvar skin and vaginal mucosa.

Classification

Not applicable.

Dermatopathology

Not necessary.

Course

Symptoms usually wax and wane and may last some days to weeks.

Complications

During pregnancy, there have been reports associating bacterial vaginosis with premature labour and perinatal infections (chorioamnionitis).

Diagnosis

The diagnosis is based on typical clinical features and complementary tests suggestive of bacterial vaginosis.

Laboratory & other workups

Typical microscopy of a vaginal smear shows epithelial cells with many adherent cocci (clue-cells) with almost no leucocytes. The vaginal pH strip test shows an elevated pH (> 4.5), unlike in vulvovaginal

candidiasis. If some drops of potassium hydroxide solution are applied on the speculum, a fishy smell can be provoked (KOH-test). The exclusion of other vaginitis causes may be necessary (e.g. fungal and bacterial culture, trichomonas). Tests to exclude concomitant STI-infections may be offered.

Some patients with positive test results (e.g. microscopy of the vaginal smear) do not have symptoms. Findings of bacterial vaginosis can be normal in asymptomatic postmenopausal women.

Differential Diagnosis

Vaginal discharge caused by other causes of vulvovaginitis (candida, aerobic and trichomonas vaginitis). If there is a discharge from the cervix, genital chlamydia and gonorrhoea should be excluded. In recurrent cases and elder women, a colposcopy should be performed to exclude malignancies.

Prevention & Therapy

Bacterial vaginosis is usually not preventable. Recurrences after treatment are common due to the biofilm produced by *G. vaginalis*. Oral combined contraceptives can reduce recurrence.

The symptoms have a tendency to spontaneously subside and treatments are not always necessary. During pregnancy, bacterial vaginosis should be treated because of the possible association with perinatal complications.

Effective treatments are a single dose of p.o. metronidazole 2 g or a course of p.o. metronidazole 400-500 mg t.i.d. for 5-7 days. Local therapy with intravaginal clindamycin is an alternative, especially in pregnancy. Vaginal tablets that reduce the pH to encourage restoration of normal vaginal lactobacilli may also be tried.

Special

Not applicable.

References

- [Abou Chacra L, Fenollar F, Diop K. \(2022\). Bacterial Vaginosis: What Do We Currently Know? Front Cell Infect Microbiol. Jan 18;11:672429. doi: 10.3389/fcimb.2021.672429. PMID: 35118003](#)

- [Sherrard J, Wilson J, Donders G, Mendling W, Jensen JS. \(2018\). 2018 European \(IUSTI/WHO\) International Union against sexually transmitted infections \(IUSTI\) World Health Organisation \(WHO\) guideline on the management of vaginal discharge. Int J STD AIDS. Nov;29\(13\):1258-1272. doi: 10.1177/0956462418785451. Epub 2018 Jul 27. PMID: 30049258.](#)

2.5.7 Syphilis

Grading & Level of importance: B

E. Hiltunen-Back, Helsinki; M. Janier, Paris; A. Ranki, Helsinki; A. Salava, Helsinki



ICD-11

1A6Z

Synonyms

Lues.

Definition

Mainly sexually transmitted systemic infection by *Treponema pallidum*.

Epidemiology

World Health Organization (WHO) estimates that in 2020, a total of 7,1 million new cases occurred among adolescents and adults aged 15-49 years worldwide. In Europe, almost 30,000 syphilis cases (6.1/100,000) and ca. 40 congenital syphilis cases were reported in 28 EU/EEA Member States in 2016. The reported syphilis rates were eight times higher in men than in women and peaked among 25-34 year old men. Two-thirds of the syphilis cases with information on transmission were among men who have sex with men (MSM).

Aetiology & Pathogenesis

Syphilis is a systemic infection caused by *Treponema pallidum* spirochete, and has four stages; primary, secondary, latent and tertiary syphilis. Syphilis is mostly considered as a sexually transmitted infection (STI), but a fetus of an untreated mother can get congenital syphilis. The incubation period from infection to the primary stage is 10-90 days. Secondary syphilis develops in 30% of untreated patients 2-3 months after the onset of chancre. Tertiary syphilis is rare and develops in 10% of untreated patients. The European Centre for Disease Prevention and Control (ECDC) defines early or infectious syphilis as an infection acquired ≤ 1 year earlier and it includes primary, secondary and early latent syphilis stages. Late

syphilis, which is divided to late latent and tertiary stages, has been acquired more than a year earlier. Patients are considered infectious during the first year (primary and secondary syphilis). Later transmission vertically and through tissue donation is known.

Signs & Symptoms: periods are clinically defined

- The typical symptom of primary syphilis is a single, painless, indurated ulcer (chancre) at the inoculation site, mainly in the anogenital area but can also be detected extragenitally, such as in the oral area. Regional lymphadenopathy is usually observed. The incubation period from infection to the primary stage varies between 10 and 90 days. This stage may be asymptomatic when chancres are not detected (chancres located in the vagina, pharynx or rectal canal).
- The typical feature of secondary syphilis is a non-itching skin rash (roseola) on the trunk and later papular syphilids on the palms and soles. Also, mucocutaneous lesions can be detected. Constitutional symptoms like fever, chills, malaise, generalized lymphadenopathy myalgias and arthritis occur as a consequence of the bacteremia. During the secondary stage of syphilis, symptoms of early neurosyphilis, like uveitis, retinitis, otitis, meningitis, and cranial nerve dysfunction may occur.
- Latent syphilis is clinically asymptomatic.
- The symptoms of tertiary syphilis present as erosive cutaneous or mucosal lesions (gumma), neurological (late neurosyphilis) and cardiovascular (aortic aneurysm) disorders may occur.

Localisation

- Stage I: anogenital, oral or elsewhere, draining lymph node enlarged.
- Stage II: all over the body, localised and generalised, general lymphadenopathy.
- Stage III: all over the body, localised and generalised, central and peripheral nerve system, cardiovascular.

Classification

Syphilis stages are clinically defined, and they may overlap each other.

- Primary stage: ulcer (ulcus durum) at the inoculation site; regional lymphadenopathy
- Secondary stage: eruptive skin rash (roseola syphilitica); papular syphilids on palms and soles; mucocutaneous lesions; fever with generalized lymphadenopathy. The manifestations of primary and secondary syphilis overlap in ca. 15% of cases.
- Tertiary: plaque-like lesions (gumma), neurological (late neurosyphilis) and cardiovascular (aortic aneurysm) disorders.

Dermatopathology

Usually not necessary. In cutaneous secondary and tertiary stages, a biopsy may become essential to exclude differential diagnoses such as viral or drug-induced exanthemas, hand eczema, psoriasis, cutaneous pseudolymphoma or cutaneous lymphoma.

Course

Untreated cases run a course according to classification and symptoms (see above).

Complications

Comorbidity with HIV and other sexually transmitted infections is frequent. The clinical picture and disease course can be severe (disseminated ulcerative skin lesions, severe constitutional symptoms, neurosyphilis, aortic aneurysm) in immunocompromised patients (lues maligna). HIV infection may increase the propensity of syphilis to progress into neurosyphilis and ocular syphilis.

Laboratory & other workups

The diagnosis of syphilis is commonly done with serological tests for syphilis (STS). The direct verification of the spirochete can be performed with dark-field microscopy in the early chancre but detection of *Treponema pallidum* by PCR is more specific and sensitive.

Serological tests for syphilis (STS) are obligatory, additionally they are used for screening and follow-up. Both treponemal tests (TT) and non-treponemal tests (NTT) are available.

- NTTs like the Venereal Diseases Research Laboratory test (VDRL) and the Rapid Plasma Reagin test (RPR) become positive 10-15 days after the onset of the primary chancre (i.e. around 6 weeks after infection). It is noteworthy that the STS may remain positive after an adequately treated syphilis infection. A person with a positive STS should be asked about earlier treatments of syphilis and treated as for syphilis if not known.

Titers of NTT correlate with the disease activity, and are used to monitor disease activity and efficacy of treatment.

- The specific TTs include *T. pallidum* Haemagglutination test (TPHA), *T. pallidum* Passive Particle Agglutination test (TPPA), Treponemal Enzyme Immunoassay (EIA) or ELISA, Chemiluminescence Immunoassay (CLIA) and IgG immunoblot tests with *T. pallidum* antigens.

These tests become positive in the first weeks of the chancre and remain positive after the treatment in most patients. If a TT test is positive, a quantitative NTT must be performed on the same serum. To identify reinfection after a previously treated infection, a confirmatory TPHA test (positive 4-8 weeks after infection) is used together with the VDRL test.

Dark-field microscopy of fresh samples obtained from the primary ulcer or erosive cutaneous lesions can identify *T. pallidum* with a sensitivity of 80%. (Dark-field microscopy cannot be used for oral ulcers, since the mouth harbors normal non-pathogenic treponemes indistinguishable from *T. pallidum* in microscopy.) This test has been replaced in most settings by amplification tests (PCR *T. pallidum*).

Notably, none of the STS differentiate venereal syphilis from the non-venereal treponematoses such as yaws, pinta and endemic syphilis (bejel).

Differential diagnosis

Primary chancres may be atypical, multiple, painful, deep and indistinguishable from genital and oral herpes although the syphilitic chancre is never vesiculous. In the female the chancre may be misdiagnosed as Bartholinitis. Roseola can mimic other dermatological exanthemas (drug reactions, viral infections) and eruptive papulosquamous dermatoses (e.g. guttate psoriasis, pityriasis rosea, pityriasis lichenoides) and primary HIV infection. Pseudolymphomas and malignant lymphomas have to be ruled out in nodular and infiltrated plaque lesions (gumma).

Prevention & Therapy

The first line therapy for the early syphilis is single dose of benzathine penicillin G (BPG) 2.4 million units intramuscularly (i.m.). The treatment of late latent syphilis is benzathine penicillin G (BPG) 2.4 million units IM weekly on day 1, 8 and 15. In case the patient is allergic to penicillin or refuses the parenteral treatment, oral doxycycline 200 mg daily (2x100) can be used for 14 days (early syphilis) and for 21-28 days (late latent). Benzyl penicillin 18-24 million units intravenously daily (3-4 million units every 4 h) during 10-14 days is the first choice of treatment for neurosyphilis, ocular and auricular syphilis. The Herxheimer reaction often occurs after the first dose of antibiotics.

NTTs are used for monitoring the effectiveness of treatment at 1, 3 and every 6 months thereafter, until it becomes negative or attains a low plateau (1:1-1:4).

All syphilis cases should be reported and contact tracing performed according to the local communicable disease legislation.

Importantly, all patients with syphilis should also be tested for HIV, HCV and HBV if risk factors are evident.

References

- [Hook EW Jr syphilis \(2017\) Lancet 2017; 389:1550-1557](#)

- [Janier M, Unemo M, Dupin N, Tiplica GS, Potočnik M, Patel R. \(2021\). 2020 European guideline on the management of syphilis. J Eur Acad Dermatol Venereol. Mar;35\(3\):574-588. doi: 10.1111/jdv.16946. Epub 2020 Oct 22. PMID: 33094521.](#)
- [Peeling RW, Mabey D, Kamb ML, Chen XS, Radolf JD, Benzaken AS. \(2017\). Syphilis. Nat. Rev. Dis. Primers 12;3:17073. doi: 10.1038/nrdp.2017.73. PMID: 29022569; PMCID: PMC5809176.](#)
- [Tiecco G, Degli Antoni M, Storti S, Marchese V, Focà E, Torti C, Castelli F, Quiros-Roldan E. A \(2021\). Update on Syphilis: Taking Stock from Pathogenesis to Vaccines. Pathogens. 21;10\(11\):1364. doi: 10.3390/pathogens10111364. PMID: 34832520](#)

2.5.8 Chancroid

Grading & Level of importance: C

E. Hiltunen-Back, Helsinki; M. Janier, Paris; A. Ranki, Helsinki; A. Salava, Helsinki



ICD-11

1A90

Synonyms

Soft chancre; Ulcus molle.

Definition

Chancroid is a sexually transmitted infection caused by *Haemophilus ducreyi* with characteristic painful ulcers in the genital area and often unilateral swollen inguinal lymph nodes. It is very rare in Europe with mostly travel related sporadic cases.

Epidemiology

Epidemiologic data is limited because in most countries the infection is not a reportable STI. The infection is very rare in Europe and most commonly found in tropical and subtropical regions of Africa, the Caribbean and southwest Asia. In Europe, it is mainly seen in travellers and patients originating from the endemic areas.

Aetiology & Pathogenesis

The causative agent *Haemophilus ducreyi* is a rod-shaped gram-negative bacterium, which is transmitted during sexual intercourse by direct inoculation from affected skin and mucosal sites.

Signs & Symptoms

The symptoms appear during the first week after transmission. Typically, there are one or more painful ulcers in the genital area. The site of most infections in men is the foreskin and other parts of the penis. In women ulcers may be located on the labia, perineum or in the vagina.

Women may demonstrate less specific symptoms such as dysuria, vaginal discharge or rectal bleeding. Some women may have less or no symptoms at all.

Localisation

In males the foreskin and other parts of the penis are usually affected, whereas in females the labia, perineum or the vagina.

Classification

No classification applicable.

Dermatopathology

Usually not necessary. Gram stain of the ulcer exudates may reveal short, plump, gram-negative rods in the classic school of fish appearance. If an ulcer is biopsied, histopathology may reveal three distinct histologic layers: superficial layer with neutrophils, central layer with endothelial cell proliferation and thrombosed blood vessels and deep layer with a dense infiltrate of plasma and lymphoid cells.

Course

Ulcers usually last for some weeks and if not treated many patients develop chronic inguinal lymphadenopathy.

Complications

If the infection is not treated, many patients develop painful inflammation of the inguinal lymph nodes (i.e. buboes), typically on one side.

Laboratory & other workups

Bacterial culture of *Haemophilus ducreyi* requires special culture media which are not widely available. Other tests such as nucleic acid amplification tests (NAATs) are available only in specialized laboratories.

Diagnosis

Usually, the diagnosis is based on typical clinical features (related to foreign travel to endemic areas) and ruling out syphilis and genital herpes simplex. A positive culture of *Haemophilus ducreyi* will confirm the diagnosis but requires special culture media or NAATs not widely available. Chancroid increases the risk of HIV-transmission, so HIV testing and screening for other STI should be undertaken as well.

Differential Diagnosis

Relevant differential diagnoses include genital herpes simplex and syphilis (primary chancre) and in travel related cases to endemic regions granuloma inguinale. If inguinal lymphadenopathy is present, the differential diagnosis also includes lymphogranuloma venereum.

Prevention & Therapy

Transmission of the infection can be prevented by barrier contraception.

A single dose of p.o. azithromycin 1 g or i.m. Ceftriaxone 250 mg is usually effective. Alternatives are p.o. ciprofloxacin 500 mg b.i.d. (3 days) or p.o. erythromycin 500 mg t.i.d. (7 days). Rarely, surgical treatments are required to drain infected lymph nodes.

Sexual activity should not take place until all lesions have healed. Sexual partners should be requested for clinical examination and treatment.

Special

None.

References

- [Lautenschlager S, Kemp M, Christensen JJ, Mayans MV, Moi H. \(2017\). 2017 European guideline for the management of chancroid. Int J STD AIDS. Mar;28\(4\):324-329. doi: 10.1258/ijsa.2010.010432. PMID: 21571970.](#)
- [Lewis DA. \(2003\). Chancroid: clinical manifestations, diagnosis, and management. Sex Transm Infect. 2003 Feb;79\(1\):68-71. doi: 10.1136/sti.79.1.68. PMID: 12576620; PMCID: PMC1744597.](#)

2.5.9 Granuloma inguinale

Grading & Level of importance: C



E. Hiltunen-Back, Helsinki; M. Janier, Paris; A. Ranki, Helsinki; A. Salava, Helsinki

ICD-11

1A91

Synonyms

Granuloma pudenda tropicum; Donovanosis.

Definition

Granuloma inguinale is a sexually transmitted infection with characteristic ulcerated nodules in the genital and perianal area. It is very rare in Europe with mostly travel-related sporadic cases.

Epidemiology

No consistent epidemiologic data exists, but granuloma inguinale is regarded as very rare in Europe. Most cases are travel-related. It is still present in the tropical and subtropical regions of southern India, the islands of western India, the Caribbean and tropical Latin America (e.g. Guyana), Oceania (e.g. Papua New Guinea), central Australia, South Africa and Southeast Asia.

Aetiology & Pathogenesis

The causative bacterium *Klebsiella granulomatis* (formerly called *Calymmatobacterium donovanense*) is a gram-negative rod-shaped bacterium. Transmission usually occurs via direct, skin or mucosal contact with an infected individual.

Signs & Symptoms

The symptoms appear weeks after transmission and there is great individual variation of the incubation time, which may be from 1 week up to 3 months (most frequently 4-6 weeks). Characteristic lesions are ulcerated nodules or plaques appearing on genital and perianal skin and mucous membranes. Some patients develop hypertrophic nodules (verrucous, resembling warts) or necrotic ulcers. Lesions are typically painless and symptoms are mild, unlike chancroid. Local lymph nodes (mostly inguinal) may be enlarged and drain abscesses into the overlying skin but are typically frequently missing. In rare cases, there are extragenital lesions (e.g. oral).

Localisation

The infection is located on the genital and perianal skin and mucous membranes, in some cases the inguinal lymph nodes.

Classification

Not applicable.

Dermatopathology

Usually not necessary. If an ulcer is biopsied, histopathology may show that the macrophages are large and vacuolated, and they contain intracellular bacilli, i.e. Donovan bodies (hence the name Donovanosis). These are best visualized using special stains. Additionally, there is a dermal infiltrate of histiocytes and plasma cells and small neutrophilic abscesses. *Klebsiella granulomatis* does not stain well in standard microscopy.

Course

Primary infection usually lasts 2-3 weeks, but recurrences are shorter, usually 7-10 days. A prolonged course is sometimes required in immunocompromised patients.

Complications

Granuloma inguinale, if not adequately treated, may lead to permanent scarring of the genitals and secondary genital lymphedema.

Diagnosis

The diagnosis is based on typical clinical features and the detection of microscopically visible Donovan bodies in a tissue sample taken by crush preparation or biopsy of skin, mucosa or lymphnodes. Screening tests for other STI should be carried out.

Laboratory & other workups

Tests such as bacterial culture, nucleic acid amplification tests or serology are usually available only in specialized laboratories.

Differential Diagnosis

Relevant differential diagnoses include genital herpes simplex and syphilis (primary chancre) and in

travel-related cases also chancroid. If inguinal lymphadenopathy is present, also lymphogranuloma venereum should be considered. In chronic genital ulcers one must also rule out penile or vulvar cancer (squamous cell carcinoma).

Prevention & Therapy

The transmission can be prevented by barrier contraception.

Antibiotic treatment is recommended for at least 3-4 weeks or longer until visible lesions have completely healed. Oral azithromycin 1 g (once a week) is considered the first line treatment. Alternatives are p.o. Doxycycline 100 b.i.d. and p.o. Erythromycin 500 mg q.i.d.

Sexual activity should not take place until all lesions have healed. Sexual partners should be requested for clinical examination and treatment. A follow-up examination may be necessary to ensure complete recovery.

Special

None.

References

- [Ceovic R, Gulin SJ. \(2015\). Lymphogranuloma venereum: diagnostic and treatment challenges. Infect Drug Resist. Mar 27;8:39-47. doi: 10.2147/IDR.S57540. PMID: 25870512; PMCID: PMC4381887.](#)
- [de Vries HJC, de Barbeyrac B, de Vrieze NHN, Viset JD, White JA, Vall-Mayans M, Unemo M. \(2019\). European guideline on the management of lymphogranuloma venereum. JEADV. Oct;33\(10\):1821–1828. doi: 10.1111/jdv.15729. Epub 2019 Jun 26. PMID: 31243838.](#)

2.5.10 Genital herpes simplex

Grading & Level of importance: A



E. Hiltunen-Back, Helsinki; M. Janier, Paris; A. Ranki, Helsinki; A. Salava, Helsinki

ICD-11

1A94

Synonyms

None.

Definition

Genital herpes simplex is the primary infection or a recurrence of the genital mucosa or adjacent skin by human herpes simplex virus (HSV) type 1 or 2.

Epidemiology

Genital herpes is considered as one of the most frequent sexually transmitted infections in Europe. In epidemiological studies, the seroprevalence has been up to 15-20%, but there is a substantial variation between countries and populations. The incidence of HSV infection as a measure of the primary infection is difficult to quantify, partly due to unrecognized or asymptomatic infections. It is estimated that the incidence of genital herpes simplex in European countries ranges from 5 to 24 per 100 persons per year.

Aetiology & Pathogenesis

The causative pathogens are human herpes viruses (HSV) type 1 and 2, which both belong to the most common human viral infections worldwide. Thus, genital herpes is one of the most common causes of genital ulcers in Europe. HSV-1 mainly associates with facial skin and mucosal infections and HSV-2 is more prevalent in genital infections. Clinical symptoms can be caused by primary infection or recurrences. After the primary infection, HSV remains latent in regional neuronal ganglia from where the virus spreads to the mucous membrane or skin epithelial cells via sensory neurons. HSV infection can recur spontaneously or as a consequence of different stimuli. The recurrent lesions typically appear at same or closely adjacent skin or mucosa sites.

Signs & Symptoms

Primary infection

Both HSV-1 and HSV-2 are possible, the first being increasingly prevalent.

In males, the most common clinical features are grouped vesicles and erosions on the penis. The erosions are painful and, if untreated, can last up to 2-3 weeks. The inguinal lymph nodes can be tender and patients can have flu-like symptoms with fever and myalgia.

In females, the lesions tend to be more erosive and ulcerative. Typical sites are the vulvar area and the mucosae of the vagina and cervix. Many patients experience dysuria and pelvic pain. Flu-like symptoms with fever may occur and the disease course may be more severe in females.

Succeeding the primary infection, immunity develops but is of short duration and does not always

protect from recurrences.

Recurrence

Recurrent genital herpes is mostly due to HSV-2.

During recurrences the symptoms are usually milder and of shorter duration than in the primary infection and have a tendency to reappear in the genital area, but not always at the identical site. HSV recurrence can occur spontaneously or be triggered individual provoking factors: minor trauma (e.g. after sexual intercourse), genital infections (e.g. Candida-vaginitis), ultraviolet radiation (sun exposure), menstrual cycle (especially before the menstrual bleeding) and emotional stress.

The primary infection usually lasts 2-3 weeks, but recurrences are shorter, 7-10 days. A prolonged course and spread to larger areas are possible in immunocompromised patients.

Localisation

In males, erosions are typically seen on the glans penis or shaft. In females, the vulvar area and the mucosae of the vagina and cervix are most often affected. In the genital area, intact blisters are rarely seen but rather painful ulcerations.

Classification

The infection can be classified based on causative agent HSV-1 or HSV-2 or based on suspected clinical course and information: as a primary infection or a recurrence.

Dermatopathology

A biopsy is usually necessary only in prolonged ulcers (exclusion of malignancy). Histologic changes of HSV-infection are distinctive: intraepidermal blister, keratinocytes show nuclear changes, multinucleation and viral inclusions. There is also a mixed inflammatory infiltrate.

Course

See symptoms.

Complications

Usually there are no complications. In rare cases genital herpes simplex can cause chronic neurogenic pain in the pelvic and genital areas. In pregnancy, genital herpes simplex can lead to infection of the foetus and should be managed by doctors of the maternity care or the obstetrician. Genital herpes increases the risk of HIV-transmission. Severe ulcerative and disseminated herpes infection possible in

immunocompromised patients.

Diagnosis

The diagnosis is based on typical clinical features and optional confirmatory microbiological tests. Additional HIV testing and screening for other STI should be undertaken.

Laboratory & other workups

HSV-1 and HSV-2 can be detected from the skin and mucosal lesions of the skin by viral culture, HSV antigen test (direct immunofluorescence) or preferably nucleic acid amplification tests. Serological tests are usually not helpful in genital herpes simplex, because they only confirm the carrier status of the patient and seroprevalence is very high in the general population.

Differential Diagnosis

Most important differential diagnoses are trauma-induced ulcers (e.g. during sexual intercourse), genital aphthae, herpes zoster (shingles), syphilis (primary chancre), ulcerative candida- infections and weeping irritant and allergic contact dermatitis. In travel-related cases, chancroid (ulcus molle) and granuloma inguinale must also be considered. Typical clinical features are easy to recognize, but challenging are patients with untypical presentations, such as intermittent genital itching, fissures and transient painful erythema.

Prevention & Therapy

Barrier contraception may prevent the transmission of the infection.

Systemic antiviral medicaments shorten the symptomatic period and may decrease pain and itching caused by the infection. The antivirals should be started early and at first symptoms upon recurrence. Patients with frequent recurrences and high disease burden may profit from repeated courses or continuous antiviral medication.

Primary infection (course duration 3-10 days): Aciclovir 400 mg t.i.d. or 200 mg q5h; Valaciclovir 500 mg b.i.d.; Famciclovir 250 mg t.i.d.

Recurrences (course duration 5 days): Aciclovir 400 mg t.i.d. or 200 mg q5h; Valaciclovir 500 mg b.i.d.; Famciclovir 125 mg b.i.d.

Immunosuppressed patients may require initial administration of Aciclovir intravenously 10 mg/kg body weight t.i.d.

Sexual activity should not take place until all lesions have healed.

Special

Not applicable.

References

- [Patel R, Kennedy OJ, Clarke E, Geretti A, Nilsen A, Lautenschlager S, Green J, Donders G, van der Meijden W, Gomberg M, Moi H, Foley E. \(2017\). 2017 European guidelines for the management of genital herpes. Int J STD AIDS. Dec;28\(14\):1366-1379. doi: 10.1177/0956462417727194. Epub 2017 Aug 24. PMID: 28836892.](#)
- [Johnston C. \(2022\). Diagnosis and Management of Genital Herpes: Key Questions and Review of the Evidence for the 2021 Centers for Disease Control and Prevention Sexually Transmitted Infections Treatment Guidelines. Clin Infect Dis. Apr 13;74\(Suppl 2\): S134-S143. doi: 10.1093/cid/ciab1056. PMID: 35416970.](#)
- [Jaishankar D, Shukla D. \(2016\). Genital Herpes: Insights into Sexually Transmitted Infectious Disease. Microb Cell. Jun 27;3\(9\):438-450. doi: 10.15698/mic2016.09.528. PMID: 28357380; PMCID: PMC5354570.](#)

2.5.11 Skin manifestations of HIV-infection

Grading & Level of importance: C

E. Hiltunen-Back, Helsinki; M. Janier, Paris; A. Ranki, Helsinki; A. Salava, Helsinki

**ICD-11**

None.

Synonyms

None.

Definition

Human immune deficiency virus (HIV) – infected patients have significantly more skin problems than the general population. Some of the skin manifestations may have an indicator character and should prompt the need for HIV-testing.

Epidemiology

The incidence of HIV-infection is still high in Europe although the trend as a whole is stable, being ca. 15.6 newly diagnosed cases per 100,000 population. In 2020, there were nearly 105,000 newly diagnosed infections, most of them (81%) in the eastern European region. The main transmission mode varies by geographical area: sex between men remains the predominant mode in the EU/EEA (39% of all new HIV diagnoses) while heterosexual transmission and injecting drug use are main transmission modes in Eastern European region. Vertical transmission from mother to child is rare (< 1% of new HIV diagnoses). Notably, a considerable number (44%) of the new diagnoses are among migrants. Most new HIV diagnoses fall in the age group 30-39 years (34%) and secondly, in the group of 50 years or older. Importantly, late HIV diagnosis remains a challenge, since 36% of the patients diagnosed with HIV in 2020 in the European region had an advanced HIV infection with a CD4 cell count below 350 cells/mm³. This percentage was highest in the East (56%) and lowest in the West (49%) of Europe and increased with age so that one in five new HIV diagnoses has been in persons over 50 years of age in past years. Thus, HIV continues to be relevant and the recognition of HIV-associated cutaneous signs is important to facilitate early diagnosis and initiation of HIV treatment, which in turn will prevent further transmission and will allow for a long and healthy life.

Aetiology & Pathogenesis

HIV infection is transmitted by sex, contaminated needles or blood products, and across the placenta from infected mothers to the infants. HIV causes a lifelong infection, slowly destroying the body's immune defenses and ending in the acquired immune deficiency syndrome (AIDS). Alongside the decrease of CD4 cells and immune response deterioration, numerous skin and mucous membrane symptoms develop, such as infections, dermatoses, malignancies and drug eruptions.

Signs & Symptoms

Primary infection of the HIV virus can cause acute flu-like symptoms with a generalized transient maculopapular exanthematous skin eruption affecting face, throat, trunk and proximal limbs. The other symptoms include fever, fatigue, sore throat with occasional aphthous stomatitis and sometimes diarrhea but typically no respiratory symptoms. The primary infection can also be asymptomatic (although unfrequently); usually the acute infection ends with clinical recovery in 2-4 weeks.

Chronic HIV-infection or clinical latency follows the primary HIV infection and lasts for years or even decades. During this time, lymphadenopathy and a multitude of skin problems (e.g. infections, dermatoses) usually develop. There is not any specific skin symptom, but the severity of the skin problems progresses proportionately to the immunosuppression. Skin manifestations have a tendency to recur and may show an atypical or more severe course. Most important is to consider a possible HIV-infection in patients with skin problems that follow uncommon or severe disease courses, or are recurrent and refractory to standard therapy. HIV-associated psoriasis and Kaposi's sarcoma usually

respond rapidly to antiretroviral therapy.

Common examples of HIV-associated skin symptoms during the chronic (latency) stage are as follows:

1. Viral infections

Herpes simplex infection may have chronic and persistent ulcerations and may be wide-spread. A special type of chronic genital herpes is the hypertrophic/hyperplastic nodular type. Ulcers increase the risk of HIV-transmission.

Herpes zoster occurs even in young individuals and may show severe haemorrhagic and ulcerative lesions.

Eruption of viral warts in adult individuals, may grow to form confluent hyperkeratotic plaques or giant warts.

Molluscum contagiosum, not commonly seen in adults, may occur in uncommon body sites (e.g. face) or may present as large tumorous lesions.

2. Bacterial infections

Recurrent folliculitis, impetigo, furunculosis and abscesses caused by *Staphylococcus aureus* or *Streptococcus pyogenes* are common. There may be a poor response to antibiotics. Bacillary angiomatosis; caused by bacteria of *Bartonella* species. Main symptoms are the appearance of numerous purplish papules and nodules on the trunk and limbs with flu-like symptoms and fever. Syphilis; concomitant HIV-infection can alter the course of syphilis. Clinical features may be atypical with haemorrhagic and necrotic skin lesions. Ulcers (primary chancre) increase the risk of HIV-transmission.

3. Fungal infections

Oral *Candida*-infections may present as atrophic or hypertrophic, chronic or recurrent infections.

Candida albicans can become resistant to standard antifungal therapy.

Tinea; may be more severe and prolonged than sporadic forms and spread to wider areas of the skin, hair and nails.

Pityriasis versicolor may be widespread and respond poorly to therapy.

4. Arthropod infestations

Scabies may be widespread and refractory to treatment. In some patients may progress to crusted scabies (Norwegian scabies).

5. Dermatoses

Seborrheic dermatitis may have an abrupt onset and may spread to uncommon body sites and be refractory to standard treatment.

Pruritic papular eruption; a chronic form of prurigo with scratched nodules on the extremities and trunk. General skin dryness (xerosis) and pruritus are common in HIV-patients.

Eosinophilic folliculitis; itchy follicular papules and pustules on the upper back, chest and shoulders. Refractory to standard acne and folliculitis treatments.

Chronic skin diseases (e.g. psoriasis, atopic dermatitis) may occur or become resistant to standard therapy during the course of HIV-infection.

6. Malignancies

B-cell lymphomas; especially in oral cavity, nodules and plaques, may have an acute and aggressive course.

Papillomavirus-associated malignancies, e.g. penile or vulvar carcinoma may be more aggressive than sporadic forms.

7. Drug eruptions

Drug eruptions, such as maculopapular rash, are common in HIV-infected patients. Frequent causative medicaments are antibiotics (e.g. sulfonamides) and ART drugs. Skin rashes occur as side effects of e.g. abacavir, nevirapine, darunavir, fosamprenavir and dolutegravir, while injection nodules may occur after enfuvirtide. Dry skin is common after indinavir. Severe systemic hypersensitivity-associated rash may occur with nevirapine (CD4 count and gender dependent) or with abacavir (HLA B*5701-dependent). Before starting abacavir, determination of the HLA B*5701 must be performed.

Late-stage (AIDS) skin conditions include the following:

1. Kaposi sarcoma, caused by HHV-8, appears first as asymptomatic violaceous or brownish patches or plaques anywhere on the skin or mucous membranes. Initially, the lesions are small and painless but they can ulcerate and become painful, can also occur in internal organs such as the gastrointestinal system or lymph nodes. Disease extension and severity is often proportional to the grade of immunosuppression. In most cases, Kaposi's sarcoma responds to the initiation of ART.
2. Oral hairy leukoplakia: whitish, stripe-like changes on the sides of the tongue. Caused by chronic mucosal reactivation of the Epstein-Barr virus (EBV).
3. Cytomegalovirus (CMV); chronic reactivation can cause persistent and chronic ulcers in skin folds, especially in the genital area, which are often refractory to therapy.

4. Disseminated mycobacterial infections of the skin (MAC or Mycobacterium tuberculosis); opportunistic non-tuberculous mycobacteria (e.g. M. avium/M. intracellulare complex, MAC) can cause disseminated skin and soft tissue infections. In AIDS the skin lesions are frequently caused by hematogenous dissemination of a pulmonary infection; erythematous nodules, which can ulcerate and lead to draining abscesses.
5. Cryptococcosis of the skin; opportunistic fungi (e.g. Cryptococcus neoformans); spread by hematogenous dissemination usually from a pulmonary focus; skin lesions consist of eruptive skin coloured, sometimes umbilicated, papules that extent to large areas of the skin. They can imitate widespread dell warts (molluscum contagiosum-like papules) or cellulitis.

Localisation

Anywhere on the skin or mucous membranes, localised or disseminated.

Classification

Acute and chronic phase of HIV infections (see above "Symptoms").

Laboratory & other workups

Diagnosis of the HIV-infection with HIV antigen/antibody test and confirmation with Western blot. The HIV AgAb test becomes positive earliest at 2 weeks and latest at 3 months after infection. A positive screening test always requires a second confirmatory test. In newborns with circulating maternal antibodies and during antiretroviral therapy, the detection of HIV RNA with nucleic acid quantitation (viral copies/ml) is used.

Pregnant women should be routinely offered HIV testing and counseling, since infection of the fetus can be prevented with ART during pregnancy.

Dermatopathology

Depends on the stage of the disease and the type of associated disease. Malignant tumors have specific histology depending on the tumor type.

Course

HIV stage classification was revised to five stages (0, 1, 2, 3, or unknown) in 2014 by the CDC. Stage 0 indicates early HIV infection and stages 1 -3 are based on the CD4+ T-lymphocyte count. WHO uses stages 1-4, also based on the CD4 cell counts.

Acute retroviral syndrome (Primary HIV infection)/ WHO stage 1.

The acute retroviral syndrome (for symptoms see above) develops 2-4 weeks after exposure in 60-90% of infected individuals. At this time the HIV viral load (viremia) is very high in the body and the infected person is highly infectious. The acute infection ends with clinical recovery in 1-3 weeks.

HIV-antibody test usually turns positive 2-4 weeks after the onset of symptoms while a combined antibody- antigen test (HIVAgAb) becomes positive already 2-4 weeks after the transmission of HIV infection; in rare cases it may take up to 3 months for the antibodies to turn positive. In new-borns (with circulating maternal antibodies), HIV-infection can be confirmed with PCR-based quantitation of HIV RNA.

Chronic HIV-infection (Clinical latency)/ WHO stages 2-3

After the primary HIV infection, a period of clinical latency follows and this stage can last for years or even decades. The patient is infectious if not on antiretroviral therapy (ART). During this time, lymphadenopathy and a multitude of skin problems (e.g. infections, dermatoses) usually develop (see Symptoms above). The severity of the skin problems often progresses corresponding to the level of immunosuppression. The total amount CD4-positive T-lymphocytes in the blood is used as a marker of the severity of the immunosuppression (normally over 0,4 E9/l).

Examples of frequent skin manifestation of a symptomatic HIV-infection in Europe are oropharyngeal Candida-infections (atrophic or hypertrophic), recurrent or ulcerative herpes simplex or herpes zoster of the skin or mucosal surfaces, widespread seborrheic dermatitis, eruptions of warts or recalcitrant psoriasis.

Even with good viral control with ART, skin rashes remain common and may be caused by HIV infection itself, other infections, ART medication or other medicines.

AIDS (WHO stage 4)

In this advanced stage, the CD4 cell count is below 0,200 x 10⁹/l, HIV viral load is high and the person is highly infectious. For skin symptoms at this stage, see Symptoms above.

Complications

Complications of an early infectious stage: none. In the latency stage depends on the type of infectious agents or dermatoses. HIV-associated dermatoses are typically recalcitrant to standard therapy unless antiretroviral therapy is initiated. Severe drug reactions due to HIV drugs may occur.

Diagnosis

Recognition of HIV primary syndrome with maculopapular eruption on face and upper body, fever,

tiredness, sore throat/apthae, diarrhoea. Latency stage with lymphadenopathy and different associated skin diseases (see above).

HIV-specific skin manifestations are usually suspected based on clinical features. HIV testing, microbiological (skin infections) and histopathological tests (dermatoses, malignancies) are necessary for confirmation. The viral load (virus copies/ml) and degree of immunosuppression (CD4-cell count) should be determined; screening tests for other STIs should be carried out.

Differential Diagnosis

In particular the primary HIV syndrome and associated exanthema is difficult to differentiate, may resemble syphilitic roseola. The differential diagnoses in the latency stage of HIV infection depends on the type of skin symptom.

Prevention & Therapy

Avoidance of skin symptoms depends on the prevention programs of HIV infection.

Early initiation of antiretroviral therapy (ART) enables people living with HIV to stay alive and reduces the risk of transmitting the virus to partners. WHO guidelines recommend ART is to be started for all people diagnosed with HIV, irrespective of their CD4 cell count. Today, about 30 different anti-retroviral drugs are available. The treatment is lifelong. Management of antiretroviral medication is usually carried out by an HIV-specialist.

Skin infections might require more effective (e.g. intravenous) and longer antibiotic, antiviral and antifungal therapies (e.g. infections due to *Candida albicans*). Similarly, dermatoses in HIV-infected patients often require a longer and more efficient therapy to achieve remission.

Special

It is important that the patients with unclear or therapy-resistant skin lesions are referred to dermatologist and specialist centers.

References

- [Osborne GE, Taylor C, Fuller LC. \(2003\). The management of HIV-related skin disease. Part I: infections. Int J STD AIDS. Feb;14\(2\):78-86; quiz 87-8. doi: 10.1258/095646203321156836. PMID: 12662385.](#)
- [Osborne GE, Taylor C, Fuller LC. \(2003\). The management of HIV-related skin disease. Part II: neoplasms and inflammatory disorders. Int J STD AIDS. Apr;14\(4\):235-40; quiz 241. doi: 10.1258/095646203321264836. PMID: 12716492.](#)

- [Landovitz RJ, Scott H, Deeks SG. \(2023\). Prevention, treatment and cure of HIV infection. Nat Rev Microbiol. Oct;21\(10\):657-670. doi: 10.1038/s41579-023-00914-1. Epub 2023 Jun 21. PMID: 37344551.](#)

Chapter 3 – Nevi, Tumours and Cysts

3.1 Naevi

3.1.1 Melanocytic Nevus

Grading & Level of importance: B

M. Bagot, Paris; G. Dobos, Paris; J. Malvehy, Barcelona; V. del Marmol, Brussels; A. De Masson, Paris; J. White, Brussels



ICD-11

2F20.Z

Synonyms

Mole, sometimes just called “nevus”.

Definition

Acquired benign neoplasms of melanocytic lineage are termed melanocytic nevi (plural of nevus). Melanocytic nevi are collections of melanocytes (nevus cells) in the epidermis (junctional nevus), dermis (dermal nevus) or both (compound nevus).

Epidemiology

A melanocytic nevus is a very frequent benign skin tumour (almost ubiquitous, even in African populations) and may be present at birth. The number of melanocytic nevi increases with age and until the age of around 50 years but there may be an involution of nevi over time as well.

Aetiology & Pathogenesis

Melanocytes are derived from the neural crest during embryogenesis. Two developmental pathways give rise to melanocyte progenitor cells. The dorsolateral pathway generates melanoblasts that travel through the mesoderm to colonize the epidermis, mucosa, and hair follicles. A second population of neural crest cells gives rise to bipotent precursors of Schwann cells and melanocytes that migrate ventromedially to reach the skin.

Acquired melanocytic nevi express a high diversity of clinical appearance and histomorphology. Age of onset mostly during first two decades of life. Common acquired nevi have the highest BRAF mutation

frequency. Increased exposure to UV light in childhood seems to be a promoting factor. Melanocytic nevi tend to disappear with aging.

Signs & Symptoms

Lesions present as mostly pigmented or less commonly skin-coloured macular, papular or nodular lesions. Atypical (by dermpathology dysplastic) nevi are often asymmetrical with a red-brown border and non-homogenous pigmentation. They fulfil the ABCD(E) rules, different melanoma types are a differential diagnosis and must be ruled out (see Melanoma and atypical nevi 9.7.).

Localisation

Melanocytic nevi may occur anywhere on the body, the scalp or plantar surfaces, interdigital folds, the umbilicus or sometimes on the oral and ano-genital mucosa.

Classification

There are several variants of melanocytic nevi which include: common acquired nevus, congenital nevus, blue nevus, Mongolian spot, congenital (hairy and non-hairy) nevus (including small, medium, large and giant), halo nevus, Spitz/Reed nevus, Wiesner nevus, combined nevus and nevi associated with syndromes. A halo nevus is a mole surrounded by a white ring. These halo naevi are also called Sutton nevi. They are more common in children and young adults.

Laboratory & other workups

No laboratory tests are needed.

Dermatopathology

The histological examination shows increased melanocytic cells, single or in nests in the basal layer of the epidermis or dropping down in the dermis. This helps distinguish between epidermal proliferation of melanocytes (junctional nevus), dermal proliferation (dermal nevus), or proliferation at both levels (compound nevus). Often macrophages storing melanin pigment can be found. Melanocytic nevi with histological signs of atypia are referred to as dysplastic nevi.

Course

Progression towards melanoma is exceptional (except in cases of giant congenital nevus), but patients with more than 100 nevi are at higher risk of developing a melanoma.

Complications

The number of melanocytic nevi (>50-100), along with skin type and UV-exposure history (severe sunburns in childhood) are the most important risk factors for melanoma.

Diagnosis

ABCDE rules/'ugly duck'/ 'mole out of context' concept may help distinguish benign from malignant lesions. The diagnosis is generally made on clinical features alone. Dermoscopy (where images are magnified x10) is a useful tool to increase diagnostic accuracy. Histological examination is required if the lesion is clinically unusual to rule out melanoma.

Differential Diagnosis

The differential diagnosis includes other pigmented, usually acquired skin lesions such as

- early melanoma,
- pigmented seborrheic keratosis (melanoacanthoma),
- pigmented basal cell carcinoma;
- less often histiocytoma, haemangioma, fibroma.

Prevention & Therapy

Observation (using the ABCDE rules to guide decision by the patient or clinician) is encouraged, but sometimes excision is required if there is diagnostic doubt or functional problems. Digital images in the clinical record may be helpful to facilitate accurate long-term follow-up. Visible change in the digital record within three months of follow-up is an absolute indication for excision. Abstention is preferred if there is no suspicion of atypical nevi. Excision may be performed if there is aesthetic discomfort, irritated nevi by trauma or localization or in case of a suspicious melanoma. Patients with giant congenital nevi or high numbers of dysplastic nevi must be regularly screened for melanoma.

Special

None.

References

- [Drozdowski R, Spaccarelli N, Peters MS, Grant-Kels JM. J Am Acad Dermatol. \(2022\). Dysplastic Nevus Part I: Historical Perspective, Classification, and Epidemiology. Aug 26;S0190-9622\(22\)02605-6. doi: 10.1016/j.jaad.2022.04.068. Epub 2022 Aug 28. PMID: 36038073.](#)

- [Spaccarelli N, Drozdowski R, Peters MS, Grant-Kels JM. \(2022\). Dysplastic Nevus Part II: Dysplastic Nevi: Molecular/Genetic Profiles and Management. J Am Acad Dermatol.Oct 14:S0190- 9622\(22\)02608-1. doi: 10.1016/j.jaad.2022.05.071. Epub 2022 Oct 14. PMID: 36252690.](#)
- [Frischhut N, Zelger B, Andre F, Zelger BG. \(2022\). The spectrum of melanocytic nevi and their clinical implications. J Dtsch Dermatol Ges. Apr;20\(4\):483-504. doi: 10.1111/ddg.14776. Erratum in: J Dtsch Dermatol Ges. 2022 Jul;20\(7\):1054. PMID: 35446494; PMCID: PMC9320830.](#)
- [Yeh I, Busam KJ.Histopathology. \(2022\). Spitz melanocytic tumours - a review. Jan;80\(1\):122-134. doi: 10.1111/his.14583. PMID: 34958498.](#)

3.1.2 Congenital melanocytic nevus

Grading & Level of importance: B

G. Girolomoni, Verona; P. Gisondi, Verona; J. Malvehy, Barcelona; M. Maurelli, Verona



ICD-11

2F20.2

Synonyms

Pigmented birth mark.

Definition

Collection of benign pigmented melanocytes in epidermis and dermis, present at birth, often associated with increased numbers of hair follicles.

Epidemiology

The incidence is 0.2-2.1% in newborn infants. The incidence in large/giant congenital nevi is 0.005%.
M:F= 1:1.17 - 1:1.4.

Aetiology & Pathogenesis

Embryonal acquired mutation in the tyrosine kinase NRAS in cells of the neural crest, present at birth. Rarely, lesions may appear after birth or within 2 years, are not different from congenital nevi, and are called tardive congenital nevus.

Signs & Symptoms

Circumscribed brown to black nodules or plaques, often with hypertrichosis. Small and medium-sized congenital melanocytic nevi are usually round or oval and fairly symmetric.

Localisation

Trunk, head, as well as extremities.

Classification

Projected adult size (PAS) is the estimated size of nevus at birth expected to reach in adulthood:

PAS 1-3 cm (Small CN): common and risk of melanoma similar to common nevi. Incidence = 1:100.

PAS 3-20 cm (medium CN). Incidence=uncommon, 1:1000-1:20000, rarely malignant change.

PAS >20 cm (large CN)

PAS >40 cm (giant CN)

CN >20 cm usually are on the trunk (i.e. bathing trunk naevus): Incidence = 1:500000; risk of melanoma 3-5%.

In large or giant CN loci of melanin-producing cells within the brain parenchyma, found on magnetic resonance imaging in ~20% of affected children. Other neurological associations comprise communicating hydrocephalus, arachnoid cysts, syringomyelia, tumors (including astrocytoma, choroid plexus papilloma, ependymoma, and pineal germinoma), and malformations such as Dandy–Walker or Arnold–Chiari. Congenital nevus syndrome is the term that has been introduced for the combination of cutaneous CN and neurological abnormalities.

Laboratory & other workups

Measurement of thickness by ultrasound could be useful.

Dermatopathology

Accumulation of melanocytes at the epidermal-dermal junction and in the dermis, often extending deeply, into the lower reticular dermis, subcutaneous fat and fascia, and even deeper. Helpful is the presence of nevus cells surrounding (cuffing) and within the walls of blood vessels, within adnexal structures such as hair follicles and sweat glands, and within cutaneous nerves, particularly when in the lower half of the reticular dermis.

Course

Permanent, no tendency to regression. Mean age at diagnosis of melanoma: 15.5 years.

Complications

Melanoma. In giant naevi, risk of leptomeningeal melanosis. Lumbosacral: spina bifida, myelomeningocele. Increased risk of neurological disorders in large (>20 cm) and giant nevi in >40 cm or those is

expected to reach this size in adulthood.

Diagnosis

The diagnosis is based on clinical features and histology.

Differential Diagnosis

Histiocytoma, haemangioma, fibroma, melanoma, plexiform neurofibromas. The differential diagnosis of small congenital nevi includes congenital smooth muscle hamartoma, atypical nevus, melanoma, Becker melanosis.

Prevention & Therapy

Preventive excision has not shown clinical benefits. The excision is indicated if the congenital nevus exhibits atypical features and melanoma has to be ruled out. For cosmetic reasons the surgical excision of large or congenital nevi is controversial. Excision can be recommended of lesions that are itching, traumatised or in case of verrucous tumours. In large lesions or tumour in visible areas dermabrasion shortly after birth or laser ablation has been suggested as an alternative to surgical excision.

The decision to remove a lesion is linked to the risk of melanoma and the cosmetically disfiguring appearance. However, it is very difficult to remove large or giant congenital nevi completely, and thus the risk of melanoma is reduced but not abolished.

Special

None.

References

- [Abdulmajid L, Bosisio FM, Brems H, De Vlieger G, Garmyn M, Segers H, Demaerel P, Segers K, Jansen K, Lagae L, Verheecke M. \(2021\). J Cutan Pathol. Dec;48\(12\):1497-1503. doi: 10.1111/cup.14097. Epub 2021 Aug 2. PMID: 34255877.](#)
- [Moustafa D, Blundell AR, Hawryluk EB. \(2020\). Congenital melanocytic nevi. Curr Opin Pediatr. Aug;32\(4\):491-497. doi: 10.1097/MOP.0000000000000924. PMID: 32692047.](#)

3.1.3 Atypical melanocytic naevus and syndrom

Grading & Level of importance: B

J. Malvehy, Barcelona; V. del Marmol, Brussels; J. White, Brussels



ICD-11

2F20.1

Synonyms

Dysplastic naevus; Clark naevus; Atypical mole syndrome; Dysplastic naevus syndrome; Familial atypical multiple mole melanoma syndrome.

Definition

Atypical or Clark melanocytic naevi were initially defined as pigmented lesions similar to ordinary melanocytic naevi but they usually measure more than 0.6 cm and have irregular or poorly defined borders and/or irregular pigmentation within the lesion, as well as possibly irregular texture. More recently, clinically atypical moles are defined as benign melanocytic lesions that share some of the features defined in melanoma at early stage (Asymmetry, multiple colours, etc). Histologically the term dysplastic is also used.

Atypical melanocytic naevus syndrome (AMS) is a phenotype with 7-10 relative risk for melanoma compared with general population. Patients with AMS are individuals with numerous melanocytic lesions (more than 50 pigmented melanocytic lesions, one of the lesions is confirmed to be dysplastic on histological analysis (excision is not always required) and the risk of melanoma increases if there is a family history of confirmed melanoma in one or more 1st/2nd degree relatives (Familial melanoma and atypical mole syndrome).

Epidemiology

Approximately 5-10% of Caucasian populations show atypical melanocytic naevi, with likely lower rates in populations with darker skin types. Increasing numbers of atypical melanocytic naevi increase the risk of developing malignant melanoma.

Familial melanoma and atypical melanocytic naevus syndrome is much rarer (5-10% of all melanoma patients).

Aetiology & Pathogenesis

Various genetic mutations have been described reducing the efficacy of tumour-suppressor genes. The number and characteristics of nevi is determined by multiple genes (polygenic trade) and is influenced by sun exposure. These mutations may be magnified by repeated sunburn.

Signs & Symptoms

Apart from the appearance and potential changes in the appearance, atypical naevi are asymptomatic but occasionally may be itchy or bleed.

Localisation

Sun-exposed sites are the most commonly affected, however any body site may be affected.

Classification

Histological classification is by the subjective degree of change: mild, moderate and severe.

Laboratory & other workups

Additional laboratory tests are not usually required unless a melanoma is diagnosed.

Dermatopathology

Melanocytic cells may have a different appearance to typical melanocytes (unusually spindle-shaped, or broad) and they may be of an unusual size (small or large). The cells may be arranged in an unusual pattern, such as with bridging between nests of melanocytes. An inflammatory infiltrate, fibrosis and increased vascularization may also be present.

Course

The course of atypical naevi is stable with tendency to involute during late adulthood. Most clinically atypical naevi never become malignant and prophylactic excision is not justified. However, there are lesions which represent a genomic profile intermediate between a benign naevus and a melanoma, and their malignant potential is uncertain.

Complications

Malignant transformation to a melanoma may occur but the risk of single lesions is very low (some authors consider that similar to other banal nevi). As excision is essential for the diagnosis of melanoma, scarring complications may occur after the procedure including hypertrophic or keloid scars, as well as functional impairment in multiple procedures that today are not justified.

Diagnosis

The diagnosis is clinical and dermatoscopic for an atypical melanocytic naevus. It is mandatory to obtain a specimen for histological analysis if a melanoma is clinically possible. Classically histological confirmation was necessary to be able to diagnose the atypical melanocytic naevus syndrome. Nowadays AMS is considered a phenotype of patients that have increased risk of melanoma that need special surveillance. The phenotype can be recognised non-invasively with dermatoscopy.

Differential Diagnosis

The differential diagnosis includes seborrhoeic keratoses, benign melanocytic naevi, pigmented basal cell carcinomas and melanomas.

Prevention & Therapy

Avoidance of sun burn is important, however with strict sun avoidance, vitamin D replacement therapy has been recommended. Examination with dermatoscopy and regular dermatological follow-up (including digital photography to track changes in individual lesion) is required for those with the atypical melanocytic naevus syndrome or numerous atypical naevi. Reflectance confocal microscopy can be used in equivocal lesions to increase the accuracy in the diagnosis and reduce excisions of benign atypical nevi. Screening of relatives may be offered. Histological excision of doubtful lesions to exclude melanoma is essential. Consider genetic testing in Familial melanoma and atypical mole syndrome.

Special

None.

References

- [Ribero S, Zugna D, Spector T, Bataille V. \(2021\). Natural history of naevi: a two-wave study. Br J Dermatol. Feb;184\(2\):289-295. doi: 10.1111/bjd.19171. Epub 2021 Feb 1. PMID: 32364244.](#)
- [Shain AH, Yeh I, Kovalyshyn I, Sriharan A, Talevich E, Gagnon A, Dummer R, North J, Pincus L, Ruben B, Rickaby W, D'Arrigo C, Robson A, Bastian BC. \(2015\). The Genetic Evolution of Melanoma from Precursor Lesions. N Engl J Med. Nov 12;373\(20\):1926-36. doi: 10.1056/NEJMoa1502583. PMID: 26559571.](#)
- [Barnhill RL, Elder DE, Piepkorn MW, et al. \(2023\). Revision of the Melanocytic Pathology Assessment Tool and Hierarchy for Diagnosis Classification Schema for Melanocytic Lesions: A Consensus Statement. JAMA Netw Open. Jan 3;6\(1\):e2250613. doi: 10.1001/jamanetworkopen.2022.50613. PMID: 36630138; PMCID: PMC10375511.](#)

3.1.4 Nevus Flammeus

Grading & Level of importance: B



M. Bagot, Paris; G. Dobos, Paris; A. de Masson, Paris

ICD-11

LC50.1

Synonyms

Port-wine nevus, port-wine stain.

Definition

Nevus flammeus is a sharply circumscribed red to bluish (port-wine coloured) patch present since birth. This is a benign vascular malformation consisting of increased numbers of dilated dermal vessels.

Epidemiology

Naevus flammeus is frequent. It affects 0.3-1% of the population, with women being twice as likely to be affected as men. Cases are usually sporadic, but a 10% familial incidence and an autosomal dominant inheritance have been described.

Aetiology & Pathogenesis

This is a benign skin condition, present since birth.

It is rarely associated with genetic angiodysplastic syndromes (Sturge-Weber syndrome (encephalotrigeminal angiomas) associated with GNAQ mutations, or Klippel-Trénaunay syndrome associated with PIK3CA mutations).

Signs & Symptoms

Lesions are sharply circumscribed red or violaceous macules or patches without palpable features. In rare, unilateral cases, papules or nodules may appear over time.

Localisation

Axial nevi flammei are named Unna nevus or stork bite in the neck and occiput; angel's kiss on the forehead. They are not associated with underlying angiodysplasia and are now called salmon patches. Lateral nevi flammei may be syndrome-associated. Facial lesions (unilateral port-wine stain in the trigeminal area) may be associated with underlying ocular, meningeal or central nervous system angiomas (Sturge Weber syndrome). Port-wine stain of a limb, associated with vein malformations and overgrowth of tissue and bone in the same region defines Klippel-Trénaunay syndrome.

Classification

Nevus flammeus comprise capillary malformations representing real naevi, and capillary malformations that do not represent nevi, such as the frequent median and regressive lesions now called salmon patches.

Laboratory & other workups

No laboratory tests needed. Ultrasound may be useful for deeper localisations.

Dermatopathology

Histology is not needed for the diagnoses. Increased dilated dermal vessels are found with no inflammatory infiltrate.

Course

Axial lesions tend to regress spontaneously but may not disappear completely. Lateral ones grow with

body growth, get darker with age and may develop nodular changes (e.g. soft tissue enlargement of lips) and pyogenic granulomas.

Complications

In periorbital nevi flammei ocular involvement (glaucoma, which can lead to blindness) should be excluded by an ophthalmologist, and brain magnetic resonance imaging (MRI) should be performed to exclude meningeal or central nervous system angioma (Sturge-Weber syndrome), which can be complicated with seizures, stroke, or mental retardation.

Klippel-Trénaunay syndrome may be associated with complications (bleeding, thrombosis, soft tissue deformities).

Diagnosis

Diagnosis is based on clinical features.

Differential Diagnosis

Infantile hemangioma, which is a red or bluish vascular tumor, not present at birth, appears in the first weeks of life, grows during a few months and then regresses spontaneously.

Prevention & Therapy

Nevus flammeus may spontaneously disappear in the first 6 months of life (especially the stork bite and angel's kiss types). A treatment is generally not needed and only indicated in cosmetically or functionally severe cases. Cosmetic camouflage, laser treatment, intense pulsed light, may be used.

Special

None.

References

- [Poliner A, Fernandez Faith E, Blieden L, Kelly KM, Metry D.\(2022\) Port-wine Birthmarks: Update on Diagnosis, Risk Assessment for Sturge-Weber Syndrome, and Management. Pediatr Rev.Sep1;43\(9\):507-516.](#)

- [Diociaiuti A, Paolantonio G, Zama M, Alaggio R, Carnevale C, Conforti A, Cesario C, Dentici ML, Buonuomo PS, Rollo M, El Hachem M. \(2021\) Vascular Birthmarks as a Clue for Complex and Syndromic Vascular Anomalies. Front Pediatr. Oct 7;9:730393. doi: 10.3389/fped.2021.730393.](#)

3.1.5 Naevus sebaceous

Grading & Level of importance: B



Z. Bukvić Mokos, Zagreb; B. Marinović, Zagreb

ICD-11

LC02

Synonyms

Naevus sebaceous of Jadassohn.

Definition

An epidermal hamartoma that comprises sebaceous, follicular, and apocrine elements.

Epidemiology

Affects 0.3% of newborns. The prevalence is equal in males and females.

Aetiology & Pathogenesis

Postzygotic somatic mutations of the RAS gene family, most commonly HRAS (95% of nevi). KRAS mutations may be found in 5% of patients. In patients with Schimmelpenning syndrome, mosaicism of HRAS and KRAS mutations has been reported.

Signs & Symptoms

At birth, nevus sebaceous presents as a slightly raised plaque with a smooth, yellowish surface. It is most commonly present on the scalp. The lesion is usually oval but, in some cases, multiple lesions develop in a linear distribution along the lines of Blaschko. During puberty, due to hormone changes, the lesions become thicker with a more verrucous surface. In adulthood, neoplasms (most

commonly benign) may develop within the lesion.

Extensive sebaceous nevi may be the sign of Schimmelpenning syndrome, a neurocutaneous disorder that affects central nervous system, eyes and bones.

Localisation

The most common localisation is the scalp area, but the lesions may also appear on the face and neck and rarely on the trunk.

Classification

None.

Laboratory & other workups

Not necessary.

Dermatopathology

Initial lesions are characterized by acanthosis and papillomatosis, and immature pilosebaceous units. At puberty, the epidermis becomes more hyperplastic, papillomatous, and verrucous. Numerous sebaceous glands with an increased number of sebaceous lobules are found in the superficial dermis. The hair follicles contain more vellus hairs than terminal hairs.

Course

See symptoms.

Complications

In adulthood, secondary neoplasms may develop. Formerly, it has been thought that malignant transformation develops in 10-15% of lesions. Today it is known that malignant tumours are less common. Among malignancies, basal cell carcinoma develops most frequently, but only in less than 1% of lesions. The most common tumour within the naevus sebaceous is trichoblastoma, followed by syringocystadenoma papilliferum. Other secondary tumours include sebaceous adenoma, tricholemmoma, desmoplastic tricholemmoma, apocrine adenoma, and poroma.

Diagnosis

Diagnosis is based on patient history and clinical features.

Differential Diagnosis

In early infancy, the differential diagnosis includes aplasia cutis congenita and mastocytoma. In later stages, pidermal nevus, congenital nevus, seborrheic keratosis, verruca vulgaris, and juvenile xanthogranuloma should be considered.

Prevention & Therapy

Since the risk of malignancy is low, particularly before adolescence, observation is recommended.

Surgical excision is the treatment of choice. For cosmetic reasons, facial lesions should be considered for surgical excision during childhood since scarring is less intense.

Special

None.

References

- [Patel P, Malik K & Khachemoune A \(2015\) Sebaceous and Becker's Nevus: Overview of Their Presentation, Pathogenesis, Associations, and Treatment. Am J Clin Dermatol \(2015\) 16:197–204](#)

3.2 Benign Tumours and Cysts

3.2.1 Seborrheic Keratosis

Grading & Level of importance: B
M. Bagot, Paris; G. Dobos, Paris; A. de Masson, Paris



ICD-11

2F21.0

Synonyms

Seborrheic wart, senile wart, basal cell papilloma.

Definition

The seborrheic keratosis is a benign verrucous epithelial tumour, without any viral association, typically seen in elderly patients but that may also occur in young people. It is the most frequent benign tumour of the skin.

Epidemiology

Seborrheic keratosis is the most frequent benign skin tumour, affecting more than 90% of the people over 60 years.

Aetiology & Pathogenesis

The cause of seborrheic keratosis is not known, but somatic mutations in FGFR3 (and other genes such as PIK3CA) are frequently found. Stable and clonal mutations or activation of FGFR3, PIK3CA, RAS, AKT1 and EGFR genes are frequently found in seborrheic keratoses.

Signs & Symptoms

Various clinical phenotypes exist: generally, it is a soft, wart-like (verrucous) keratotic brown or black plaque of the skin with a “pasted-on” appearance. However, it can have a lighter, yellowish colour or be flat. Some lesions may be pedunculated. The warty surface may be covered with a thick, squamous, keratotic film. The lesions can vary in size from a few millimetres to several centimetres. If exposed to physical contact, it can get irritated or inflamed and be pruritic.

Localisation

Seborrheic keratoses can be localized on all areas of the body, most often on trunk and face. A dermatome-like pattern may occur.

Classification

There is no classification. Stucco keratosis and black papular dermatitis (dermatosis papulosa nigra) are considered to be variants of seborrheic keratosis.

Laboratory & other workups

Laboratory tests are not needed for the diagnosis.

Dermatopathology

Several histological variants exist. Major criteria are acanthosis, hyperkeratosis and horn pseudo-cysts, usually accompanied by epidermal hyperpigmentation. There are different histological types of seborrheic keratosis, such as the acantholytic, hyperkeratotic, reticulated or adenoidal forms. The presence of moderate atypia or mitosis is suggestive of irritation or local inflammation. In such cases, a dermal, perivascular, diffuse or lichenoid lymphocytic infiltrate may be present.

Course

Seborrheic keratoses show a slow growth and may reach several centimetres in size. There is usually no spontaneous regression.

Complications

If seborrheic keratoses appear on areas prone to physical injury, they may become irritated, infected or may be bleeding. Itching is often related to *M. furfur* colonization. Malignant transformation is extremely rare. Leser-Trélat sign is the explosive onset of multiple, itchy seborrheic keratosis, and may indicate an underlying solid tumour, most often stomach cancer or a colon adenocarcinoma.

Diagnosis

Seborrheic keratoses can be identified by clinical features. Dermoscopy may be helpful in visualising the horn pearls in particular when naevi are a differential diagnosis. Histology is generally not necessary except for melanoacanthoma type.

Differential Diagnosis

It is important to distinguish seborrheic keratoses from other recent pigmented lesions (melanoma, pigmented basal cell carcinoma, melanocytic naevus, longstanding black angioma).

Prevention & Therapy

Treatment of seborrheic keratosis is generally not needed except in traumatized and infected ones. Recurrence after treatment is very frequent. Treatment options include curettage, cryosurgery, laser ablation, shave excision.


Special

None.

References

- [Gorai S, Ahmad S, Raza SSM, Khan HD, Raza MA, Etaaee F, Cockerell CJ, Apalla Z, Goldust M. \(2022\) Update of pathophysiology and treatment options of seborrheic keratosis. Dermatol Ther. Oct 13:e15934.](#)
- [Natarelli N, Krenitsky A, Hennessey K, Moore S, Grichnik J. \(2022\) Efficacy and Safety of Topical Treatments for Seborrheic Keratoses: A Systematic Review. J Dermatolog Treat. Oct 10:1-29.](#)
- [Diep D, Calame A, Cohen PR. \(2021\) Morphologic Mimickers of Seborrheic Keratoses: Cutaneous Lesions Masquerading as Seborrheic Keratoses. Cureus.Oct 7;13\(10\):e18559. doi: 10.7759/cureus.18559.](#)

3.2.2 Keratoacanthoma

Grading & Level of importance: B 
H. Gollnick, Magdeburg; P. Pasquali, Barcelona

ICD-11

2F2Y / 2F2Z

Synonyms

Epidermoid carcinoma.

Pseudocarcinoma.

Definition

Keratoacanthoma (KA) is by histology a well-differentiated cutaneous squamous cell carcinoma. It grows very fast, it typically presents as a dome-shaped nodule with a central keratin-filled crater. It is a low malignancy tumor with uncertain biologic behavior that might present spontaneous regression. This regression is thought to be due to immune mediated destruction of squamous cells.

Epidemiology

Quite common tumor mostly affecting those older than 60 years. Males are more affected than females(3:1). Smoking and solar damage are risk factors.

Aetiology & Pathogenesis

Keratoacanthomas are derived from follicular infundibular areas out of the epidermal hair follicle stem cell pool. About 25% are human papilloma virus type 21-related. Transforming growth factor beta receptor 1 (TGFBR1) can cause multiple self-healing squamous cell carcinomas (MMSE, type Ferguson-Smith), which is the most common cause of multiple KA's. There is evidence for germline mutations of hMSH2 and hMLH1 mismatch repair genes causing Muir-Torre syndrome in solitary and multiple KA's.

It has also been reported to occur in sites of iatrogenic or accidental trauma.

There is now strong evidence that Mitochondrial Microsatellite Instability (MtMSI) help to differentiate between KA's and SCC's. MtMSI was detected at mitochondrial D514 D-loop and presented with (CA) n repeats. In contrast, all of the SCC patient experienced mtMSI with (C)n repeats at the D-loop region D310. These differences in location are highly significant, which further supports the hypothesis that KA and SCC have different pathogenetic pathways.

KA, in contrast to SCC, shows three clinical stages:

- a. proliferative,
- b. mature, and,
- c. involutinal / regressing.

Regression is thought to be due to immune mediated destruction of squamous cells. In particular, it is of note that in the proliferative stage, strong infiltration of the epithelial strands with eosinophils can be seen, and they are known to have potent anti-cancer properties. Spontaneous tumour regression in keratoacanthomas is driven by Wnt/retinoic acid signalling cross-talk.

In patients with metastazing malignant melanoma under treatment with BRAF inhibitors, KA'S can occur as multiple eruptive variants.

Signs & Symptoms

Typically, KA appears solitary but KA may present with multiple tumors or may be of a giant type. Lesions are hyperkeratotic, irregular papules or nodules, sometimes crusted and ulcerated. As a highlight one can see a crater filled with keratotic and necrotic material. A large and centrifugal growing subtype of KA with elevated margins without the central keratotic plug or crater can be seen at the dorsum of hands and feet.

Localisation

Head and neck most common sites, followed by extremities. Rarely the oral cavity is affected.

Classification

- Solitary keratoakanthoma, classical type
- Aggregated KA type
- KA centrifugum type
- Giant KA type
- Subungual KA type
- Intraoral and mucosal transition zone KA type (lip, conjunctiva)

Laboratory & other workups

None specific.

Dermatopathology

For a reliable and clear dermatopathological diagnosis of a KA, one needs a representative ellipse biopsy (a punch biopsy is usually less helpful). By low power magnification one can see a proliferating well-differentiated squamous tumor with a central keratin-filled crater. Typically, the surrounding epidermis forms a lip around the invaginating crateriform tumor composed of rather normal cells. The proliferating tumor itself is composed of squamous cells with abundant eosinophilic or milky-glassy cytoplasm and enlarged hyperchromatic to vesicular-appearing nuclei. In the proliferative stage, one finds in the epithelial strands eosinophilic and neutrophilic microabscesses and also eosinophils in large numbers invading the tumor or free in the inflammatory infiltrate. Huge keratin horn pearls are seen within the tumor.

Regressing tumors ultimately show epidermal atrophy, bland cytologic features, dermal inflammation and fibrosis at the periphery of tumor. Scarring occurs to a variable degree.

Course

KA is typically a non-fatal tumor. It can regress; however, final size prior to regression is difficult to predict. Recurrence is uncommon with surgical removal. The scar is permanent.

Complications

Scarring. In cases of ambiguous dermatopathological findings, a fast proliferating SCC or other types of benign or malignant mostly skin appendage-related tumors may have been overlooked.

Diagnosis

Diagnosis relies on clinical features and histology. Dermoscopy is extremely helpful and the main features are: white circles (white ring-like structures within the hair follicle; a centrally located keratin mass, and white structureless areas. Vessels can be hairpin-like linear-irregular or glomerular. Skin ultrasound can help determine tumor depth and volume.

Differential Diagnosis

Squamous cell carcinoma, nodular basal cell carcinoma, verruca vulgaris, hypertrophic lichen planus, prurigo nodularis and tumors of skin adnexal structures.

Prevention & Therapy

Treatment depends on size and localization. Monitoring for spontaneous regression is common in clinical practice. In particular, in the situation of tumors in the face and at functional areas over joints and close to orifice, two weeks will often be enough to assess if the tumour will regress or not.

Typically, if not regressing, it is treated with complete surgical excision. Mohs' surgery or 24 hrs. dermatopathological finding is performed dependent on location.

Electrosurgery, cryosurgery, laser surgery, systemic or topical chemotherapy are occasionally performed. Low dose radiotherapy can be used if the lesion recurs or if there would be significant cosmetic disfigurement with other surgical options.

Special

None.

References

- [Tobias Gleich , Elena Chiticariu , Marcel Huber , Daniel Hohl \(2016\) Keratoacanthoma: a distinct entity? Exp Dermatol 25\(2\):85-91.](#)
- [Bartlomiej Kwiek, MD, PhD, and Robert A. Schwartz, MD, MPH. Keratoacanthoma \(KA\): An update and review. J Am Acad Dermatol 2016;74:1220-33.](#)
- [Ogita A, Ansai SI. \(2021\) What Is a Solitary Keratoacanthoma? A Benign Follicular Neoplasm, Frequently Associated with Squamous Cell Carcinoma. Diagnostics \(Basel\). 11\(10\):1848. doi: 10.3390/diagnostics11101848. PMID: 34679546; PMCID: PMC8535102.](#)

3.2.3 Dermatofibroma

Grading & Level of importance: B



M. Bagot, Paris; G. Dobos, Paris; A. De Masson, Paris

ICD-11

2F23.0

Synonyms

Fibrous histiocytoma; sclerosing haemangioma; subepidermal nodular fibrosis; histiocytoma, histiocytofibroma; benign fibrous histiocytoma.

Definition

The dermatofibroma is a frequent, benign fibrohistiocytic dermal tumor. It may occur after an initial skin trauma (such as vaccination or insect bite) and is generally a firm, slow-growing lentil-shaped papule of pale or brownish colour.

Epidemiology

Dermatofibroma is one of the most common skin tumor-like lesions.

Aetiology & Pathogenesis

The aetiology of dermatofibromas is not known, they sometimes occur after arthropod bite or cutaneous trauma.

Signs & Symptoms

Lesions present as solitary or multiple brownish, lentil-shaped, firm itchy papules. Pigmentation is often increased at the periphery.

Localisation

Dermatofibromas are most often found on legs and upper extremities but can occur on the whole body except palms and soles.

Classification

The histopathological types include cell rich fibrous histiocytoma (80%) and the aneurysmal, hemosiderotic, epithelioid, cellular, lipidized, atrophic and clear cell variants.

Laboratory & other workups

There is no need for laboratory testing for dermatofibromas.

Dermatopathology

Fibrous histiocytomas are benign fibrohistiocytic tumors. Most commonly, these tumors are located in the dermis and subcutis. They are made up of a mixture of fibroblastic and histiocytic cells, collagen and blood vessels. Variable hemosiderin, multinucleated giant cells, chronic inflammatory cells may be found in the lesions. Many variants have been described; more than one variant can be seen in the same lesion.

The histological features may include acanthosis or pseudoepitheliomatous hyperplasia of the overlying skin, a vague storiform pattern of bland spindle cells centred in dermis with possible extension to subcutis. The infiltration into and around fat cells is uncommon.

Some dermatofibromas present an atypical appearance on histopathological examination. These lesions are often in a phase of rapid growth or have reached a large size. They are often exophytic, globular or polypoid. Atypical features of the nucleus and cytoplasm are found and along with a number of mitoses. This is a pseudosarcoma-type presentation in which there is no risk of metastases.

Course

Dermatofibromas have a chronic course and may remain unchanged or flatten with time. If left untreated, a dermatofibroma often stabilises in size and remains unchanged for a very long period of time.

Complications

Sometimes growing and itching may lead to scratching and superinfection.

Diagnosis

Dermatofibromas are firm dermal papules that show a central depression when lateral pressure is applied to them (dimple-sign). Diagnosis is based on clinical features, and histology is rarely needed.

Differential Diagnosis

Dermatofibromas may look similar to basal cell carcinomas. Frequent differential diagnoses include melanocytic naevus, old regressing congenital nevi, melanoma, scars, haemangioma. Giant dermatofibromas must be differentiated from dermatofibrosarcoma protuberans, a rare infiltrating soft tissue sarcoma.

Prevention & Therapy

There is no need for treatment of dermatofibromas. However, some lesions may itch or may be at a site of the body skin where they are disturbing or may be continuously traumatized. A local corticosteroid injection can cause the lesion to regress. Surgical excision, cryosurgery or laser ablation can be performed.

Special

None.

References

- [Bernhard Zelger, Bettina Gudrun Zelger, Walter H C Burgdorf \(2004\) Dermatofibroma-a critical evaluation Int J Surg Pathol 12\(4\):333-44.](#)
- [Ramirez- Fort MK, Meier-Schiesser B, Niaz MJ, Niaz MO, Feily A, Fort M, Lange CS, Caba D. \(2020\) Dermatofibrosarcoma Protuberans: The Current State of Multidisciplinary Management. Skinmed. Oct1;18\(5\):288-293.](#)

3.2.4 Keloid

Grading & Level of importance: C



S. Hobelsberger, Dresden; C. C. Zouboulis, Dessau

ICD-11

EE60

Synonyms

Cheloid, cicatrix keloidalis.

Definition

Benign scar tissue which grows beyond the borders of the original injury or surgical defect.

Epidemiology

Incidence in dark-pigmented populations 4.5-16% (African, Asian, and Hispanic descent), higher compared to Caucasians. Higher incidence during puberty and pregnancy. A positive family history increases the risk for the development of keloids although no specific gene has been identified. Rare genetic syndromes can confer increased risk for the development of keloids including Rubinstein-Taybi and Goeminne syndromes.

Aetiology & Pathogenesis

Keloids are a result of aberrant wound healing of surgical wounds, injuries (piercings, tattooing, insect bites, vaccinations), burns, skin-damaging infections, acne, increased skin tension, spontaneous (no trigger found). In keloids, the fibroblastic phase of wound healing continues unchecked, resulting in the clinical and histopathological findings. Keloidal fibroblasts have increased proliferative activity, persist for longer, and have lower rates of apoptosis compared to the ones in typical wound healing. Overproduction of collagen (20x greater than that of healthy skin and 3x greater than a hypertrophic scar). Transforming growth factor- β (promotes chemotaxis of fibroblasts to the site of inflammation and produces collagen) and platelet-derived growth factor are the primary drivers of this process.

Signs & Symptoms

Bizarre sharply bordered nodular proliferation of connective tissue with erythema, pruritus and sometimes pain. Keloid extends beyond original defect.

Localisation

Predilection sites: presternal, neck, shoulders, ears, tense wounds.

Classification

No international classification exists, clinically: suppurative keloid, presternal keloid, juxta-articular keloid, folliculitis keloidalis nuchae.

Laboratory & other workups

None.

Dermatopathology

Increased whorls of thickened, hyalinized collagen bundles widely known as keloidal collagen (up to 55% of specimens). Random organization of Type I and Type III collagen fibers. Horizontal fibrous band in the upper reticular dermis.

Course

Keloids may develop as early as 1 to 3 months or as late as one year after injury. Do not improve with time or heal spontaneously.

Complications

Contractures over joints hamper motion, chronic itching/pain.

Diagnosis

History, clinical features.

Differential Diagnosis

- Hypertrophic scar (remains confined to area of surgery or damage),
- sarcoidosis,
- dermatofibroma,
- dermatofibrosarcoma.

Prevention & Therapy

Keloids remain a therapeutic dilemma. Not only are they difficult to treat but incomplete therapy can lead to a keloid worsening. Predisposed individuals should avoid elective procedures, if possible, especially ear piercing and tattooing (primary prevention). In accidental trauma or required surgical interventions, rapid primary closure, adequate haemostasis and reduction of wound tension reduce the risk for keloid development (secondary prevention). Compression therapy with pressures of 15-45 mmHg for more than 23 hours per day for at least 6 months may reduce keloid development (tertiary prevention).

Intralesional corticosteroids (2 mg/cm²) 4 to 6 sessions at 15-30-day intervals alone or in monthly sessions after contact (pressure) (30 sec), intralesional cryosurgery, surgical excision accompanied with post-surgical radiation or intralesional steroid injections (due to recurrence rates of 45-100% after

surgery alone), radiotherapy (adjuvant therapy 24 h following excision), LASER treatment (Pulse-dye, 585 nm, Nd-YAG, 1065 nm) can be considered. Other treatments (topical imiquimod following excision, intralesional botulinum toxin, intralesional bleomycin or 5-fluorouracil, silicone gel tapes) may alleviate symptoms and reduce the volume of existing keloids.

It is important to manage patient expectations.

Special

None.

References

- [Ekstein SF, Wyles SP, Moran SL, Meves A. Keloids: a review of therapeutic management. Int J Dermatol. 2021 Jun;60\(6\):661-671. doi: 10.1111/ijd.15159. Epub 2020 Sep 9. PMID: 32905614; PMCID: PMC7940466](#)

3.2.5 Lipoma

Grading & Level of importance: B



M. Bagot, Paris; G. Dobos, Paris; A. De Masson, Paris

ICD-11

2E80.0

Synonyms

Fatty tumor or steatoma.

Definition

Adipocytic tumors are benign soft tumors of the skin, arising from the subcutaneous fat tissue.

Epidemiology

Lipoma is a relatively frequent benign tumor, more frequent in male, older than 30 years. Lipomas occur in 1-2% of the population.

Aetiology & Pathogenesis

Lipoma is most frequently spontaneous, but there may be a genetic predisposition (see subtypes).

Signs & Symptoms

The clinical presentation is an indolent (slowly growing), rubbery-consistency, painless, soft, mobile, circumscribed, round, subcutaneous mass.

Localisation

Lipoma may be solitary, multiple or disseminated, and may occur on the trunk, upper extremities, shoulders, nuchal region or face.

Classification

- Single or multiple (lipomatosis) non-pain associated lipomas
- Subtypes: Launois Bensaude lipomatosis is characterized by multiple symmetric lipomatous masses in the face, neck, upper trunk and upper arms, and is frequently linked to alcoholism. Adiposis dolorosa (Dercum disease), is a condition marked by painful lipomas. Familial multiple lipomatosis, is a hereditary condition that causes multiple lipomas. [Benign symmetric lipomatosis](#) (Madelung disease), is a rare condition marked by lipomas forming around the upper body.

Laboratory & other workups

No laboratory tests are needed.

Dermatopathology

The histological examination of the lesion shows well limited fatty tissue lobules, frequently with a connective tissue capsule. Lipomas with vessel proliferation are angiolipomas; lipomas with connective tissue proliferation: fibrolipomas and mixed types: angiofibrolipomas. Malignant transformation is exceptional.

Course

The typical course is a slow growth followed by stabilization.

Complications

Pressure on adjacent tissues and vessel thrombosis within the lipoma may rarely lead to pain or aesthetic discomfort.

Diagnosis

The diagnosis is suspected with the clinical characteristic features, ultrasonography, and confirmed histologically.

Differential Diagnosis

The most important differential diagnosis is malignant liposarcoma, which must be suspected if the tumor is rapidly growing or painful. If liposarcoma is suspected, the lesion must be removed surgically for histopathological examination. Other differential diagnoses include cysts, connective tissue tumours, benign symmetrical lipomatosis, or panniculitis.

Prevention & Therapy

Excision is performed in case of discomfort, or to rule out a malignant tumor if the clinical presentation is atypical (e.g. rapid growth, pain).

Special

None.

References

- [Al Ghazal P, Grönemeyer LL, Schön MP. Lipomatoses. \(2018\) J Dtsch Dermatol Ges. Mar;16\(3\):313-327.](#)
- [Yee EJ, Stewart CL, Clay MR, McCarter MM. \(2022\) Lipoma and Its Doppelganger: The Atypical Lipomatous Tumor/Well-Differentiated Liposarcoma. Surg Clin North Am. 2022 Aug;102\(4\):637-656.](#)

3.2.6 Haemangioma

Grading & Level of importance: B



M. Bagot, Paris; G. Dobos, Paris; A. de Masson, Paris

ICD-11

XH5AW4

Synonyms

Infantile haemangioma, strawberry nevus, hemangioma of infancy (HI).

Definition

Infantile haemangiomas are benign vascular tumours that appear in the first weeks after birth.

Epidemiology

Childhood haemangioma is relatively frequent (4-5% of infants).

Aetiology & Pathogenesis

The aetiology of this benign skin condition is not known but has been discussed.

Signs & Symptoms

Haemangiomas are dome-shaped circumscribed bright red nodules (cutaneous haemangioma), or pink to blue soft swelling (subcutaneous haemangioma), or both (mixed type) or superficial.

Localisation

They can be located in any area of the body, but hemangioma more frequently occur on face, scalp, chest or back. Pattern can be focal, multifocal, segmental or indeterminate.

Classification

Haemangiomas are superficial (cutaneous), deep (subcutaneous) or mixed (superficial and deep). Other categories are reticular, abortive, and minimal growth.

Laboratory & other workups

Laboratory tests are not needed.

Dermatopathology

Histology is not needed for the diagnosis. A proliferation of dermal mature vessels without inflammatory infiltrate is observed if a biopsy is performed. However, growing HI express more GLU-1 receptor by immunohistochemistry. Such an appearance should prompt consideration of intervention.

Course

Childhood haemangioma are not present at birth, appear in the first weeks of life, grow during a few months and then spontaneous regress in the first or first years of life. Those which are rapidly and continuously growing need intervention.

Complications

Childhood haemangiomas may lead to: ulceration (infection, pain), scar with esthetic consequences, bleeding (uncommon), functional disturbances depending on location:

- Eye: amblyopia
- Nose: cartilage deformation
- Lips, mouth: feeding difficulties
- Lower jaw and neck: associated subglottic hemangioma (with possible respiratory obstruction)
- Segmentary facial hemangiomas and perineal/lumbo-sacral hemangiomas may be associated with underlying malformations.

PHACE association/syndrome includes posterior fossa malformations, hemangioma, arterial anomalies, cardiovascular anomalies, eye anomalies, sternal clefting and/or supra-umbilical raphe.

LUMBAR (SACRAL, PELVIS) association / syndrome includes lower body hemangioma, urogenital anomalies, ulceration, myelopathy, bony deformities, ano-rectal malformations, arterial anomalies, and renal anomalies.

inally, miliary hemangiomatosis is a rare condition which may be associated with visceral hemangiomas and high output cardiac insufficiency.

Diagnosis

Diagnosis is, in the vast majority of cases, based on clinical features. In case of diagnostic uncertainty, an ultrasonography could be performed (differential diagnosis: vascular malformations, other tumours). Referral to ENT (ear-nose-throat) specialist should be considered in case of suspicious subglottic hemangioma (lower jaw hemangioma, stridor).

A brain or medullary MRI should be performed in case of suspicious PHACES or PELVIS syndrome, respectively. GLUT-1 staining may be helpful for the diagnosis.

Differential Diagnosis

Differential diagnoses include numerous entities.

Congenital hemangioma include rapidly involuting congenital hemangioma (RICH), sometimes associated with thrombocytopenia and/or consumptive coagulopathy, non-involuting congenital hemangioma (NICH), and partially involuting congenital hemangioma (PICH). Causal genes are GNAQ/GNA11.

Tufted angioma may also be associated with thrombocytopenia and/or consumptive coagulopathy. Tufted angioma and kaposiform hemangioendothelioma are part of a spectrum. Causal gene is GNA14. Other types of benign vascular tumors are spindle-cell hemangioma (causal genes IDH1/IDH2), epithelioid hemangioma (causal gene FOS), and pyogenic granuloma, also known as lobular capillary hemangioma (causal genes BFAF/RAS/GNA14).

Kasabach-Merritt syndrome is a rare condition characterized by profound and sustained thrombocytopenia, with profound hypofibrinogenemia, consumptive coagulopathy and elevated D-dimers, with a hemorrhagic risk, in association with vascular tumors (especially kaposiform hemangioendothelioma or tufted angioma).

Other rare types of benign vascular tumors are hobnail hemangioma, microvenular hemangioma, anastomosing hemangioma, glomeruloid hemangioma, papillary hemangioma, intravascular papillary endothelial hyperplasia, cutaneous epithelioid angiomatous nodule, acquired elastotic hemangioma, and littoral cell hemangioma of the spleen.

Differential diagnoses also include capillary malformations: nevus simplex/salmon patch, cutaneous and/or mucosal capillary malformations (also known as port-wine stain), including non-syndromic

capillary malformations, capillary malformations with central nervous system and/or ocular anomalies (Sturge-Weber syndrome), capillary malformations with bone and/or soft tissue overgrowth and diffuse capillary malformation with overgrowth, reticulate capillary malformation and cutis marmorata telangiectica congenita.

Finally, infantile haemangioma must be differentiated from malignant vascular tumors (angiosarcoma, and epithelioid hemangioendothelioma), and from locally aggressive or borderline vascular tumors (including kaposiform hemangioendothelioma, retiform hemangioendothelioma, papillary intralymphatic angioendothelioma, composite hemangioendothelioma, pseudomyogenic hemangioendothelioma, polymorphous hemangioendothelioma, hemangioendothelioma not otherwise specified, and Kaposi sarcoma).

Kasabach-Merritt syndrome is a rare condition characterized by profound thrombocytopenia, consumptive coagulopathy with a hemorrhagic risk, in association with vascular tumors (especially kaposiform hemangioendothelioma or tufted angioma).

Prevention & Therapy

Because of the spontaneous regression, therapy is generally not needed. In severe cases of childhood haemangioma or based on cosmetic demand, systemic (or sometimes topical) propranolol (beta-blocker) is now used as first line treatment.

Special

Aggressive early treatment (LASER) may be needed in fast growing lesions in anatomically risky localisations (i.e. eyes), however, systemic β -blocker under hospitalization may be preferable.

References

- [Hasbani DJ, Hamie L. Dermatol Clin. \(2022\) Infantile Hemangiomas. Oct;40\(4\):383-392.](#)
- [Luu J, Cotton CH \(2022\) Hemangioma Genetics and Associated Syndromes. Dermatol Clin Oct;40\(4\):393-400.](#)

3.2.7 Pyogenic granuloma (PG)

Grading & Level of importance: C.



G.Burg, Zürich

ICD-11

D23a.57

Synonyms

Various terms are used to designate lesions on the skin or on the mucous membranes: Granuloma pediculatum, Granuloma teleangiectaticum, lobular capillary hemangioma, pseudobotryomycoma, eruptive angioma, proliferating angioma; epulis granulomatosa (gingiva).

Epidemiology

Frequent; all ages are affected; M = F; more common in white than in black people.

Definition

“Pyogenic granuloma” is a misnomer, since this exophytic benign reactive proliferation of small vessels has nothing to do with bacterial “pyogenic” (pus producing) infection, like “botryomycosis”, which again is a misnomer (mostly due to staphylococcal, not fungal infection).

Aetiology & Pathogenesis

Injuries, wounds, hormones (pregnancy) are initiating factors. Nitrogen Monoxide Synthase (NOS), Fibroblast Growth Factor (FGF) and Connective Tissue Growth Factor (CTGF) are important pathogenetic factors, which promote the process.

Signs & Symptoms

Friable, bleeding exophytic proliferation with collarette by the surrounding epidermis is seen. Occasionally small angiomatous satellites are found in the vicinity. Older involuting lesions deep blue-brownish.

Localisation

PG tends to appear in wounds; areas exposed to injuries like extremities, face, tips of the fingers and

toes are often affected; lips, tongue, gingiva (epulis).

Classification

- eruptive pyogenic granuloma
- subcutaneous intravascular pyogenic granuloma
- pyogenic granuloma with satellites
- pyogenic granuloma on lips, gingiva (epulis)

Laboratory & other workups

Not needed; microbiologic swab in order to exclude differential diagnoses (see there).

Dermatopathology

Erosion of the surface with hemorrhagic crust formation; proliferation of newly formed capillaries with many mitoses around a central vessel. There is a mixed cellular inflammatory infiltrate in the dermis. Collarette of the epidermis.

Course

Spontaneous involution is possible. The prognosis is good following complete removal.

Complications

Bleeding; superinfection; recurrence if not completely removed.

Diagnosis

Typical clinical feature and history (trauma, pregnancy).

Differential diagnosis

Granulation tissue, amelanotic melanoma, hemangiosarcoma, botryomykosis (bacterial infection), bacillary angiomatosis (Bartonella Henselae-infection i.e. in HIV). Nevi.

Prevention & Therapy

Avoid injuries. Removal by excision or laser.


Special

Cave: Confusion with malignant melanoma.

References

- [Jafarzadeh, H, Sanatkhani M and Mohtasham N. \(2006\). Oral pyogenic granuloma: a review. Journal of Oral Science, Dec;48\(4\):167-75. doi: 10.2334/josnurd.48.167. PMID: 17220613](#)
- [Wollina U, Langner D, França K, Gianfaldoni S, Lotti T, Tchernev G. \(2017\). Pyogenic Granuloma - A Common Benign Vascular Tumor with Variable Clinical Presentation: New Findings and Treatment Options. Open Access Maced J Med Sci. Jul 13;5\(4\):423-426. doi: 10.3889/oamjms.2017.111. PMID: 28785323; PMCID: PMC5535648.](#)
- [Lomeli Martinez SM, Carrillo Contreras NG, Gómez Sandoval JR, Zepeda Nuño JS, Gomez Mireles JC, Varela Hernández JJ, Mercado-González AE, Bayardo González RA, Gutiérrez-Maldonado AF. \(2023\). Oral Pyogenic Granuloma: A Narrative Review. Int J Mol Sci. Nov 28;24\(23\):16885. doi: 10.3390/ijms242316885. PMID: 38069207; PMCID: PMC10706684.](#)
- [Zahid E, Bhatti O, Zahid MA, Stubbs M. \(2022\). Overview of common oral lesions. Malays Fam Physician. Aug 1;17\(3\):9-21. doi: 10.51866/rv.37. PMID: 36606178; PMCID: PMC9809440.](#)

3.2.8 Cutaneous mastocytosis

Grading & Level of importance: B 

A. de Masson, Paris; G. Dobos, Paris; M. Bagot, Paris

ICD-11

2A21.1

Synonyms

Mastocytosis, mast cell disease.

Definition

Cutaneous mastocytosis is characterized by a proliferation of mast cells in the skin.

Epidemiology

Cutaneous mastocytosis is a rare disease, most common in children. The prevalence is between 0.1 to

0.8% of dermatology consultations.

65% are observed in children below 15 years. Two peaks of incidence are observed one between 6 months and 2 years (55%) and one between 20 and 40 years (35%).

Aetiology & Pathogenesis

This disease is caused by an accumulation of mast cells in the skin. It is frequently caused by mutations in the KIT gene (KIT D816V) and is most often sporadic. MRGPRX2 activates mast cells which in turn release tryptase and histamine with local or systemic symptoms. Patients with severe MC mediator-related symptoms are usually diagnosed with MC activation syndrome (MCAS).

Signs & Symptoms

The most common form of skin mastocytosis is urticaria pigmentosa (maculopapular mastocytosis) presenting as numerous isolated red-brown, maculopapular lesions. Flashes and pruritus are common.

Diffuse cutaneous mastocytosis is rare and can manifest as diffuse erythema, skin infiltration, blistering, generally occurring in the first month of life.

Localized mastocytosis (mastocytoma) is a single lesion (or sometimes 1-3 lesions), most often found in children.

Telangiectatic mastocytosis is an extremely rare form of cutaneous mastocytosis.

Mastocytosis skin lesions respond with an urticarial reaction spontaneously or after irritation (Darier's sign: wheal, erythema, itch).

Furthermore, a so-called idiopathic mast cell activation syndrome (MCAS) was recently introduced as an entity within the mast cell disorders. Patients experience repeated episodes of symptoms mimicking anaphylaxis – allergic symptoms such as hives, swelling, low blood pressure, difficulty breathing and severe diarrhea may occur.

Localisation

Cutaneous mastocytosis (urticaria pigmentosa and diffuse cutaneous mastocytosis) shows a disseminated appearance on the entire body. Mastocytoma is a unique lesion, or multiple (generally 1 to 3) lesions localized anywhere on the skin. MCAS is a mast cell products release disorder without

specific localization without diffuse increase of mast cells as in the diffuse type and can be accompanied by angioedema.

Classification

The 2022 updated WHO classification of mastocytosis identifies 4 forms of cutaneous mastocytosis:

- Maculopapular cutaneous mastocytosis
- Urticaria pigmentosa
 - Monomorphic variant
 - Polymorphic variant
- Diffuse cutaneous mastocytosis
- Cutaneous mastocytoma
 - Isolated mastocytoma
 - Multilocalized mastocytomas

Laboratory & other workups

Serum tryptase levels are correlated with the mast cell tumor burden. A complete blood count is useful to screen for hematologic (medullary) involvement followed by bone marrow aspiration. Increases in serum mast cell tryptase and in urine levels of N-methylhistamine, 11B -Prostaglandin F₂α (11B-PGF₂α) and/or Leukotriene E₄ (LTE₄) are the only useful tests in diagnosis of MCAS.

Dermatopathology

The histological image is characterized by dense perivascular infiltrates of mast cells which stain positively with Giemsa or toluidine blue (heterochromasia). Immunohistochemistry (anti-CD117=KIT, anti-tryptase, and anti-CD25 antibodies) can help identify mast cells in skin. The KIT mutation (mostly D816V) can be identified in skin by molecular biology.

Course

If appearing in childhood, spontaneous remission is frequent. The adult version is generally clinically stable but mast cells may proliferate and lead to systemic symptoms.

Complications

Complications are not common. In adults, flushes, diarrhoea, vomiting, headache, depression, breathing problems can occur. Osteoporosis can be detected by osteodensitometry. Visceral

involvement should be investigated at diagnosis (abdominal ultrasonography, complete blood count). Anaphylaxis is a rare but severe complication. Worsening of symptoms may be provoked by alcohol and certain foods (histamine provocation) or drugs.

Diagnosis

Diagnosis is made based on typical clinical features: hyperpigmented macules and papules with positive Darier's sign, and confirmed by histopathology. At baseline, no additional workup is required in children. Serum tryptase levels, complete blood count, abdominal ultrasonography and osteodensitometry are performed at baseline in adults. In diffuse type of mastocytosis and KIT anomaly a bone marrow aspiration is indicated.

Differential Diagnosis

Differential diagnoses include lichen planus, disseminated granuloma annulare or sarcoidosis, secondary syphilis (not permanent, no swelling), plane warts, multiple leiomyomas various adnexal tumours and pseudolymphoma.

Prevention & Therapy

No therapy is needed for this disease if the symptoms are mild. Treatment possibilities include non-sedating antihistamines; H2 blockers or cromoglycate for gastrointestinal symptoms; PUVA; short-term high-potency topical glucocorticoids. Patients (especially with elevated tryptase levels) should be informed about the risk of anaphylaxis, and given written information about the avoidance of triggers (e.g., certain medications, anesthetics, may trigger histamine release). Patients with a high risk of anaphylaxis (or history of anaphylaxis) should be prescribed an adrenaline syringe and be informed about how to use it in case of anaphylaxis.

Special

Malignant transformation very rare.

References

- [Arock M, Hoermann G, Sotlar K, Hermine O, Sperr WR, Hartmann K, Brockow K, Akin C, Triggiani M, Broesby-Olsen S, Reiter A, Gotlib J, Horny HP, Orfao A, Metcalfe DD, Valent P. \(2022\) Clinical impact and proposed application of molecular markers, genetic variants, and cytogenetic analysis in mast cell neoplasms: Status 2022. J Allergy Clin Immunol. Jun;149\(6\):1855-1865.](#)

- [Leguit RJ, Wang SA, George TI, Tzankov A, Orazi A. \(2023\) The international consensus classification of mastocytosis and related entities. Virchows Arch. Oct 10. doi: 10.1007/s00428-022-03423-3.](#)
- [Valent P, Akin C, Hartmann K, Alvarez-Twose I, Brockow K, \(2021\) Updated Diagnostic Criteria and Classification of Mast Cell Disorders: A Consensus Proposal. Hemasphere. 2021 Oct 13;5\(11\): e646.](#)

3.2.9 Cutaneous Cysts

Grading & Level of importance: B



M. Bagot, Paris; G. Dobos, Paris; S. Hobelsberger, Dresden; A. de Masson, Paris

ICD-11

LOBz

Synonyms

Cysts of skin, lips, mucous membrane.

Definition

Cysts with epithelial lining (CEL): benign encapsulated firm or fluctuant lesions, containing material of various types (squamous material, sebum, sweat, hair, oily fluid).

Cysts without epithelial lining (pseudocysts) (PC): clinically are similar to CEL, but do not have a capsule.

Epidemiology

Frequent. M>F.

Aetiology & Pathogenesis

Often superficial trauma, small injuries or subepidermal blistering diseases (milia due to blisters in porphyria cutanea tarda or epidermolysis). Dispersion of epidermal or follicular germs or ductal structures into the dermis.

Signs & Symptoms

CEL: Round, slowly growing nodule, showing a central pore in some cases. Fixed or slightly movable

beyond the overlying erythematous smooth skin surface.

PC: Translucent submucosal node developing on lip, tongue or buccal mucosa in the vicinity of salivary glands, following minor injury.

Milia (sing.milium) are tiny epidermal cysts arising from the infundibular portion of vellus hairs or dermal sweat ducts, without connection to the overlying epidermis. They present as white or yellowish tiny papules and usually disappear within a few weeks.

Ganglion: synovial pseudocyst with wall formed by fibrous tissue, surrounding amorphous myxoid material and with connection to synovia.

Localisation

CEL: Preferred localisations are face, neck, capillitium and back. PC: lips or mucous membranes, site of injury.

Classification

- Epithelial cysts
 - Sebaceous cysts
 - Epidermal cysts
 - Trichilemmal cysts
 - Hybrid cysts
- Mucous (pseudo-) cysts (mucocele)
 - Oral Mucous Cyst
 - Lip cyst
 - Digital Myxoid Cyst
 - Synovial Cyst (Ganglion)

Laboratory & other workups

None or biopsy; diaphanoscopy (translucency), ultrasound.

Dermatopathology

Cysts with Epithelial Lining (CEL): epithelial wall with epidermal or trichilemmal cornification and

squamous debris with or without follicular structures. Reactive inflammatory infiltrate of the dermis, sometimes after rupture of wall with granulomatous features and multinucleated foreign body giant cells.

Cysts without Epithelial Lining (Pseudocysts) (PC): Fibrous wall including oily liquid or amorphous myxoid material.

Course

Sometimes self-healing by spontaneous regression, especially in mucous cysts.

Complications

CEL: Frequent rupture of the epithelial cyst wall with subsequent inflammatory reaction with or without bacterial superinfection leading to granulomatous foreign body reaction, abscess formation, bursting, and draining.

PC: none, sometimes spontaneous jelly-like exsudate.

Diagnosis

Clinical and histologic features.

Differential Diagnosis

Acneiform reactions, fibroma, lipoma, adnexal tumor.

Prevention & Therapy

Prevention not possible. Superinfected epidermal cysts developing in an abscess need an incision and tamponade. Antibiotics if severely superinfected and additional surrounding tissue inflamed. Surgical removal including capsule in the native non-inflamed status. PC of mucous membranes may regress spontaneously.

Special

None.

References

- [Kaya G, Saurat JH. \(2018\) Cutaneous Adnexal Cysts Revisited: What We Know and What We Think We Know. Dermatopathology \(Basel\). Jun 7;5\(2\):79-85.](#)

3.3 Premalignant and Malignant Tumours

3.3.1 Actinic Keratosis

Grading & Level of importance: B
M. Bagot, Paris; J. Malvehy, Barcelona



ICD-11

EK90

Synonyms

Solar keratosis.

Definition

Actinic keratosis is a carcinoma in situ caused by chronic light exposure.

Epidemiology

The frequency is dependent of skin type and life conditions. Prevalence in the US is 10% in females and 26% in males, however, in UK it is 6% in females and 15% in males. Total prevalence of AK in Germany, standardized for age and sex, was 2.66%; the age-standardized rate was higher for men (3.85%) than for women (1.45%). In the group of 60-70 years old males it is 11.5%. The highest incidence rates are found in Queensland /Australia.

Aetiology & Pathogenesis

Actinic keratosis, a non-melanoma skin cancer precursor, is mainly induced by chronic UV exposure, and genetic predisposition such as skin types I-III. In some patients, human papilloma virus (HPV) infective types or immunosuppression after transplantation or in HIV patients may play an important role. Chemical agents including tar may play also a role. AK's may slowly progress over years and in 1 out of 10 cases progress after several years to an invasive squamous cell carcinoma. First molecular

changes are the occurrence of p53. At this point, some AKs may even regress. Further oncogenic changes with occurrence of, for example c-myc, turns the process on and single mutated keratinocytes may aggregate to a clonal expansion in the epidermis.

Signs & Symptoms

Lesions present as circumscribed hyperkeratotic yellow-brown or red papules and plaques. Finally, they may be confluent and involve large areas of lesions (field cancerisation). Other lesions may be flat and atrophic, some are hyperpigmented.

Cornu cutaneum (cutaneous horns) are conical projections, made of hyperkeratotic material and look similar to animal horns.

Localisation

They are mainly located on sun-exposed areas (scalp, face - preferentially over the brows and on the cheeks, back of hands, shins, forearms, helix).

Classification

Actinic keratoses are usually classified in grades 1 to 3 which relates to increasing atypia of keratinocytes in the different layers of the epidermis. However, involvement of the perifollicular and periacrosyringial layers of keratinocyte can already move towards invasion. Actinic keratosis may evolve from all grades towards a squamous cell carcinoma.

Dermatopathology

The histology shows hyperkeratosis, epidermal disarray, and atypical keratinocytes, assembled in different layers of the epidermis, and around the acroinfundibula. A strong inflammatory infiltrate is present in the upper dermis, which usually shows actinic elastosis.

Course

The evolution is chronic and long-lasting. Actinic keratosis may regress spontaneously or evolve towards a squamous cell carcinoma.

Complications

A transition to squamous cell carcinoma is possible, with an estimation of a frequency of 5% per year. Resistance or recurrence after topical or ablative treatments, fast growth and pain are reliable signs

of transformation. Field cancerisation is an additional risk factor of transition to squamous cell carcinoma.

Diagnosis

The diagnosis relies on clinical features and is proven by histology. Physical examination is usually sufficient for the diagnosis. However, in some cases (thicker AK, pigmented AK) dermoscopy is useful for the diagnosis. If a squamous invasive skin carcinoma or other malignancy cannot be ruled out a biopsy is mandatory.

Differential Diagnosis

Actinic keratoses must be differentiated from Bowen's disease, seborrhoeic or HPV keratoses, adnexal tumors of the skin, and superficial basal cell carcinoma. Pigmented seborrhoeic or viral keratosis must be differentiated from lentigo maligna and lentigo maligna melanoma.

Prevention & Therapy

Prevention relies on sun protection (sunscreens, textile UV protective clothes, UV glasses, umbrella, avoidance of high UV energy exposure times such as 11 am to 3 pm). Oral daily supplementation with niacin is proven to be a preventive measurement. Lesions can be destroyed by curettage, cryosurgery or photodynamic therapy. Topical treatments are with 5-fluorouracil or immune modifiers such as imiquimod cream, diclofenac or ingenol mebutate. Suspicious lesions must be biopsied and may need to be excised.

Special

Any patients undergoing transplantation and long-term immunosuppression should be examined before transplantation and offered regular follow-up examination.

References

- [de Oliveira ECV, da Motta VRV, Pantoja PC, Ilha CSO, Magalhães RF, Galadari H, Leonardi GR. \(2019\) Actinic keratosis review for clinical practice. Int J Dermatol.; 58:400-407.](#)
- [Willenbrink TJ, Ruiz ES, Cornejo CM, Schmults CD, Arron ST, Jambusaria-Pahlajani A. Field cancerization: Definition, epidemiology, risk factors, and outcomes. J Am Acad Dermatol. 2020; 83:709-717](#)
- [Schmitz L, Broganelli P, Boada A. \(2022\) Classifying Actinic Keratosis: What the Reality of Everyday Clinical Practice Shows Us. J Drugs Dermatol. Aug 1;21\(8\):845-849. doi: 10.36849/JDD.6704. PMID: 35946975.](#)

- [Balcere A, Konrāde-Jilmaza L, Pauliņa LA, Čēma I, Krūmiņa A. \(2022\) Clinical Characteristics of Actinic Keratosis Associated with the Risk of Progression to Invasive Squamous Cell Carcinoma: A Systematic Review. J Clin Med. Oct 6;11\(19\):5899.](#)
- [Sinclair R, Baker C, Spelman L, Supranowicz M, MacMahon B. \(2021\) A review of actinic keratosis, skin field cancerisation and the efficacy of topical therapies. Australas J Dermatol. May;62\(2\):119-123. doi: 10.1111/ajd.13447. Epub 2020 Aug 25. PMID: 32840870; PMCID: PMC8247342.](#)

3.3.2 Carcinoma in situ

Grading & Level of importance: B.

M. Bagot, Paris; P. Pasquali, Barcelona



ICD-11

2E64

Synonyms

Bowen's disease, erythroplasia of Queyrat (glans penis).

Definition

Carcinoma in situ is an intraepidermal or intraepithelial carcinoma.

Aetiology & Pathogenesis

Carcinoma in situ can be induced by UV exposure, immunosuppression, HPV, tobacco or betelnut.

Signs & Symptoms

Lesions are circumscribed, often unique, erythematous (sometimes scaly) well-demarcated patch or plaques, or persistent whitish mucosal lesions.

Localisation

They are localized on sun-exposed skin, genitalia or buccal mucosa.

Classification

Lesions are classified grade 1 to 3 according to progression and involvement in histology. Carcinoma in situ may evolve towards an invasive squamous cell carcinoma.

Laboratory

The abnormal expression of p53 is considered a marker of premalignant lesions and plays a central role in the development of SCC.

Dermoscopy

Dermoscopy can be of great help diagnosing this entity. Vessels can form irregular clusters of coiled vessels and/or globular vessels (small red clods). A scaly surface and pigmented structures may be seen arranged in lines as well as white circles may be present, often in irregular clusters. There may be superficial erosion and crusting.

Using polarisation, white shiny 'crystalline' structures may form rosettes on facial skin.

Dermatopathology

Histology shows atypical keratinocyte with proliferation through the whole thickness of the epidermis. The atypical cells have hyperchromatic nuclei and show sometimes atypical mitoses.

Course

Lesions gradually enlarge in an irregular fashion. The surface may become hyperkeratotic or crusting. Field cancerisation may finally develop.

Complications

Lesions may evolve towards an invasive cutaneous or mucosal squamous cell carcinoma (known as Bowenoid carcinoma). Lesions then become infiltrated and sometimes ulcerated.

Diagnosis

Diagnosis relies on clinical features and histology.

Differential Diagnosis

Carcinoma in situ must be differentiated from superficial basal cell carcinoma, bowenoid papulosis or extramammary Paget's disease. Confirmation of the diagnosis must be performed by histology.

Prevention & Therapy

The treatment depends on localisation and histological type. It relies on topical treatments (imiquimod, 5-fluorouracil), minimally invasive techniques (cryosurgery, photodynamic therapy, radiotherapy) and eventually, surgical excision.

Special

None.

References

- [Arlette JP, Trotter MJ. Squamous cell carcinoma in situ of the skin: history, presentation, biology and treatment. \(2004\) Australas J Dermatol.45:1-9;](#)
- [Bell HK, Rhodes LE. \(1999\) Bowen's disease--a retrospective review of clinical management. Clin Exp Dermatol. 1999; 24:338-9.](#)

3.3.3 Paget's Disease

Grading & Level of importance: B
M. Bagot, Paris; P. Pasquali, Barcelona



ICD-11

Code of breast: XH3E21: extramammary: XH70F8

Synonyms

None.

Definition

Paget's disease, also known as Paget's disease of the breast or mammary Paget's disease, is an uncommon intra-epidermal adenocarcinoma, arising from intraductal carcinoma in the breast. It can also arise from apocrine sweat glands or underlying carcinomas, for example, rectum, prostate (extramammary Paget's disease).

The term Paget's disease of the nipple is used to distinguish the condition from Paget's disease of the bone (where bones become weak and deformed) and it is unrelated to it.

Epidemiology

Paget's disease is rare and represents 3% of all breast cancers.

Aetiology & Pathogenesis

Paget's disease occurs in less than 3% of breast cancers. The associated breast carcinoma is of the intraduct variety.

Signs & Symptoms

Lesions are circumscribed, erythematous, sometimes scaly, increasingly infiltrated plaques located on nipple (unilateral), axilla, groin or perianal skin. A chronic dermatitis involving one nipple must raise suspicion of Paget's disease.

Localisation

Lesions are localized on nipple, axilla, genitalia, lower abdomen, or perianal region.

Classification

Extramammary PD (EMPD) is classified - based on the presence or absence of associated malignancies- into:

1. Primary or intraepithelial
2. Secondary

The secondary type is associated with underlying carcinoma or distant tumors.

Laboratory & other workups

When confronted with a diagnosis of mammary Paget's disease, it is essential to investigate mammary gland neoplasm. A careful clinical examination and imaging exams assessment are necessary for diagnostic conclusion. Mammographs and ultrasound are the most commonly used techniques to detect masses or calcifications. A negative exam does not exclude the presence of an underlying tumor.

Dermoscopy of mPD shows pink structureless areas, fine white scales, dotted and a few short linear vessels. In case of pigmentation brown structureless areas and pigmented granules can be present.

Reflectance confocal microscopy can be used for diagnosing and for differentiation between invasive EMPD versus in situ.

Dermatopathology

Histology/immunohistology shows large clear intra-epithelial tumour cells, PAS positive.

Paget cells are present in the epidermis. In histochemical reactions for acid mucin, such as Alcian Blue, colloidal iron and mucicarmine Mayer are detected in the cytoplasm of neoplastic cells. Immunohistochemical examination is very important to the differential diagnoses with Bowen's disease, a melanotic superficial spreading melanoma and to determine whether it is a primary or secondary disease.

Course

The lesions slowly and gradually spread.

Complications

Lesions are often associated with intraductal carcinoma (Paget's disease) or adenocarcinoma (extramammary Paget's disease). One area may become thickened and ulcerated.

Diagnosis

Diagnosis relies on clinical features (localisation) and histology/immunohistochemistry.

Differential Diagnosis

Paget's disease must be differentiated from nipple chronic dermatitis, Naevoid hyperkeratosis of the nipple, perianal dermatitis, psoriasis.

Prevention & Therapy

Extramammary Paget lesions can be treated with topical (imiquimod), minimally invasive (cryosurgery, photodynamic therapy) and surgical excision adjusted to tumour size and underlying disease. A multidisciplinary approach is important.

Special

None.

References

- [Kanitakis J. \(2007\) Mammary and extramammary Paget's disease. J Eur Acad Dermatol Venereol.; 21:581-90.](#)

- [Ishizuki S, Nakamura Y. \(2021\) Extramammary Paget's Disease: Diagnosis, Pathogenesis, and Treatment with Focus on Recent Developments. Curr Oncol.; 28:2969-2986.](#)
- [Apalla Z, Errichetti E, Kyrgidis A, Stolz W, Puig S, Malvehy J et al. \(2019\) Dermoscopic features of mammary Paget's disease: a retrospective case-control study by the International Dermoscopy Society. J Eur Acad Dermatol Venereol.Oct;33\(10\):1892-1898.](#) [Lopes Filho LL, Lopes IM, Lopes LR, Enokihara MM, Michalany AO, Matsunaga N. \(2015\) Mammary and extramammary Paget's disease. An Bras Dermatol. Mar-Apr;90\(2\):225-31.](#)

3.3.4 Cutaneous Squamous Cell Carcinoma

Grading & Level of importance: B
M. Bagot, Paris; P. Pasquali, Barcelona



ICD-11

2C31

Synonyms

Epidermoid carcinoma, keratinocyte tumor

Definition

Squamous cell carcinoma is a malignant keratinocytic tumour that starts in the epidermis and potentially can invade into deeper layers and metastatize.

Epidemiology

The incidence is about 30-50 /100,000 per year in Europe. Incidence is 387/100,000/year in Australia.

Aetiology & Pathogenesis

Squamous cell carcinoma arises on previously damaged skin: UV (which causes mutations in the p53 tumour suppressor gene; especially UVB), ionizing radiation, arsenic, tar, soot, scars, HPV (β -HPV and HPV subtypes 5, 8, 17, 20, 24, and 38). Lesions tend to arise from precursors lesions: actinic keratoses, scars, chronic ulcers. Predisposing factors are skin types I and II, occupations with marked UV exposure (farmers, mountaineers, sailors, roofers and construction workers).

Signs & Symptoms

Lesions are hyperkeratotic, irregular papules or nodules, sometimes crusted and ulcerated, more commonly occurring on sun-exposed areas.

Localisation

Lesions are mainly located on head, ear, lower lip, back of hands, forearms, shins.

Classification

According to dermatopathologic findings, the grading is related to differentiation of tumor cells with final complete de-differentiation (Broder's classification).

Histologically, they can be classified as well differentiated, moderately, poorly differentiated or anaplastic cutaneous SCC.

Cutaneous SCC can be classified as low-risk or high-risk, depending on the chance of tumour recurrence and metastasis. High-risk SCC have diameter greater than or equal to 2 cm, located in high-risk area, arising in immune suppressed patient, have a histological thickness greater than 2 mm, poor differentiated histology, or with the invasion of the subcutaneous tissue, nerves and blood vessels.

Laboratory & other workups

Dermoscopy can aid in diagnosing, classification, and follow-up; high frequency ultrasound and optical coherence tomography allow to determine depth, length and shape of tumor; reflectance confocal microscopy is used for diagnosis.

Dermatopathology

Histology shows hyperkeratosis, strands of epithelium extending into dermis, atypia, mitoses, inflammatory infiltrate, dyskeratosis, single cell necrosis (apoptosis with eosinophilic cytoplasm), and keratin pearls. Degree of differentiation varies from grade I (well-differentiated, risk of metastasis 1-2%), to grade IV (poorly differentiated with high risk).

Course

Tumours on tongue, vulva, penis and anus have greater risk of metastasis. Prognosis is worse in immunosuppressed patients.

Complications

Local tissue destruction and metastasis are the main complications.

Diagnosis

Diagnosis relies on clinical features and histology.

Differential Diagnosis

Squamous cell carcinoma must be differentiated from actinic keratoses, Bowen's disease, basal cell carcinoma, keratoacanthoma, verruca vulgaris, hypertrophic lichen planus and tumors of skin adnexal structures.

Prevention & Therapy

Treatment depends on size and localization. Surgical excision should be done with histologically proven margins: other options are cryosurgery, radiotherapy, radiofrequency therapy with bleomycin, immune modulators (check point inhibitors) and specific targeted therapies.

References

- [Nehal KS, Bichakjian CK. \(2018\) Update on Keratinocyte Carcinomas. N Engl J Med. 379:363-374.](#)
- [Ashley Wysong \(2023\) Squamous-Cell Carcinoma of the Skin. N Engl J Med 2023;388:2262-73](#)
- [Bander TS, Nehal KS, Lee EH. \(2019\) Cutaneous Squamous Cell Carcinoma: Updates in Staging and Management. Dermatol Clin. ; 37:241-251.](#)

3.3.5 Basal Cell Carcinoma

Grading & Level of importance: B.
M. Bagot, Paris



ICD-11

2C32

Synonyms

Basal cell epithelioma, basalioma.

Definition

Basal cell carcinoma is a locally destructive malignant tumour derived from pluripotential epidermal stem cells. It almost never metastasises.

Epidemiology

The incidence in Europe is 450 to 500/100,000/year. Incidence in US is 1,019/100,000/y in women and 1,488/100,000/year in men. It is the most common skin malignancy.

Aetiology & Pathogenesis

Predisposing factors are skin types I and II, UV exposure, immunosuppression, radiation, arsenic exposure/ingestion, and genetic. Naevoid basal cell carcinoma syndrome (Gorlin-Goltz syndrome) is a genetic predisposition for multiple basal cell carcinomas. Most, if not all, cases of BCC demonstrate overactive Hedgehog signalling.

Signs & Symptoms

Lesions are pearly nodules with telangiectases, with an often-raised border and central ulceration. They may have various presentations: solid or nodular; cystic ulcerated (rodent ulcer); pigmented sclerosing (greater risk of recurrence); sclerodermiform infiltrating without sharp borders.

Localisation

Lesions are usually located on the face (85%), less often on trunk or extremities. In contrast to squamous cell carcinoma, they are not restricted to sun-exposed areas.

Classification

There are no precursor lesions. Classification is done due to clinical (C) or histological (H) features.

- Superficial BCC (C)
- Nodular (solid) BCC (C)
- Sclerodermiform (Morphaeic infiltrating) BCC (C and H)

- Adenocystic BCC (H)
- Pigmented BCC (C)
- Baso-squamous BCC (H)
- Dedifferentiated BCC (H)
- Ulcus rodens (C)
- Ulcus terebrans (C)
- Genetically based BCC such as Gorlin-Goltz syndrome (basal cell nevus syndrome) (C)

Laboratory & other workups

None.

Dermatopathology

Histology shows proliferation of basaloid cells streaming downwards from the basal cell layer of the epidermis or from follicular epithelium in upper dermis, peripheral palisading cell layer (darker row of cells at periphery), mitoses, and single cell necrosis (apoptosis).

There are subtypes which mimic abnexal structures of the skin. In the infiltrating type may show dedifferentiation and carcinoma-like pattern.

Course

Lesions run a slow progressive course of peripheral or vertical extension. They may become ulcerated and locally extensive. Metastases in BCC are extremely rare.

Complications

The recurrence rate is up to 5% within 5 years after surgery or radiation.

Diagnosis

Diagnosis relies on clinical features and histology.

Differential Diagnosis

Basal cell carcinoma must be differentiated from dermal naevi, sebaceous gland hyperplasia, fibroma, pseudolymphoma, melanoma, carcinoma in situ (Bowen disease or Paget disease), actinic keratosis

and tumors of skin adnexal tumors.

Prevention & Therapy

Prevention

UV-light protection is essential.

Treatment depends on the type, size and location. Surgical excision with appropriate margins is the main treatment but recurrences may occur. For the sclerosing tumour type, micrographic control of margins is mandatory. Curettage, radiation therapy and cryosurgery can also be used in the small superficial types. Superficial variants can also be treated with photodynamic therapy, topical 5-fluorouracil, immunotherapy (imiquimod) or ablative laser with monitoring follow up.

New targeted therapies with inhibition of hedgehog pathway may be indicated in advanced cases (Vismodegib, Sonidegib).

Special

None.

References

- [Firnhaber JM. \(2020\) Basal Cell and Cutaneous Squamous Cell Carcinomas: Diagnosis and Treatment. Am Fam Physician. ; 102:339-346.](#)
- [Tanese K. \(2019\) Diagnosis and Management of Basal Cell Carcinoma. Curr Treat Options Oncol. ; 20:13.](#)
- [Fania L, Didona D, Morese R, Campana I, Coco V, Di Pietro FR, Ricci F, Pallotta S, Candi E, Abeni D, Dellambra E. \(2020\) Basal Cell Carcinoma: From Pathophysiology to Novel Therapeutic Approaches. Biomedicines.; 8:449.](#)

3.3.6 Lentigo Maligna

Grading & Level of importance: B
M. Bagot, Paris; J. Malvehy, Barcelona



ICD-11

2E63.00

Synonyms

Hutchinson melanotic freckle; lentigo maligna melanoma in situ; premalignant melanosis of Dubreuilh; Hutchinson freckle.

Definition

Lentigo maligna is an intraepithelial proliferation of atypical melanocytes occurring mostly in sun-damaged skin and in elderly patients. LM is defined as melanoma in situ (MIS) on chronically sun-damaged skin. If the lesion becomes invasive, it is termed lentigo maligna melanoma (LMM).

Epidemiology

Lentigo maligna represents 10-15% of all melanoma with a slight female predominance. Incidence is 3.84/100,000/y. Mean age around 70 years.

Aetiology & Pathogenesis

Lentigo maligna occurs after natural and artificial chronic UV exposure, and it accounts for about 5-15% of melanomas and 10-26% of head and neck melanomas, accounting for a larger percentage of melanomas occurring in patients over the age of 65 years. The progression rate of LM to LMM is not known but it is estimated to be about 5%. The 5 years survival rate about 97-100%. LM/LMM is more likely to harbor mutations in KIT, compared to other subtypes of melanoma, in which BRAF mutations are more common. Other mutations are in CCND1, MITF, NRAS, and p53.

Signs & Symptoms

Lesions are irregularly pigmented macules or patches with irregular borders, not palpable, slowly growing.

Localisation

They are most frequently located on sun-exposed areas of the face and neck and scalp in bald patients but they can also appear in the trunk and extremities of patients with chronic sun damage.

Classification

Precursor of lentigo maligna melanoma.

Diagnosis

The differential diagnosis of pigmented macules of the face are other epithelial tumours such as pigmented actinic keratosis and seborrheic keratosis of the face. The examination with dermatoscopy is recommended for the clinical diagnosis. Reflectance confocal microscopy is the most accurate non-invasive diagnostic technique for flat pigmented lesions that are in the differential diagnosis of LM. They can also guide the most adequate place for the skin biopsy that is mandatory when LM is suspected.

Dermatopathology

Histology shows epidermal atrophy, increased number of atypical melanocytes in basal layer (also extending into hair follicle), dermal lymphocytic infiltrate, melanophages, and solar elastosis. Specific immunostainings of melanocytes are recommended for the diagnosis of LM and evaluation of margins after surgery.

Course

Lesions are slowly extending and finally develop into a lentigo maligna melanoma. Lesions located at the mucosal borders at the eye lids and lips may show a higher risk of progression.

Complications

After several years, lesions may become infiltrated and nodular, and may evolve towards an invasive malignant melanoma with metastasis.

Diagnosis

Diagnosis relies on clinical features, histology and dermatoscopy.

Differential Diagnosis

Lentigo maligna must be differentiated from pigmented actinic keratosis, lentigo simplex, solar lentigo, flat seborrhoeic keratoses, melanoma (lentigo maligna melanoma, superficial spreading melanoma), naevoid lentigo, or atypical naevi.

Prevention & Therapy

The treatment depends on the size and location. Surgical excision is preferred. Mohs micrographic surgery with special staining of the atypical melanocytes reduces the risk of recurrence and spares benign skin tissue compared to conventional surgery with wider margins. If excision is not possible or otherwise contraindicated, alternatives are soft X-ray treatment, or topical imiquimod (off label).

References

- [Naik PP. \(2021\) Diagnosis and Management of Lentigo Maligna: Clinical Presentation and Comprehensive Review. J Skin Cancer.; 24:7178305](#)
- [Kallini JR, Jain SK, Khachemoune A. \(2013\) Lentigo maligna: review of salient characteristics and management. Am J Clin Dermatol.; 14:473-80.](#)
- [Robinson M, Primiero C, Guitera P, Hong A, Scolyer RA, Stretch JR, Strutton G, Thompson JF, Soyer HP. \(2020\) Evidence-Based Clinical Practice Guidelines for the Management of Patients with Lentigo Maligna. Dermatology.; 236:111-116.](#)

3.3.7 Malignant Melanoma

Grading & Level of importance: B



M. Bagot, Paris; G. Dobos, Paris; J. Malvehy, Barcelona; A. De Masson, Paris

ICD-11

2C30.Z

Synonyms

Often referred to just as melanoma.

Definition

Malignant tumour arising from neuroectodermal cells (melanocytes, naevus cells) with a high risk of

metastasis.

Epidemiology

In Europe, the incidence rate is <10-25 new melanoma cases per 100,000 inhabitants and is increasing by 5% yearly; in the USA 20-30 per 100,000; and in Australia, where very high incidence is observed 50-60 per 100,000. There may be a familial (genetic) predisposition in 5-10% of cases, such as a germline mutation in the CDKN2A gene. Melanoma is slightly more frequent in female patients, the average age at diagnosis is 40-50 years. Melanoma occurs mainly in adults and is exceptional in children.

The following types are observed in order of decreasing frequency: Superficial spreading melanoma (SSM) 41%, Nodular melanoma (NMM) 14%, Lentigo maligna melanoma (LMM) 2.7-14%, Acral lentiginous melanoma (ALM) 1-5 % with lower frequency in Caucasians, higher in people of colour.

Aetiology & Pathogenesis

Most melanomas arise on normal skin. Risk factors of melanoma include fair skin, red-blond hair, freckles, blue eyes, history of sunburn as a child, UV exposure, large number (>100) of melanocytic naevi, and personal or familial (1st degree relative) history of melanoma. Melanoma is one of the tumors with the highest mutational charge. Assays determining the genetic expression profile measure of various sets of genes define a gene signature. This signature may be useful to evaluate the prognostic, the metastatic potential and the possible treatments.

The most frequent somatic mutations involve BRAF, NRAS, NF1, PTEN, and KIT. These genes are involved in the MAPK (mitogen-activated protein kinase) and PI3K (phosphoinositol-3-kinase) signalling pathways. These pathways control proliferation, activation, differentiation and survival of cells. The most frequent mutation, found in 50% of melanoma involves the codon 600 of BRAF. BRAF V600E (substitution of a valine to glutamic acid) is found in 80-90% of cases, and BRAF V600K (substitution of a valine to lysine) is found in 5-12% of cases. These mutations induce an activation of the MAPK pathway. Other mutations involve NRAS (15-30%), NF1 (10-15%) and KIT (<10%).

Melanoma occurring on intermittently UV exposed regions often present BRAF V600E mutations. In contrast, melanomas occurring on chronically sun exposed regions more frequently present NRAS, NF1 or BRAF V600K mutations.

Signs & Symptoms

Superficial spreading melanoma (SSM), the most frequent form, typically presents as a heterogeneous, irregular, pigmented skin lesion with a rapid evolution. Nodular melanoma presents as a pigmented (or not) nodule of the skin. Acrolentiginous melanoma is found on the extremities. The lesions may be

ulcerated. Lentigo maligna melanoma (Dubreuilh melanoma) is an irregular pigmented lesion of sun-exposed areas typically found in elderly people.

Suspicious features are known as the ABCDE criteria and include: A for Asymmetry, B for irregular Border, C for inhomogeneous Color, D for Diameter over 6 mm, E for rapid Evolution. Additional danger signs include bleeding, crusting, ulceration, inflammation.

Localisation

Melanoma can arise anywhere on the skin, and occasionally also on mucosa (vagina, mouth, sinuses, choroid, retina, anus/rectum,). Lentigo maligna melanoma occurs on chronic sun damaged skin (face, scalp, trunk, extremities) and acrolentiginous melanoma on the extremities. Rarely, the diagnosis may be performed at the metastatic stage and the primary tumour is not found any longer.

Classification

Traditional and new clinical classification:

- Superficial spreading melanoma (SSM): heterogeneous, irregular, pigmented skin lesion with a variable evolution. (Low cumulative sun damage melanoma)
- Nodular melanoma: pigmented (or not) often eroded or bleeding nodule of the skin. No UV exposure preference.
- Acrolentiginous melanoma is found on the extremities (plantar site, nails). Low to no UVR exposure (or variable/incidental).
- Lentigo maligna melanoma is an irregular pigmented lesion of sun-exposed areas arising from an intraepidermal Lentigo maligna (Dubreuilh's disease or Lentigo maligna of Hutchinson). High cumulative sun damage melanoma.

Other subtypes are: melanoma arising in a congenital naevus, desmoplastic melanoma, nevoid melanoma, mucosal melanoma, uveal melanoma, etc.

AJCC (American Joint Committee on Cancer) Staging.

The evidence-based updated AJCC melanoma staging system guides patient treatment with cutaneous melanoma, provides better prognostic estimates and precises the stratification of patients entering clinical trials.

Table 1. AJCC Melanoma Staging system, 8th Edition.

Adapted from Gershenwald et al, 2017

T (primary tumor)	N (regional lymph nodes)	M (distant metastasis)
<p>T1: Breslow \leq 1 mm</p> <p>a: \leq 0.8mm without ulceration</p> <p>b: 0.8 mm with ulceration</p> <p>or $>$ 0.8 mm and $<$ 1 mm without ulceration</p>	<p>N1: 1 tumor-involved node or in transit, satellite, and/or microsatellite metastases with no tumor-involved nodes</p> <p>a: 1 clinically occult (detected by SLN biopsy)</p> <p>b: 1 clinically detected</p> <p>c: no regional lymph node disease</p>	<p>M1a: distant metastasis to skin, soft tissue including muscle, and/or nonregional lymph node</p> <p>0: LDH level not elevated</p> <p>1: LDH level elevated</p>
<p>T2: Breslow $>$ 1.0–2.0 mm</p> <p>a: without ulceration</p> <p>b: with ulceration</p>	<p>N2: 2 or 3 tumor-involved nodes or in transit, satellite, and/or microsatellite metastases with one tumor-involved node</p> <p>a: 2 or 3 clinically occult (detected by SLN biopsy)</p> <p>b: 2 or 3, at least 1 clinically detected</p> <p>c: 1 clinically occult or clinically detected</p>	<p>M1b: distant metastasis to lung with or without M1a sites of disease</p> <p>0: LDH level not elevated</p> <p>1: LDH level elevated</p>
T (primary tumor)	N (regional lymph nodes)	M (distant metastasis)
<p>T3: Breslow $>$ 2.0–4.0 mm</p> <p>a: without ulceration</p> <p>b: with ulceration</p>	<p>N2: 2 or 3 tumor-involved nodes or in transit, satellite, and/or microsatellite metastases with one tumor-involved node</p> <p>a: 2 or 3 clinically occult (detected by SLN biopsy)</p> <p>b: 2 or 3, at least 1 clinically detected</p> <p>c: 1 clinically occult or clinically detected</p>	<p>M1: distant metastasis to non-CNS visceral sites with or without M1a or M1b sites of disease</p> <p>0: LDH level not elevated</p> <p>1: LDH level elevated</p>

<p>T4: Breslow > 4 mm</p> <p>a: without ulceration</p> <p>b: with ulceration</p>	<p>N3: ≥ 4 tumor-involved nodes or in transit, satellite, and/or microsatellite metastases with 2 or more tumor-involved nodes, or any number of matted nodes without or with in-transit, satellite and/or microsatellite metastases</p> <p>a: 4 or more clinically occult (detected by SLN biopsy)</p> <p>b: 4 or more, at least one of which clinically detected or any number of matted nodes</p> <p>c: 2 or more clinically occult or clinically detected and/or presence of any number of matted nodes</p>	<p>M1d: distant metastasis to CNS with or without M1a, M1b, or M1c sites of disease</p> <p>0: LDH level not elevated</p> <p>1: LDH level elevated</p>
---	---	---

AJCC Staging 8th Edition	
Stages I and II	Primary tumor, N0 and M0
Stages IIIA, IIIB, IIIC and IIID	Primary tumor with locoregional metastase(s), M0
Stages IV	Distant metastases
<p>SLN: sentinel lymph node</p> <p>CNS: central nervous system</p>	

Laboratory & other workups

Dermoscopy is essential for the differentiation between melanoma and other skin tumours (atypical naevi, pigmented epithelial tumours, etc). Other useful methods for early non-invasive diagnosis are confocal reflectance microscopy or electric impedance spectroscopy and / or gen expression profiles.

Genetic profiling may be proposed to selected patients with familial or multiple primary melanoma.

According to type and histopathological grading blood tests and imaging procedures are essential: ultrasound, MRI, CT or PET-CT.

Metastatic melanoma can be associated with abnormalities in the blood test and elevated serum LDH (lactate dehydrogenases) is used in the staging of advanced melanoma (elevated LDH is associated with worse prognosis).

Dermatopathology

There are varying types of histopathologic patterns in all MM's. Highlight is an asymmetrical tumour growth with atypical melanocytes (clear cytoplasm, pleomorphic nuclei) growing in nests or singly, extending from the epidermal-dermal junction involving the upper layers of the epidermis, then invading the dermis or subcutaneous fat (thickness -Breslow depth- in mm). Early invasion of lymph vessels or capillaries is possible. Mitosis rate, immunohistochemistry and molecular diagnostic of mutation type status is for further examination necessary. Lesions must be classified according to TNM classification. Sentinel node biopsy is part of the staging of patients with invasive melanomas with risk factors to rule out the presence of micrometastasis in the lymph nodes.

Course

The clinical course is strongly associated with the tumor thickness (Breslow depth), which is the thickness between the stratum granulosum of the epidermis and the deepest melanoma cell in mm, and the presence of ulceration on histological examination. The 10 year survival is around 95% for thin melanomas (<1 mm) compared to 40-50% for thick melanomas (>4 mm). The main prognostic factors apart from the tumor thickness and ulceration are the presence of nodal and visceral involvement and are summarized in the AJCC TNM (tumor, node, metastasis) prognostic stage (I-IV).

Complications

About 90% of melanomas are diagnosed as primary tumors without any evidence of metastasis. The tumor specific 10-year-survival for such tumors is 75 to 95%. The 10-year-survival is 30 to 50% for patients with satellite and in-transit metastases, 69-75% for patients with lymph node micrometastases, and 40 to 60% for those with clinically apparent regional lymph node metastases. In patients with distant metastasis the prognosis is significantly reduced may vary depending of the number, size and localization of metastasis.

Diagnosis

The diagnosis is suspected clinically and confirmed by the histopathological examination of the whole skin lesion. The clinical diagnosis by the dermatologist is based on a combination of the following analyses of any skin tumour in the differential diagnosis of melanoma and prior to the excision:

- (1) Visual analysis (ABCDE or EFG rule)
- (2) Intra-individual comparative analysis with other pigmented lesions on patients skin
- (3) Chronologic analysis of changes (evolution)
- (4) A dermatoscopic evaluation of a skin tumour within the differential diagnosis of melanoma is mandatory prior to the excision. Clinical and dermatoscopic photos are highly recommended before the excision of the tumour for clinical pathological correlation and

final diagnosis. Reflectance confocal microscopy, when available, increases the accuracy of early non-invasive diagnosis.

In patients with risk factors and atypical mole syndrome the digital follow-up (Total body photography and digital dermatoscopy) are recommended to identify new and changing lesions that are indicative of early melanoma. After confirmation of the diagnosis, the staging may include blood test, ultrasonography of the regional lymph nodes, thoracic-abdominal-pelvic CT scan, brain CT scan or MRI and PET-TDM.

Prognostic is evaluated by AJCC pathological (pTNM) prognostic staging.

Differential Diagnosis

Differential diagnoses include melanocytic naevi of different types, pigmented skin carcinoma, seborrhoeic keratosis, dermatofibroma or vascular lesions among others.

Prevention & Therapy

The treatment of a suspected lesion is done by immediate excision under local anaesthesia. Usually in atypical nevi (intraepidermal dysplasia), a 0.5 cm safety margin is sufficient.

After histological confirmation and after having determined the Breslow thickness, an excision of the scar is performed with margins of 1 to 2 cm depending on the Breslow thickness.

A sentinel lymph node biopsy may be performed (if the Breslow is >0.8 mm). Adjuvant therapy is discussed in patients with a high risk of metastasis (stage IIB, IIC, III or IV after surgery) and may include targeted therapy (in cases with a V600 mutation of the oncogene BRAF) or immunotherapy. Therapy of systemic metastases includes: immunotherapy with checkpoint inhibitors (anti-PD1 and anti-CTLA-4), targeted therapy (BRAF and MEK inhibitors) if BRAF V600 mutation is present (around half of the cases), or a clinical trial. Radiotherapy is used only in selected cases, and chemotherapy is very poorly efficient and not generally indicated.

Follow-up: 5 years in intervals of 3-6 months with clinical examination and imaging, depending on risk group; looking for signs of recurrence and second primary melanomas, then life-long surveillance is recommended.

Prevention is based on the education of the patient: sun protection, self-skin screening (ABCDE criteria), and skin screening of at-risk patients via themselves and partner/parents, and digital photo assessment. Governmental skin cancer screening campaigns. Telemedicine is helpful.

Special

None.

References

- [Garbe C, Amaral T, Peris K et al \(2022\); European Dermatology Forum \(EDF\), the European Association of Dermato-Oncology \(EADO\), and the European Organization for Research and Treatment of Cancer \(EORTC\). European consensus-based interdisciplinary guideline for melanoma. Part 1: Diagnostics: Update 2022. Eur J Cancer. Jul;170:236-255. .](#)
- [Garbe C, Amaral T, Peris K et al \(2022\) European Dermatology Forum \(EDF\), the European Association of Dermato-Oncology \(EADO\), and the European Organization for Research and Treatment of Cancer \(EORTC\). European consensus-based interdisciplinary guideline for melanoma. Part 2: Treatment - Update 2022. Eur J Cancer. Jul;170:256-284.](#)
- [Atkins MB, Curiel-Lewandrowski C, Fisher DE et al\(2021\) Melanoma Research Foundation. The State of Melanoma: Emergent Challenges and Opportunities. Clin Cancer Res.; 27:2678-2697](#)

3.3.8 Kaposi's Sarcoma

Grading & Level of importance: CM. Bagot, Paris; G. Dobos, Paris; A. de Masson, Paris

ICD-11

2B57.1

Synonyms

(Sarcoma idiopathicum multiplex haemorrhagicum: old terminology).

Definition

Kaposi sarcoma is a multifocal neoplasm of spindle-shaped lymphatic-endothelium-derived cells infected with HHV-8 (human herpes virus 8).

Epidemiology

Kaposi sarcoma is a rare disease (<10 cases/1000 patients) but is more common in HHV8 endemic

areas (Mediterranean, African) and in immunocompromised subjects.

Aetiology & Pathogenesis

Kaposi's sarcoma is associated with HHV8 infection. Immunosuppression (solid organ transplant, HIV) is a well-known risk (and prognostic) factor. A genetic disposition may play a role as familial cases of Kaposi's sarcoma have been observed.

Signs & Symptoms

Characteristic findings include blue-red (purple) macules, plaques or tumours on the skin and mucosae. Lymphoedema is also common.

Localisation

Classic Kaposi's sarcoma typically begins as nodules of the legs and has a slow progression. In immunosuppressed patients disseminated macules are frequently found on the skin and mucous membranes, along with involvement of lymph nodes, gastrointestinal- or respiratory tract (lungs).

Classification

Kaposi sarcoma is classified into four types:

- Classic Kaposi's sarcoma, typically in older men in Southeastern Europe and the Mediterranean basin
- Endemic (African) Kaposi's sarcoma appears primarily in patients from sub-Saharan Africa
- HIV-associated (epidemic) Kaposi's sarcoma is frequently found in advanced stage of HIV infection in men who have sex with men (MSM)
- Kaposi's sarcoma in immunosuppressed patients (iatrogenic) may occur for example in solid organ transplant recipients.

Laboratory & other workups

HIV serology and standard blood tests must be performed in all cases. HHV8 viremia and CD4 T-cell count are performed in epidemic and iatrogenic forms.

Dermatopathology

Biopsy is mandatory for the diagnosis. It shows a proliferation of spindle-cells sometimes with mild to

moderate cytologic atypia, forming vascular and pseudovascular structures dissecting between collagen fibres, often mixed with a variable chronic inflammatory infiltrate. Kaposi sarcoma cells stain for endothelial cell markers such as CD34 and CD31. The identification and localisation of HHV8 within Kaposi lesional cells using a monoclonal antibody against HHV-8 latent nuclear antigen (LANA) is the most diagnostically helpful immunostaining technique available to differentiate Kaposi from its simulators because it is specific for Kaposi sarcoma.

Course

The clinical course depends on the type of the Kaposi sarcoma. Owing to its slow progression and indolent biologic behaviour, classic Kaposi sarcoma does not seem to impact the mortality rate.

Classic and endemic Kaposi sarcoma are rarely associated with nodal or visceral involvement. The HIV-associated and iatrogenic Kaposi sarcoma are more frequently associated with visceral involvement.

Complications

Untreated Kaposi sarcoma can show a local, slow progression. Lymphedema may occur. Visceral involvement (lung, esophagus, colon) may lead to bleeding or breathing difficulties.

Diagnosis

Diagnosis is obtained by clinical features, anamnesis, histology, and detection of HHV-8. A total body CT scan +/- lung and digestive endoscopies can be performed depending on the clinical form.

Differential Diagnosis

Clinical differential diagnoses include benign and malignant vascular tumours (angiosarcoma) bacillary angiomatosis, lymphomas, syphilis, pseudo-Kaposi's sarcoma (acroangiodermatitis).

Prevention & Therapy

Reduction of the immunosuppression is important in HIV-associated and iatrogenic Kaposi sarcoma: antiretroviral therapy is used as first-line in HIV-associated Kaposi sarcoma. In iatrogenic forms, the optimisation (decrease) of the immunosuppressive medication (and switch to mammalian Target Of Rapamycin (mTOR) inhibitors) must be considered. In classic Kaposi sarcoma, no treatment is needed in many cases. Surgery or laser may be used to destroy lesions. Radiotherapy, intralesional chemotherapy and electrochemotherapy have high response rates. Topical treatments— imiquimod or topical 9-cis-retinoid acid—can also be used. Systemic treatments are reserved for locally aggressive extensive and disseminated Kaposi sarcoma: the recommended first-line agents are pegylated

liposomal doxorubicin and paclitaxel. In classical Kaposi sarcoma pegylated liposomal doxorubicin or pegylated interferon-alfa are the recommended first-line agents in younger patients.

Special

Interdisciplinary approach in epidemic forms of disseminated Kaposi sarcoma.

References

- [Cesarman E, Damania B, Krown SE, Martin J, Bower M, Whitby D. Kaposi sarcoma. \(2019\) Nat Rev Dis Primers.;5:9.](#)
- [Etemad SA, Dewan AK. Kaposi Sarcoma Updates. \(2019\) Dermatol Clin.; 37:505-517.](#)

3.3.9 Dermatofibrosarcoma protuberans

Grading & Level of importance: C
H. Gollnick, Magdeburg; S. Hobelsberger, Dresden



ICD-11

2B53.Y

Synonyms

DFSP

Definition

Dermatofibrosarcoma protuberans (DFSP) is a rare usually non metastizing mesenchymal malignant tumor with an undermining-infiltrative, aggressive growth pattern and high local recurrence rate.

Epidemiology

Rare tumor, but on the skin the most frequent sarcoma type, pan-ethnic, 1:100,000/ year. male: female ratio 1:1.5, mean age around 40 years. Children mostly not affected.

Aetiology & Pathogenesis

The cause of DFSP is unknown, but a traumatic initiation is discussed. Trauma has been reported in

about 10-20% of cases. In 90 % of cases, a translocation of genetic material 17q22; 22q13 with fusion of genes COL1A1 and PDGF β has been detected. The gene product, a **COL1A1-PDGF β - fusion protein**, binds to a constitutive expressed PDGF-receptor acting thereafter as an autocrine growth stimulus for DFSP-cells. It usually does not metastasize (< 1%), however, it grows horizontally in the surrounding tissue in a highly aggressive manner, therefore it is classified as G2.

Signs & Symptoms

DFSP arises from deeper layers of the dermis. Typically, at the beginning no subjective symptoms are reported. DFSP appears solitary and starts starts as a small, firm skin coloured patch and may turn into purplish, reddish, or flesh-colored and is usually without clear margins. A rare variant is pigmented. The tumor grows slowly and infiltrates horizontally and polycyclically but later becomes a plaque and /or classical big dermal nodule. At late stages it can ulcerate.

Localisation

It is commonly found on the trunk, usually in the shoulder and chest area.

Classification

- Dermatofibrosarcoma protuberans, classical type.
- Bednar- tumor, pigmented type.
- Myxoid type.
- Pleomorphic –storiform type.

Laboratory & other workups

None specific.

Dermatopathology

Biopsy is essential to diagnose the tumor. For the diagnosis one needs a representative ellipse biopsy, a punch biopsy is usually less helpful. By low power magnification one can see the whole dermis infiltrating mesenchymal tumor composed of bundles of spindle cells. A fascicular and radial growth produces the typical cartwheel pattern. Infiltration of the subcutis produces a honeycomb pattern with large bundles of tumor cells surrounding the adipose cells. By immunohistochemistry, the tumor cells express the CD 34 antigen plus tenascin, COL1A1.

Course

A regular follow-up is essential after tumor removal to monitor for recurrence. Local relapses appear in 10-20% of DFSP's, usually within three years of the initial surgery. Despite being locally aggressive, the tumor spreads to other parts of the body (metastasizes) in only 5% of cases.

Complications

Infiltration with joint involvement, exulceration. Scarring.

Diagnosis

Diagnosis relies on clinical features and dermatopathology.

Differential Diagnosis

- Nodular basal cell carcinoma.
- Dermatofibroma including giant type.
- Keloid.
- Pleomorphic sarcomas, nodular B-cell lymphoma, pigmented or non-pigmented malignant melanoma (spindle cell type).

Prevention & Therapy

Treatment depends on size and localization. Typically, it is treated with complete wide surgical excision of > 3 cm (lowest recurrence rate of 7%); Mohs surgery or 24 hrs dermpath finding is performed dependent on localisation.

The chemotherapeutic agent imatinib mesylate is approved for adults with unresectable, recurrent, or metastatic dermatofibrosarcoma protuberans.

Special

None.

References

- [Hao X, Billings SD, Wu F, Stultz TW, Procop GW, Mirkin G, Vidimos AT. Dermatofibrosarcoma Protuberans: Update on the Diagnosis and Treatment. J Clin Med. 2020 Jun 5;9\(6\):1752. doi: 10.3390/jcm9061752. PMID: 32516921; PMCID: PMC7355835.](#)

- [Ramirez-Fort MK, Meier-Schiesser B, Niaz MJ, Niaz MO, Feily A, Fort M, Lange CS, Caba D. Dermatofibrosarcoma Protuberans: The Current State of Multidisciplinary Management. Skinmed. 2020 Oct 1;18\(5\):288-293. PMID: 33160438.](#)

3.3.10 Cutaneous Metastases

Grading & Level of importance: C



H. Gollnick, Magdeburg

ICD-11

2E08

Synonyms

Skin metastases; skin secondaries.

Definition

Cutaneous spread of cells of malignant tumours of internal organs or of the hematological system, direct penetrating or via blood vessels, perineural sheath or lymphatics.

Epidemiology

Prevalence is around 2%, incidence varying from 8 - 10%. In up to 10%, skin manifestation is the first visceral tumor sign or leads to source of origin via histological examination. Most common sources: breast, colon and lung carcinomas as well as leukemias followed by ovarian, head & neck and throat, renal cell - and gastrointestinal carcinoma.

Aetiology & Pathogenesis

There is no clear pathomechanism behind why metastases localise to the skin except by direct penetration. Some homing factors can play a role in leukemia dissemination. Sometimes skin metastases are found in a post-zoster area.

Signs & Symptoms

Solitary or multiple, firm blue-red to yellow papules and nodules in various levels of the skin with rapid growth and a short history. Appearing as single lesion or aggregated, zosteriform or disseminated.

Sometimes erysipela-like pattern or lymphangiosis-like (cancer en cuirasse) in mammary carcinoma.

Localisation

Allocation of the localisation of a skin metastasis with regard to the original tumour is not possible. Exceptions are penetrating tumors to skin from bone, muscle, fascia or joint. Mammary carcinomas are often thoracal, prostate suprapubic. Sister Mary Joseph's nodules located at the umbilicum derive from the ovarian and gastro-intestinal origin. Oesophageal, gastric and colonic cancers, biliary tract, pulmonary and renal carcinomas prefer hairy scalp, neck and face.

Classification

No clear classification of cutaneous metastases of visceral tumours but grouping them into nodular, inflammatory, fibrotic and sclerodermic-like types is widely accepted.

Laboratory & other workups

First action is a biopsy or complete resection for histopathological evaluation. Often immunohistochemistry or modern molecular cell differentiation is indicated. Thereafter, tumor screening with different methods (i.e. serum, different imaging techniques) follow.

Dermatopathology

Depends on origin of cell and tumor. Mostly needs immunohistochemistry and molecular typing.

Course

Often metastases appear in free tumor interval. Survival after detection of metastases in most cases less than 1 year.

Complications

Depending on the type of primary tumor, stage, pretreatment and available resources of modern surgical, radiologic or chemotherapeutic / biologic / targeted cancer treatment. Some metastases melt, become necrotic or bleed or become superinfected.

Diagnosis

Whenever an unknown lesion in the skin appears slowly or rapidly and when it cannot be classified to the spectrum of benign or malignant tumors of the skin or certain dermatoses.

Differential Diagnosis

Primary skin tumours and primary cutaneous lymphomas.

Prevention & Therapy

There is no prevention. Biopsy or excision for diagnosis is a first step to lead to decision algorithms of therapy according to the individual tumor.

Special

Interdisciplinary approach and tumor boards to be involved.

References

- [Jaros J, Hunt S, Mose E, Lai O, Tsoukas M. Cutaneous metastases: A great imitator. Clin Dermatol. 2020 Mar-Apr;38\(2\):216-222. doi: 10.1016/j.clindermatol.2019.10.004. Epub 2019 Oct 25. PMID: 32513401.](#)

3.3.11 Parapsoriasis-Group

Grading & Level of importance: C
G. Burg, Zürich; P. Ortiz-Romero, Madrid



ICD-11

LP4

Small Plaque Parapsoriasis (SPP) LP19

Large Plaque Parapsoriasis (LPP) LP40

Poikiloderma atrophicans vasculare (PVA) LP41

Synonyms

Xanthoerythroderma perstans

Digitate dermatosis

Atrophic parapsoriasis

Poikilodermatous parapsoriasis

Definition

Parapsoriasis is a group of diseases characterized by the presence of scaling macules or patches that can resemble light psoriatic lesions. Its importance comes from the fact that some cases can represent (or transform into) cutaneous T-cell lymphomas.

Epidemiology

Rare. Second half of life (>50 years).

Aetiology & Pathogenesis

Unknown.

Signs & Symptoms

SPP: Small red-brown, indolent (no itch), slightly scaling macules (1-2 cm), following the splitskin lines.

LPP: large geographic irregular but sharply demarcated, slightly scaling macules or plaques; no itch.

PAV: Mottled slightly (pityriasiform) scaling erythematous patches.

Localisation

SPP: predominantly trunk; skin split lines

LPP: predominantly trunk and upper extremities

PAV: trunk or total skin

Classification

Small Plaque Parapsoriasis: usually no evolution into CTCL.

Large Plaque Parapsoriasis: potential precursor of CTCL (mycosis fungoides). Poikiloderma atrophicans

vasculare: potential precursor of CTCL (mycosis fungoides).

Laboratory & other workups

No special; biopsy.

Dermatopathology

Subtle eczematous changes of the epidermis with a few lymphocytes in the dermis and the epidermis.

No band like infiltrate in the papillary dermis. No lymphocyte microabscesses in the epidermis. Atrophy

of the epidermis and poikiloderma (hyper- and depigmentation) in PAV.

Course

Chronic over years or decades. Follow-up mandatory because of potential development of mycosis fungoides. Multiple biopsies should be taken during the course of the disease.

Complications

LPP and PAV may develop to CTCL, preferentially mycosis fungoides (years or decades). Some cases represent patients that are in fact mycosis fungoides but we do not have enough clinical-pathologic-molecular criteria to confirm the diagnosis of lymphoma.

Diagnosis

Clinical picture, histopathology and course.

Differential Diagnosis

Atopic or seborrheic eczema, CTCL subtypes in particular mycosis fungoides, tinea corporis, pityriasis versicolor, pityriasis rosea.

Prevention & Therapy

Prevention not possible. Topical therapy: photo-(helio-) or photochemotherapy. Glucocorticosteroid-cream temporarily. Topical calcineurin inhibitors.

References

- [Kossard S. \(2023\). Critical Review-A Tribute to Louis Brocq Lymphomatoid Papulosis, the Key in Exploring the Relationship of Parapsoriasis and Mycosis Fungoides. Am J Dermatopathol. Nov 1;45\(11\):753-761. doi: 10.1097/DAD.0000000000002546. Epub 2023 Sep 27. PMID: 37782018](#)
- [Chairatchaneeboon M, Thanomkitti K, Kim EJ. \(2022\). Parapsoriasis - A Diagnosis with an Identity Crisis: A Narrative Review. Dermatol Ther \(Heidelb\). May;12\(5\):1091-1102. doi: 10.1007/s13555-022-00716-y. Epub 2022 Apr 15. PMID: 35426607](#)
- [Balan R, Grigoraş A, Popovici D, Amălinei C. \(2021\). The histopathological landscape of the major psoriasiform dermatoses. Arch Clin Cases. Oct 27;6\(3\):59-68. doi: 10.22551/2019.24.0603.10155. PMID: 34754910; PMCID: PMC8565680.](#)

- [Burg G, Dummer R, Haeffner A, Kempf W, Kadin M. \(2001\). From inflammation to neoplasia: mycosis fungoides evolves from reactive inflammatory conditions \(lymphoid infiltrates\) transforming into neoplastic plaques and tumors. Arch Dermatol. Jul;137\(7\):949-52. PMID: 11453817.](#)
- [Burg, G., Dummer, R., Nestle, F. O., Doebbeling, U., & Haeffner, A. \(1996\). Cutaneous lymphomas consist of a spectrum of nosologically different entities including mycosis fungoides and small plaque parapsoriasis. Arch Dermatol, 132\(5\), 567-572.](#)
- [Burg, G., & Dummer, R. \(1995\). Small plaque \(digitate\) parapsoriasis is an 'abortive cutaneous T-cell lymphoma' and is not mycosis fungoides. Arch Dermatol, 131\(3\), 336-338.](#)

3.3.12 Cutaneous Lymphomas

Grading & Level of importance: C

M. Bagot, Paris; G. Dobos, Paris; A. de Masson, Paris; P. Ortiz-Romero, Madrid



ICD-11

Code: nil (group of diseases).

Synonyms

Cutaneous T-cell lymphomas (CTCL), cutaneous B-cell lymphomas (CBCL).

Definition

Cutaneous lymphomas are a heterogeneous group of non-Hodgkin lymphomas that primarily involve the skin. They can be classified into primary cutaneous lymphomas (only affecting the skin) and secondary cutaneous lymphomas (with systemic involvement).

Epidemiology

Cutaneous lymphomas are officially listed as rare diseases. The age adjusted incidence of CTCL is 6.4 per 1,000,000 persons and this incidence rate is highest between the ages of 70-79 years of age. The incidence rate of CBCL is reported to be approximately 3 per 1,000,000 persons.

Aetiology & Pathogenesis

The aetiology of cutaneous lymphomas is not known in most cases. Older age is a risk factor. Some cutaneous lymphomas have been associated with a viral infection (HTLV-1 for adult T-cell lymphoma/

leukemia, EBV for EBV-associated lymphoproliferative diseases). Typical mutations of mycosis fungoides have the fingerprint of ultraviolet irradiation.

Pathophysiology could also involve lymphoproliferation related to antigen persistence and secondary occurrence of mutations leading to more aggressive clones.

Signs & Symptoms

Symptoms of primary cutaneous lymphomas vary depending on the subtype.

Erythematous, hypopigmented or poikilodermic macules or patches with mild scaling can be found in mycosis fungoides (the most frequent CTCL). 70-80% of patients remain at this indolent stage. 20-30% of patients evolve towards a more aggressive stage with development of nodules or tumors or develop extracutaneous progression (leukemic, lymph node or visceral involvement). Erythroderma is present in erythrodermic mycosis fungoides and Sézary syndrome, a rare form of CTCL characterized by the presence of circulating malignant blood T-cells. Patients often develop ectropion, alopecia and palmoplantar keratoderma. Pruritus is a common symptom. Enlarged adenopathies are frequent.

B-cell lymphomas characteristically appear with dome-shaped bluish-red papules and nodules, which may become large aggregates. Follicular B-cell lymphoma realize infiltrated plaques and tumor, usually non ulcerating. Marginal zone lymphoproliferative disease more often presents as usually non ulcerating nodules and predominate on members. Primary cutaneous B cell lymphoma leg type realize tumors and infiltrated plaques, which are often ulcerated.

Localisation

Cutaneous lymphomas can appear anywhere on the body, localisation may depend on the subtype of lymphoma. Early lesions of mycosis fungoides are frequently found on sun—protected areas. Follicular B-cell lymphoma predominate on scalp and trunk. Marginal zone lymphoma predominates on the members. Primary cutaneous B cell lymphoma leg type are located mainly on legs and buttocks.

Classification

Primary cutaneous lymphomas are classified by the WHO-EORTC classification system. The classification relies on clinical and histological features and is obtained by clinico-pathological correlation.

- Cutaneous T-cell lymphomas account for approximately 75% of the cases. Mycosis fungoides and its variants represent 50% of CTCL. The group of CD30 lymphoproliferative disorders represents 30% of CTCL cases. This group comprises lymphomatoid papulosis and anaplastic large cell lymphoma. The remaining cases are various rare types of CTCL.

- 25% of primary cutaneous lymphoma are CBCL, comprising primary cutaneous follicular lymphoma, primary cutaneous marginal zone lymphoproliferative disease, and primary cutaneous large B cell lymphoma, leg-type.

Laboratory & other workups

Laboratory tests can be useful for the diagnosis. Serologic testing for lymphotropic viruses (HIV, EBV, HTLV-1) should be considered depending on the clinical form. In advanced cases of CTCL or in case of erythroderma, flow cytometry (CD3, CD4, CD8, loss of CD26 and CD7) should be used. LDH is a useful reflect of tumor mass. A T or B-cell clonal pattern can be identified in skin +/- blood by PCR tests or high throughput sequencing. Staging should be precised according to the TNMB (Tumor nodes metastasis blood) classification in mycosis fungoides or Sézary syndrome and according to TNM classification in the rest of primary cutaneous lymphomas. CT scan (or PET-CT) can be recommended to study extracutaneous dissemination.

Dermatopathology

Cutaneous lymphomas are a proliferation of lymphocytes with variable size, atypia, architecture, and immunophenotype, depending on the subtype.

Histological features of mycosis fungoides, the most frequent form, include a dense infiltrate of small to medium mononuclear cerebriform cells with mild to moderate atypia in the upper dermis with epidermotropism (spread of lymphocytes into the epidermis), without spongiosis, typically at the dermo-epidermal junction with an "indian file" lining up of the lymphocytes or forming Pautrier's microabscesses (intraepidermal collections of primarily atypical lymphocytes). Sézary cells (atypical lymphocytes with cerebriform nuclei) can be found in the skin or in the peripheral blood (by cytomorphological examination of the peripheral blood smear) of patients with Sézary syndrome. Immunohistochemistry is used to describe the cell of origin and the histological subtype.

The group of CD30 lymphoproliferative disorders is characterized by the expression of CD30 by tumor T-cells.

CBCL express CD20. In primary cutaneous large B cell lymphoma, immunochemistry with bcl-2, bcl-6, MUM and search for MyD88 mutation are mandatory to differentiate indolent lymphoma from aggressive lymphoma.

Course

Prognosis of primary cutaneous lymphomas depends on the subtype and stage and is generally considered better than primary nodal lymphomas. The majority of mycosis fungoides cases are early stage and have an indolent evolution. Advanced stage mycosis fungoides have a worse prognosis.

CD30 lymphoproliferative disorders have a good prognosis.

As concerns CBCL, follicular B cell lymphoma and marginal zone B cell lymphoma have an indolent evolution, whereas large B cell lymphoma, leg type have a more aggressive evolution.

Complications

Many cutaneous lymphomas have an indolent evolution. Erythroderma types are accompanied with severe pruritus and often loss of protein and trace elements via desquamation as well as risk of hypo- or hyperthermia due to inadequate temperature control. Patients with cardiac insufficiency can have aggravation of the problem because maintaining the skin red requires a very important increase of the cardiac output. Large nodular aggregates at groin or axillar region can stop lymph drainage. In case of advanced-stage or aggressive form, immunosuppression (primary, and secondary to the treatments) combined with the presence of ulcerated lesions or the erythroderma (erythrodermic skin is not able to stop the bacteria to cross and increases the risk of sepsis. Lymphoma progression (nodal involvement, visceral or peripheral blood involvement at leukemic level) may occur.

Diagnosis

The precise diagnosis of cutaneous lymphomas is always obtained by clinical-histological correlation.

Differential Diagnosis

Differential diagnoses include in patch stage: contact dermatitis, atopic dermatitis, psoriasis, parapsoriasis, dermatomycoses, pseudolymphomas. In tumour stage CTCL or CBCL: other primary or secondary lymphomas or other tumours. In erythrodermic patients, with psoriasis, drug reactions, pityriasis rubra pilaris or eczema.

Prevention & Therapy

The treatment should be adjusted to the subtype (indolent or aggressive) and stage (early or advanced).

Skin directed treatments are used in early-stage mycosis fungoides, they include topical corticosteroids, phototherapy (narrow band UVB or PUVA), and topical chlormethin. Radiation therapy (localized or full skin irradiation with electrons (Total Skin Electron Beam) can be used in advanced cases. Systemic treatments include methotrexate, bexarotene, pegylated interferon. In more advanced cases, HDAC (histone deacetylase) inhibitors, immunotherapies (e.g., anti-CD30, anti-CCR4) or chemotherapy are used. Photopheresis are used in erythrodermic mycosis fungoides. Allogeneic stem cell transplantation is considered in aggressive cases.

Indolent B-cell lymphomas may be treated by surgical excision, radiation therapy, topical steroids, or rituximab (anti-CD20 antibody) in disseminated cases. Aggressive B-cell lymphomas usually require

rituximab and polychemotherapy.

Special

Early aggressive treatment modalities must be avoided, unless systemic involvement has been documented (blood, lymph nodes, internal organs).

References

- [Dobos G, Miladi M, Michel L, Ram-Wolff C, Battistella M, Bagot M, de Masson A. \(2022\). Recent advances on cutaneous lymphoma epidemiology. Presse Med.Mar;51\(1\):104108.](#)
- [Olsen EA, Whittaker S, Willemze R, Pinter-Brown L, Foss F, Geskin L, Schwartz L, Horwitz S, Guitart J, Zic J, Kim YH, Wood GS, Duvic M, Ai W, Girardi M, Gru A, Guenova E, Hodak E, Hoppe R, Kempf W, Kim E, Lechowicz MJ, Ortiz-Romero P, Papadavid E, Quaglino P, Pittelkow M, Prince HM, Sanches JA, Sugaya M, Vermeer M, Zain J, Knobler R, Stadler R, Bagot M, Scarisbrick J. \(2022\). Primary cutaneous lymphoma: recommendations for clinical trial design and staging update from the ISCL, USCLC, and EORTC. Blood.Aug 4;140\(5\):419-437.](#)
- [A, Klager S, Hatch L, Sarriera-Lazaro C, Chen PL, Seminario-Vidal L. \(2022\). Update in Diagnosis and Management of Primary Cutaneous B-Cell Lymphomas. Am J Clin Dermatol. Sep;23\(5\):689-706.](#)
- [Willemze R, Cerroni L, Kempf W, Berti E, Facchetti F, Swerdlow SH, Jaffe ES. \(2019\). The 2018 update of the WHO-EORTC classification for primary cutaneous lymphomas. Blood. Apr 18;133\(16\):1703-1714. doi: 10.1182/blood-2018-11-881268. Epub 2019 Jan 11.PMID: 30635287](#)
- [Whittaker S, Hoppe R, Prince HM. \(2016\). How I treat mycosis fungoides and Sézary syndrome. Blood. Jun 23;127\(25\):3142-53.](#)
- [Swerdlow SH, Quintanilla-Martinez L, Willemze R, Kinney MC. \(2013\). Cutaneous B-cell lymphoproliferative disorders: report of the 2011 Society for Hematopathology/European Association for Haematopathology workshop. Am J Clin Pathol. 2013 Apr;139\(4\):515-35. doi: 10.1309/AJCPNLC9NC9WTQYY.PMID: 23525619](#)
- [Senff NJ, Noordijk EM, Kim YH, Bagot M, Berti E, Cerroni L, Dummer R, Duvic M, Hoppe RT, Pimpinelli N, Rosen ST, Vermeer MH, Whittaker S, Willemze R \(2008\) European Organization for Research and Treatment of Cancer and International Society of Cutaneous Lymphoma consensus recommendations for the management of cutaneous B-cell lymphomas. European Organization for Research and Treatment of Cancer; International Society for Cutaneous Lymphoma. Blood. Sep 1;112\(5\):1600-9. doi: 10.1182/blood-2008-04-152850. Epub 2008 Jun 20. PMID: 18567836](#)

3.3.13 Lymphomatoide Papulose

Grading & Level of importance: C
G. Burg, Zürich; P. Ortiz-Romero, Madrid



ICD-11

LP4; LP44

Synonyms

None.

Epidemiology

Prevalence 0.1-0.2 /100'000; all age groups; predominantly young adults; M>F.

Definition

Chronic recurrent, self-healing papulo-nodular skin eruption with histologic features of a malignant anaplastic lymphoma; CD30 (Ki-1) positive. Is part of the spectrum of primary cutaneous CD30+ T-cell lymphoproliferative diseases.

Nosologic relationship to Pityriasis lichenoides et varioliformis acuta (PLEVA), to other CD30 positive malignant T-cell lymphomas, like anaplastic large cell lymphoma (ALCL), and to Hodgkin's disease.

Aetiology & Pathogenesis

Unknown.

Signs & Symptoms

Disseminated papules and/or small nodules, which within days or a few weeks become red-brown, hemorrhagic or pustular and finally undergo ulceration, followed by complete spontaneous regression of the lesion, occasionally leaving behind hyper- or hypopigmented varioliform scars.

Localisation

Trunk, buttocks, extremities.

Classification

Histological and immunocytochemical subtypes, depending on the shape of and number of atypical CD30 positive cells within the lymphoid infiltrate: Types A-E and Type 6p25.3 (genetic). Different histopathologic or molecular subtypes can mimic different aggressive lymphomas. Correct diagnosis is crucial to avoid unnecessary aggressive multi agent chemotherapy or even bone marrow transplantation.

Laboratory & other workups

Biopsy; immunocytochemistry (CD30).

Dermatopathology

Broad spectrum with variably dense infiltrates of medium-sized to large atypical pleomorphic CD30+ cells are the hallmarks of the disease. Depending on the lesion's stage of evolution, the histological presentation is different. In fresh lesions, there is a wedge-shaped infiltrate of tumor cells with ulceration.

Types A and C mimic histopathologically (or can be impossible to differentiate) CD30+ anaplastic large cell lymphoma. Type B mimics mycosis fungoides. Types D and E mimic aggressive epidermotropic CD8+ or nasal type T/NK primary cutaneous lymphomas respectively.

Course

Chronic recurrent over decades.

Complications

Between 10-20% of cases are associated (pre, post or at the same time of diagnosis) to mycosis fungoides or Hodgkin's disease.

Threat of overtreatment due to confusion with malignant anaplastic lymphoma.

Diagnosis

Clinically; typical spontaneous regressions and recurrences of lesions.

Differential diagnosis

Malignant anaplastic T-cell lymphoma (CD30 positive anaplastic large cell lymphoma (ALCL)); CD30-positive pseudolymphomatous reactions (scabies); Hodgkin's disease (histology).

Prevention & Therapy

Prevention not possible. The prognosis is quo ad vitam excellent; permanent healing not possible, only temporizing clearing. Watch and wait is acceptable. No treatment has demonstrated to cure LyP. No treatment has shown to reduce the risk of development of mycosis fungoides or Hodgkin's disease. Follow up with respect to possible transformation to Hodgkin's disease (very rare) or mycosis fungoides.

Temporal clearing: Methotrexate (10-20 mg/week); photo- or photochemotherapy.

Skin care and prevention of superinfection; erosive lesions may be treated with antibiotic weak glucocorticosteroid creme.

Special

It is important to avoid aggressive systemic (cytostatics, bone marrow transplantation) therapy, based on misdiagnosis.

References

- [Kossard S. \(2023\) Critical Review-A Tribute to Louis Brocq Lymphomatoid Papulosis, the Key in Exploring the Relationship of Parapsoriasis and Mycosis Fungoides. Am J Dermatopathol. Nov 1;45\(11\):753-761. doi: 10.1097/DAD.0000000000002546. Epub 2023 Sep 27. PMID: 37782018; PMCID: PMC10581442.](#)
- [Nowicka D, Mertowska P, Mertowski S, Hymos A, Forma A, Michalski A, Morawska I, Hrynkiewicz R, Niedźwiedzka-Rystwej P, Grywalska E. \(2022\). Etiopathogenesis, Diagnosis, and Treatment Strategies for Lymphomatoid Papulosis with Particular Emphasis on the Role of the Immune System. Cells. Nov 21;11\(22\):3697. doi: 10.3390/cells11223697. PMID: 36429125; PMCID: PMC9688547.](#)
- [Martinez-Cabriaes, S. A., Walsh, S., Sade, S., & Shear, N. H. \(2020\). Lymphomatoid papulosis: an update and review. J Eur Acad Dermatol Venereol, 34\(1\), 59-73.](#)
- [Di Raimondo C, Parekh V, Song JY, Rosen ST, Querfeld C, Zain J, Martinez XU, Abdulla FR \(2020\) Primary Cutaneous CD30+ Lymphoproliferative Disorders: a Comprehensive Review. Curr Hematol Malig Rep. Aug;15\(4\):333-342. doi: 10.1007/s11899-020-00583-4. PMID: 32435988](#)
- [Wagner G, Rose C, Klapper W, Sachse MM \(2020\) Lymphomatoid papulosis. J Dtsch Dermatol Ges. Mar;18\(3\):199-205. doi: 10.1111/ddg.14041. Epub 2020 Feb 26. PMID: 32100965](#)
- [Kempf W, Zimmermann AK, Mitteldorf C. \(2019\). Cutaneous lymphomas-An update 2019. Hematol Oncol. Jun;37 Suppl 1:43-47. Doi: 10.1002/hon.2584. PMID: 31187534.](#)

3.3.14 Pseudolymphomas

Grading & Level of importance: B.



E.Gaffal, Magdeburg; H. Gollnick, Magdeburg ; P. Ortiz-Romero, Madrid

ICD-11

EH6Y

Synonyms

Lymphocytic infiltration, reactive lymphoid hyperplasia.

Definition

Reactive pseudolymphomatous infiltrate of B-, T-, and combined T/B-cell type that mimic clinically and/or histopathologically malignant lymphomas.

Epidemiology

Epidemiological data for *Borrelia lymphocytoma* are known for about 2% (see chapter 2.2.9) for other subtypes is lacking.

Aetiology & Pathogenesis

In pseudolymphoma B - and T-lymphocytes and other inflammatory cells accumulate in the dermis and subcutis as a reaction to stimuli of different origin. Often a causative agent is missing. Cutaneous pseudolymphoma with known etiology include reactions to tattoo dyes, arthropods, medications, allergens, viral or bacterial infections (molluscum contagiosum, herpes, HIV, syphilis...) or vaccinations. A subset of pseudolymphoma is the result of an unusual systemic mixed T- and B- cell response to several drug classes.

UV light can produce a T-cell dominated actinic reticuloid and persistent contact allergens (nickel or para-phenylenediamine).

A specific subset of B- cell type pseudolymphoma, *Borrelia lymphocytoma* (see 2.2.9), primarily occurs in Europe in areas endemic for the tick *Ixodes ricinus*. Borrelial lymphocytoma is a tick bite response to infection by *Borrelia burgdorferi* subsp *afzelius* and *garinii*. Causative agents: *Borrelia garinii* and *Borrelia afzelii* (both in Europe), not *Borrelia burgdorferi sensu strictu*.

Signs & Symptoms

Different forms: localized erythematous macules sometimes confluent, solitary or multiple nodules, plaques. Occasionally disseminated; rarely with lymphadenopathy.

In Borrelia lymphocytoma lesions are often indolent soft blue-red nodules up to 5 cm. Post scabies lymphocytomas are localized or often disseminated. T-cell pseudolymphomas occur with localized plaques, nodules and disseminated papules or annular pattern. An erythroderma may also be seen. Some lesions may be also severely itchy. Red-blue lupoid infiltrate (diascopy).

Localisation

Sites of predilection: in Borrelia lymphocytoma the sites of predilection are: loose skin (ear, nipple, scrotum); red-blue lupoid infiltrate (diascopy). Other T- or B-/T- pseudolymphomas may be localized (facial), single or multiple all over the body incl. erythrodermas.

Classification

No international classification as compared with malignant cutaneous lymphomas. B -, T- and B-/T-cell dominated subtypes.

Laboratory & other workups

Borrelia IgG and IgM titers raised in Borrelia lymphocytoma. In actinic reticuloid UV light provocation test. In lymphocytic infiltration immunoserology to exclude lupus erythematosus and blood count for leukemic infiltrate. Repeated biopsies with B or T-cell genetic rearrangement studies can help (but many benign conditions present monoclonal populations of lymphocytes, careful clinical-pathologic and molecular correlation is required).

No specific other tests.

Dermatopathology

Most important to differentiate the subtypes of pseudolymphomas and to exclude malignant B-or T-cell infiltrates from skin or systemic lymphomas.

Course

Depends on subtype. In Borrelia lymphocytoma after adequate 2nd stage oral doxycycline over 3 weeks slowly fading of lesion(s).

Cessation of drugs leads to resolution after weeks or months.

Complications

None.

Diagnosis

Clinical features, serology, histology, PCR.

Differential Diagnosis

Each primary cutaneous lymphoma can have a mimicker. Clinical appearance will be similar to the mimicked lymphoma.

- Malignant B- / T- cell lymphomas
- Disseminated cutaneous sarcoidosis
- Stage II syphilis

Prevention & Therapy

Depending on subtype.

Antibiotics (doxycycline 100 mg b.i.d. for 21 days) in Borrelia lymphocytoma.

Cessation of responsible drugs. Topical mid and high potency corticosteroids. Occasionally oral steroidpulse.

Special

None.

References

- [Diana Miguel , Melanie Peckruhn, Peter Elsner \(2018\) Treatment of Cutaneous Pseudolymphoma:A Systematic Review. Acta Derm Venereol. 13;98\(3\):310-317](#)
- [Christina Mitteldorf, Werner Kempf \(2020\) Cutaneous pseudolymphoma—A review on the spectrum and a proposal for a new classification J Cut Path 47, 1 :76-97](#)

3.3.15 Paraneoplastic Disorders

Grading & Level of importance: C
H. Gollnick, Magdeburg; P. Ortiz-Romero, Madrid



ICD-11

EL10

Synonyms

Cutaneous markers of internal malignancy.

Definition

Paraneoplastic disorders are defined as cutaneous markers for underlying malignancies (not including metastases) with manifestation on the skin. It is a parallel course for tumour or blood diseases and skin findings followed by improvement when the neoplastic proliferation is surgically removed or treated by drugs or radiotherapy and is worsening with recurrence or progression.

Epidemiology

No clear data in general, however, prevalence of association of skin signs with most of the individual neoplasm exist.

Aetiology & Pathogenesis

- No deletion of this sentence Paraneoplastic syndromes which occur as a result of circulating factor(s) or presumed factors produced by the underlying cancer
- Factors related to neoplastic disorders are: immune reaction and production of tumor-associated antibodies from tumor or lymphoma cells or T-cells or certain cytokines, enzymes, embryonic or fetal or other growth factors/proteins. Hormones or hormone precursors including several altered metabolic pathways.

Signs & Symptoms

The clinical symptoms are very different and are depending on the underlying disease producing several clinical patterns involving all skin structures including adnexes, the musculoskeletal system and nerves or vessels.

Localisation

The localization may be localized or generalized, but is mostly symmetrical because of circulating factors.

Classification

- Obligate paraneoplastic disorders/syndromes (almost 100% tumour-associated): Necrolytic migratory erythema (glucagonoma syndrome), acrokeratosis paraneoplastica of Bazex, acanthosis nigricans malignas, paraneoplastic pemphigus, erythema gyratum repens, hypertrichosis lanuginosa acquisita.
- Stands as it is no deletion Facultative paraneoplastic disorders (less reliable markers, but still deserve investigation): Ichthyosis acquisita, thrombophlebitis migrans, dermatomyositis in adults, bullous pemphigoid, Sweet's syndrome, paraneoplastic pruritus, endocrine flushing (carcinoid).

Laboratory & other workups

The laboratory work up depends on the suspected tumor which includes skin biopsies, immunofluorescence /-histochemistry, immunoblotting, molecular tumor pattern and tumor markers. It is essential to assess blood markers of hematological diseases. Occult blood on stools. Image tests also depends on the suspected tumor.

Dermatopathology

It depends on skin signs, but commonly similar microscopic features to the disease itself are seen, because the paraneoplastic one is mimicking it. Some are specific: dermatomyositis where one finds T-cell infiltration into skin muscles or changes of the epidermis and adnexal structures in correlation with the clinic as in genodermatoses-related neoplasias.

Course

It is very much depending on the type of a paraneoplastic disorder. Removal of the tumor or remission of a hematologic disorder can lead to complete resolution of symptoms.

Complications

Depending on underlying neoplasm.

Diagnosis

Often to be made by clinical picture and case history and laboratory and imaging techniques/procedures. Clinical experience is necessary.

Differential Diagnosis

The clinical picture resembles the picture of a skin disorder, therefore, a great variety has to be excluded.

Prevention & Therapy

No prevention possible despite early detection by regular tumor prevention programs. Family members of some syndromes with a genetic background need to be checked regularly.

The therapy depends on underlying tumor / hematological disease.

Special

Because of orphan status of paraneoplastic skin disorders, a dermatologic examination is always necessary with interdisciplinary work up.

References

- [Murina A, Allen A. \(2024\) Paraneoplastic Dermatoses and Cutaneous Metastases. Clin Geriatr Med. Feb;40\(1\):177-195. doi: 10.1016/j.cger.2023.09.005. Epub 2023 Oct 13. PMID: 38000859](#)
- [Souza PK, Amorim RO, Sousa LS, Batista MD \(2023\) Dermatological manifestations of hematologic neoplasms. Part II: nonspecific skin lesions/paraneoplastic diseases. An Bras Dermatol. Mar-Apr;98\(2\):141-158. doi: 10.1016/j.abd.2022.08.005. Epub 2023 Jan 20. PMID: 36682966](#)
- [Souza PK, Amorim RO, Sousa LS, Batista MD \(2023\) Dermatological manifestations of hematologic neoplasms. Part I: secondary specific skin lesions. An Bras Dermatol. Jan-Feb;98\(1\):5-12. doi: 10.1016/j.abd.2022.06.002. Epub 2022 Nov 4. PMID: 36344350](#)
- [Didona D, Fania L, Eming R, Hertl M & Di Zenzo G \(2020\) Paraneoplastic Dermatoses: A Brief General Review and an Extensive Analysis of Paraneoplastic Pemphigus and Paraneoplastic Dermatomyositis Int J Mol Sci. 21\(6\): 2178.](#)
- [Beltraminelli H & Borradori L \(2020\) Paraneoplastic Disorders. In: Braun-Falco's Dermatology. Editors Plewig G, French L, Ruzicka Th, Kaufmann R & Hertl M \[https://doi.org/10.1007/978-3-662-58713-3_113-1\]\(https://doi.org/10.1007/978-3-662-58713-3_113-1\)Geng G, Yu X, Jiang J, Yu X \(2020\)](#)

[Aetiology and pathogenesis of paraneoplastic autoimmune disorders. Autoimmun Rev. Jan;19\(1\):102422. doi: 10.1016/j.autrev.2019.102422. Epub 2019 Nov 13.PMID: 31733369](#)

- [Wick MR, Patterson JW \(2019\) Cutaneous paraneoplastic syndromes. Semin Diagn Pathol. Jul;36\(4\):211-228. doi: 10.1053/j.semdp.2019.01.001. Epub 2019 Jan 31.PMID: 30736994](#)

Chapter 4 – Diseases of the Appendages and of the Mucous Membranes

4.1 Diseases of Sebaceous and Apocrine Glands

4.1.1 Acne vulgaris and Subtypes

Grading & Level of importance: B
H. Gollnick, Magdeburg



ICD-11

ED80Z

Synonyms

Pimples. Spots.

Definition

Very common, chronic, inflammatory disease of the sebaceous follicles almost always appearing in the pre and pubertal age. 30% of patients are adults.

Epidemiology

One can distinguish between physiological acne (60%) as a mild variant from clinical acne (40%) that needs medical care. It starts at the age of 8-9 years at beginning of releasing growth factors and other puberty associated hormonal factors continuing into late adolescents time and decreases in clinical activity by around 20 years of age. Highest prevalence in 14-18 years old adolescents with a prevalence of up to 94%. Specific forms may also occur in newborn, infants and children and adults up to the 5th life decade as well.

Aetiology & Pathogenesis

Acne has a complex aetio-pathogenesis. A specific gene mutation directly linked to acne does not exist, however, there is a tendency for more severe courses of acne in families having such history. In homozygotic twins the clinical course shows > 80% homology. Genes that have established roles in controlling the development, morphology and activity of hair follicles are WNT10A, LGR6, TP63 and LAMC2.

- The 4 main pathogenetic factors are: seborrhoea as a result of increased proliferation and modification of sebocyte differentiation caused by androgens and insulin growth factor

followed by an increased production of sebum.

- Proliferation of follicular keratinocytes (response to androgen and growth signals) resulting in follicular retention hyperkeratosis with keratin- and integrin-pattern disturbance.
- Low oxygen saturation and sebum components in the infra-infundibulum ideal for proliferation of *Cutibacterium acnes* (*C. acnes*). Specific *C. acnes* strains drive the inflammation. Increased expression of TLR-2 and 4 and other danger signals are upregulated. IL-1 α and *C. acnes* mediators are involved.
- Inflammation driven by IL-1 α and *C. acnes* mediators. The innate immune system reacts strongly. CD4 and CD17 T-cells accumulate and invade the follicular wall. Neutrophils do not play a primary role. Later macrophages come into the surrounding perifollicular area and micro-scarring takes place.

Furthermore, nutritional factors can play a role: increased carbohydrate load with stimulation of IGF-receptor-1 and stimulation of androgens via nuclear factors (FoxO1). Endogenous cannabinoids and corticotropin-releasing hormone are also involved (stress reactions).

Signs & Symptoms

Precursor lesion is a microcomedo, which is invisible for the naked eye. Primary lesions are: closed comedones (whiteheads), open comedones (blackheads), papules, pustules, nodules <1cm, nodes >1cm. Secondary lesions are: macules, abscesses, fistules, hemorrhagic crusts, atrophic and hypertrophic scars and keloids. There is often a marked emotional reaction reaching up to an increased risk for suicidal intention. Social phobias are very common.

Localisation

Face, chest, upper back.

Classification

Typical forms:

- Comedonal acne: primarily comedones.
- Papulo-pustular acne: primarily papules and pustules.
- Severe papulo-pustular acne: with nodules.
- Acne conglobata: nodes, scars, abscesses, fistules, typical localisation (mid-face, shoulders, chest, upper back).

Special forms:

- Acne neonatorum (common and temporary, relative hyperplasia of the adrenals in newborn)
- Infantile acne after 1 year of age, uncommon, LH/FSH-induced raise in testosterone and other androgens, deficiency of isoenzymes of steroid metabolism, genetic background possible. Primary manifestation of adrenogenital syndrome
- Late onset acne (persisting or relapsing or first onset). Most prominent in females. Often mild endocrinological dysfunction. Sometimes evident with polycystic ovary syndrome (PCOS) and androgenic signs.
- Late type of androgenital syndrome (LTAGS): late onset of changes in androgen and cortisol metabolism in adolescent when malfunction or deficiency of 11-, 17- or 21 OH-dehydrogenase is present. Full spectrum disease is usually detected after birth and in childhood.
- Acne fulminans: severe acne with fever, leukocytosis, arthralgias, immune-mediated vasculitis, sterile abscesses of bone, elevated CRP.
- Cosmetic acne: overuse of washing and cleansers followed by microbial dysbiosis, occlusive cosmetics, lipid rich ointments.
- Acne venenata: induction, maintenance or aggravation of acne by medications (for example corticosteroids, anabolic steroids), chlorinated organic compounds (Agent Orange), iodine, oil, tar. High humidity i.e. in washing salons. Friction.
- Acne excoriée des jeunes filles (skin picking disorder): artefactual disorder with excoriations and squeezing of papules around the mouth and chin, often marked emotional component. Belongs to obsessive compulsive disorders.

The special acneiform type acne inversa/hidradenitis suppurativa as a disease of the terminal hair follicle is discussed under the diagnosis "4.1.4. Hidradenitis suppurativa". It shows marked inflammation of terminal hair follicles in intertriginous regions rich in apocrine glands.

Acne tetrad = acne conglobata, folliculitis et perifolliculitis capitis abscedens et suffodiens, pilonidal sinus and acne inversa. Specific syndromes, such as PAPA: see diagnosis 2.2.2.

Laboratory & other workups

In therapy-refractory acne, compliance / adherence has to be checked. Causes of elevated androgen levels (isoenzyme deficiency of steroid metabolism, hormone-producing tumours, adrenogenital syndrome, polycystic ovarian syndrome, exercise induced androgen increase) should be excluded.

Dermatopathology

Usually not necessary. In papulo-pustular acne sebaceous hyperplasia with infundibular widening and perifollicular lympho-mononuclear cells including acroinfundibular neutrophils forming a pustule. Some lymphocytes invade the follicular wall leading to spongiosis. Depending on severity of the clinical course, inflammation, microabscesses and scarring may appear.

Course

Self-limited with downsizing around end of the second decade of life. Late onset type acne see above.

Complications

Late onset of therapy leads to scars in 20% of patients (atrophic, hypertrophic, keloids), fistules, and pigmentary changes. Long-term psychiatric problems may develop.

Diagnosis

Clinical findings and case history.

Differential Diagnosis

- Rosacea papulo-pustulosa.
- facial folliculitis including Gram-negative folliculitis and beard folliculitis.
- Ulerythema ophryogenes.
- P-type of atopic dermatitis.
- PRIDE syndrome: following oncologic therapy with EGF receptor antagonists.
- Acne aestivalis ("Mallorca acne"): it is not acne, but an acneiform reaction in predisposed persons who develop follicular irritation from sun creams and UV exposure. It is itchy; comedones are lacking.

Prevention & Therapy

Prevention: no obligatory prevention possible, however, avoidance of provoking factors for lowering course of severity.

Therapy:

Basic topical therapy:

- In comedonic acne are drugs of first choice retinoids (comedolytic, anticomedogenic, and anti-

inflammatory) and azelaic acid (anticomedogenic, antimicrobial and anti-inflammatory. Topical sebum suppressing drugs such as clacosterone (synthetic antiandrogen) are now available and should be given acne as a part of a combination therapy in all types where the topical route is indicated.

- Papulo-pustular acne grades I or II: treat sequentially or better with combination preparation retinoids plus benzoyl peroxide (BPO) or azelaic acid or clascosterone. An antibiotic such as clindamycin can be combined with BPO or retinoid or azelaic acid. Never use topical antibiotics as monotherapy (development of resistance).
- Papulo-pustular acne with small nodules grades III-IV: treat always combined topically and systemically often oral tetracyclines such as doxycycline or minocycline, which have strong anti-inflammatory effect.
- Papulo-pustular acne with nodes: treat always topically and systemically (often oral tetracycline such as doxycycline or minocycline, which have strong anti-inflammatory effect). Consider isotretinoin and in females oral contraceptives indicated for acne or anti-androgens (e.g. cyproterone acetate, chlormadinone acetate (in reserve), drospirenone or dienogest alone or combined with estrogens).
- Acne conglobata: Isotretinoin is the first choice. Systemic tetracycline plus retinoids plus BPO or with azelaic acid. In women consider antiandrogens (e.g. cyproterone acetate, chlormadinone acetate (in reserve), drospirenone or dienogest combined with estrogens).

Treatment of different types of scars: chemical peels, dermabrasion, microneedling, CO2 Laser, fillers, cryosurgery, surgical defect elevation for depressed scars.

Maintenance treatment to prevent relapses is essential. Above all, topical retinoids or azelaic acid for the prevention of the development of new microcomedones are indicated.

Special

None.

References

- [Plewig G, Melnik B & Chen W Ch \(2019\) Acne pathogenesis. In: Plewig and Kligman's Acne and Rosacea. Springer, Cham.](#)
- [Gollnick H, Bettoli V, Lambert J, Araviiskaia E, Binic I, Dessinioti C, Galadari I, Ganceviciene R, Iltter N, Kaegi M, Kemeny L, López-Estebarez JL, Massa A, Oprica C, Sinclair W, Szepietowski JC, Dréno B \(2016\) A consensus-based practical and daily guide for the treatment of acne patients. JEADV 2016;30 – S. 1480-1490](#)
- [Karoglan A & Gollnick H \(2021\) Acne. Hautarzt 72 \(9\):815-827. doi: 10.1007/s00105-021-04856-8.](#)

4.1.2 Rosacea

Grading & Level of importance: B.
C. C. Zouboulis, Dessau



ICD-11

ED90

Synonyms

Acne Rosacea, Kupferfinne, Couperose, Copparosa.

Definition

Centrofacial, chronic, inflammatory disease.

Epidemiology

Incidence: 165/100,000 per year, prevalence: 1 - 22% (great variation).

Individuals with fair skin type have an increased risk.

Conflicting data on gender preference.

Age of onset 30 to 50 years; in rare cases rosacea can occur in children.

Aetiology & Pathogenesis

Multifactorial etiology:

- Environmental trigger factors (extreme temperatures, temperature changes, sunlight)
- Micro-organisms (demodex mites, possibly helicobacter pylori)
- Nutrition (caffeine, alcohol, hot and spicy foods)
- Body conditions (exercise, acute psychological stress, menstruation)
- Certain medications

Pathogenesis:

- Impaired permeability barrier in the stratum corneum (cytokine release leading to cutaneous inflammation)

- Antimicrobial peptides (defensin, cathelicidin)
- Overexpression of Toll-like receptors
- Inflammatory cells (adaptive immune cells, B lymphocytes)
- Reactive oxygen species
- Angiogenesis (leading to telangiectasias)
- Sensory nerve activation (release of vasoactive neuropeptides)

Signs & Symptoms

Centrofacial transient erythema (flushing), telangiectatic erythema, papules and pustules without comedones, phymas, bilateral conjunctivitis, stinging and burning sensations.

Localisation

Mid-face, forehead, nose, conjunctiva, V-area of chest.

Classification

Type I (telangiectatic): Flushing, telangiectatic erythema

Type II (papulopustular): Flushing, telangiectatic erythema, centrofacial inflammatory papules and pustules

Type III (phymatous): Rhinophyma, disfiguring growth of hyperplastic sebaceous glands on the nose and other facial regions.

Ocular rosacea.

Morbihan's disease.

Laboratory & other workups

Skin biopsy for ruling out other facial dermatoses, cyanoacrylate tapestrip for demodex detection.

Dermatopathology

All subtypes show dilated lymph and blood vessels in the upper and mid-dermis and a superficial perivascular and perifollicular mononuclear lympho-histiocytic infiltrate. Oedema and thickened elastic fibres may be seen.

Type I: changes are sparse.

Type II: epithelia of follicular infundibula can show spongiotic changes and intrafollicular neutrophils

as well as lymphohistiocytic infiltrates.

Type III: sebaceous glands are hyperplastic and granuloma formation and cysts develop. In the granulomatous subtype, non-caseating epithelioid cell granulomas arise. Demodex mites are found in around 10% of routine biopsies causing follicular dilation, folliculitis and perifollicular inflammation.

Course

Progressive course.

Complications

Proliferation of connective tissue and sebaceous follicles: rhinophyma (enlarged nose), otophyma (ears), metophyma (forehead), gnathophyma (chin). Rosacea fulminans and rosacea conglobata = maximal variant of rosacea. Keratitis in ocular rosacea.

Diagnosis

Typical clinical findings.

Differential Diagnosis

Large list of differential diagnoses.

Major: Late-onset acne, corticosteroid-induced acne, perioral dermatitis.

In stage I also lupus erythematosus.

If lupoid: sarcoidosis (lupus pernio), erysipelas.

Prevention & Therapy

Elimination of triggers.

Type I: Topical: Brimonidine tartrate 0.33-1% gel 1x/d, oxymetazoline 1% cream.

Procedures: Nd: YAG Laser, pulsed dye Laser, intense pulsed light (IPL)

Type II: Topical: Metronidazole 0.75-1% cream or gel 2x/d, azelaic acid 20% cream/15% gel 2x/d, ivermectin 1% cream 2x/d, pimecrolimus 1% ointment 1x/d, tretinoin 0.025% cream 1x/d, adapalene 0.1% cream 1x/d, permethrin 5% cream 1x/d, benzoyl peroxide 5% gel 1x/d, erythromycin 2% gel, dapson 5% gel - Systemic: Doxycycline 50-200 mg/d in one or two doses, isotretinoin 0.15-0.3 mg/kg bw/d, zinc sulphate 100 mg/d.

Type III: Systemic: Isotretinoin 0.3 mg/kg bw/d and procedures: Surgical approach, including dermabrasion, ablative lasers.

Ocular rosacea: Systemic: Doxycycline 100 -200 mg/d

Special

None.

References

- [Joerg Buddenkotte , Martin Steinhoff \(2018\) Recent advances in understanding and managing rosacea. F1000 Faculty Rev-1885.](#)
- [Hanlin Zhang , Keyun Tang , Yuchen Wang , Rouyu Fang , Qiuning Sun \(2021\)Rosacea Treatment: Review and Update Dermatol Ther \(Heidelb\) .11\(1\):13-24.](#)

4.1.3 Periorificial Dermatitis

Grading & Level of importance: B
H. Gollnick, Magdeburg



ICD-11

ED90.1

Synonyms

Perioral dermatitis; Rosacea-like dermatitis.

Definition

Acneiform dermatosis with small papules and tiny pustules without comedones and with almost exclusively perioral and periorbital involvement. F 70% > 30% M. 20-40 years of age. Increasing number of children and adolescents with POD. The name is deduced from its location of lesions occurring primarily around the mouth but also around the eyes, the nostrils, and occasionally, the genitals.

Epidemiology

In the USA around 0.5 to 1%, no clear data from Europe. Often misdiagnosed.

Aetiology & Pathogenesis

Some evidence exists that a hyperhydration of the follicular epithelium and steroid induced atrophy of the epithelium can support the release of inflammatory mediators into the surrounding superficial dermis and acroinfundibulum.

- Long term use of topical steroid preparations. Periorificial dermatitis (POD) has also been reported after the use of nasal steroids sprays and creams or steroid inhalers.
- Daily cosmetics: skin care with high water content creams including sunscreens, and an ingredient of the moisturizing vehicle isopropyl myristate are to be causative. Fluorinated toothpastes.
- Physical factors: high humidity
- Microbiologic factors: Fusiform spirilla bacteria from the oral microbiome settling in the perioral region (saliva excess in the night running from the angulae to the surrounding skin). Often induction or worsening after long lasting dental procedures, Malassezia furfur and Candida species can superinfect.

Signs & Symptoms

Inflammatory small papules with tiny pustules, erythema and small scales are dominant lesions. The patients often complain of burning and tight sensation. No comedones. Often impaired quality of life.

Localisation

Perioral, periorbital, nasolabial, glabella. Genital.

Classification

None.

Laboratory & other workups

Not necessary.

Dermatopathology

In granulomatous-like lesions a biopsy to exclude rosacea, acne agminata or sarcoidosis and histiocytic diseases can become necessary. Mostly perifollicular and dermal edema and prominent lymphomononuclear infiltrates with slight spongiosis of the acroinfundibular and interfollicular epidermis, sometimes acanthotic epithelium.

Course

It mostly starts slowly over 2-3 weeks. Flares can be seen whilst reducing frequency of application of corticosteroid creams.

Complications

Granulomatous type of POD.

Diagnosis

Sometimes difficult. Case history and localization important. Exclude comedones and rosacea.

Differential Diagnosis

- Rosacea of papulo-pustular type.
- Gram-negative folliculitis.
- Corticosteroid-induced acne, PRIDE syndrome from oncologic therapy with EGF receptor antagonists.
- Sometimes a mixture of acne and / or rosacea with POD can be complicated to differentiate.

Prevention & Therapy

Prevention: Avoid facial use of corticosteroids and of overwashing and overmoisturizing.

Therapy:

Topical: withdraw corticosteroids, however, flare up may occur. Initially slow down corticosteroids to every other day or every third day. Change from strong moisturizer galenics to less water containing ones. Apply initially overnight drying zinc lotion. Metronidazole lotion, fusidic acid cream, topical ketoconazole helps to reduce spirilla microbes. Further for reducing inflammatory course pimecrolimus or tacrolimus.

Systemic: low dose doxycycline (anti-inflammatory, para-antibiotic effect).

Important point: never use topical corticosteroids as a treatment.


Special

None.

References

- [Gray NA, Tod B, Rohwer A, Fincham L, Visser WI, McCaul M. Pharmacological interventions for periorificial \(perioral\) dermatitis in children and adults: a systematic review. J Eur Acad Dermatol Venereol. 2022;36\(3\):380–90.](#)

4.1.4 Hidradenitis Suppurativa

Grading & Level of importance: C 
C. C. Zouboulis, Dessau

ICD-11

ED92.0

Synonyms

Acne inversa; inverse acne; suppurative hidradenitis; pyoderma fistulans sinifica; hidrosadenitis suppurativa; Verneuil disease.

Definition

Chronic, inflammatory, recurrent, debilitating skin disease (of the terminal hair follicle) that usually presents after puberty with painful, deep-seated, inflamed lesions in the apocrine gland-bearing areas of the body, most commonly the axillary, inguinal, and anogenital regions.

Epidemiology

Prevalence 0.04% (range 0.03-1%), annual age- and sex-adjusted incidence 6.0 per 100,000. Increasing incidence over the past four decades particularly among women. Male: female ratio 1:1.2 to 1:3.3.

Aetiology & Pathogenesis

The exact pathogenetic mechanism of hidradenitis suppurativa remains unclear. Potential causes are related to genetic, environmental, endocrine and microbiological factors. Follicular keratinocyte differentiation, adipocyte function and inflammation seem to be the major molecular pathogenetic pathways. Sporadic disease 70%, familial disease 30% (mutations at the nicotinic domain within the γ -secretase complex, chromosome 19p13). Smoking (12.6x), obesity (1.1x with every BMI unit; 18% from BMI>30) and metabolic syndrome (4.5x) are major predisposing factors.

Signs & Symptoms

Chronic recurrent inflammatory nodules, nodes, abscesses, draining tunnels (double comedones, fistulae, and sinuses) and scars.

Localisation

Mostly intertriginous occurrence in decreasing order of frequency: inguinal, axillary, perineal and perianal, submammary and/or intermammary fold in women, buttocks, mons pubis, scalp, retroauricular area and eyelids.

Classification

Combination of anatomical classification (Hurley I, II, III) and severity classification (mild, moderate, severe; IHS4 score). IHS4 can also evaluate HS severity in a dynamic manner.

IHS4 (points) =	
number of nodules	× 1 +
number of abscesses	× 2 +
number of draining tunnels (fistulae/sinuses)	× 4
Mild HS:	≤ 3 points
Moderate HS:	4–10 points
Severe HS:	≥ 11 points

Syndromic hidradenitis suppurativa diseases (follicular occlusion, Bazex-Dupré-Christol, Down's, KID, PAPASH, PASS, PASH, and SAPHO syndromes, Dowling-Degos disease).

Laboratory & other workups

C-reactive protein, erythrocyte sedimentation rate.

Dermatopathology

Heterogeneous histological pattern with hyperplasia of hair follicular epithelium, hyperkeratosis of the terminal follicles, pronounced perifolliculitis, follicle rupture, epidermal psoriasiform hyperplasia, subepidermal and deep cellular inflammatory infiltrate, pronounced acute/chronic dermal inflammation, involvement of apocrine glands and involvement of the subcutis (fat tissue).

Course

Acute: Recurrent, painful, deep-seated, inflamed nodules with burning, itching, local warmth, and hyperhidrosis.

Chronic: Multiple abscesses, double pseudocomedones, tunnels, foul-smelling discharge, scarring, ulceration.

Complications

Squamous cell carcinoma in chronic anogenital lesions, deep scars, depression, unemployment, change of profession.

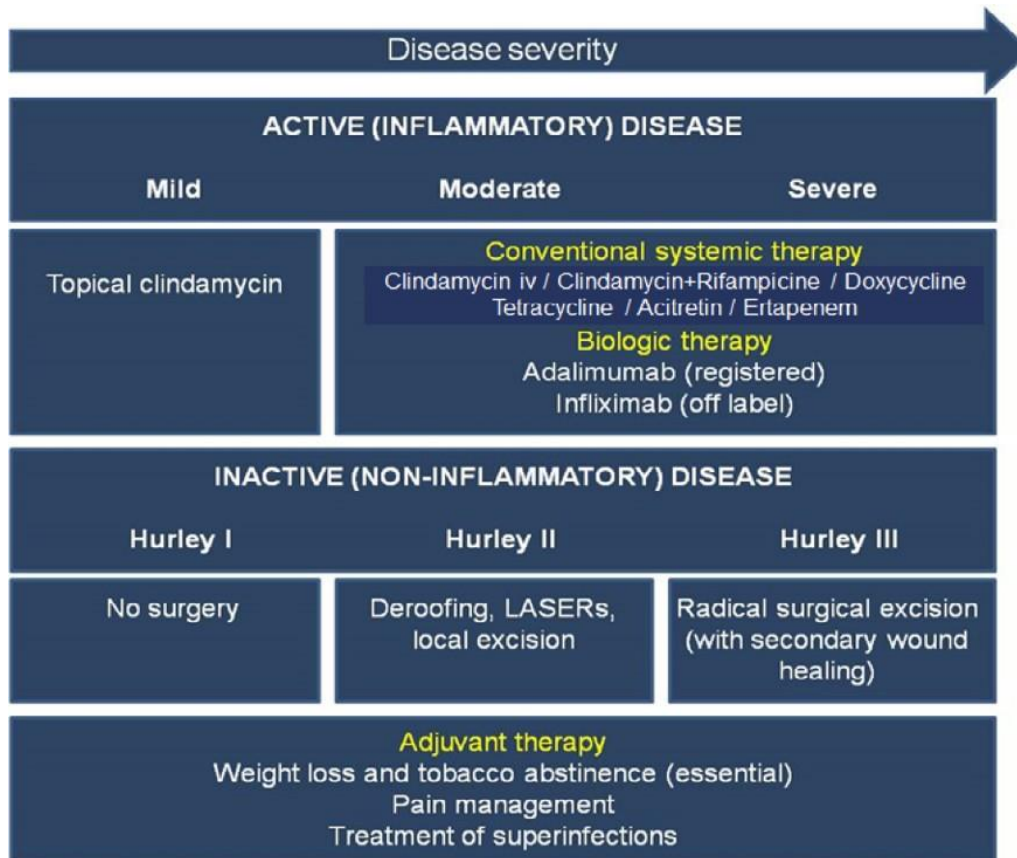
Diagnosis

Outbreak of boils during the last 6 months with a minimum of 2 boils in one of the following 6 locations: axilla, groin, genitals, buttocks, under the breasts and perianal, neck and abdomen regions.

Differential Diagnosis

Staphylococcal infection (furuncle, carbuncle), cutaneous Crohn’s disease, primary or metastatic tumors, lymphogranuloma venereum, apocrine abscess, rare diseases (cutaneous actinomycosis, tuberculosis cutis colliquativa).

Prevention & Therapy



Prevention: Weight loss and tobacco abstinence, pain management, treatment of superinfections.

Special

Comorbid disorders: Inflammatory bowel disease, spondylarthropathy, increased cardiovascular risk. Syndromic hidradenitis suppurativa diseases are rare.

4.2 Diseases of Hair and Nails

4.2.1 Alopecia Areata

Grading & Level of importance: B

H.Gollnick, Magdeburg; V. del Marmol, Brussels; J. White, Brussels

**ICD-11**

ED70.2

Synonyms

Spot baldness, patchy alopecia, autoimmune hair loss.

Definition

A reversible, non-scarring, usually localised but occasionally generalised form of autoimmune hair loss involving sometimes the nails.

Epidemiology

Alopecia areata may affect 0.1% to 2% of the population, usually in a mild form. It is present in all ethnic populations.

Aetiology & Pathogenesis

It is caused by an autoimmune process with lymphocytic (T-helper and T-cytotoxic cell subsets) infiltrate around anagen hair bulb causing (initially) reversible hair loss. A breakdown of immune privilege of the hair follicle is thought to be an important driver of alopecia areata. There is an association with other autoimmune diseases (atopic syndrome, vitiligo, thyroid diseases) and Down's syndrome.

Signs & Symptoms

Usually there are no symptoms reported by the patient apart from a noticeable loss of hair. Itch, pain or erythema are missing. There is no visible inflammation, but local minor oedema can occur and the loss of hair is non-scarring loss, typically in circular shapes with solitary, multiple or diffuse patterns. Pull test from the margin is in active disease positive. Sometimes there are associated nail changes (pitting, or roughness, termed trachyonychia, or even nail loss at a late stage, termed onychomadesis). Exclamation mark hairs may be seen on careful examination, but are not pathognomonic.

Localisation

It may occur in any part of the body, but is most easily identified in hairy areas such as the scalp or beard region, brows and eye lashes.

Classification

Classification is according to extent of hair loss:

- alopecia areata (AA) (patchy alopecia),
- ophiasis type (occipito-temporal alopecia),
- alopecia totalis (AT; complete scalp alopecia), and
- alopecia universalis (AU; complete scalp and body alopecia).

Recently a new scoring system has been introduced: AA-spectrum disease should simply be classified as AA with two additional qualifiers, a SALT score (Severity of Alopecia Tool (SALT), used to calculate an AA severity score (0-100%, no hair loss to complete scalp hair loss) and the presence or absence of body involvement (complete or incomplete loss of body hair).

Laboratory & other workups

An association with atopy (e.g. with increased IgE) conveys a worse prognosis. Sometimes an associated autoimmune thyroiditis is present and may be screened for (e.g. microsomal thyroid antibodies, antibodies against thyroglobulin). Syphilis serology (where there are multiple small patches clinically) should be considered to exclude moth-eaten alopecia of secondary syphilis. A fungal culture should be performed if there is diagnostic doubt or scaling present incl. *M. furfur* and trichophytes.

Dermatopathology

A biopsy is not usually required but would show a heavy perifollicular lymphocytic infiltrate around stage III and IV anagen follicles with apoptosis of follicular keratinocytes and formation of dystrophic

hair shafts. No destruction of the permanent part of the hair follicle.

Course

Focal lesions have a high spontaneous remission rate (30% within 6 months, 50% with 1 year, 80% within 3 years). Widespread disease has low spontaneous remission rate (<10%).

Factors conveying a poor prognosis include involvement of occipital scalp hairline (ophiasis type), widespread disease, recurrent disease, longer duration (onset in childhood), atopy, vitiligo, thyroid disease and familial occurrence.

Complications

Loss of eyebrows and eyelashes may occur with chronic conjunctivitis. Nail involvement may be troublesome (twenty nail dystrophy). The association with autoimmune thyroiditis and vitiligo (other autoimmune disorders are less commonly associated) should be considered and investigated. Psychosocial problems are very common with persistent alopecia and severe hair loss.

Diagnosis

The diagnosis is clinical in most cases.

Differential Diagnosis

The differential diagnosis includes secondary syphilis, trichotillomania, trichotemnomania, early stage of scarring alopecias (such as deep trichophyton infections) and chronic telogen effluvium.

Prevention & Therapy

Spontaneous regrowth most commonly occurs so treatment is not always required. Unpigmented hairs can occur at the beginning until bulb melanocytes recover. Small lesions can be treated with high-potency topical corticosteroids or intralesional corticosteroids. More widespread forms may respond to topical immunotherapy with diphenylcyclopropenone or short-term high dose systemic corticosteroids. Third line treatments include methotrexate, zinc and phototherapy. Wigs, permanent make-up for eyebrows and self-help groups can be helpful, especially those with psychosocial problems due to the hair loss. Currently, there are ongoing studies with the CTLA4-Ig fusion protein abatacept, anti-IL15R β monoclonal antibodies and the Janus kinase inhibitors tofacitinib, ruxolitinib and baricitinib are already launched.

Special

None.

References

- [Trüeb RM, Dias MFRG. \(2018\). Alopecia Areata: a Comprehensive Review of Pathogenesis and Management. Clin Rev Allergy Immunol. Feb;54\(1\):68-87. doi: 10.1007/s12016-017-8620-9. PMID: 28717940.](#)
- [Sterkens A, Lambert J, Bervoets A. \(2021\). Alopecia areata: a review on diagnosis, immunological etiopathogenesis and treatment options. Clin Exp Med. May;21\(2\):215-230. doi: 10.1007/s10238-020-00673-w. Epub 2021 Jan 1. PMID: 33386567.](#)

4.2.2 Androgenetic Alopecia

Grading & Level of importance: B



H. Gollnick, Magdeburg; V. del Marmol, Brussels; J. White, Brussels

ICD-11

ED70.0

Synonyms

Male pattern hair loss; common balding; male-pattern balding; male-pattern baldness; hormone-induced alopecia.

Definition

Androgenetic alopecia is a non-scarring, progressive, androgen-dependent form of hair loss/hair follicle rarefaction. It occurs in typical locations (different patterns for women and men) associated with a genetic predisposition and natural aging. In women, early aggressive disease or a Hamilton-Norwood pattern of hair loss may indicate an endocrine disorder.

Epidemiology

30-40% of women will have thinning hair by the age of 70 or older. 50-60% of men have a bald scalp by 70 years.

The condition is less commonly seen in men of East Asian ancestry.

Aetiology & Pathogenesis

There is polygenic inheritance. Abnormalities of androgen metabolism, especially enhanced activity of

5 α -reductase, lead to increased levels of dihydrotestosterone in target organ. However, several other enzymes (aromatase pattern) and hormones of the androgen metabolism pathway are associated.

Signs & Symptoms

The hair loss in young male patients is progressive and persistent, but generally asymptomatic. Very occasionally scalp pain (known as trichodynia) can be a feature of the hair loss. The hairs are lost in a symmetrical pattern. In women and older men, usually normal levels of hair loss occur, however, hair regrowth is markedly diminished and hair shafts are thinner. In these cases “hair follicle rarefaction” and not hair loss represents the term properly describing the disorder.

Localisation

Women show thinning of centro-parietal scalp, with a widened parting but retained anterior hair line. The clinical pattern is variable and can be diffuse. There is never complete hair loss on the vertex.

Men typically show bi-temporal symmetrical regression, thinning of the vertex, but later, more complete loss leaving a residual parietal-occipital band intact.

Classification

Female pattern androgenetic alopecia: Ludwig scale I-III.

Male pattern androgenetic alopecia: Hamilton-Norwood scale (typical pattern; anterior pattern or vertex pattern) I-VII.

Laboratory & other workups

Tests are not usually required. However, an endocrinologic evaluation in women with other signs of androgen excess (irregular menses, hirsutism, virilisation) should be considered. Consider testing for concomitant causes of hair loss (e.g. strict diet with nutritional deficiencies, low ferritin or biotin, thyroid dysfunction, lupus erythematosus).

Dermatopathology

A biopsy is only required in cases of diagnostic difficulty (or if multiple causes of hair loss are suspected). Typical histologic findings are of miniaturisation of the hair follicle with pseudohypertrophy of the associated sebaceous glands and an increase in telogen hair follicles. Microscarring in longstanding courses.

Course

The course is generally progressive but with highly variable course, in terms of rate of hair loss and distribution.

Complications

Loss of hair may lead to chronic UV damage of the exposed scalp and easier trauma. Long-standing hair loss can cause micro-scarring. Sometimes hair loss can lead to psychosocial problems in both women and men. A couple of comorbidities are reported incl. hyperandrogenemia, polycystic ovary syndrome, hypothyroidism, prostate cancer, androgen-secreting tumors, hirsutism, SAPHO or metabolic syndrome.

Diagnosis

The diagnosis is almost always made on clinical grounds by the typical findings. Consider a hair pull test and scalp dermoscopy in cases of diagnostic difficulty. In women with early androgenetic alopecia, a trichogram may be helpful. Excessive androgen production in women must be excluded by history and clinical findings; if other clues of androgen excess are present, endocrine evaluation is needed.

Differential Diagnosis

Other causes of hair loss e.g. diffuse alopecia areata or especially telogen effluvium in women. Diffuse hair loss with metabolic deficiencies. Frontal hair fibrosing alopecia. Traction alopecia.

Prevention & Therapy

First line topical treatments are Minoxidil 2% and 5% solutions. Systemic administration of Finasteride may prevent further hair follicle rarefaction (strict avoidance of pregnancy is required in women of child-bearing years as finasteride is teratogenic). Also, spironolactone, oral contraceptives or cyproterone acetate or finasteride are to be considered in women. Hair transplantation may be suitable in some cases. Psychosocial support and provision of wigs can be considered, especially those with psychosocial issues as a result of the hair loss.

Special

None.

References

- [Porriño-Bustamante ML, Fernández-Pugnaire MA, Arias-Santiago S. \(2021\). Frontal Fibrosing Alopecia: A Review. J Clin Med. Apr 21;10\(9\):1805. doi: 10.3390/jcm10091805. PMID: 33919069; PMCID: PMC8122646.](#)
- [Ntshingila S, Oputu O, Arowolo AT, Khumalo NP. \(2023\). Androgenetic alopecia: An update. JAAD Int. Jul 22;13:150-158. doi: 10.1016/j.jdin.2023.07.005. PMID: 37823040; PMCID: PMC10562178.](#)
- [Rohini Janivara, Ujani Hazra, Aaron Pfennig et al \(2024\). Uncovering the genetic architecture and evolutionary roots of androgenetic alopecia in African men. bioRxiv preprint <https://doi.org/10.1101/2024.01.12.575396>](#)
- [Kanti V, Messenger A, Dobos G, Reygagne P, Finner A, Blumeyer A, Trakatelli M, Tosti A, Del Marmol V, Piraccini BM, Nast A, Blume-Peytavi U. \(2018\). Evidence-based \(S3\) guideline for the treatment of androgenetic alopecia in women and in men - short version. J Eur Acad Dermatol Venereol. Jan;32\(1\):11-22. doi: 10.1111/jdv.14624. Epub 2017 Nov 27. PMID: 29178529](#)

4.2.3 Hirsutism and Hypertrichosis

Grading & Level of importance: B
V. del Marmol, Brussels; J. White, Brussels



ICD-11

ED72

Synonyms

Hirsutes, excessive hair, endocrine hypertrichosis; endocrine and para-endocrine hypertrichosis (whereas hirsutism defines an excessive form of hypertrichosis probably due to underlying disease).

Definition

Excessive, disease-associated, terminal hair in women with a male pattern distribution or ethnic hypertrichosis pattern without endocrinological changes.

Epidemiology

Around 4-11% of women may show signs of hirsutism in several populations. The main manifestation

of hyperandrogenism in women is with polycystic ovary syndrome (PCOS), with a prevalence estimated at 65-75%. Certain populations (e.g. far east) may present ethnic hypertrichotic hair patterns not considered as hirsutism. It is a common medical finding affecting approximately 5-15 % of premenopausal women worldwide.

Aetiology & Pathogenesis

There are many different causes and an early and late onset of hirsutism.

Genetically determined in both genders with early onset in a hirsute pattern. This is not ethnic or genetic hypertrichosis. While 80-90 % of women with hirsutism have measurable hyperandrogenemia, the severity of hirsutism and the level of androgen metabolism and excess are not well-correlated. Most probably a peripheral metabolic disorder affects the distribution of hair and within the follicle.

Endocrine hirsutism with late onset around puberty or even later: about 50% of women with hirsutism have endocrine abnormalities: polycystic ovary syndrome; androgen-producing ovarian tumours; congenital adrenal hyperplasia (adrenogenital syndrome); adrenal tumours; ACTH-cell hyperplasia; pituitary adenomas (Cushing's disease); hyperprolactinemia; acromegaly.

Other causes: postmenopausal hirsutism; idiopathic hirsutism; medication-induced hirsutism (e.g. anabolic steroids).

Signs & Symptoms

Female patients report secondary or post-pubertal increase of hair growth of terminal and vellus hair on upper lip, chin, inframammary area, around nipples, on shoulders, linea alba and interior aspects of thighs. This may vary from discrete excess hair to an obvious male pattern with involvement of different locations. The clinical appearance may be highly variable.

Localisation

This may include the upper lip, chin, breast, abdomen, pubic area, arms, legs, back and buttocks.

Classification

Revised Ferriman-Gallwey system with 19 locations to be considered. The minimum score is 0 and the maximum is 36. A score of more than 8 indicates hirsutism.

Laboratory & other workups

In most women with hirsutism, the hormone status (FSH/LH ratio, DHEAS, androstendione, free

testosterone, 17-hydroxyprogesterone, SHBG, anti-Müllerian hormone, prolactin, TSH) should be assessed and investigations such as a transvaginal ultrasound evaluation of ovaries considered.

Dermatopathology

This is not required.

Course

This is persistent, unless an underlying cause can be found and treated adequately.

Complications

Psychosocial problems are common. Females suffer very strongly and spend a lot of time and money for hair removal. There is also a tendency towards folliculitis due to shaving and dewaxing. Type 2 diabetes mellitus may be more common if polycystic ovarian syndrome is present.

Diagnosis

The diagnosis is usually clinical, with typical hair pattern. Endocrine screening is usually performed with more detailed evaluation if hyperandrogenism is present. Duplex sonography should be considered to exclude superficial thrombophlebitis.

Differential Diagnosis

There can be considerable ethnic variability. Other diagnoses to consider include hypertrichosis (ethnic background) and virilisation (mostly tumour-associated).

Prevention & Therapy

Examine and treat the causes of hyperandrogenism and metabolic changes if present.

Mechanical removal of hair includes shaving, waxing, epilation, electroepilation, laser or light-assisted hair removal. Hair growth may be slowed or stopped by chemical means (e.g. eflornithine topically). Consider spironolactone, finasteride, low dose cyproterone acetate or oral contraceptives. Clinical effects may be seen after six to twelve months.

Psychosocial support should be offered.

Special

None.

References

- [Somani, N., Turvy, D. \(2014\). Hirsutism: An Evidence-Based Treatment Update. Am J Clin Dermatol15, 247–266 \(2014\). https://doi.org/10.1007/s40257-014-0078-4. PMID: 24889738.](#)
- [Spritzer PM, Marchesan LB, Santos BR, Figuera TM. \(2022\). Hirsutism, Normal Androgens and Diagnosis of PCOS. Diagnostics \(Basel\). 2022 Aug 9;12\(8\):1922. doi: 10.3390/diagnostics12081922. PMID: 36010272; PMCID: PMC9406611.](#)

4.2.4 Nail Dystrophies

Grading & Level of importance: B
V. del Marmol, Brussels; J. White, Brussels



ICD-11

EE10.5

Synonyms

Onychodystrophy.

Definition

Disturbances in nail growth (proliferation, differentiation and maturation).

Epidemiology

Very common disorder. Incidence and prevalence are unknown, it depends on the pathogenetic background (trauma, mycosis, autoimmune disorder, vascular diseases, scleroderma, internal diseases).

Aetiology & Pathogenesis

The cause of nail dystrophy is often idiopathic, but may alternatively reflect manifestations of other

diseases e.g. psoriasis, lichen planus, dermatitis, metabolic disorders, toxic damage, infections or medications (particularly chemotherapeutic agents). They may also be due to mechanical irritation (e.g. excessive nail manicures).

Signs & Symptoms

The nail changes are often asymptomatic, apart from the changes in colour, structure and growth pattern of nails. Occasionally functional problems are encountered, such as pain on movement or putting on shoes.

Localisation

Finger- or toe-nails. The skin, hair and teeth (in children) should otherwise be examined for further signs.

Classification

This may be based on the site of the dystrophy within the nail and may be described with one of the following terms: onychoschisis, onychorrhhexis, onycholysis or onychomadesis.

Laboratory & other workups

Consider taking clippings for microscopy and culture to exclude dermatophyte, yeast or a pseudomonas infection. Sometimes blood tests are required if a vitamin or mineral deficiency is suspected.

Dermatopathology

A biopsy is not usually required.

Course

Varies according to underlying cause.

Complications

Secondary fungal infections are possible.

Diagnosis

The diagnosis is made from the clinical findings in context of associated findings.

Differential Diagnosis

There is a wide differential diagnosis. Consider - among others - infection, psoriasis, atopic dermatitis, allergic or irritant contact dermatitis, lichen planus.

Prevention & Therapy

Avoid prolonged wetting of the hands and finger nails to prevent mycotic infections. Certain nail polishes and the use of artificial nails can adversely affect the nail surface and lead to nail plate defects and infections. The use of a protective, uncoloured nail lacquer should be considered.

Active treatment is predominantly of the underlying disease. Podiatry review may be required for severe toenail involvement impinging on walking.

Special

None.

References

- [Wollina U, Nenoff P, Haroske G, Haenssle HA. \(2016\). The Diagnosis and Treatment of Nail Disorders. Dtsch Arztebl Int. Jul 25;113\(29-30\):509-18. doi: 10.3238/arztebl.2016.0509. PMID: 27545710; PMCID: PMC5527843](#)
- [Tasia, M., Richert, B. \(2021\). What's New in Pediatric Nail Disorders?. In: Baran, R.L. \(eds\) Advances in Nail Disease and Management. Updates in Clinical Dermatology. Springer, Cham. \[https://doi.org/10.1007/978-3-030-59997-3_14\]\(https://doi.org/10.1007/978-3-030-59997-3_14\).](#)

4.2.5 Nail Colour Changes

Grading & Level of importance: B
V. del Marmol, Brussels; J. White, Brussels



ICD-11

None.

Synonyms

Not available.

Definition

Abnormal colours (e.g. black, brown, green, yellow, blue-red or others) in nail plate or nail bed.

Epidemiology

The incidence and prevalence of the different conditions is unknown, but would vary according to the cause of the colour change.

Aetiology & Pathogenesis

Causes vary according to color.

Brown-black

- Medications: anti-malarials, cytostatic agents, antibiotics, psoralens, zidovudine in HIV infection
- Melanocytic: ethnic, melanocytic nevus, malignant melanoma
- Endocrine: Addison disease, Cushing disease
- Iron: hematoma, hemochromatosis
- Lupus erythematosus
- Infections, e.g. candida
- Splinters

Yellow-brown

- Psoriasis
- Onychomycosis
- Lichen planus

Green

- Pseudomonas aeruginosa

Yellow

- Onychomycosis
- Yellow nail syndrome (often associated with chronic sinusitis, bronchitis, pleuritis, pulmonary fibrosis, bronchiectases)

Blue-red

- Glomus tumor
- Nail bed cyanosis (central circulatory problems, methemoglobinemia)
- Vasculitis

White

- Vitamin/mineral deficiencies (e.g. zinc, calcium etc.)

Signs & Symptoms

The discoloration of the nails is usually asymptomatic. Early-stage haematomas and some infections may be uncomfortable.

Localisation

Finger- or toe-nails.

Classification

There is no classification, apart from by underlying cause.

Laboratory & other workups

Tests will depend on the suspected underlying disease. Consider clipping of nail for mycological analysis or biopsy (see below).

Dermatopathology

A biopsy is mandatory when a melanoma is suspected. Where adequate laboratory support is present, histological analysis from a biopsy may help with the diagnosis.

Course

This may be acute, subacute to chronic or relapsing. Most of the colour changes result from chronic disease.

Complications

This depends on the underlying cause but the changes may infrequently lead to nail destruction.

Diagnosis

The diagnosis is made on the clinical findings, mycology, bacteriology or histology tests. A key diagnostic factor is whether the whole nail is affected or not and the progression of the colour change. Sometimes targeted questions can help make the diagnosis, e.g. did the discolouration start proximally or distally, slowly or rapidly?

Differential Diagnosis

See above causes. Always consider a melanoma in cases of brown/black discolouration.

Prevention & Therapy

Treatment is directed at the underlying cause. Routine nail hygiene including clipping and moisturizing may be relevant. In general, patients should be discouraged from excessive manipulation or removal of the cuticle.

Special

None.

References

- [Tasia, M., Richert, B. \(2021\). What's New in Pediatric Nail Disorders?. In: Baran, R.L. \(eds\) Advances in Nail Disease and Management. Updates in Clinical Dermatology. Springer, Cham. https://doi.org/10.1007/978-3-030-59997-3_14](https://doi.org/10.1007/978-3-030-59997-3_14)
- [Singal A, Bisherwal K. \(2020\). Melanonychia: Etiology, Diagnosis, and Treatment. Indian Dermatol Online J. Jan 13;11\(1\):1-11. doi: 10.4103/idoj.IDOJ_167_19. PMID: 32055501; PMCID: PMC7001389.](https://doi.org/10.4103/idoj.IDOJ_167_19)

4.3 Diseases of Mucous Membranes

4.3.1 Oral Leukoplakia

Grading & Level of importance: B
H.Gollnick (Magdeburg)



ICD 11

DA01.00

Definition

“A predominantly white patch or plaque that cannot be characterized clinically or pathologically as any other disorder; oral leukoplakia carries an increased risk of cancer development either in or close to the area of the leukoplakia or elsewhere in the oral cavity or the head-and-neck region” (WHO 2005 and 1978 adjustment suggestion).

Synonyms

None.

Epidemiology

Current incidence of cancers of the oral cavity is mainly consisting of squamous cell carcinomas. It varies worldwide from less than three to seven or eight per 100,000 population. It affects mainly middle-aged and elderly people. Prevalence of oral leukoplakia is approximately 0.1% with a huge variation in different parts of the world above the age of 30-40 years. Annual risk of malignant transformation of oral leukoplakia from 2 to 3% or even much higher.

Aetiology & Pathogenesis

Tobacco habits of different types (nitrosamines and aromatic carbohydrates such as 3,4-benzpyrene) and alcohol consumption are the most important etiologic fac-

Tors (combined risk increases by 6 to 15 fold). Human papilloma virus plays a limited role in the etiology of oral cancer in contrast to its role in oropharyngeal cancer.

Signs & Symptoms

Homogenous and inhomogenous leukoplakia. Both forms are different in border, surface, profil, thickness and colour. Homogeneous Leukoplakia shows flat, thin, sharply bordered and homogenous

surface pattern. Inhomogenous leukoplakia in contrast has verrucous and erosive surface as well as colour varying from white to red (erythroleukoplakia).

Localization

Mainly buccal, gingiva and lateral tongue.

Classification

Classically, two major clinical types of leukoplakia are recognized, being the homogeneous and the non-homogeneous type. The last should have a higher risk of malignant development.

Squamous intraepithelial neoplasia SIN I-III.

Course

Chronic and slow growing.

Complications

HPV 16, 18, 31 in lesion increases risk of malignant transformation.

Laboratory & other work ups

No specific.

Dermatopathology

Oral leukoplakia histopathological findings range from hyperkeratosis without epithelial dysplasia to various degrees of epithelial dysplasia. Absence of epithelial dysplasia does not exclude oral leukoplakia as being a potentially (pre)malignant lesion. 5% invasive, 25% precursor intraepithelial.

Diagnosis

Inspection and palpation followed by VELscope (Vision Enhanced Lesion Scope) and algorithm of steps incl. brush biopsy for DNA testing and regular biopsy.

Differential diagnosis

Frictional hyperkeratosis, lichen planus, hyperplastic type of candidiasis, restoration associated epithelial lesion, alveolar ridge keratosis. [Naevus spongiosus albus mucosae](#).

Prevention & Therapy

Prevention: avoiding risk factors as mentioned above.

Therapy: no harmonized unifying concept. Excision, cryotherapy, laser, local vitamin A acid and photodynamic therapy

References

- [Isaac van der Waal \(2019\) Oral Leukoplakia: Present Views on Diagnosis, Management, Communication with Patients, and Research \(2019\) Current Oral Health Reports 6:9–13](#)
- [Renaud-Vilmer C, Cavelier-Balloy B. \[Precancerous lesions of the buccal epithelium\]. Ann Dermatol Venereol. 2017 Feb;144\(2\):100-108.](#)
- [Lodi G, Franchini R, Warnakulasuriya S, Varoni EM, Sardella A, Kerr AR, Carrassi A, MacDonald LC, Worthington HV. Interventions for treating oral leukoplakia to prevent oral cancer. Cochrane Database Syst Rev. 2016 Jul 29;7\(7\):CD001829. doi: 10.1002/14651858.CD001829.pub4. PMID: 27471845; PMCID: PMC6457856.](#)

4.3.2 Mucosal Aphthae

Grading & Level of importance: B
C. C. Zouboulis, Dessau



ICD-11

DA01.15

Synonyms

Recurrent aphthous stomatitis (RAS), aphthous stomatitis, recurrent oral ulcers (ROU), recurrent bipolar (oral/genital) aphthosis.

Definition

Aphthae present as acute, recurrent and chronic multiple, small, round or ovoid ulcers, having a yellow floor and surrounded by an erythematous halo, usually occurring first in childhood or adolescence.

Epidemiology

Recurrent oral aphthae are considered as the most common mucosal lesions. They affect up to 2-10% of people with a 3-month recurrence rate of 50% and a lifetime prevalence of >35%. They are more common in females. Recurrent oral aphthae are more commonly seen with increasing age. Recurrent genital aphthous ulcers are much less common. Family history has been reported in 24-46%.

Aetiology & Pathogenesis

The aetiology of recurrent aphthae is unclear. Many factors have been implicated in disease pathogenesis, including vitamin B and/or folic acid deficiency or resorption defect, anemia (including serum iron/ ferritin deficiency), neutropenia, stress, diverse bacterial and viral pathogens, hormonal changes, trauma, drugs, food hypersensitivity (chocolate, coffee, peanuts, cereals, almonds, strawberries, cheese, tomatoes and wheat flour containing gluten). Smoking seems to increase severity and the frequency of recurrence of oral aphthae. A weak association with HLAB12 and HLA-DR2 has been described in certain populations.

Signs & Symptoms

Minor oral aphthae are usually concentrated in the anterior part of the mouth, are superficial, <1 cm in diameter (usually 4-5 mm) and tend to heal within 10-14 days. Major oral aphthae are >10 mm in diameter, deeper, can last for weeks. Herpetiform aphthae are small (1-2 mm), multiple lesions (5-100) may be present at the same time. Individual aphthae are grey and without a delineating erythematous border, making them difficult to visualize. Aphthae induce pain in eating and speaking. A single crop of ulcers may last for approximately 7-14 days, the period of remission between attacks is variable. Herpetiform aphthae may coalesce to larger lesions, and are predominantly detected in female patients and have a later age onset than the other types.

Localisation

Minor aphthae involve the non-keratinized mucosa of the oral cavity (labial and buccal mucosa, the floor of the mouth and the ventral or lateral surface of the tongue) or genital mucosa. Lesions are more rounded on the labial or buccal mucosa and elongated in the buccal sulcus. Major aphthae have a predilection for lips, tongue, soft palate, and the palatal fauces and cause significant pain and dysphagia (frequent in patients with “malignant” aphthae: HIV infection, Adamantiades-Behçet’s disease). Herpetiform aphthae may involve any non-keratinized mucosa but characteristically affect the lateral margins and ventral surface of the tongue and the floor of the mouth.

Classification

Classification depends on the dimensions of the lesions, their number and form:

- Minor: Most common form (85%; do not result in scarring)
- Major: Approximately 10-15% (may leave a scar)
- Herpetiform: 5-10%

Laboratory & other workups

Non-specific. Hemoglobin, full blood count, erythrocyte sedimentation rate, c-reactive protein, serum vitamin B complex, serum/red cell folate, iron, ANA, ENA, HHV-PCR, anti-gliadin and anti-endomysial autoantibodies, Coxsackie- and Echo-Virus serum titres. Bacterial and viral swabs for specific microbe examination.

Dermatopathology

Early aphthae: Disruption of the epithelial ductal orifice of minor salivary glands and moderate mononuclear (lymphocytic) infiltrate surrounding the duct and the lobules of minor salivary glands.

Developing aphthae: Small focal ulceration immediately above the excretory duct of minor salivary glands with consequent development of a fibropurulent membrane. Mononuclear cells and neutrophilic acute inflammatory infiltrate are seen at the base of the ulcer and, within it, a fibrinous exudate but only occasionally in adjacent and subjacent tissues where mononuclear (lymphocytic) cells predominate.

Course

Usually recurrent with varying frequency (2-12x/year up to intervals of few days). Decrescendo and crescendo courses of years have been observed. Female patients may relate the onset of aphthae to their menstrual cycle, pregnancy, and dysmenorrhea. Aphthae usually improve during pregnancy and may be affected by sex steroids.

Complications

Aphthous ulcers may occur at sites of trauma, particularly due to toothbrushing, or the site of a local anesthetic injection and dental treatment. The use of certain drugs (sodium hypochlorite, piroxicam, phenobarbital, phenindione, niflumic acid, nicorandil, gold salts, captopril, non-steroidal anti-inflammatory drugs) may induce oral aphthae.

Diagnosis

Clinical picture, personal and family history.

Differential Diagnosis

The spectrum of differential diagnoses is broad and one should always examine the mucosa of oral and ano-genital areas, as well as the rest of the skin.

One of the important differential diagnosis is Adamantiades-Behçet disease which is a chronic recurrent systemic vasculitis in which oral and genital ulcers are major diagnostic criteria. 99% of patients have recurrent oral aphthae. Recurrent genital aphthous ulcers are seen in 65%. In 85% of patients, the first manifestation is oral aphthae, while 4% start with genital aphthous ulcers (2nd most frequent symptom). About 10% of the patients with recurrent severe aphthosis in Caucasian populations develop Adamantiades-Behçet disease; the likelihood is higher in the eastern Mediterranean region, Middle East and Asia. Clinical diagnostic criteria are applied.

Other systemic or localized diseases are gastrointestinal inflammatory diseases (ulcerative colitis, Crohn's disease, celiac disease), infections (herpes simplex, zoster, infectious mononucleosis, hand foot and mouth disease, herpangina, HIV infection, syphilis, acute necrotizing ulcerative gingivitis, candidiasis), autoimmune diseases (lupus erythematosus, Sweet syndrome, reactive arthritis, MAGIC syndrome, sarcoidosis), bullous and lichenoid dermatoses (lichen planus, erythema multiforme and its variants, incl.

Stevens-Johnson syndrome and toxic epidermal necrolysis, bullous autoimmune disorders (pemphigus vulgaris, cicatricial pemphigoid, epidermolysis bullosa acquisita, linear IgA dermatosis), other oral disorders (allergic contact stomatitis, drug-induced ulcerative stomatitis, geographic stomatitis, PFAPA syndrome (periodic fever, aphthous ulcers, pharyngitis, cervical adenitis).

Prevention & Therapy

The aim of minor and major aphthae treatment is to decrease symptoms; reduce ulcer number, size and pain and increase disease-free periods. Approved therapies include topical corticosteroids, topical antiseptics (reduction of new aphthae) and topical anesthetics (pain relief). However, topical calcineurin inhibitors such as topical pimecrolimus or tacrolimus can also be applied.

In severe cases, topical treatment can be combined with systemic therapy, e.g. with colchicine, pentoxifylline or prednisolone.

Hard, acidic and salty food, alcohol and carbonated beverages should be avoided.

Special

None.

References

- [Gasmi Benahmed A, Noor S, Menzel A, Gasmi A. \(2021\). Oral Aphthous: Pathophysiology, Clinical Aspects and Medical Treatment. Arch Razi Inst. Nov 30;76\(5\):1155-1163. doi: 10.22092/ari.2021.356055.1767. PMID: 35355774; PMCID: PMC8934078.](#)
- [Altenburg A, El-Haj N, Micheli C, Puttkammer M, Abdel-Naser MB, Zouboulis CC \(2014\). The treatment of chronic recurrent oral aphthous ulcers. Dtsch Arztebl Int 2014; 111: 665–73. DOI: 10.3238/arztebl.2014.0665](#)
- [Yazici, Y., Hatemi, G., Bodaghi, B. et al. \(2021\). Behçet syndrome. Nat Rev Dis Primers 7, 67. https://doi.org/10.1038/s41572-021-00301-1](#)

4.3.3 Balanitis

Grading & Level of importance: B

E. Hiltunen-Back, Helsinki; A. Ranki, Helsinki; A. Salava, Helsinki



ICD-11

GB06.01 Irritant balanitis/balanoposthitis, GB06.02 Balanitis/balanoposthitis due to infection, GB06.0Z Balanoposthitis, unspecified, GB06.0Y Circinate balanitis, 1F23.11 Candida balanoposthitis, 2E67.4 Carcinoma in situ of penis (penile intraepithelial neoplasia).

Synonyms

Inflammation of the glans penis and/or prepuce (foreskin).

Definition

Balanitis is a descriptive term which refers to inflammation of the glans penis and since also the prepuce is often affected, the term balanoposthitis may be used, too. Posthitis refers to inflammation of the prepuce. Balanitis/balanoposthitis has varying aetiologies but the clinical presentation is often similar.

Epidemiology

Balanitis/balanoposthitis is one the most frequent male genital skin problems affecting both (at ages 2-5 years) pediatric patients and adults. Prevalence in males of all ages is between 12% to 20%. In adult men, uncircumcised males with diabetes mellitus have the highest prevalence of 35%. Circumcision considerably decreases the prevalence of inflammatory conditions of the glans penis.

Aetiology & Pathogenesis

The most common etiology of balanoposthitis is poor hygiene and preputial dysfunction is often a contributing factor. Balanitis/ balanoposthitis is uncommon in circumcised men. Balanitis/balanoposthitis may be caused by irritation, various types of infection or cutaneous autoimmune processes (see Classification below).

The pathophysiology can be irritant, allergic, infectious, autoimmune-mediated or secondary to trauma or malignancy. Many cases of balanoposthitis are 'intertrigo' in nature, i.e. inflammation between two adjacent skin layers with bacterial or fungal overgrowth. Also, many skin diseases, such as erythema multiforme and immuno-bullous disorders, may affect the glans penis and genitalia.

Lichen sclerosus is an inflammatory scarring skin condition for which an autoimmune pathogenesis has been postulated. The condition occurs in all ages. It is probably responsible for many cases of phimosis in childhood. Obesity, congenital and acquired anatomical abnormalities (hypospadias), piercing and urological surgery are predisposing factors.

Pre-malignant conditions include penile intraepithelial neoplasias (PeIN): Erythroplasia of Queyrat, Bowen's disease of the penis and Bowenoid papulosis, which are strongly associated with human papillomavirus infection and/or lichen sclerosus. All may progress to squamous cell carcinoma (SCC), the risk being greatest for Erythroplasia of Queyrat (10-40%). In immunocompromised patients the risk is increased (e.g. HIV infection, immunosuppressive medication). Notably, SCC presenting as an irregular tender or painful ulcer or nodule may coexist with PeIN and lichen sclerosus.

Signs & Symptoms

The symptoms and signs vary according to the aetiology.

Candidal balanoposthitis is a common cause of balanoposthitis in children. It presents as blotchy erythema with small papules (may be eroded), or dry dull red areas with a glazed appearance with soreness and/or itch. In adults, candida may often be secondary to primary inflammatory dermatoses.

Bacterial infection presents as uniform erythema with eventual oedema and transudative or exudative preputial discharge. Anaerobic subpreputial infection typically yields a foul smelling and discharge with preputial oedema and superficial erosions, sometimes accompanied by swollen inguinal lymph nodes.

Irritant / allergic balanitis-balanoposthitis presents as mild erythema with or without pruritus. It may result from irritation such as frequent genital washing with soap, a history of atopy, or exposure to topical agents suggesting delayed hypersensitivity to e.g. common allergens (latex condoms, preservatives and fragrances) found in intimate hygiene products. **Seborrheic** balanitis presents with mild itch or redness. Fixed drug eruptions appear after using certain medications (tetracyclines,

phenolphthalein, phenacetin, NSAIDs, barbiturates or sulfa-drugs) present as round, erythematous patches that turn dark upon healing. Vesicles may occur.

Non-specific balanoposthitis is often chronic with relapses and remissions or persistence and there is no evidence of underlying infective cause.

Lichen sclerosus presents with itching, soreness, splitting, haemorrhagic blisters, dyspareunia, problems with urination including post micturition micro-incontinence or dribbling but may also be asymptomatic. The appearance is lichenoid (lilac) balanoposthitis with white patches on the glans, often with involvement of the prepuce. There may be haemorrhagic vesicles, purpura and rarely blisters and ulceration. Tissue changes such as blunting of the coronal sulcus, destruction of the frenulum, phimosis or 'waisting' of the prepuce (constrictive posthitis), and meatal thickening and narrowing, often develop. In contrast with female LSA, perianal disease is rare.

Lichen planus may be asymptomatic but appears purplish with well demarcated plaques on the glans and prepuce and on the shaft of the penis, or may present as erosive or annular lesions on the mucosal surfaces. Mucosal lichen planus is often a chronic condition with remissions and exacerbations.

Psoriasis appearing on the glans presents as red scaly plaques. In the uncircumcised scaling is lost and the patches appear red and glazed. The glazed appearance resembles pre-malignant Bowen's disease and extramammary Paget's disease and other inflammatory conditions.

Zoon's (plasma cell) balanitis is a disease of uncircumcised males aged 40 years or older. It presents with well-circumscribed orange-red glazed areas on the glans and the inside of the foreskin, with multiple pinpoint redder spots - "cayenne pepper spots" in a symmetrical distribution. It is thought to be due to irritation, partially caused by urine, in the context of a 'dysfunctional prepuce'. It is generally regarded as a benign condition. Zoonoid inflammation (clinically and histologically) frequently complicates other dermatoses, including precancer and cancer, but especially lichen sclerosus.

Circinate balanitis may occur sporadically or as a sign of the post infective Reiter's disease (triggered by urethritis or enteritis in genetically predisposed individuals). It may also occur in association with HIV infection. It has a typical appearance of greyish white areas on the glans which coalesce to form "geographical" areas with a white margin.

The premalignant lesions locate on the prepuce (45%), glans (38%) or shaft of the penis (3%).

Erythroplasia of Queyrat (PeIN of the balanopreputial epithelium) appears as red, velvety, well-circumscribed area on the glans or visceral prepuce.

Bowen's disease (PeIN of keratinised, hair-bearing, skin) appears as scaly, discrete, erythematous patches or plaques and bowenoid papulosis, usually in younger patients than the two aforementioned, appears as firm papules to plaques, often grouped and pigmented or erythematous.

Localisation

Glans penis and/or prepuce (foreskin).

Classification

The balanitis/balanoposthitis is classified in three main groups based on the etiopathogenesis. Infective balanoposthitis may be caused by viral infections such as Human papillomavirus (HPV) and Herpes simplex virus (HSV), fungal infections including *Candida* spp, and bacterial infections such as *Staphylococcus* spp or *Streptococcus* spp. Sexually transmitted infections such as *Trichomonas vaginalis*, syphilis and *Mycoplasma genitalium* may also cause balanoposthitis.

Inflammatory balanoposthitis group includes lichen sclerosus, lichen planus, psoriasis and circinate balanitis, Zoon's balanitis, eczema (irritant allergic or seborrheic), allergic reactions (including fixed drug eruptions).

Penile intraepithelial neoplasia (PeIN) is a premalignant precursor lesion of invasive penile SCC, a SCC in situ. It includes Bowen's disease, Bowenoid papulosis and Erythroplasia of Queyrat. In 2016, the World Health Organization (WHO) introduced a new pathological classification of PeIN based on aetiology, with two main pathways for malignant transformation, one named "undifferentiated PeIN" based on HPV-induced carcinogenesis, and the other one "differentiated PeIN" derived from inflammatory lichen sclerosus (LS) and lichen planus (LP). Transformation of a premalignant lesions transform to invasive cancer occurs in 10-30% of cases in PeIN, with the glans and inner prepuce having the highest risk. Penile cancer is rare but aggressive.

Notably, a range of skin diseases may affect the glans penis and genitalia. These include psoriasis, erythema multiforme, immuno-bullous disorders (e.g. pemphigus) and dermatitis artefacta.

Laboratory & other workups

The duration of symptoms, clinical appearance, hygiene habits, infectious exposures, potential allergens, and sexual practices need to be clarified before deciding which laboratory examinations to select.

Sub-preputial swab for *Candida* and bacterial cultures (e.g. *Gardnerella vaginalis* as a facultative anaerobe), urinalysis for glucose (if candidal infection suspected), *Trichomonas vaginalis* nucleic acid amplification test (NAAT) if a female partner has an undiagnosed vaginal discharge, full routine screening for other STIs and particularly *Chlamydia trachomatis* infection / non-specific urethritis if a

circinate-type balanitis is present.

If ulceration is present, HSV and *Treponema pallidum* NAAT and/or examination for spirochaetes (see Syphilis chapter) or syphilis serology with follow up at 3 months need to be performed.

Testing for HLAB27 in case of circinate balanitis. If contact allergy is suspected, patch testing with common allergens.

A penile biopsy should be performed if features are atypical or do not resolve with treatment and if lichen sclerosus or Zoon's plasma cell balanitis is suspected. Biopsy should be carried out by an experienced practitioner, to obtain a representative sample and to avoid unnecessary risks.

Dermatopathology

Not needed for infectious balanoposthitis patients.

In lichen sclerosus, histopathology initially shows a thickened epidermis which later becomes atrophic with follicular hyperkeratosis. In dermis, a band of hyalinisation with loss of the elastin fibres, with an underlying perivascular lymphocytic infiltrate is seen. Histological interpretation can be difficult and needs clinico-pathological correlation. A negative biopsy result does not exclude lichen sclerosus, and a positive biopsy does not necessarily exclude PeIN elsewhere.

Lichen planus histology shows irregular saw-toothed acanthosis, increased granular layer and basal cell liquefaction and a band-like dermal lymphocytic infiltrate. Biopsy may be necessary also to distinguish the glazed appearance lesions of penile psoriasis, which can look similar to pre-malignant conditions.

Fixed drug eruptions show hydropic degeneration of the basal layer and epidermal detachment and necrosis with pigmentary incontinence. Circinate balanitis shows spongiform pustules in the upper epidermis, similar to pustular psoriasis.

In Zoon's plasma cell balanitis, epidermal thickening first occurs and is followed by epidermal atrophy (with erosions). Often mild epidermal oedema is seen with a predominantly plasma cell infiltrate in the dermis with haemosiderin deposition and extravasated red blood cells. However, a Zoonoid inflammation may complicate other dermatoses and 'positive' biopsy findings do not confirm the diagnosis or exclude neoplasia.

In PeIN the squamous epithelium shows dysplastic changes. PeINs are morphologically divided into four subgroups: differentiated PeIN (most prevalent), warty-basaloid, basaloid and warty morphology.

Course

Acute balanitis is often caused by infectious agents and most balanitis cases recover with treatment. The majority of patients without an infectious etiology will respond to changes in hygiene and therapy with emollients within one to two weeks. Balanitis relapses are common in men who are not circumcised and if good hygiene, such as cleaning under the foreskin, is not practiced.

Complications

Severe balanitis may be complicated by phimosis and urinary retention. Fever and malaise may also occur. If symptoms recur or are refractory to treatment after four weeks, present with pathologic phimosis or urinary obstruction, the patient should be referred to a urologist. Balanitis has often a profound effect on the patient's sexual life and may cause substantial psychosocial problems.

Diagnosis

The diagnostic entity includes the following procedures and examinations: sexual history, medication, presence of phimotic and urethral discharge, urinary retention, clinical appearance of lesions, inguinal lymphadenitis, testicular status. A dermatological examination for skin diseases (like psoriasis) and history of possible contact or drug allergy (e.g. erythema fixum). If contact allergy is suspected, patch testing with common allergens needs to be performed. For laboratory and histopathological examinations, see paragraph "Laboratory" above.

Differential Diagnosis

Biopsy may be needed if the diagnosis is uncertain and the condition persists or to exclude a pre-malignant condition. Differential diagnosis includes some common dermatological diseases which may affect the male genitalia, such as psoriasis, lichen planus, erythema multiforme, autoimmune bullous diseases and fixed drug reaction as discussed in this chapter. Notably, syphilis lesions may resemble circinate balanitis. Artefactual dermatitis and traumatic lesions must be differentiated, too.

Prevention & Therapy

Predisposing factors for balanoposthitis include poor hygiene, non-retraction of the foreskin, and some medical conditions such as diabetes mellitus. Good personal hygiene, washing daily, avoiding irritants (including soap), and keeping the foreskin retracted until the glans penis is dry (risk of paraphimosis if the prepuce is tight) are recommended. Attention should be paid to risk factors for PeIN, which include lichen planus, inflammation of the glans, genital warts, obesity and immunosuppressive drugs (e.g. organ transplantation).

Treatment depends on the causative agent or condition.

Nonspecific balanoposthitis is the most common etiology in children and is due to poor hygiene. Treatment involves gentle cleaning of the area 2 to 3 times per day by retracting the foreskin and cleaning with gentle use of cotton swab. Forceful prepuce retraction should be avoided in case of phimosis. Symptoms usually resolve within five days.

Candidal balanoposthitis is treated with clotrimazole or miconazole cream, twice a day for 7-14 days. Topical imidazole with 1% hydrocortisone is a choice if marked inflammation is present. Alternatively, fluconazole 150 mg orally can be used if symptoms are severe and nystatin cream if the patient has allergy to imidazoles. Sexual partners should also be tested for candida or offered empiric anti-candidal treatment to reduce the reservoir of infection in the couple.

Aerobic bacterial balanoposthitis is usually treated topically with mupirocin cream twice a day or with clobetasone butyrate /oxytetracycline/ nystatin-cream once or twice daily for 7-10 days. Severe cases may require systemic antibiotics while awaiting culture results: flucloxacillin 500 mg x4/ d or clarithromycin 250 mg twice daily for seven days. Management of anaerobic subpreputial infection includes improved genital hygiene, topical or oral metronidazole 400-500 mg twice daily for one week. Alternatively, co-amoxiclav 375 mg three times daily for one week or clindamycin cream twice daily until resolved.

Balanoposthitis caused by HSV, *Trichomonas vaginalis*, *Mycoplasma genitalium* or syphilis is treated as per specific guidelines for these diseases.

Irritant / allergic balanitis-balanoposthitis is treated by the avoidance of precipitants like soaps, use of low-allergy products, emollients (used as a soap substitute), hydrocortisone once or twice daily until resolution of symptoms. In florid cases more potent topical steroids, combined with antifungals and/or antibiotics, or calcineurin inhibitors may be required. Follow up is not required, although recurrences are common. Potential allergens such as latex condom use and lubricants, should be investigated and avoided.

Fixed drug eruptions are treated symptomatically with mild to moderate steroid creams, since the lesions will heal without treatment after discontinuation of the culprit drug. However, the lesions return on the same location if the culprit medication is resumed.

Balanitis due to seborrheic dermatitis is treated with topical antifungal cream with a mild to moderate steroid. Psoriasis on the penis can be treated with moderate potency topical steroids (+/- antibiotic and antifungal), emollients, calcipotriol or calcitriol (applied twice daily). Circinate balanitis is treated similarly and any underlying infection must be treated, too.

Lichen sclerosus is managed by soap-free washing, avoidance of contact with urine, barrier preparations, weight loss and removal of any genital jewellery. Topically, ultrapotent topical steroids

(e.g. clobetasol propionate) is applied twice daily for a month, then ceased and replaced with a barrier preparation. Intermittent use to maintain remission is not encouraged. Secondary bacterial or candidal infection should be treated. Alternatively, topical calcineurin inhibitors (e.g. pimecrolimus) may be used. Circumcision is indicated if topical treatment fails. Follow up is advisable, since there is risk of recurrence, urethral disease or neoplastic change.

Lichen planus may affect the genital area in addition to the skin and oral mucous membranes. Certain drugs, most frequently ACE-inhibitors, beta blockers, NSAIDs and thiazide diuretics, and biologics may cause lichen planus like eruptions. For the treatment of lichen planus, see the corresponding chapter.

Zoon's (plasma cell) balanitis, regarded as a benign condition, is thought to be due to irritation, partially caused by urine, in the context of a 'dysfunctional prepuce'. In therapy, good hygiene, management of underlying dermatoses, topical steroid creams and antibacterial creams (e.g. mupirocin) applied twice daily are used. Alternative topical treatments include calcineurin inhibitors (pimecrolimus twice daily, not for continuous use) and imiquimod 5% cream. Laser ablation may be used to treat individual lesions and circumcision is an alternative for recalcitrant lesions.

Premalignant penile lesions, PeIN, should be referred to specialists in dermatology and urology/andrology. A combined, sequential approach is often needed, taking into account age, circumcision status, site/sites, comorbidities, concomitant immunosuppression and the pathogenesis (HPV and/or lichen sclerosus) and histology (differentiated or undifferentiated type). For topical therapy imiquimod 5%, fluorouracil cream 5%, fluorouracil 0.5% / salicylic acid 10% combination or podophyllotoxin 0.5% are alternatives. Local surgical excision (usually adequate and effective), cryotherapy, photodynamic therapy or laser treatment are often needed, too. Circumcision is used for balanopreputial disease, especially for uncircumcised high-risk patients (HIV, transplant recipient etc.) to avoid recurrence. Additionally, polyvalent HPV vaccination and smoking cessation are recommended. Follow up is mandatory because of the risks of field change and recurrence (up to one third of patients may harbour microinvasive disease), except for circumcised patients with Bowenoid papulosis or PeIN confined to the prepuce.

Special

Lichen sclerosus may be complicated by phimosis and paraphimosis, urethral stenosis, penile intraepithelial neoplasia (PeIN) or even malignant transformation to squamous cell carcinoma. In established penis cancer the association with lichen sclerosus is thought to be about 50% (the other 50% being associated with HPV). Surgery, such as circumcision, meatotomy, glans resurfacing, urethroplasty and bariatric surgery, may be indicated to address symptoms due to persistent phimosis or meatal stenosis and urethral disease.

References

- [Edwards SK, Bunker CB, van der Snoek EM, van der Meijden WI. \(2023\). 2022 European guideline for the management of balanoposthitis. J Eur Acad Dermatol Venereol. Jun;37\(6\):1104-1117. doi: 10.1111/jdv.18954. Epub 2023 Mar 21. PMID: 36942977.](#)
- [Nemirovsky DR, Singh R, Jalalian A, Malik RD. \(2022\). Urologic dermatology: a comprehensive foray into the noninfectious etiologies of balanitis. Int J Dermatol. Dec;61\(12\):1467-1478. doi: 10.1111/ijd.15985. Epub 2021 Nov 26. PMID: 34826136.](#)
- [Dayal S, Sahu P. \(2016\). Zoon balanitis: A comprehensive review. Indian J Sex Transm Dis AIDS. Jul-Dec;37\(2\):129-138. doi: 10.4103/0253-7184.192128. PMID: 27890945](#)

Chapter 5 - Diseases of Blood and Lymph Vessels, Ulcers and Panniculitis

5.1 Vascular Diseases

5.1.1 Allergic vasculitis

Grading & Level of importance: B
M Bagot, Paris; G. Gabor, Paris; A. de Masson, Paris



ICD-11

Leukocytoclastic vasculitis: 4A44.B

Synonyms

Hypersensitivity vasculitis; Immunologic type III vasculitis.

Definition

Allergic vasculitis is a small vessel damage, usually caused by immune complex deposition in postcapillary venules (Type III reaction of the Gell and Coombs classification), leading to palpable purpuric lesions.

Epidemiology

Allergic vasculitis is one of the most frequent forms of vasculitis.

Aetiology & Pathogenesis

Deposition of immune complexes (variable amounts of antibodies and antigens in their proportion to each other) in the small vessel walls, leads to complement activation, activation of granulocytes and extravasation (leucocytoclasia) and finally microthrombosis of the small vessels.

Triggers include infections (HIV, HCV, bacteria), autoimmune and inflammatory diseases (connective tissue disease, ANCA-associated vasculitis, inflammatory bowel disease), medications, tumor associated antigens (solid tumors, haematological). In almost 50% of the cases no trigger is found.

Frequent triggering factors are:

1. Medications
2. Infections: bacteria (especially streptococci), viruses (e.g., hepatitis C, HIV).
3. Chronic inflammatory and autoimmune diseases such as connective tissue diseases, inflammatory bowel disease, ANCA-associated vasculitis (granulomatosis with polyangiitis, eosinophilic granulomatosis with polyangiitis). Special variant: Schönlein-Henoch purpura (primarily in children) with deposition of IgA immune complexes.
4. Malignancies: myeloproliferative disorders, lymphomas, multiple myeloma.

Signs & Symptoms

Initial symptoms of allergic vasculitis include palpable purpura, which may later become necrotic and sometimes urticarial and nodular lesions. Internal organ involvement (kidneys, GI tract, joints, nervous system) with corresponding symptoms may occur. Arthralgia, low-grade fever and abdominal pain may be present in Schönlein-Henoch purpura.

Localisation

Allergic vasculitis is typically localized on the lower legs. Lesions generally predominate on the distal extremities.

Classification

Allergic vasculitis can be separated into purely cutaneous forms (single organ vasculitis) and systemic forms (multi-organ vasculitis).

Laboratory & other workups

In allergic vasculitis, first of all, systemic involvement should be assessed and a potential underlying disease should be determined.

- Parameters reflecting internal involvement: urinalysis (proteinuria, urine cytobacteriology), elevated creatinine levels, BUN, faecal occult blood, liver function, complete blood count and platelets count.
- Parameters reflecting inflammation: C-reactive protein, erythrocyte sedimentation rate, leukocyte count.
- Parameters reflecting aetiology: CBC with differential, platelet count, antistreptolysin antibody titre, hepatitis serologies (VHB, VHC), HIV test, ANA, anti-dsDNA antibodies, anti-extractable nuclear antigens antibodies, complement levels, RhF, ANCA, IgA, cryoglobulinemia, blood cultures in any case of suspicious endocarditis, ASCA.

Dermatopathology

Early stages may show perivascular lymphocytes, macrophages and apoptotic leucocytes (“leucocytoclasia”, nuclear dust). Eosinophilic granulocytes may be present. Postcapillary venules may have swollen endothelia with fibrin deposition leading to erythrocyte extravasation. Microthrombosis of the small vessels may cause necrosis of the surrounding tissue.

IgG and IgM deposition may be found by direct skin immunofluorescence, whereas IgA deposition is more characteristic of Schönlein-Henoch purpura.

Course

The course of allergic vasculitis may be acute, subacute, chronic or recurrent.

Complications

Allergic vasculitis may affect internal organs depending on the underlying cause.

Glomerulonephritis (with possible renal insufficiency), circumferential wall thickening and gastrointestinal haemorrhage may occur in Schönlein-Henoch purpura.

Diagnosis

Allergic vasculitis is diagnosed based on the clinical manifestations and skin histology. Laboratory tests (renal and aetiological workup) are also required as well as imaging of the inner organs depending on the clinical presentation (abdominal sonography or tomodesitometry).

Differential Diagnosis

Differential diagnoses of allergic vasculitis include

- thrombotic diseases (cryoproteinemia, antiphospholipid syndrome, cold agglutinins),
- thrombocytopenia clotting factor deficiency, including blood thinners,
- embolic disorders (cholesterol emboli, atrial myxoma) and
- septic-embolic diseases (endocarditis).

Prevention & Therapy

The treatment includes avoidance of triggers, bed rest, medication (systemic corticosteroids) depending on the etiology and internal organ involvement. Anti-coagulants in some specific cases.

Special

None.

References

- [Alpsoy E. \(2022\) Cutaneous vasculitis; An algorithmic approach to diagnosis. Front Med \(Lausanne\). Sep 21;9:1012554](#)
- [Frumholtz L, Laurent-Roussel S, Lipsker D, Terrier B. \(2021\) Cutaneous Vasculitis: Review on Diagnosis and Clinicopathologic Correlations. Clin Rev Allergy Immunol.Oct;61\(2\):181-193.](#)
- [Cord H Sunderkötter, Bernhard Zelger, Ko-Ron Chen, Luis Requena, Warren Piette et al \(2018\). Nomenclature of Cutaneous Vasculitis: Dermatologic Addendum to the 2012 Revised International Chapel Hill Consensus Conference Nomenclature of Vasculitides Arthritis Rheumatol 70\(2\):171- 184.](#)
- [Lutze S, Westphal T, Jünger M, Arnold A. \(2023\). Microcirculation disorders of the skin.JDDG: 2023;1-27.](#)

5.1.2 Varicose Veins and Chronic Venous Insufficiency

Grading & Level of importance: B
A. Altenburg, Dessau; C.C. Zouboulis, Dessau



ICD-11

BD74.1

Synonyms

Varicosis, varicosity, chronic venous disease, chronic peripheral venous insufficiency.

Definition

Ectatic changes in the superficial veins due to insufficient valves.

Epidemiology

17% of adults and 37% of those over the age of 70 have chronic venous insufficiency (CVI).Varicose

veins: 37% in females, 19% in males.

CVI: 20% in females and 17% in males.

Aetiology & Pathogenesis

Primary varicosities (95%): Familial predisposition, prolonged (occupational) standing, multiple pregnancies, obesity and smoking all lead to dilatation of the veins and incompetence of the venous valves with reflux and increased venous stasis.

Secondary varicosities (5%): Postinflammatory or post-thrombotic changes.

Signs & Symptoms

Stages of chronic venous insufficiency (by Widmer):

- Stage I: corona phlebectatica paraplantaris (prominent dilated vessels along sides of foot)
- Stage II: atrophie blanche, deposition of haemosiderin, hyperpigmentation, dermatoliposclerosis, stasis dermatitis, eczema, indurated edema
- Stage III: ulcer (active or healed)

Further clinical symptoms: pain, itching, leg heaviness.

Symptoms are in more detail described in the CEAP classification (essential classification).

Localisation

Venous system of the lower legs:

- Truncular
- Epifascial varices: Areas drained by the great or small saphenous veins and accessory branches, localizations of perforant veins (e.g. medial lower leg).

Cutaneous varices with cosmetic relevance.

Reticular varices: Reticular superficial venectasia with a diameter of 2-4 mm; preferably on the back of the knee and lateral leg

- Spider veins: Intradermal telangiectasia with diameter <1 mm; most common on the inner aspect of the calves and the back of the thighs. Correspond to corona phlebectatica on the sides of the feet.

Classification

International standard classification for chronic venous disease:

- CEAP (clinical-etiology-anatomy-pathophysiology): Clinical signs (0–6) supplemented by (A) for asymptomatic and (S) for symptomatic patients, Etiologic classification: congenital (C), primary (P), secondary (S), Anatomic distribution: superficial (S), deep (D), or perforating veins (P), or combinations, Pathophysiologic dysfunction: reflux (R) or obstruction (O), alone or in combination.
- Grading of truncal vein incompetence of the greater and lesser saphenous vein according to Hach: Greater saphenous vein: grade I-IV, lesser saphenous vein: grade I: -III.
- Widmer's classification of varicose veins 1. teleangiectatic veins 2. reticular varicose veins 3. truncular varicosities: greater or lesser saphenous vein and their branches.

Laboratory & other workups

Imaging techniques: Duplex sonography, doppler sonography, photoplethysmography, hyperspectralimaging, infrared thermography.

Dermatopathology

Usually not necessary, except in situations like capillary convolutes mimicking Kaposi's sarcoma.

Course

Chronic over years.

Complications

Ulcer, stasis dermatitis and/or contact dermatitis, superficial thrombosis, bleeding, deep vein insufficiency.

Diagnosis

Clinical findings. Palpation of the insufficient visible veins, imaging techniques.

Differential Diagnosis

Congenital vessel malformation. Dermatitis of different causes.

Lower leg eczema: Allergic contact dermatitis, asteatotic, nummular dermatitis, skin mycosis, psoriasis.

Prevention & Therapy

Leg training programme with activation of the foot, lower leg and upper leg muscle system. Movement at working place. In the evening resting legs by moving up.

Compression therapy: 90% of venous ulcers heal with adequate compression therapy. Note: If arterial disease is also present, compression may be contraindicated.

Truncal varicosities: surgery (ligation and stripping), endovenous laser ablation, radiofrequency, sclerotherapy, combination of treatments Accessory varicosities: Surgery or sclerotherapy. Spider veins: Sclerotherapy or laser destruction.

Accessory varicosities: Surgery or sclerotherapy. Spider veins: Sclerotherapy or laser destruction.

Special

In young men with CVI, think of Klinefelter's syndrome.

References

- [Lutze S, Westphal T, Jünger M, Arnold A. \(2023\). Microcirculation disorders of the skin. JDDG: Journal der Deutschen Dermatologischen Gesellschaft; 127.](#)
- [Khilnani NM, Davies AH. \(2020\). CEAP: A review of the 2020 revision. Phlebology; 35\(10\):745-748. doi:10.1177/0268355520961239](#)
- [Eberhard Rabe, Catherine Régnier, Fabienne Goron, Ghislaine Salmat & Felizitas Pannier \(2020\). The prevalence, disease characteristics and treatment of chronic venous disease: an international web-based survey. J. Comp. Eff. Res 9\(17\), 1205–121](#)

5.1.3 Lymphangitis

Grading & Level of importance: B
C.C. Zouboulis, Dessau



ICD-11

BD91

Synonyms

None.

Definition

Inflammation along the lymphatic pathways between a site of cutaneous inflammation / infection / infarction and the regional lymph nodes.

Epidemiology

No clear statistical data available.

Aetiology & Pathogenesis

Most common cause is bacterial infection, leading to ascending infection of lymphatics draining to regional lymph nodes. It is usually a complication of soft tissue bacterial infections. Lymphangitis most often results from an acute streptococcal infection of the skin. Less often, it is caused by a staphylococcal infection. Lymphangitis may be a sign that a skin infection is getting worse, initiating bacteraemia and sepsis. Non-infectious inflammatory processes, such as an arthropod bite or sting (filariasis and onchocerciasis), can also cause lymphangitis/lymphadenitis. Lymphangitis has also been seen in patients with Crohn's disease. Tumor cell infarction causes lymphangitis carcinomatosa. Breast, lung, stomach, pancreas, rectal, and prostate cancers are common types of tumors that can lead to lymphangitis.

Signs & Symptoms

Linear, tender erythema between the primary skin lesion (entry point for infection, site of bite or sting, tumor infarction) and the regional lymph nodes and throbbing pain along the affected area. Additionally, fever and chills, enlarged and tender lymph nodes, malaise, headache, loss of appetite and muscle aches may occur as general symptoms.

Localisation

Mostly on extremities, sometimes trunk.

Classification

- Bacterial lymphangitis
- Infestation-induced lymphangitis
- Sclerosing lymphangitis (of the penis)
- Lymphangitis carcinomatosa

Laboratory & other workups

Inflammatory markers, bacterial swabs of entry point, regional lymph node sonography, tumor staging.

Dermatopathology

Depending on cause widening of vessels and accumulation by neutrophils and positive staining for bacteria or nodular lymphatic vessels like in sporotrichosis (PAS stain). In cancerous lymphangitis the lumen of vessels is filled with tumor cells which can be stained by immunohistochemistry according to suspected tumor origin.

Course

Acute. Usually responds rapidly to antibiotic therapy.

In tumor association chronic progressive. Lymph vessels may become occluded and lymphedema occurs.

Complications

The primary site can evolve into an abscess. Development of cellulitis or sepsis. Chronic lymphedema (filariasis, relapsing erysipelas).

Diagnosis

Clinical findings, microbiology. Possibly duplex sonography to exclude superficial thrombophlebitis or tumor.

Differential Diagnosis

Superficial thrombophlebitis.

Prevention & Therapy

Antibiotic and antimycotic therapy, intravenous in severe cases. Start with empiric regimen based on likely causes and adjust with culture results. Treat the entry site (incision, debridement, drainage, disinfection). In severe cases: bed rest, thromboprophylaxis with fractionated heparin. Topical: cool compresses. Treatment of infestation, tumor surgery (primary tumor) or systemic antitumor therapy (metastases). Pain medication, anti-inflammatory medication, surgery to drain any abscesses that may have formed, surgical debridement, or removal, of a node (if it causes obstruction) may be required in severe complicated cases.

Special

Special location: sulcus beneath glans on penis (sclerosing lymphangitis). Differential diagnosis: Mondor's disease.

References

- [Kano Y, Momose T. \(2020\). Acute lymphangitis. Cleve Clin J Med. Mar;87\(3\):129-130. doi: 10.3949/ccjm.87a.19095. PMID: 32127433.](#)
- [Gasper, Warren J., et al. \(2022\). "Lymphangitis & Lymphadenitis." Current Medical Diagnosis & Treatment Eds. Maxine A. Papadakis, et al. McGraw-Hill Education, 2022, <https://accessmedicine.mhmedical.com/content.aspx?bookid=3081§ionid=258962646>](#)

5.2 Ulcers

5.2.1 Venous leg ulcers

Grading & Level of importance: B

A. Altenburg, Dessau; H. Gollnick, Magdeburg; C.C. Zouboulis, Dessau



ICD-11

BD74.3

Synonyms

Varicose or stasis ulcers.

Definition

A chronic ulcer on the lower leg between knee and ankle joint resulting from improper functioning of venous valves and advanced chronic venous insufficiency (CVI). They are the most common cause of leg ulcers at all.

Epidemiology

Prevalence of all leg ulcers: 1-2% in the general population, 4-5% of individuals older than 80 years. CVI is considered to cause 60-80% of leg ulcers, mixed venous-arterial insufficiency (PAOD) is the cause in 10-20%.

Aetiology & Pathogenesis

The common denominator of venous ulcers is ischaemia of the upper dermis. Ulcers occur in superficial CVI (30-40%), such as marked insufficiency of the great saphenous vein, combined superficial and deep CVI, deep CVI (60-70%), post-thrombotic syndrome (50-60%) of patients with a venous ulcer have post- thrombotic syndrome.

Venous hypertension is the first factor followed by fibrin cuff and inflammatory cytokine release. Thereafter, leukocytes get trapped in the capillaries releasing proteolytic enzymes and reactive oxygen metabolites, which finally cause endothelial damage. In certain cases thrombophilia like factor V Leiden mutation, prothrombin mutations, deficiency of antithrombin, presence of antiphospholipid antibodies, protein C and S deficiencies and increased homocystein are co-morbidities complicating and driving the disease.

Signs & Symptoms

Moderate pain, which improves on elevation (unlike in PAOD).

Irregular edges, associated oedema due to increased hydrostatic pressure, which contributes to 'atrophie blanche', pigmentation, associated superficial CVI.

Localisation

Peri-malleolar i.e. anterior to medial malleolus, pretibial area, lower third of leg and almost always medial.

Classification

CEAP: Clinical class 5: inactive (healed) ulceration, clinical class 6: active ulceration. CVI stage III by Widmer: Active or healed ulceration.

Laboratory & other workups

Several. Swaps for microbial contamination. Rule out neuropathic (nylon filament test) and arterial (Doppler ultrasound) evidence. Functional tests such as duplex ultrasound, photoplethysmography.

Dermatopathology

Biopsies from the edge of the wound should be considered if an ulcer does not respond or responds inadequately to therapy and has an atypical appearance.

Course

- Chronic, recurrent. Duration of more than 1 year - recurrence rate in these ulcers is more than 70%
- larger wounds
- fibrin in >50% of wound surface
- ankle-brachial pressure index (ABPI) <0.8
- history of venous stripping/ligation and relapse.

Complications

- Dermatoliposclerosis.
- Cellulitis (erysipelas) with an ulcer as the entry site. Recurrent cellulitis is often relatively asymptomatic but may lead to
- chronic lymphedema and further impaired drainage.
- Allergic and irritative or protein dermatitis. In particular, the common allergic contact sensitizers such as lanolin, topical antibiotics (gentamycin, neomycin, bacitracin), antiseptics, preservatives, emulsifiers, resins and latex are responsible.
- Other factors are not sufficiently working muscle pumps (ankle, calf)

Diagnosis

Additional clinical findings: Oedema, atrophie blanche, varicose vein(s).

Identification of CVI: duplex (first choice), phlebography, doppler sonography: only low sensitivity. For the assessment of the deep venous system the systolic ankle-brachial-pressure index for ruling out concomitant PAOD is recommended.

Differential Diagnosis

Vascular: PAOD, lymphatic vasculitis.

Haematological diseases: sickle cell anaemia, thalassaemia.

Infections: bacterial ecthyma; mycobacterial - TB and leprosy; gumma (syphilis); parasitic (tropics); fungal (tropics).

Traumatic/physical.

Autoimmune: pyoderma gangrenosum, vasculitis, antiphospholipid antibody syndrome, systemic sclerosis, localized bullous pemphigoid, rheumatoid arthritis.

Metabolic/endocrine: necrobiosis lipoidica, calciphylaxis, diabetes mellitus. Iatrogenic: radiation

dermatitis, hydroxyurea treatment.

Neoplasia: Primary ulcerated skin tumours: malignant melanoma; squamous cell carcinoma; basal cell carcinoma. Secondary: skin metastases; malignant change in chronic ulcer (squamous cell carcinoma). Congenital: Klinefelter's syndrome, dysgenesis of the venous valves, primary lymphoedema.

Prevention & Therapy

- Improve general factors: Anaemia, hypoalbuminaemia, diabetes mellitus. Nutrition and physical activity should be optimized.
- Improve venous return by muscle pump activation and compression. No bed rest.
- Multicomponent compression systems are more effective than single-component compression systems; High compression is more effective than lower compression; Medical compression stockings are more effective than compression with short stretch bandages.
- Stripping of varicosities, selective vein surgery, endovascular ablative techniques and sclerotherapy.
- Necrotomy reduces the level of contamination and speeds up granulation. Maggots can be used in the early treatment phase.
- Enhance granulation in moist milieu. Encourage re-epithelialisation in non-occlusive, semi-moist milieu.
- Skin grafting when sufficient granulation tissue is present.

Special

Costs: Venous leg ulcers account for about 1% of health care budgets in Western countries.

References

- [Alavi A, Sibbald RG, Phillips TJ, Miller OF, Margolis DJ, Marston W, Woo K, Romanelli M, Kirsner RS. \(2016\). What's new: Management of venous leg ulcers: Treating venous leg ulcers. J Am Acad Dermatol; 74\(4\):643-664.](#)
- [Lutze S, Westphal T, Jünger M, Arnold A. \(2023\). Microcirculation disorders of the skin. JDDG: J. 1-27.https://doi.org/10.1111/ddg.15242](#)
- [Jockenhöfer F, Gollnick H, Herberger K, Isbary G, Renner R, Stücker M, Valesky E, Wollina U, Weichenthal M, Karrer S, Kuepper B, Roesch A, Dissemond J. \(2016\). Aetiology, comorbidities and cofactors of chronic leg ulcers: retrospective evaluation of 1 000 patients from 10 specialised dermatological wound care centers in Germany. Int Wound J. Oct;13\(5\):821-8. doi: 10.1111/iwj.12387. Epub 2014 Dec 5. PMID: 25483380](#)

- [Protz K, Heyer K, Dörler M, Stücker M, Hampel-Kalthoff C, Augustin M. \(2014\). Compression therapy: scientific background and practical applications. J Dtsch Dermatol Ges. Sep;12\(9\):794-801. doi: 10.1111/ddg.12405. Epub 2014 Aug 18. PMID: 25134422](#)
- [H.A.M. Neumann, A. Cornu-Thénard, M. Jünger, G. Mosti, K. Munte, H. Partsch, E. Rabe, A.-A. Ramelet, M. Streit \(2016\). Evidence-based \(S3\) guidelines for diagnostics and treatment of venous leg ulcers. JEADV, 30, 11 : 1843-1875](#)

5.2.2 Arterial leg ulcers

Grading & Level of importance: B
A. Altenburg, Dessau; C.C. Zouboulis, Dessau



ICD-11

BD52.Y

Martorell's ulcer: BD41.Y

Synonyms

None.

Definition

A chronic ulcer due to peripheral arterial occlusive disease (PAOD).

Epidemiology

Prevalence of all leg ulcers: 1-2% in the general population, 4-5% of individuals older than 80 years. PAOD is considered to be cause of leg ulcers in 5-10%, mixed CVI-PAOD in 20%. Ulcus hypertonicum Martorell, a special type of arterial ulcer, occurs in 5%.

Aetiology & Pathogenesis

Patients with arterial ulcers suffer from chronic limb ischemia. Frequent trigger is a minor trauma. Martorell's ulcer combines PAOD with hypertensive arteriopathy and skin infarction in patients with essential arterial hypertension.

Signs & Symptoms

Severe local pain.

Clinical description of ulcer:

- Ulcer base: Necrotic, fibrinous, granulating, epithelialising
- Ulcer border: Raised or flat, signs of re-epithelialisation, bland or inflamed, undermined, irregular/ polycyclic (Matorell's ulcer) or oval
- Perilesional skin: bland or inflamed, tender, warm, scaly, atrophic, sclerotic, brown (haemosiderin) and white (atrophie blanche) colour.

Localisation

Lateral side of the lower leg, proximal from (or including) the lateral malleolus or pretibial. Mixed CVI-PAOD ulcer: Medial and lateral at the same time.

Martorell's ulcer: Latero-dorsal or Achilles tendon area.

Classification

Fontaine stage IV and Rutherford stages III and IV define ulceration with distal necrosis.

Laboratory & other workups

None.

Dermatopathology

Biopsies from the edge of the wound should be considered if an ulcer does not respond or responds inadequately to therapy or has an atypical appearance.

Course

Chronic, progressive.

Critical ischemia: poor prognosis without re-vascularization (amputation and mortality).

Complications

Cellulitis (erysipelas) with an ulcer as the entry site.

Diagnosis

Clinical examination: Absent foot pulses, cold extremities, severe wound pain, claudicatio intermittens, rest pain, distal necrosis.

Investigations: Systolic ankle and toe pressure, ankle brachial index (ABI): 0.9 or less, transcutaneous oxygen pressure (tcPO₂), duplex sonography, angiography.

Differential Diagnosis

Vascular: CVI, lymphatic vasculitis.

Haematological: sickle cell anaemia, thalassaemia.

Infections: bacterial ecthyma; mycobacterial (TB, leprosy); gumma (syphilis); parasitic (tropics), fungal (tropics).

Traumatic/physical.

Autoimmune: pyoderma gangrenosum, vasculitis, antiphospholipid antibody syndrome, systemic sclerosis, localized bullous pemphigoid, rheumatoid arthritis.

Metabolic/endocrine: necrobiosis lipoidica, calciphylaxis. Iatrogenic: radiation dermatitis, hydroxyurea treatment.

Neoplasia: Primary ulcerated skin tumours: malignant melanoma, squamous cell carcinoma, basal cell carcinoma; Secondary: skin metastases, malignant change in chronic ulcer (squamous cell carcinoma).

Congenital: Klinefelter's syndrome, dysgenesis of the venous valves.

Prevention & Therapy

Topical treatment: Appropriate phase-adjusted therapy of chronic wounds: debridement (surgical, enzymatic), enhance granulation in moist milieu, encourage re-epithelialisation in non-occlusive, semi-moist milieu.

Medications improving arterial flow (PGE₁, vasodilators). Angioplasty stents, bypass surgery.

Martorell's ulcer: necrosectomy and split skin transplantation.

Special

5-10% of ulcers on lower leg are neuropathic (alcoholism, metabolic disorders such as diabetes mellitus, leprosy, neurosyphilis). Diabetes is found in 60% of patients with Martorell HYTILU.

References

- [Campia U, Gerhard-Herman M, Piazza G, Goldhaber SZ. Peripheral Artery Disease: Past, Present, and Future. Am J Med 2019; 132\(10\):1133-1141.](#)
- [Isoherranen K, O'Brien JJ, Barker J, Dissemond J, Hafner J, Jemec GBE, Kamarachev J, Läuchli S, Montero EC, Nobbe S, Sunderkötter C, Velasco ML. Atypical wounds. Best clinical practice and challenges. J Wound Care. 2019 Jun 1;28\(Sup6\):S1-S92.](#)
- [Läuchli, S., Streit, M. \(2023\). Leg Ulcers. In: Katsambas, A.D., Lotti, T.M., Dessinioti, C., D'Erme, A.M. \(eds\) European Handbook of Dermatological Treatments. Springer, Cham. <https://doi.org/10.1007/978-3-031-15130-9> 48](#)
- [Hafner J, Nobbe S, Partsch H, Läuchli S, Mayer D, Amann-Vesti B, Speich R, Schmid C, Burg G, French LE. Martorell hypertensive ischemic leg ulcer: a model of ischemic subcutaneous arteriosclerosis. Arch Dermatol. 2010 Sep;146\(9\):961-8. doi: 10.1001/archHafn](#)

5.2.3 Neuropathic Ulcers

Grading & Level of importance: C



G. Burg, Zürich

ICD-11

LW024

Synonyms

Neurotrophic ulcer, Acroosteopathia ulceromutilans, malum perforans.

Definition

Ulceration through the epidermal and dermal tissue layers in areas of physical/mechanical pressure on the basis of polyetiological sensory polyneuropathy. Foot is the most common localization, but other pressure points also can be affected. Disturbance of the “trophic of the tissue”, not of the venous or arterial circulation.

Epidemiology

Incidence >70 per 100,000 population. Prevalence up to 50 (6-51)% in patients with diabetes during their lifetime. There are no statistics on the epidemiology of malum perforans in late-stage syphilis,

leprosy or nerve injuries. Alcohol-induced malum perforans occurs exclusively in males with a distinct genetic disposition.

Aetiology & Pathogenesis

Sensory polyneuropathy with preference of thin nerve fibers on the basis of a genetic predisposition. Dissociated sensation deficit with loss of sensorium, motor weakness, and loss of autonomic function, thermo-, pressure- and pain-sensation. Inability to withdraw the area from painful stimuli such as friction, shear forces, or traumatic processes lead to hyperkeratosis, bleeding, ulceration and necrosis.

Potential causes are:

- Metabolic disorders: diabetes; rarely amyloidosis; monoclonal gammopathy; thyroid disease, renal disease, and chronic liver disease
- Alcohol (Bureau-Barrière-syndrome)
- Inflammatory, non-infectious: sarcoidosis, Sjogren's syndrome
- Infectious:
 - Syphilis (III/IV)
 - Leprosy
 - HIV
 - Borrelia infection (due to tick bite)
- Nerve trauma (Ischias)
- Neoplasms: Carcinoma
- Toxic: multiple vitamin deficiencies (B1, B6, B12), vitamin B6 excess, heavy metal poisoning, drug- induced neuropathy, organophosphate exposure, and alcohol use
- Hereditary (Thevenard-syndrome)

Signs & Symptoms

Numbness, tingling, pain, and weakness starting in the toes.

Loss of thermo- and pressure sensitivity and of pain. Formation of a localized hyperkeratosis with a hemorrhagic bulla and finally ulceration. Fractures of the underlying bones (foot or toes) (Acroosteopathia ulceromutilans). Hyperthermy of the involved limb with anhidrosis (diabetes) or hyperhidrosis (alcoholic polyneuropathy).

Localisation

Areas of mechanical pressure; preferentially heel and ball of the foot and toes, but also all other localizations exposed to mechanical or thermal damage.

Classification

According to aetiology. In diabetic foot ulcers Wagner's classification.

Laboratory & other workups

Detailed medical (trauma, surgery) and social (alcohol, infections, drugs) history.

Physical examination including vascular status, neurological status, and potential musculoskeletal abnormalities. Search for underlying disease.

Vascular examination: palpation of pulses in the area, ultrasound doppler, capillary refill time both peri-wound and distal to the ulceration.

Imaging methods (x-ray; MRI) to exclude bone injuries. Determination of the (severely reduced) nerve conduction velocity.

Orthopedic counseling.

Dermatopathology

Not indicated.

Course

Chronic; depending on the underlying disorder.

Complications

Superinfection; (painless) fractures; mutilation.

Diagnosis

Clinical picture of painless ulcer in conjunction with an underlying disorder (see aetiology).

Differential Diagnosis

Venous or arterial ulcers.

Prevention & Therapy

Prevention: avoidance and treatment of the aetiopathogenetic background. Tricyclic antidepressants; voltage-gated calcium channel ligands.

Since the polyneuropathy is irreversible (vitamin B-complex may be supportive in some instances), the only effective treatment is avoidance of pressure by appropriate orthopedic shoes. Plastic reconstructive surgery must be an exception, since the benefit is only temporarily.

Special

Cooperation with internal medicine and orthopedics.

References

- [Urso, B., Ghias, M., John, A., & Khachemoune, A. \(2021\). Neuropathic ulcers: a focused review. Int J Dermatol, 60\(10\), e383-e389. doi: 10.1111/ijd.15362. Epub 2020 Dec 17. PMID: 33332620.](#)
- [Clayton W Jr, Elasy TA. \(2009\). A Review of the Pathophysiology, Classification, and Treatment of Foot Ulcers in Diabetic Patients. Clin Diabetes 1 April; 27 \(2\): 52–58. https://doi.org/10.2337/diaclin.27.2.52](#)
- [Shah P, Inturi R, Anne D, Jadhav D, Viswambharan V, Khadilkar R, Dnyanmote A, Shahi S. \(2022\) Wagner's Classification as a Tool for Treating Diabetic Foot Ulcers: Our Observations at a Suburban Teaching Hospital. Cureus. Jan 22;14\(1\): e21501. doi: 10.7759/cureus.21501. PMID: 35223277; PMCID: PMC8861474.](#)

5.2.4 Pressure sore

Grading & Level of importance: B
A. Altenburg, Dessau; C.C. Zouboulis, Dessau



ICD-11

EH90.Z

Synonyms

Pressure ulcer, decubitus, decubital ulcer.

Definition

Pressure-induced defect of skin and subcutis.

Epidemiology

Prevalence: 10% of hospitalized patients (23% in hospitals in Europe) and 5% of patients requiring nursing care.

Aetiology & Pathogenesis

Ischaemia caused by prolonged pressure (>72 mm Hg) over bony prominences in patients who are unable to move and naturally avoid pressure. Two hours of ischaemia are sufficient to induce a pressure sore. Risk factors: bed-ridden patient, cachexia, paraplegia, unconsciousness, anaesthesia, shock, diabetes mellitus, anaemia. Since the musculature is even more sensitive to pressure than the skin and subcutis, cavitating wounds extending from below the skin to the periosteum may evolve.

Signs & Symptoms

Initial livid or bruise-like colour changes over the pressure points, reduced capillary refill. This stage is reversible. Later ulcers develop, involving skin, subcutis, muscles and often extending to the bones. Expanding cavitating defect, which is larger at its base. Foetid odour.

Localisation

Typical sites: sacrum, trochanters, heels, vertebral column, elbows, hands, back of head.

Classification

Stage I: Livid erythema (macule or patch), some capillary refill. Stage II: Ulcer to dermis.

Stage III: Ulcer with full thickness skin loss to subcutaneous fat.

Stage IV: Ulcer with exposed or directly palpable fascia, muscle, tendon, ligament, cartilage or bone.

Additional PI definitions: Medical device-related PI.

Laboratory & other workups

Inflammatory markers, reduced serum albumin. Imaging studies, possibly nutritional evaluation.

Dermatopathology

Biopsies of the ulcer margin (and possibly ulcer base) should be taken after 8 to 12 weeks of ulcers without tendency to heal, primarily to rule out tumors, vasculitis and other causes. Biopsy should be taken especially before invasive measures.

Course

If pressure is not relieved, relentlessly progressive. Risk of cellulitis and sepsis.

Complications

Progression, superinfection with mixed bacterial flora, often with anaerobes, cellulitis, sepsis, osteomyelitis.

Diagnosis

Clinical findings, assessment of depth with probe. Debridement. Imaging studies. Assessment of risk factors.

Differential Diagnosis

Neuropathic pressure ulcer, ulcerated tumours, chronic infections with fistula formation (for example, infected hip prosthesis).

Prevention & Therapy

Prevention is most important: Bed-ridden weak patients who cannot move adequately should be turned or shifted every two hours. Pillows should be employed to place patients in a 30° lateral position, as this simultaneously relieves pressure over the sacrum and trochanters. Offload heels with a prophylactic dressing or a pillow, without placing pressure on the Achilles tendon. Use textiles with low friction coefficients and consider specific single layer foam mattress or an alternating pressure air mattress or overlay. Optimize energy intake.

In stage I, the tissue damage is reversible. Immediate institution of pressure-relieving measures. Protection of damaged skin (e.g. hydrocolloid dressings). In stage II superficial tissue damage has occurred. Debridement of necrotic tissue and standard moist wound therapy. Appropriate antibiotic coverage.

In stages III and IV the actual extent of the tissue damage is often underestimated. Two hours of ischaemia are sufficient to induce a pressure sore. Extensive debridement, resection of the overhanging wound edges, vacuum-assisted wound therapy until adequate granulation is induced, then standard moist wound therapy. Pressure sores in stage III and IV often require reconstructive surgery.

Special

Consider the potential impact of impaired nutritional status, critical care stay, presence of medical devices and the impact of increased body temperature on pressure injury risk.

References

- [Cushing CA, Phillips LG. Evidence-based medicine: pressure sores. *Plast Reconstr Surg* 2013; 132\(6\):1720-1732.](#)
- [Hess, Cathy Thomas BSN, RN, CWCN. \(2020\) Classification of Pressure Injuries. *Advances in Skin & Wound Care* 33\(10\): p 558-559, | DOI: 10.1097/01.ASW.0000697324.90597.6d](#)
- [Zhang X, Zhu N, Li Z, Xie X, Liu T, Ouyang G. The global burden of decubitus ulcers from 1990 to 2019. *Sci Rep.* 2021 Nov 5;11\(1\):21750. doi: 10.1038/s41598-021-01188-4. PMID: 34741095; PMCID: PMC8571371.](#)

5.3 Panniculitis

5.3.1 Panniculitis



Grading & Level of importance: B

V. del Marmol, Brussels; F. Rongioletti, Milan; J. White, Brussels

ICD-11

EF00

Synonyms

None.

Definition

A heterogeneous group of diseases showing inflammation of subcutaneous adipose tissue.

Epidemiology

Rare depending on underlying cause.

Pathogenesis

Various underlying causes of panniculitis exist:

- Inflammatory and autoimmune
- Infection and infestation
- Trauma and physical agents (exogenous)
- Malignancy (hemolymphoproliferative disorders including lymphomas).
- Enzymatic (pancreatic, alpha-1-antitrypsin deficiency)

In association with:

- Tuberculosis (erythema induratum).
- Pancreatic disease.
- Perinatal asphyxia or hypothermia (sclerema neonatorum and subcutaneous fat necrosis of the newborn).
- Post-steroid therapy.
- Autoimmune dermatoses (systemic lupus erythematosus; dermatomyositis).
- Post trauma including surgery.
- Post infection.
- Chronic venous insufficiency (lipodermatosclerosis).

There may be overlapping causes of panniculitis (e.g. lupus erythematosus and trauma).

Signs & Symptoms

Painful inflammatory nodules and plaques occur in all form of panniculitis but making a diagnosis of a specific type of panniculitis on clinical examination is difficult except erythema nodosum. The patient history and additional clinical findings such as ulceration with discharge, atrophy, sclerosis, livedo reticularis, fever, arthralgias may be useful.

Localisation

The location of lesions is also a diagnostic clue. Erythema nodosum: anterior lower legs. Lupus panniculitis: Face, upper arms, breasts, upper torso and hips. Alpha1-antitrypsin deficiency-associated panniculitis: pelvic girdle. Erythema induratum/nodular vasculitis: posterior lower legs. Lipodermatosclerosis: medial lower legs.

Classification

The classification of panniculitis is based on clinical grounds and histopathology. Accordingly, panniculitis can be divided into septal, lobular and mixed (see Dermatopathology). The panniculitides most likely to ulcerate were calciphylaxis (85.7% ulcerating), pancreatic panniculitis (66.6%), and α 1-antitrypsin deficiency-associated panniculitis (100%). The panniculitides least likely to ulcerate were erythema nodosum and medication-induced and granulomatous panniculitis.

Laboratory & other workups

Depending on the underlying diagnosis.

Dermatopathology

Dermatopathology plays an integral role in the diagnosis of panniculitis. An elliptical biopsy is the recommended procedure. Panniculitides have been divided into septal (erythema nodosum, scleroderma) and lobular including most of the other forms. In addition to the localization of the inflammation, the composition of the infiltrate is also useful. Lymphocytic infiltrate predominates in lupus panniculitis, neutrophil-rich infiltrate in alpha-1-antitrypsin deficiency panniculitis, histiocyte-rich infiltrate in erythema nodosum, mixed-type in traumatic panniculitis. The presence or absence of vasculitis is also another clue.

Course

Depending on the underlying cause. Some forms will burn out leaving hard permanent scars. Longstanding and migrating subtypes exist.

Complications

Depending on the underlying cause.

Diagnosis

Clinico-pathologic correlation is essential.

Differential Diagnosis

Polyarteritis nodosa, cellulitis, cutaneous T-cell lymphoma. Behçet disease; Eosinophilic panniculitis; Lipodermatosclerosis; Lupus erythematosus; Morphea profunda; Post-irradiation panniculitis; Sclerema neonatorum; Subcutaneous fat necrosis of the newborn.

Prevention & Therapy

Depending on aetiology.

Special

None.

References

- [Wick MR \(2017\) Panniculitis: A summary. Semin Diagn Pathol. 34\(3\):261-272. doi: 10.1053/j.semdp.2016.12.004.](#)
- [Anand NC, Takaichi M, Johnson EF, Wetter DA, Davis MDP, Alavi A. Suggestions for a New Clinical Classification Approach to Panniculitis Based on a Mayo Clinic Experience of 207 Cases. Am J Clin Dermatol. 2022 Sep;23\(5\):739-746. doi: 10.1007/s40257-022-00709-9. Epub 2022 Jul 18. PMID: 35849324.](#)

Chapter 6 – Genodermatoses, Metabolic Diseases and Pigmentary Disorders

6.1 Genodermatoses

6.1.1 Neurofibromatosis

Grading & Level of importance: B
C. C. Zouboulis, Dessau



ICD-11

LD2D.1Z

Synonyms

Von Recklinghausen disease.

Definition

Autosomal dominant (57%) or sporadic (43%) neurocutaneous disease characterized by a predisposition to develop multiple benign mesenchymal tumors, esp. neurofibromas, and multi-organ involvement.

Epidemiology

Neurofibromatosis Type 1 (NF1): Prevalence 1:2,000–3,500 (most common neurocutaneous disease), incidence 1:2,000–3,000 – Male: female ratio approximately 1:1.

Neurofibromatosis Type 2 (NF2): Prevalence 1:100,000, incidence 1:33,000–40,000.

Aetiology & Pathogenesis

Mutations in suppressor genes.

NF1: Neurofibromin, an essential negative regulator of Ras cellular proliferation pathways (chromosome 17q11.2).

NF2: Merlin (or schwannomin), important in anchoring of the cytoskeleton to the cell membrane, the organization of cell membrane proteins and interaction with cytosolic proteins (chromosome 22q12).

Signs & Symptoms

NF1:

- Skin: cutaneous neurofibromas (localised, buttonhole phenomenon, 75-99%), plexiform neurofibromas (large nodular or diffuse tumors, 30%), café-au-lait macules (>5, larger than 1.5 cm, 86%), axillary and inguinal freckling (84%)
- Eyes: pigmented iris hamartomas (Lisch nodules) (40%)
- Skeletal system: kyphoscoliosis (25%), long-bone dysplasia (2%), sphenoid wing dysplasia (<1%)
- CNS: optic pathway glioma (13%), cerebral glioma (1%)
- Other organs: malignant peripheral nerve sheath tumor (6%), hydrocephalus (3%), renal arterystenosis (1%), pheochromocytoma (1%)

NF2:

- Vestibular schwannomas (usually bilateral; 95%)
- Schwannomas on other intracranial nerves and in the spinal compartment
- Meningiomas, ependymomas, and gliomas

Localisation

Generalized.

Classification

Molecular classification

- NF1: skin findings (+/-), neurofibromas, Lisch nodules.
- NF2: bilateral acoustic schwannomas (rarely skin findings of NF1).

Severity classification (DNB classification)

Stage	DNB classification			
	D	N	B	Life function and social activity
1	D1	N0	B0.	No problems in daily life and social activity
2	D1-2	N0	B1	Mild problems in daily life and social activity
		N1	B0-1	
3	D3	N0	B0	Mild problems in daily life and severe problems in social activity
4	D3	N1	B0-1	Moderate problems in daily life and severe problems in social activity
	D3	N0-1	B1	
5	D4	any N	any B	Severe problems in daily life due to physical abnormality
	any D	N2	any B	
	any D	any N	B2	

Dermatological manifestations

D1 Pigmented macules and a few neurofibromas

D2 Pigmented macules and many neurofibromas

D3 Numerous neurofibromas (>1000 in number, >1 cm in size)

D4 Severe plexiform neurofibromas or malignant peripheral nerve sheath tumor

Neurological manifestations N0 No neurological symptoms

N1 Neurological symptoms (e.g. paralysis or pain) or/and abnormal neurological findings

N2 Severe or progressive neurological symptoms

Bone manifestations

B0 No bone lesion

B1 Mild or moderate bone lesion (deformity in spine or extremities that does not need treatment)

B2 Severe bone lesion (dystrophic type or spine deformity that needs surgical treatment (e.g. scoliosis or kyphosis), severe bone deformity in extremities (e.g. pseudarthrosis, fracture) or defect of the skull or facial bone.

Laboratory & other workups

Genetic analysis.

Radiological examinations for detection of organ involvement and complications.

Dermatopathology

Cutaneous neurofibroma: Non-encapsulated lesion in the dermis representing a proliferation of all elements of peripheral nerves. The cells have wavy serpentine nuclei and pointed ends. There is stromal mucin deposition and fibroplasia. Mast cells are easily recognisable. Axon course may be illustrated with immunohistochemical stains for neurofilament.

Plexiform neurofibroma: Tumour growth within and irregularly expanding over a nerve bundle.

Course

The course of the disease is not predictable and depends on the individual organ manifestations and the severity grade. Cutaneous neurofibromas and café-au-lait macules can increase with progressing age but are always benign, whereas plexiform neurofibromas have a potential for malignant transformation into malignant peripheral nerve sheath tumors. Half of the patients with optic pathway glioma will develop visual symptoms. Long-bone dysplasia can result in pseudarthrosis.

NF1 life time risk for malignant nerve sheath tumor-associated mortality 8-13%. Significant excess mortality in the ages of 10-20 years (5.2x) and 20-40 years (4.2x), in females > males, mostly due to malignant nerve sheath tumors (60%).

Complications

The spectrum of complications in NF1 patients includes osteoporosis, learning disability, pregnancy and delivery complications, cardiovascular abnormalities, speech defects and cancer.

Rare complications (6%):

- Malignant transformation of plexiform neurofibromas (neurofibrosarcomas)
- Increased risk for lymphoma and leukemia

Diagnosis

Clinical findings, family history, genetic analysis.

Differential Diagnosis

Clinical: Neurofibrosarcoma.

Histopathological: Schwannoma, perineurioma, dermatofibrosarcoma protuberans.

Prevention & Therapy

Genetic counselling.

Excision of disturbing or painful neurofibromas, which may also be destroyed with CO₂ or Erb: YAG laser. Methylphenidate (0.5-0.8 mg/kg/d) has a short-term effectiveness in NF1 children with ADHD-like symptoms.

Chemotherapy does not reduce mortality in metastasized neurofibrosarcoma. Multidisciplinary approach to diagnosis and treatment.

Special

None.

References

- [Legius, E., Messiaen, L., Wolkenstein, P. et al. Revised diagnostic criteria for neurofibromatosis type 1 and Legius syndrome: an international consensus recommendation. Genet Med 23, 1506–1513 \(2021\). https://doi.org/10.1038/s41436-021-01170-5](https://doi.org/10.1038/s41436-021-01170-5)
- [Farschtschi S, Mautner VF, McLean ACL, Schulz A, Friedrich RE, Rosahl SK. The Neurofibromatoses. Dtsch Arztebl Int. 2020 May 15;117\(20\):354-360. doi: 10.3238/arztbl.2020.0354. PMID: 32657748; PMCID: PMC7373809.](https://doi.org/10.3238/arztbl.2020.0354)

6.1.2 Xeroderma Pigmentosum

Grading & Level of importance: C

C. C. Zouboulis, Dessau



ICD-11

LD27.1

Synonyms

XP.

Definition

Group of uncommon genodermatoses with markedly increased light sensitivity and tendency towards developing actinic damage and malignant skin tumours.

Epidemiology

From about 1 in 500,000 live births in Western Europe to much higher frequencies in Japan and North Africa.

Aetiology & Pathogenesis

Autosomal recessive inherited defects in DNA excision repair enzymes (NER; Groups XPA to XPG). Cells cannot repair UV-induced damage. The group XPV exhibits defective translesion DNA synthesis because of mutations in the POLH gene encoding DNA polymerase η .

Signs & Symptoms

Wide variety of clinical features with marked photosensitivity with acute photodermatitis and marked actinic damage, including actinic keratoses, squamous cell carcinomas, basal cell carcinomas, malignant melanomas, poikiloderma and skin atrophy. Eyes also suffer UV damage. Some types (DeSanctis-Cacchione syndrome) have neurological findings. Individuals in which NER remains functional (XPC, E and V) have skin and eye (photophobia, pterygia, pingueculae, corneal scarring and ocular surface cancers) defects but no significant neurological problems. Individuals with affected NER may additionally have neurological abnormalities (progressive neurological degeneration with peripheral neuropathy, sensorineural hearing loss, impaired cognition and declining gait) in addition to severe and exaggerated sunburn reactions.

Localisation

Light-exposed areas.

Classification

Types A-G. Splicing mutations in XPA and XPD and a specific amino acid change in XPD are associated with mild phenotypes. The XP-F group has reduced pigmentation changes and a lower susceptibility to skin cancer than XPs in other groups.

Laboratory & other workups

Gene sequencing, identification of endonuclease defects in cultured fibroblasts, DNA sequencing of known genes.

Dermatopathology

Corresponds to solar lentigines, showing atrophy of the epidermis and spot-like hyperpigmentation in the stratum basale.

Course

Reduced life expectancy because of multiple malignant skin tumours, especially malignant melanomas.

Complications

Development of malignant skin tumours (squamous cell carcinoma, basal cell carcinoma, malignant melanoma) before 20 years of age.

Diagnosis

Clinical findings (photosensitivity, early actinic damage), genetic analysis.

Differential Diagnosis

Xeroderma pigmentosum variant with same phenotype, later onset, no genetic defects (pigmented xerodermoid).

Prevention & Therapy

Early use of high-potency broad-spectrum sunscreens, close clinical control, prompt tumour excision. Perhaps systemic retinoids for prophylaxis.

Special

XP-C patient with advanced metastatic cancer arising from an angiosarcoma had a dramatic recovery following immunotherapy treatment (after molecular analysis).

6.1.3 Epidermolysis Bullosa

Grading & Level of importance: C

G. Girolomoni, Verona; P. Gisondi, Verona; M. Maurelli, Verona



ICD-11

EC30-3ZEB43 etc.

Synonyms

None.

Definition

Group of genetic diseases with skin fragility in which minimal trauma leads to the formation of blisters; autosomal dominant and autosomal recessive inheritance.

Epidemiology

1.2 in 100000 live births worldwide; estimated 500000 cases worldwide (Orphan disease). Epidermolysis bullosa simplex the most common sub-type of epidermolysis diseases (>90%) followed by dystrophic epidermolysis bullosa (5%) and junctional epidermolysis bullosa (1-2%).

Aetiology & Pathogenesis

Mutations in structural proteins and adhesive complexes of the epidermis and the epidermal-dermal junction.

Signs & Symptoms

Blisters heal with or without scars, depending on the level of the defect (mutilations). With widespread disease, disturbances in electrolyte, water and protein balance. With oral and gastrointestinal tract involvement with life threatening scarring, difficulty eating and failure to thrive.

Localisation

Every part of the body can be involved, predilection to areas exposed to pressure and friction.

Classification

Several subtypes depending on location of defective protein and level of blister formation in the skin: epidermolysis bullosa simplex, junctional epidermolysis bullosa, dystrophic epidermolysis bullosa. Clinically mild and severe forms.

- Epidermolysis bullosa simplex: most cases are inherited in an autosomal dominant pattern, caused by defect in the genes encoding keratin 5 and keratin 14. Clinically it is characterized by blisters with an erythematous halo, caused by friction and exacerbated by sweating and excessive heat.
- Junctional epidermolysis bullosa: cleavage occurs within the lamina lucida at the dermo-epidermal junction. Most case are due to mutation in laminin genes-, collagen XVII or $\alpha 6\beta 4$ integrin. The mode of inheritance is autosomal recessive, and the distribution of lesions can be localized or generalized. Clinically, it is characterized by blisters, erosions, skin dystrophy, hypoplasia of dental enamel and caries. On healing, the blisters leave atrophic scars.
- Dystrophic epidermolysis bullosa: caused by the mutation in collagen VII. Blisters may be localized or generalized, and the lesions hesitates in dystrophic scars. The inheritance pattern can be autosomal dominant or autosomal recessive (the more severe, but the less common). Clinically, milia and nail dystrophy are commonly observed, as well as the involvement of mucous membranes.

Laboratory & other workups

Dermatopathology, immunofluorescent antigen mapping, electron microscopy, DNA sequencing of candidate genes.

Dermatopathology

Epidermolysis bullosa simplex: intraepidermal cleavage (keratin 5 and 14 defects).

Junctional epidermolysis bullosa: cleavage at the dermo-epidermal junction (lamina lucida). Dystrophic epidermolysis bullosa: subepidermal cleavage (collagen VII).

Histology and immunofluorescence mapping allow for the identification of the plane of cleavage as well as determination of semiquantitative protein expression.

Course

Depending on variant ranging from mild nuisance to fatal disease. Marked psychosocial problems and reduced quality of life. Epidermolysis bullosa simplex improves with age.

Complications

Variable - none in mild forms; infections, scarring with mutilations and with development of squamous cell carcinomas in more severe variants. Early death possible.

Diagnosis

Clinical findings, laboratory investigations, family history.

Differential Diagnosis

Other blistering disorders (pemphigoid, pemphigus, linear IgA bullous dermatosis, epidermolysis bullosa acquisita), peeling skin syndrome, congenital localized absence of skin, Bart's syndrome (rare inherited disorder characterized by the localized absence of the skin, blister formation, and nail deformity; it is a variant of aplasia cutis congenita with epidermolysis bullosa), suction blisters and mechanical blisters by friction and trauma.

Prevention & Therapy

Intensive skin care, avoidance of pressure and friction. Prevention of secondary infections. No specific systemic therapy available. Treatments are focused on the prevention of lesions and complications. Patient support groups very helpful. Gene therapy of stem cells in combination with advanced tissue-engineering techniques for severe forms of junctional and dystrophic epidermolysis bullosa under development.

Special

Address severe cases to special centers. Autologous skin transplantation and gene therapy. Patient support groups very helpful.

References

- [Bardhan A, Bruckner-Tuderman L, Chapple ILC, Fine JD, Harper N, Has C, Magin TM, Marinkovich MP, Marshall JF, McGrath JA, Mellerio JE, Polson R, Heagerty AH. \(2020\). Epidermolysis bullosa. Nat Rev Dis Primers Sep 24;6\(1\):78. doi: 10.1038/s41572-020-0210-0. PMID: 32973163.](#)
- [Koga H, Prost-Squarcioni C, Iwata H, Jonkman MF, Ludwig RJ, Bieber K. \(2019\). Epidermolysis bullosa acquisita: the 2019 update. Front Med \(Lausanne\) Jan 10;5:362. doi: 10.3389/fmed.2018.00362. PMID: 30687710; PMCID: PMC6335340.](#)

6.1.4 Ichthyoses

Grading & Level of importance: C

G. Girolomoni, Verona; P. Gisondi, Verona; M. Maurelli, Verona



ICD-11

ED20.0-Y; ED50.0; ED50.Z

Synonyms

None.

Definition

Group of hereditary disorders of keratinisation with different patterns of inheritance and genetic defects.

Epidemiology

Ichthyosis vulgaris: prevalence 1:250- 1:1000. Autosomal dominant. X-linked recessive ichthyosis: 1:2000-1:6000 males.

Autosomal recessive congenital ichthyosis (ARCI): 1:100000. Syndromic ichthyosis: very rare

Acquired ichthyosis: unknown.

Aetiology & Pathogenesis

- Ichthyosis vulgaris: autosomal dominant, often associated with atopic dermatitis (50%) because of the loss-of-function mutations in the gene coding profilaggrin (FLG).
- X-linked recessive ichthyosis: hereditary deficiency of the steroid sulfatase (STS) genes deletions.
- Autosomal recessive congenital ichthyosis (ARCI): defects in keratin genes, transglutaminase, or other structural proteins.
- Syndromic ichthyosis: involvement of other organ systems in addition to the skin
- Acquired ichthyosis: associated with HIV infection, certain drugs, such as statins, paraneoplastic diseases, cutaneous T-cell lymphomas, metabolic disorders.

Signs & Symptoms

Mild to severe scaling and hyperkeratosis.

- Ichthyosis vulgaris: starts in 1st year of life, dry rough scaly skin, symmetrical sparing on extremities, especially on flexural areas, hyperlinearity of palms and soles. In 50% of cases is associated with atopic dermatitis. Clinically is characterized by grey-white scales.
- X-linked recessive ichthyosis: similar to ichthyosis vulgaris, but flexures are involved, undescended testes in 30%. Clinically characterized by large, dark-brown, polygonal scales associated with generalized dryness. The lesions usually spreads to the whole body.
- Autosomal recessive congenital ichthyosis (ARCI): generalised ichthyoses, over almost the entire body surface, present at birth often associated with erythroderma. Occasionally ectropion of eyelids.
- Collodion baby: newborn with thick, stiff fissured sheets of stratum corneum; many causes. Initial manifestation of an autosomal recessive congenital ichthyosis.

Localisation

- Extremities, especially on the extensor surfaces. The flexural areas and groin are spared because of humidity in these regions. On the palms, soles and lower legs the scales are often larger.
- All body surface in the extensive and the more severe forms, with mild erythema and generalized scaling or peeling.

Classification

- Non syndromic: only affecting the skin (ichthyosis vulgaris, ARCI, epidermolytic ichthyosis, and others).
- Syndromic: involvement of other organ systems in addition to the skin (Chanarin-Dorfman syndrome, Comèl-Netherton syndrome, KID syndrome, Refsum's disease, Sjögren-Larsson syndrome [SLS], trichothiodystrophy, and others).

Laboratory & other workups

Complete blood count, electrolytes, hepatic panel, immunoglobulin levels (including IgE). Peripheral blood smear to evaluate for vacuoles in leukocytes. Hearing screening. Ophthalmologic examination. X-rays to evaluate epiphyses. Skin biopsy and genetic test.

Dermatopathology

Mild orthokeratotic hyperkeratosis, diminished granular layer. Immunohistochemistry demonstrates diminished or absent filaggrin.

Course

Severity and symptoms (itch) depend on the season and the climate, improving in the summer and with high humidity. Ichthyosis vulgaris is usually progressive during childhood, and improves with age.

Complications

Bacterial superinfections. Psychosocial problems.

Diagnosis

- Clinical
- Molecular test
- Histology

Differential Diagnosis

Acquired ichthyosis, i.e. malnutrition, paraneoplasia.

Prevention & Therapy

Pre-natal diagnosis for congenital ichthyosis.

Emollients. Keratolytic agents, such as urea, salicylic acid, lactic acid ointments, topical retinoids. Systemic retinoids (isotretinoin, acitretin).

Special

Reference centers for severe cases.

References

- [Limmer AL, Nwannunu CE, Patel RR, Mui UN, Tying SK. \(2020\). Management of Ichthyosis: a brief review. Skin Therapy Lett. Jan;25\(1\):5-7. PMID: 32023022.](#)

- [Vahlquist A, Törmä H. \(2020\) Ichthyosis: a road model for skin research. Acta Derm Venereol. Mar 25; 100\(7\):adv00097. doi: 10.2340/00015555-3433. PMID: 32147743; PMCID: PMC9128938.](#)

6.1.5 Palmoplantar Keratoderma

Grading & Level of importance: C



RM. Pujol, Barcelona

ICD-11

ED55

Synonyms

Keratosis palmoplantaris.

Definition

Persistent thickening of the epidermis of palms and soles.

Epidemiology

Includes genetic as well as acquired forms. Uncommon disorders. Autosomal dominant (1:100,000) and autosomal recessive disorders.

Aetiology & Pathogenesis

Hereditary palmo-plantar keratodermas (PPK) include a high number of genodermatoses with different prognoses with multiple associated cutaneous and extracutaneous features.

Many different genes identified in diffuse PPK secondary to keratin mutations (epidermolytic and non-epidermolytic) in autosomal dominant and recessive pattern of inheritance. Many different clinical variants with multiple implicated genes in focal, striated, complex and syndromic hereditary PPK (some examples):

1. Diffuse PPK secondary to KRT1/KRT9 mutations: epidermolytic PPK and non-epidermolytic PPK. Autosomal dominant
2. Diffuse PPK secondary to SLURP1 mutations: mal de Meleda. Autosomal recessive

3. Diffuse sclerosing palmo-plantar keratoderma (sclerolyosis)
4. Focal PPK due to KRT6c and KRT16 mutations
5. Striate PPK due to Desmoglein 1 and desmoplakin mutations
6. Punctate PPK due to AAGAB and COL14A1 mutations
7. Complex PPK due to LOR mutations (Vohwinkel syndrome): ichthyosis, PPK, pseudoainhum and mutilations.
8. Complex PPK due to TRPV3/MBTP2 mutations (Olmsted syndrome): periorificial keratotic plaques, pseudoainhum, hair and nail abnormalities.
9. PPK with deafness (due to GJB2 mutations, due to MMTS mutations)
10. PPK with periodontitis (Papillon-Lefèvre syndrome: CTSC mutations)
11. PPK with arrhythmogenic right/left ventricular cardiomyopathy and woolly hair (Naxos disease/ Carvajal disease): JUP/DSP mutations.

Acquired PPK include a spectrum of disorders of different etiology:

1. Keratoderma climatericum (women of menopausal age)
2. Chemicals (arsenic, chloracnogens)
3. Drugs: Tegafur, bleomycin, hydroxyurea, lithium, verapamil, mepacrine
4. Systemic disease (thyroidal disorders, lymphedema)
5. Malignancies (lymphomas, paraneoplastic)
6. Infectious disorders (syphilis, tinea, scabies, tuberculosis)
7. Dermatoses (occupational, irritative, psoriasis, atopic dermatitis, pityriasis rubra pilaris, contactallergies, chronic hand eczema)

Signs & Symptoms

Onset usually in infancy, symmetrical, palms and soles thickened, yellow and fissured with diffuse or focal symmetrical lesions, often hyperhidrosis. Some variants may worsen by age. Association with other ectodermal defects possible.

Acquired PPK may also be focal, diffuse or punctate.

Localisation

Palms and soles. In some cases, may extend to the dorsal surfaces of the hands and feet, wrists and Achilles tendons. Different disorders may present associated hyperkeratotic cutaneous or mucosal

lesions, often involving the extensor surfaces of the extremities (knees, elbows), hair, nail and teeth abnormalities.

Classification

1. Depending on etiology: Hereditary or acquired PPK

1.1. Hereditary PPK

Diffuse or focal hyperkeratosis, with or without associated findings, exact classification based on molecular genetic identification of mutations. Hereditary PPK can be divided into:

- Non-syndromic isolated PPK: Predominant or unique palmo-plantar involvement
- Complex PPK: Non-syndromic PPK with additional distinctive cutaneous and adnexal manifestations
- Syndromic PPK: PPK associated with specific extracutaneous manifestations
 - PPK associated with sensorineural deafness
 - PPK associated with prominent mucosal involvement
 - PPK associated with cardiomyopathy and woolly hair
 - PPK associated with other systemic signs

1.2. Acquired PPK

Multiple etiologies: Inflammatory (psoriasis, eczema), systemic diseases, chemicals, drugs, hormonal changes, malignancy, idiopathic.

2. Classification according to the observed clinical patterns:

- Diffuse PPK: Generalized epidermal thickening involving the entire palmo-plantar surfaces.
- Focal PPK: Multiple callosities (soles)
- Striate PPK: Linear hyperkeratotic bands in correspondence with the underlying tendons
- Punctate PPK: Multiple papular lesions with epidermal thickening (with a central pit or spiny projections)

Laboratory & other workups

No abnormalities are usually detected. For certain hereditary forms molecular profiling has to be studied. For acquired forms an individual workup is often necessary depending on the underlying cause.

Dermatopathology

Non-epidermolytic PPK: Acanthosis, hypergranulosis, hyperkeratosis, orthokeratosis.

Epidermolytic PPK variants: Peri-nuclear vacuolization, granular degeneration of keratinocytes, large, irregular keratohyaline granules. Subcorneal intra-epidermal cleavage.

In acquired PPK the histopathological features are non-specific: hyperkeratosis with orthokeratosis, occasional parakeratosis with variable amounts of inflammation.

Course

Chronic. Persistent. In some variants of acquired PPK the detection and resolution of the underlying cause may lead to clinical improvement and/or resolution.

Complications

Secondary fungal infection. Psychosocial problems. In some rare variants, sclerotic bands develop around the fingers (pseudoainhum) and automutilation may occur. In syndromic PPK the associated features (i.e., cardiomyopathy) may have prognostic implications.

Diagnosis

Clinical history and features combined with histopathological findings. Positive family history and onset in infancy or childhood may be helpful to distinguish between hereditary and acquired PPK. The clinical pattern (diffuse, striate/focal or punctate) along with the presence of other cutaneous or extra-cutaneous manifestations may also be helpful. In some cases, the genetic study may confirm the diagnosis. In acquired PPK a systematic search for an underlying cause is mandatory.

Differential Diagnosis

The different acquired etiologies that may lead to PPK. Other causes of palmoplantar keratoses: hand dermatitis (hyperkeratotic, fissured), psoriasis, cutaneous T-cell lymphoma (especially Sézary syndrome), dyskeratosis follicularis (Darier) and hyperkeratotic lesions in secondary syphilis.

Prevention & Therapy

Topical keratolytics: salicylic acid (5-10%), urea, lactic acid, vitamin A acid, abrasive soaps, mechanical removal. Customized footwear.

Systemic: low dose retinoids (acitretin).

In the acquired variants of PPK: To identify (if possible) and treat the underlying etiology.

Special

None.

References

- [Has C, Technau-Hafsi K. Palmoplantar keratoderms: clinical and genetic aspects. J Dtsch Dermatol Ges. 2016; 14:123-39.](#)
- [Guerra L, Castori M, Didona B, Castiglia D, Zambruno G. Hereditary palmoplantar keratoderms. Part I. Non-syndromic palmoplantar keratoderms: classification, clinical and genetic features. J Eur Acad Dermatol Venereol. 2018; 32:704-719.](#)
- [Guerra L, Castori M, Didona B, Castiglia D, Zambruno G. Hereditary palmoplantar keratoderms. Part II: syndromic palmoplantar keratoderms - Diagnostic algorithm and principles of therapy. J Eur Acad Dermatol Venereol. 2018; 32:899-925.](#)

6.1.6 Dyskeratosis Follicularis Darier (DF)

Grading & Level of importance: C
G. Burg, Zürich



ICD-11

EC20.2

Synonyms

Keratosis follicularis, Darier-White disease, Darier's disease.

Definition

Dyskeratosis follicularis (Darier's disease) is a rare autosomal dominant genodermatosis. It affects not only the skin but also the oral mucosa and nails, indicating that the term "dyskeratosis follicularis" is a misnomer. Typical clinical features are keratotic papules, predominantly on the upper trunk and on the scalp in conjunction with palmar pits and nail dystrophy. Histologic changes include acantholysis and

dyskeratosis.

Epidemiology

Darier disease is one of the most common genodermatoses, first reported by Darier and White in 1889. The prevalence is 1:30,000-100,000 and an incidence of new cases of four per million per 10 years. The occurrence of sporadic cases is approximately 40-50%, with a high penetrance of about 95%. There is no gender difference with respect to incidence. However, the disease affects men more severely than women. It develops initially in childhood and persists throughout adolescence. The life expectancy is normal.

Aetiology & Pathogenesis

The ATP2A2 gene maps to the long arm of chromosome 12 at 12q23-24.1 and encodes SERCA2, a calcium pump classified as a P-type calcium ATPase.

A mutation leads to defect differentiation of keratinocytes and disturbed formation of desmosomal tonofilaments, resulting in acantholysis. High temperatures, high humidity, excessive sweating, UV light, virus infections (herpes simplex), caffeine, alcohol, stress, and mechanical irritation are trigger factors.

Signs & Symptoms

Skin: small grayish-brown, itchy keratotic papules several millimeters in diameter; occasionally confluent, weeping, sometimes itching and foul-smelling. Papules do not always occur in the hair follicles, but often aggregate to form a verrucous lesion with keratotic crusts, leading to hair loss. Papules developing at sites of friction, such as the groin may fuse and become papillary.

Disturbances in dermatoglyphics, tiny palmoplantar pits and punctiform interruptions of the papillary strip structure on the fingers and toes, sometimes with small keratotic plugs may point to early diagnosis of Darier disease. A rare variant shows disabling palmoplantar hyperkeratosis.

Oral mucosa and hard palate: leukoplakia-like changes with small white grouped papules are found in about 15% of patients, initially on the palate, resembling cobblestones. They may become very widespread. Similar lesions are seen on the genital mucosa.

Nails: Marked nail dystrophies may evolve over time in up to 90% of patients, presenting as grooves and subungual hyperkeratosis and distal notches. The nails often show distal notches, subungual hyperkeratosis, and longitudinal ridging and splitting and longitudinal red or white lines. Fingernails and toenails may become brittle and weak.

Psycho-neurological problems, including seizure, mental retardation and psychoses. Maniac depressive illness and epilepsy are seen more frequently in patients with Darier's disease.

Acrokeratosis verruciformis Hopf also is caused by mutations in the SERCA2-ATPase gene, indicating the nosologic relationship to Darier's disease. It presents as verrucous papules on the back of the hand.

Localization

Seborrheic regions: centrofacial, scalp, axillary region, central breast and back regions, inguinal region, anogenital. The nape is often the first site of involvement.

Classification

Linear and circumscribed forms exist.

Various mutations in the SERCA2-ATPase gene are known, without evident impact on the clinical expression of the disease. Mild forms and more severe forms can be differentiated, considering the course of the disease.

Special form: Verrucous papules on the back of the hand are also referred to as Acrokeratosis verruciformis Hopf.

Laboratory & other workups

Skin biopsy.

Dermatopathology

- Dyskeratosis: defective differentiation of keratinocytes with corps ronds (eosinophilic cells in Str. spinosum) and corps grain (granular nuclear residues in St. Granulosum) Verrucous hyperkeratosis, especially in acrokeratosis verruciformis Hopf
- **Acantholysis**: suprabasal cleft formation with numerous eosinophilic granulocytes. The basal layer may be retained, producing a tombstone pattern like in pemphigus vulgaris
- Inflammatory infiltrate in the dermis

Course

Chronic with progressing worsening in the first years of illness and following the impact of triggering factors, like UV-light or virus infection (herpes), which can lead to widespread flare and acute worsening.

Bacterial superinfection may become a problem at intertriginous sites. Severe complications are rare.

Complications

Superinfection.

Diagnosis

Clinical and histological picture.

Differential Diagnosis

- seborrheic dermatitis,
- pemphigus benignus familiaris (Hailey-Hailey),
- transient acantholytic dermatosis (Grover's disease),
- pemphigus vegetans (intertriginous),
- acanthosis nigricans,
- verrucous epidermal nevi

Prevention & Therapy

Prevention: Avoidance of direct exposure to the sun (UV; sweating) and other triggering factors (see above).

Topical: emollient-like soap substitutes and moisturizers are usually sufficient in mild forms. Retinoids, antiseptic baths, short-term weak glucocorticosteroids

Systemic: oral retinoids (acitretin: 0.6 mg/kg daily, increased gradually up to 10-25 mg daily; isotretinoin) are effective in up to 90% of patients. Slow tapering down necessary to find optimal maintenance dose. In case of superinfection: oral antibiotics.

Surgical: exceptionally dermabrasion, laser.

Special

Grover's disease (transitory and i.p. persisting form of acantholytic dermatosis) is an important differential diagnosis predominantly in older men with a tendency to relapse after transient phases of regression.

References

- [Takagi, A., Kamijo, M., & Ikeda, S. \(2016\). Darier disease. J Dermatol, 43\(3\), 275-279. doi: 10.1111/1346-8138.13230. PMID: 26945535.](#)
- [Korman AM, Milani-Nejad N. \(2020\). Darier Disease. JAMA Dermatol.;156\(10\):1125. doi:10.1001/jamadermatol.2020.2543. PMID: 32785629.](#)
- [Hanna N, Lam M, Fleming P, Lynde CW. \(2022\). Therapeutic Options for the Treatment of Darier's Disease: A Comprehensive Review of the Literature. J Cutan Med Surg. May-Jun;26\(3\):280-290. doi: 10.1177/12034754211058405. Epub 2021 Nov 28. PMID: 34841914; PMCID: PMC9125141.](#)
- [Bachar-Wikstrom, E. and Wikström JD. \(2021\). Darier Disease - A Multi-organ Condition? Acta Derm Venereol 101\(4\): adv00430. doi: 10.2340/00015555-3770. PMID: 33606037; PMCID: PMC9364244](#)

6.1.7 Pseudoxanthoma elasticum (PXE)

Grading & Level of importance: C



G. Girolomoni, Verona; P. Gisondi, Verona; M. Maurelli, Verona

ICD-11

Q82.8

Synonyms

Grönblad-Strandberg syndrome.

Definition

Pseudoxanthoma elasticum (PXE) is an autosomal recessive disorder, in which elastic fibers of skin, eyes and cardiovascular system become progressively calcified and lead to a spectrum of manifestations with a variable phenotype.

Epidemiology

The prevalence has been estimated at between 0.25 to 1 per 100,000 of the general population, with a slight female predominance. Cutaneous alterations usually develop during childhood; the ocular and cardiovascular complications manifest in the third and fourth decade of life.

Aetiology & Pathogenesis

In the majority of patients, various gene-mutations on the short arm of chromosome 16, resulting in impairing the proper function of elastin and elastic fibers in the mid and deep dermis, the media and the intima of mid-sized arteries, and Bruch's membrane in the eye, with the clinical and histological typical pathologic alterations.

Localisation

PXE typically affects the elastic fibers of three organ systems: the skin, eyes and cardiovascular system. Cutaneous features include discrete yellowish skin papules, localized in flexural areas, most commonly during the first or second decade of life. The lateral neck is usually the first site. Over the time, the papules coalesce to form cobblestone-like plaques, with a 'plucked chicken skin' appearance. Other flexural areas affected are the antecubital and popliteal fossae, the wrists, axillae and groin. In the extensive cases, also the non-flexural areas are involved.

The symptoms are typically associated with the complications, such as loss of visual activity, in the case of the ocular involvement, and claudication, hypertension, angina and myocardial infarction, the cardiovascular system involvement.

Classification

The cutaneous involvement is characterized by small yellow papules with diameter of up to 10 mm on the nape and sides of the neck and in flexural areas, with coalesce into reticulated plaques as the disease progresses, giving a cobblestone aspect of the skin. The skin subsequently becomes loose and wrinkled. A specific characteristic of PXE is the presence of horizontal and oblique chin creases before age of 30 years. In the advanced disease, significant calcium deposits may present as firm papules or plaques, and may occasionally extrude from the skin in 'perforating PXE'. Mucosal involvement is most prominent in the inner aspect of the lower lip, manifesting as yellow papules.

The ophthalmologic complications are characterized by angioid streaks, with a prevalence of 100% after the age of 30 years. Angioid streaks results from breaks in the calcified elastic lamina of Bruch's membrane, which is derived from the retina and the choroid plexus. These fractures can lead to neovascularization from choriocapillaris, and leakage of newly formed vessels may lead to haemorrhage and scarring. These pathologic alterations cause progressive loss of visual activity and, rarely, blindness.

The cardiovascular complications affect primarily mid-sized arteries, in particular the extremities, with a progressive calcification of the elastic media and intima that leads to the formation of atheromatous plaques. Clinical manifestations are intermittent claudication, loss of peripheral pulses, renovascular hypertension, angina pectoris, and myocardial rupture; moreover, cerebral ischemic attacks, mitral valve prolapse and, in the case of the blood vessels calcification of gastric and intestinal mucosa, the rupture and haemorrhage, with a gastrointestinal bleeding, particularly from the stomach.

Laboratory & other workups

There are no specific or general laboratory or biochemical assays for PXE.

Clinical examinations, exploration of the vascular vessels with MR angiography and ultrasound, fundus examination of the posterior pole of both eyes.

Patients are screened for ABCC6 mutations.

Dermatopathology

Elastin is stained with Verhoeff-van Gieson reagent, whereas calcium deposits are stained with Von Kossa. The mid-dermal elastic fibers in PXE are short, fragmented, clumped and calcified. In addition, in some PXE patients, splitting, thickening, coiling, calcification and flower-like deformation of cutaneous collagen fibers, are observed.

Course

PXE patients should be monitored with clinical examinations, exploration of the vascular vessels with MR angiography and ultrasound, fundus examination of the posterior pole of both eyes. The purpose is to avoid the systemic involvement and the complications. The life-span is normal in most patients.

Complications

Systemic involvement, in particular ocular and cardiovascular (described above).

Diagnosis

The diagnosis is made on clinical and histologic features. Additional workup (see above).

Differential diagnosis

Differential diagnosis encounters actinic damage for older individuals, but this typically involves the neck, but not axillae or groin. In addition, late-onset focal dermal elastosis, elastoderma, white fibrous papulosis of the neck, perforating periumbilical calcific elastosis and fibroelastolytic diseases of the skin. PXE-like lesions in flexural sites and with similar histological findings have been observed in patients treated with D-penicillamine, in longstanding end-stage renal disease and in L-tryptophan-induced eosinophilia myalgia syndrome. In these cases, ophthalmologic and cardiovascular findings are absent. In addition, PXE-like phenotype is present in up to 20% of patients affected by beta-thalassemia or sickle cell anaemia.

Prevention & Therapy

No treatments are currently available. Antioxidant therapy with daily doses of tocopherol acetate and ascorbic acid is important to combat oxidative stress.

Ophthalmologic exams include biannual or annual funduscopy, prevention of retinal haemorrhage through avoidance of head trauma, and avoidance of smoking. Use of sunglasses is recommended. Bevacizumab is a treatment for stopping choroidal neovascularization.

Cardiovascular prevention is important to avoid the calcification of blood vessels, through regular exercise, weight control, avoidance of smoking and alcohol consumption and treatment of hypercholesterolemia and hypertension. Low-dose acetylsalicylic acid may be indicated to prevent myocardial infarction in some cases. Pentoxifylline, cilostazol and clopidogrel are used in patients with intermittent claudication.

Prenatal diagnosis is essential in families with known mutations.

References

- [Germain DP. \(2017\). Pseudoxanthoma elasticum. Orphanet J Rare Dis. May 10;12\(1\):85. doi: 10.1186/s13023-017-0639-8. PMID: 28486967; PMCID: PMC5424392.](#)
- [Brokamp G, Mori M, Faith EF. \(2022\) Pseudoxanthoma elasticum. JAMA Dermatol. Jan 1;158\(1\):100. doi: 10.1001/jamadermatol.2021.4059. PMID: 34787669.](#)

6.2 Cutaneous Manifestations of Metabolic Diseases

6.2.1 Skin Changes in Diabetes Mellitus



Grading & Level of importance: C

V. del Marmol, Brussels; F. Rongioletti, Milan; J. White, Brussels

ICD-11

EL3Y

Synonyms

Nil.

Definition

The spectrum of skin changes seen as a result of hyperglycaemia and its multiple effects on the body.

Epidemiology

Between 30 and 70% of patients with diabetes mellitus, both type 1 and type 2 have skin changes. Such changes are more common with advancing age, but may occur in all people with diabetes mellitus.

Aetiology & Pathogenesis

Due to hyperglycaemia, there are pathological changes in the circulation, nerves and an increased tendency to infection, with reduced wound healing. Many skin changes are caused by a combination of these factors.

Signs & Symptoms

Microangiopathy:

- Pretibial pigmented patches (PPP): these manifest as small, poorly-defined brown macules over the shins.
- Rubeosis faciei: persistent facial erythema. Macroangiopathy:
- Peripheral arterial occlusion: intermittent claudication, calves and feet pale or livid and cold, absent or reduced pulses in feet, sometimes ulcers or delay in wound healing.

Polyneuropathy:

- Neurotrophic ulceration: indolent painless ulcers with hyperkeratotic border, primarily on heels and the tips of the toes.

Granulomatous disorders:

- Necrobiosis lipoidica: primarily on shins, oval sharply demarcated yellow-red plaques with central glassy white-yellow area, mostly asymptomatic, may ulcerate. They may be a cosmetic problem.
- Disseminated granuloma annulare: primarily on trunk, asymptomatic papules and plaques, sometimes confluent and often with prominent border (see chapter granuloma annulare).

Infections:

- Candidiasis: most often intertriginous, also involves mouth, genitalia (balanitis, vulvovaginitis), nails.
- Folliculitis and furuncles: usually on trunk.

Others:

- Generalised pruritus: always rule out diabetes mellitus in patients with unexplained diffuse persistent pruritus.
- Nodular prurigo: pruritic papules with central excoriations, usually on shoulders and arms (females more than males).
- Bullosis diabeticorum: large acral blisters.
- Scleroderma-like changes: skin tightening (fingers).
- Scleredema diabeticorum: erythema and diffuse skin thickening (upper back, neck, chest, shoulders) with mucin deposition.

Localisation

See above.

Classification

This is according to pathogenesis. Skin manifestations strongly associated with diabetes includes acanthosis nigricans, diabetic dermopathy, diabetic foot syndrome, diabetic thick skin, scleredema, necrobiosis lipoidica, bullosis diabeticorum

Laboratory & other workups

Swabs to exclude an infection may be required.

Dermatopathology

Histopathology different according to the different manifestations. Sometimes clinical diagnosis is enough and skin biopsy can be spared, due to impaired wound healing.

Course

Clinical course depends on the underlying cause. Generalised pruritus tends to persist, even despite good glycaemic control. Often there is a gradual worsening of the skin changes over time.

Complications

The most important complication is generally infection, particularly in the context of the diabetic foot. This may even include osteomyelitis. High dose antibiotics are strongly recommended according to the resistogram. Amputation should be considered as a last resort.

Diagnosis

Always relies on a secure diagnosis of diabetes mellitus (fasting plasma glucose >7mmol/L), pathologic HbA1c levels.

Differential Diagnosis

Depends on individual condition.

Prevention & Therapy

Optimise glycaemic control. Regular diabetology/dermatology follow-up in high-risk patients.

Special

None.

References

- [Rongioletti F, Smoller BR \(eds\). \(2010\). Clinical and pathological aspects of skin diseases in endocrine, metabolic, nutritional and deposition disease. New York: Springer.](#)
- [Labib A et al. Skin manifestations of diabetes mellitus. \(2022\). In Feingold KR, et al \(eds\) Endotex \(Internet\) South Dartmouth \(MA\) MD Text.com, Inc 2000- PMID 29465926](#)

6.2.2 Porphyria Cutanea Tarda

Grading & Level of importance: B
V. del Marmol, Brussels; J. White, Brussels



ICD-11

5C58.10

Synonyms

Nil.

Definition

Porphyria cutanea tarda is a disease caused by a chronic disturbance in hepatic porphyrin synthesis, resulting in accumulation of photosensitive porphyrins in the skin and other organs.

Epidemiology

The disease typically manifests around the age of 40-70 years. It is a rare condition, with less than 1% of the general population affected. However, it accounts for around 1/3 of all cases of porphyria. Males are twice as likely as women to suffer from this disease.

Aetiology & Pathogenesis

The aetiology is genetic and may be inherited in an autosomal dominant fashion, or acquired. It is characterised by a deficiency in uroporphyrinogen-III decarboxylase. External triggers include alcohol, medications (anti-fungals, analgesics, barbiturates, contraceptive pill, chloroquine and many others) and poisoning with heavy metals (such as lead and arsenic). Liver infections such as HIV and/or hepatitis C may cause or unmask the disease.

Signs & Symptoms

Blistering occurs in light-exposed areas and with minimal trauma (e.g. on the face and backs of the hands). As the blisters are fragile and easily de-roofed, commonly only erosions are seen. Skin frequently heals with the appearance of milia and atrophy. Hypertrichosis variably occurs on the cheeks and temples. Pseudoscleroderma is rarely seen. Some patients notice that their urine is discoloured.

Localisation

Typically, the face and dorsa of the hands are affected, but occasionally other body sites may be involved.

Classification

Type 1 (exogenous cause) and type 2 (genetic).

Laboratory & other workups

Laboratory tests are essential for a firm diagnosis, as there can be considerable clinical overlap between different forms of porphyria.

Blood: elevated liver enzymes are usually seen.

Urine: levels of uroporphyrins (I > III) may be measured to confirm the clinical diagnosis.

Dermatopathology

The features on biopsy are not specific but may include subepidermal blisters, thickened basement membrane and thickened vessels. Biopsy may be helpful to exclude other causes of blistering (e.g. autoimmune blistering conditions).

Course

The course is often chronic. It is important to eliminate as many trigger factors as possible (even in type 2) e.g. reduction of alcohol intake, avoidance of prohibited medications etc. Lists of safe medications are available online.

Complications

Complications include cosmetically troublesome hypertrichosis, delayed wound healing, and scarring.

Diagnosis

Whilst a clinical diagnosis may be possible in classical cases, the diagnosis should always be confirmed via laboratory tests.

Differential Diagnosis

The differential diagnosis includes other porphyrias (e.g. variegate porphyria), blistering disorders and pseudoporphyrias.

Prevention & Therapy

Sun avoidance is important with the use of topical sunscreens (SPF >30) and textile protection. Avoidance of triggers (such as alcohol, hepatotoxic medications) can be very helpful clinically. If iron stores are very high, regular phlebotomy may be employed. Chloroquine given in very low doses may be an effective treatment.

Special

None.

References

- [Handler NS, Handler MZ, Stephany MP, Handler GA, Schwartz RA.\(2017\). Porphyria cutanea tarda: an intriguing genetic disease and marker. Int J Dermatol. 56\(6\): e106-e117. doi: 10.1111/ijd.13580. PMID: 28321838](#)

6.2.3 Erythropoietic Protoporphyrin (EPP)

Grading & Level of importance: C
G. Burg, Zürich



ICD-11

AIB2.0; AIB2.1

Synonyms

EPP, acute phototoxic porphyria

Definition

Chronic polyetiologic disturbance of the hem-(porphyrin) biosynthesis in the erythrocytes, leading to accumulation of photosensitive porphyrins in the skin and other organs.

Epidemiology

Second most common porphyria (after porphyria cutanea tarda), affecting 1-2 per 100'000 population. Symptoms (light sensitivity) start early in life (<10 years) and the condition is often misdiagnosed for up to 10 years because of the absence of clinically visible symptoms (sometimes patients are accused of malingering). There is low clinical penetrance, with less than 10% of mutation carriers developing overt clinical symptoms.

Aetiology & Pathogenesis

Autosomal-(co-dominant) recessive inherited mutation, usually in the ferrochelatase (FECH) -gene, in which more than 175 mutations have been reported. The single intronic nucleotide polymorphism (SNP) (rs: 2272783) of C at IVS3-48 in trans to a mutated FECH (Gouya et al.). The promoter activity on the transcriptional activity of the FECH is decreased.

A large number of red fluorocytes are observed in the peripheral blood under the fluorescence

microscope (green or blue excitation wavelength). The reduced mounting of iron-ions in the hemoglobine of the erythrocytes leads to accumulation of its precursor protoporphyrin, which is released into the circulation, triggering singlet oxygen free radical reactions by visible light and the long wave UVA (400nm, Soret-band), that lead to severe neuropathic pain, which lasts hours to days. Protoporphyrin is excreted through the biliary system.

Rarely EPP-like symptoms can occur in conjunction with sideroblastic anemia related to myelodysplastic conditions.

Variant: X-linked protoporphyria: In contrast to EPP, there is increased activity of the ALA synthase 2 enzyme in the red blood cell line leading to total increased protoporphyrin production with increase in zinc chelated protoporphyrin whereas the activity of the ferrochelatase enzyme is normal.

Signs & Symptoms

The clinical features are very different from those of the porphyria cutanea tarda, which presents mainly with blistering, fragility, scarring and formation of milia.

Acute: Burning (not itching) of the skin upon sun exposure, also through window glass or windscreen of the car, which filters only UVB but not the pathogenetically important visible light and UVA. Acute erythema and edema in the light exposed areas (face, hands, lower arms). Never blistering. Edema due to damage of the vessel endothelia. Petechia may occur.

Permanent chronic changes: cerebriform lichenification and thickening of the skin, especially on the back of the nose, margins of the conch of the ear, back of hands and fingers.

Urine: normal color, since protoporphyrin is not water soluble and therefore is excreted through the stool.

Localisation

Face, back of the nose, margins of the concha of the ear, back of hands and fingers. Sun exposed areas.

Classification

Hepatic porphyrias

- Prototype: porphyria cutanea tarda: sporadic, genetic/familial, toxic Erythropoietic porphyrias
 - Erythropoietic protoporphyria
 - Mild phenotype
 - Severe phenotype
 - X-linked protoporphyria
- Congenital erythropoietic porphyria (Günther)

Laboratory & other workups

Diagnostic rapid test: red fluorescence of some (30%) erythrocytes in a blood smear under the fluorescence microscope (blue light excitation). Cave: quick fading. The blood smear should be handled in a dark room.

Urine: negative, since protoporphyrin is not water soluble

Stool: qualitative and quantitative determination of protoporphyrin (special laboratory). Determination of the defective enzymes.

Blood: full blood count and liver function tests; protoporphyrin level (special laboratory)

Dermatopathology

Acute: dermal edema; chronic: lichenification; perivascular PAS positive deposits.

Course

Acute with chronic sequelae. Risk of liver failure, gallstones and anemia.

Complications

Limitation of the open-air mobility; accusation of hypochondric behavior.

Protoporphyrin is cleared by the hepatobiliary system and may exhibit a hepatotoxic effect and potentially lead to liver failure. Mild hypochromic microcytic anemia and cholelithiasis may develop.

Diagnosis

Typical clinical features; confirmation by laboratory tests.

Differential Diagnosis

- Other photodermatoses without blisters.
- Drug-induced phototoxicity and atypical polymorphic light eruption,
- idiopathic solar urticaria.

Blisters never occur in erythropoietic protoporphyria.

Prevention & Therapy

Prevention: advice on environmental, behavioural, clothing, and topical sunscreen photoprotection (SPF/LSF > 30). Cave: Vitamin D-deficiency due to lack of vitamin-D production in the skin by UVB. Photoprotection against long wave UVA; oral β -carotene (60-180 mg/day); afamelanotid; narrowband UVB phototherapy.

References

- [Lecha, M., Puy, H., & Deybach, J. C. \(2009\). Erythropoietic protoporphyria. Orphanet J Rare Dis, 4, 19. doi:10.1186/1750-1172-4-19. PMID: 19744342; PMCID: PMC2747912.](#)
- [Balwani, M. \(2019\). Erythropoietic Protoporphyria and X-Linked Protoporphyria: pathophysiology, genetics, clinical manifestations, and management. Mol Genet Metab, 128\(3\), 298-303. doi: 10.1016/j.ymgme.2019.01.020. Epub 2019 Jan 24. PMID: 30704898; PMCID: PMC6656624.](#)
- [Phillips, J. D. \(2019\). Heme biosynthesis and the porphyrias. Mol Genet Metab 128\(3\): 164-177. doi: 10.1016/j.ymgme.2019.04.008. Epub 2019 Apr 22. PMID: 31326287; PMCID: PMC7252266.](#)
- [Muschalek W, Hermasch MA, Poblete-Gutierrez P. and Frank J. \(2022\). The Porphyrrias. J Dtsch Dermatol Ges 20\(3\): 316-331. doi: 10.1111/ddg.14743. PMID: 35304965.](#)

6.2.4 Congenital Erythropoietic Porphyria (ERP)

Grading & Level of importance: C
G. Burg, Zürich



ICD-11

AIB1

Synonyms

Disturbance of the heme biosynthesis.

Definition

Chronic polyetiologic disturbance of the hem-(porphyrin) biosynthesis in the erythrocytes, leading to accumulation of photosensitive porphyrins in the skin and other organs, clinically presenting blistering,

chronic ulcers, and delayed healing and mutilation of light-exposed parts.

Hypersplenism, haemolytic anaemia with thrombocytopenia may occur.

Epidemiology

Very rare. Symptoms (light sensitivity) starting early in life (<10 years of age); Incidence 0.1:100000. Onset in adult life are milder variants.

Aetiology & Pathogenesis

Autosomal-recessive inherited biallelic mutation of the heme biosynthesis due to deficient activity of the fourth enzyme of the heme biosynthetic pathway, uroporphyrinogen III synthase, which is encoded by the uroporphyrinogen III synthase gene leading to accumulation of the non-physiologic porphyrinogen I isomers, uroporphyrinogen I and coproporphyrinogen I in bone marrow erythroid precursors and erythrocytes and in skin, teeth and internal organs. The isomer I porphyrinogens undergo auto-oxidation to the corresponding porphyrins, which are photo-activated.

Signs & Symptoms

Severely affected patients are transfusion-dependent throughout life, have secondary hypersplenism and significant cutaneous involvement, presenting as extreme light hypersensitivity, starting at birth. Blister formation and disfigurement due to scarring mutilations by UV light ("wolf children"). Hypertrichosis and poikiloderma. Risk of carcinoma development on scars. Red fluorescence of urine and red teeth (erythrodonty: brown teeth that fluoresce under Wood's lamp (about 410 nm) illumination).

Localisation

Light exposed areas.

Classification

Hepatic porphyrias

- Prototype: porphyria cutanea tarda: sporadic, genetic/familial, toxic

Erythropoietic porphyrias

- Erythropoietic protoporphyria
- Congenital erythropoietic porphyria (Günther)

Variegate porphyria and hereditary coproporphyria are acute porphyrias, which present with abdominal

pain and skin manifestations as seen in porphyria cutanea tarda.

Laboratory & other workups

Determination of the defective enzymes and of uroporphyrinogen I in the urine (special laboratory). Red fluorescence of the urine and of teeth under Wood's lamp (about 410 nm).

Dermatopathology

Subepidermal blisters; scarring tissue.

Course

Acute with chronic sequelae.

Complications

Secondary skin infections with subsequent bone resorption and photomutilation and scars, leading to loss of digits and facial profile. Secondary hypersplenism, haemolytic anaemia with thrombocytopaenia may occur.

Diagnosis

Typical clinical features; confirmation by laboratory tests.

Differential Diagnosis

Other photodermatoses. Porphyria cutanea tarda and other blistering dermatoses.

Prevention & Therapy

Prevention: strict avoidance of sun and light exposure as well as erythrocyte transfusions to maintain the hematocrit >35; protection against visible light and long wave UVA.

Topical: Light protection (SPF/LSF > 30). Cave: Vitamin D-deficiency due to lack of vitamin-D production in the skin by UV.

Systemic: Bone marrow or hematopoietic stem cell transplantation is the only curative approach and has to be considered in a multidisciplinary approach.

References

- [Erwin, A. L., & Desnick, R. J. \(2019\). Congenital erythropoietic porphyria: Recent advances. Mol Genet Metab, 128\(3\), 288-297.](#)
- [Fritsch, C., Bolsen, K., Ruzicka, T., & Goerz, G. \(1997\). Congenital erythropoietic porphyria. J Am Acad Dermatol, 36\(4\), 594-610.](#)
- [Dickey, A. K., R. K. Leaf and M. Balwani \(2024\). "Update on the Porphyrins." Annu Rev Med 75: 321-335.](#)
- [Yasuda, M., B. Chen and R. J. Desnick \(2019\). "Recent advances on porphyria genetics: Inheritance, penetrance & molecular heterogeneity, including new modifying/causative genes." Mol Genet Metab 128\(3\): 320-331.](#)

6.2.5 Xanthomas

Grading & Level of importance: C



Z. Bukvić Mokos, Zagreb; B. Marinović, Zagreb; F. Rongioletti, Milan

ICD-11

Code: e.g. 5C80.0Z; 5C80.2

Synonyms

None.

Definition

Tumour-like accumulation of lipid-laden macrophages (foam cells).

Epidemiology

Xanthomas are a common manifestation of hyperlipidemia. Xanthelasma are the most common xanthomas and comprise 6% of eyelid tumors, usually occurring in persons older than 50 years.

Aetiology & Pathogenesis

Xanthomas usually develop because of systemic or local disturbance in lipid metabolism.

Signs & Symptoms

- Xanthelasmas: soft, flat, yellowish papules.
- Eruptive xanthomas occur in the setting of severe hypertriglyceridemia: multiple, small yellow papules.
- Tuberous xanthomas occur in the setting of hypercholesterolemia: firm, yellow nodules. Tendinous xanthomas: subcutaneous nodules.
- Plane xanthomas may be associated with monoclonal gammopathies: yellow macules.
- Verruciform xanthomas are not associated with dyslipidemia.
- Xanthoma nevus.

Localisation

Xanthelasmas: eyelids. Eruptive xanthomas: buttocks, shoulders, extensor sites of the extremities. Tuberous xanthomas: knees, elbows. Tendinous xanthomas occur in familial hyperlipidemia syndromes: along the extensor tendons of the hands, the feet, and the Achilles tendons. Plane xanthomas: any site; often in palmar creases. Verruciform xanthomas: oral mucosa and anogenital skin.

Classification

See Symptoms.

Laboratory & other workups

Plasma levels of triglyceride, cholesterol, and HDL-cholesterol are evaluated.

Dermatopathology

The main histologic feature are vacuolated macrophages (foamy macrophages) in the dermis. Occasionally, typical multinucleated histiocytes (Touton giant cells) are present.

Course

The lesions are usually slowly enlarging; eruptive xanthomas may resolve spontaneously.

Complications

Complications, such as atherosclerosis, pancreatitis, develop because of hyperlipidemia.

Diagnosis

Diagnosis is based on clinical features and may be confirmed by histology.

Differential Diagnosis

Syringoma; nodular localized cutaneous amyloidosis.

Prevention & Therapy

Therapy: treatment of hyperlipidemia; for cosmetically disturbing lesions: surgery or CO2 laser. Treatment of xanthelasma: topical trichloroacetic acid, excision, laser (CO2 laser, Q-switched Nd: YAG laser, Er: YAG laser).

Prevention: diet (in cases of hyperlipidemia).

Special

None.

References

- [Vy Mai & Akhondi H \(2022\) Xanthomas: Differentiating atherogenic from nonatherogenic. CLEVELAND CLINIC JOURNAL OF MEDICINE 89; 429-431; DOI: https://doi.org/10.3949/ccjm.89a.21088](https://doi.org/10.3949/ccjm.89a.21088)

6.3 Pigmentary Disorders

6.3.3 Melasma/Chloasma/PIH

Grading & Level of importance: B

M. Bagot, Paris; G. Burg, Zürich; H. Gollnick, Magdeburg



ICD-11

LF104

Synonyms

Post-inflammatory hyperpigmentation (PIH), chloasma (hormonal), melasma.

Definition

Troublesome hyperpigmentation of the face, mostly in females.

Epidemiology

Frequent disorder. Mostly appearing due to physical, chemical or drug induced changes of melanocyte activity or basal membrane destruction and melanophage accumulation. Chloasma in women during and after pregnancy or under hormonal contraception. Especially in dark skinned people (South America, Southeast Asia, mediterranean region).

Aetiology & Pathogenesis

Physical (UV-light), chemical (cosmetics), drugs (minocycline), hormones (women, pregnancy, contraceptives) and genetic disposition (coloured skin/phototypes III - VI) play an important role. Postinflammatory hyperpigmentation from acne lesions, after traumatic events, friction or facial inflammatory disorders.

Signs & Symptoms

Irregular, «dirty-gray», muddling, poikilodermic, cosmetically compromising, circumscribed hyperpigmentation of the face, forehead and neck. In chloasma distribution in the middle line/front of the lower trunk. PIH may occur elsewhere depending on causative agent or trauma.

Localisation

Face, predominantly cheeks and zygomatic arch, forehead, neck and other areas.

Classification

Depending on aetiology: physical, chemical, hormonal, post-traumatic.

Laboratory & other workups

Not needed. Sometimes endocrinological examination.

Dermatopathology

Usually not needed. In order to determine the localisation of pigment a biopsy may sometimes be recommended. Increased deposits of melanin in basal keratinocytes and in melanophages of the dermis. Lasers can dermoscopy can be used too.

Course

Chronic; depends on aetiology.

Complications

Cosmetically compromising; psyche, decreased quality of life index.

Diagnosis

Typical clinical pictures.

Differential Diagnosis

Phototoxic dermatitis; (exogenous) ochronosis. Pigmentary skin deposits (minocycline).

Prevention & Therapy

Strict UV-protection. Topical bleaching, using a combination of hydroquinone, tretinoin (Vit A- acid) and hydrocortisone (Kligman-formula). Azelaic-acid. Thiazolidin. Superficial chemical peeling and laser treatment have a limited effect and success depends on skin area and depth of pigmentation. Skin pastilla grafts. Sometimes when obsessive manipulation is causative psychosomatic counselling is necessary.

Special

None.

References

- [Jalal Maghfour, Jadesola Olayinka, Iltefat H. Hamzavi, Tasneem F. Mohammad \(2022\) A Focused review on the pathophysiology of post-inflammatory hyperpigmentation. Pigment cell&Melanoma research.35,3: 320-327](#)
- [Rajanala, S., Maymone, M. B. C., & Vashi, N. A. \(2019\). Melasma pathogenesis: a review of the latest research, pathological findings, and investigational therapies. Dermatol Online J, 25\(10\).](#)

6.3.4 Vitiligo

Grading & Level of importance: B

H. Gollnick, Magdeburg; V. del Marmol, Brussels; J. White, Brussels



ICD-11

ED63.0

Synonyms

None.

Definition

Acquired, circumscribed depigmentation induced by auto-immune destruction of melanocytes in the epidermis and hair follicle.

Aetiology & Pathogenesis

It is a complex, initially reversible, autoimmune process affecting melanocytes. Defects in autophagy can lead to reduced ability to resist oxidative stress, leading to increased expression of the pro-inflammatory protein HSP70. IFN- γ -CXCR9/10-CXCR3-CD8+ T-cells are initiated and attack melanocytes.

Signs & Symptoms

The lesions are asymptomatic but cosmetically noticeable. Circumscribed small (sometimes confetti-like) macules develop, which may also be confluent to produce larger patches. The disease is usually symmetrical and shows a complete depigmentation (rather than hypopigmentation), especially when examined under Wood's light.

Localisation

Vitiligo favours the face, hands, ano-genital region and peri-umbilical area, but any location is possible. Sometimes the disease is generalized, with little body surface area (BSA) spared.

Rule of nine procedure for estimation of BSA. Other scoring systems are Vitiligo Area Scoring Index (VASI) or Vitiligo Extent Score (VES).

Reliable marker of an acute vitiligo are the Koebner-phenomen, lesion of confetti type, hypo- and trichrome- lesions, inflammatory vitiligo with presence of erythematous margin around the depigmented lesion and leucotrichia.

Classification

- **Segmental** (affecting only one side of the body)
- **Non-segmental** (affects both sides of the body)
- **Mixed forms**
- **Non-classified forms**

Laboratory & other workups

There is an association with atopy and autoimmune thyroid disease, although screening for such diseases is not mandatory but TSH and thyroid antibody testing are recommended.

Dermatopathology

Biopsies are only rarely done in cases of diagnostic difficulty but on histological analysis, absent epidermal pigment is seen, with a lack of melanocytes and a lymphocytic inflammatory infiltrate in early phases.

Course

Spontaneous resolution is possible. Acral sites (hands, feet and ano-genital areas) are often resistant to treatment; facial vitiligo is often more responsive to treatment than other body sites. Treatment response generally declines with the age of the lesion.

Complications

Because of lack of biological filter (melanin pigment), there is an increased risk of sunburn, and consequent actinic damage. Stigmatisation of vitiligo patients, trend for depressive disorders and reduced quality of life leads to “willingness-to-pay” of treatments without proven benefit-risk assessment and evidence.

Diagnosis

The diagnosis is usually made on clinical grounds. Examination with Wood’s light can be helpful, especially in paler skin types.

Differential Diagnosis

The differential diagnosis includes any condition causing hypopigmentation such as pityriasis versicolor, naevus anaemicus, naevus depigmentosus, pityriasis alba, progressive macular hypomelanosis, dry skin

in darker skin types, macular forms of lichen sclerosus, any cause of post-inflammatory hypopigmentation (leucodermas of different origin) or other rare, hereditary causes of hypopigmentation (e.g. piebaldism, albinism etc).

Prevention & Therapy

Early treatment is critical for therapeutic success.

Topical potent/superpotent corticosteroids with or without vitamin D3 or topical calcineurin inhibitors are first line treatments. Pseudocatalase creme. Phototherapy may be considered but treatment courses are long. Consider melanocyte-keratinocyte transplants from normally pigmented skin. Afamelanotide (Nle5-d-Phe7- α -MSH) with UVB phototherapy. New treatments such as JAK inhibitors are recently launched to the market (topical ruxolitinib).

Cosmetic camouflage with make-up may give good results in certain cases. Bleaching agents for normally pigmented skin may be used if the vitiligo is widespread.

Topical sunscreens are recommended to prevent sun damage.

Counselling/psychological support should be considered especially for those with darker skin types, where the psychosocial impact of the disease may be severe.

Special

None.

References

- [Cunningham KN, Rosmarin D. \(2023\). Vitiligo Treatments: Review of Current Therapeutic Modalities and JAK Inhibitors. Am J Clin Dermatol. Mar;24\(2\):165-186. doi: 10.1007/s40257-022-00752-6. Epub 2023 Jan 30. PMID: 36715849.](#)
- [Perez-Bootello J, Cova-Martin R, Naharro-Rodriguez J, Segurado-Miravalles G. \(2023\). Vitiligo: Pathogenesis and New and Emerging Treatments. Int J Mol Sci. Dec 9;24\(24\):17306. doi: 10.3390/ijms242417306. PMID: 38139134; PMCID: PMC10743634.](#)
- [Mosca S, Morrone A. \(2023\). Human Skin Pigmentation: From a Biological Feature to a Social Determinant. Healthcare \(Basel\). Jul 22;11\(14\):2091. doi: 10.3390/healthcare11142091. PMID: 37510532; PMCID: PMC10379278.](#)

6.3.5 Oculo-cutaneous Albinism and Piebaldism

Grading & Level of importance: C
V. del Marmol, Brussels; J. White, Brussels



ICD-11

Codes: oculocutaneous albinism: EC23.20; partial albinism EC23.2Y; albinism-deafness syndrome LD2H.Y; piebaldism EC23.2Y.

Synonyms

None.

Definition

These genetic conditions cause partial or total depigmentation of the skin, hair or eyes. Clinical manifestations are eight known subtypes of OCA.

Epidemiology

Albinism affects 1 in 20,000 people but this is highly variable in different populations. It may be as high as 1 in 1,000 people in some genetically isolated communities.

Piebaldism affects 1 in 40,000 Caucasians. Data on non-Caucasian populations is patchy.

Aetiology & Pathogenesis

Albinism usually shows autosomal recessive inheritance. It is a non-inflammatory disease, due to reduced or absent tyrosinase activity, causing reduced or absent melanin pigment, despite normal numbers of melanocytes (unlike vitiligo, where there are fewer melanocytes). This is due to interruption of the synthesis of melanin via enzyme malfunction or absence, as well as other, rarer, mechanisms.

Piebaldism usually shows autosomal dominant inheritance. Mutations in the KIT proto-oncogene cause reduced melanocytes.

Signs & Symptoms

Albinism is usually asymptomatic for the skin, apart from a tendency to sunburn. There is however

considerable potential for cosmetic embarrassment, particularly in those from ethnic groups with darker skin types. Reduction of visual acuity, nystagmus, strabismus, iris translucency, foveal hypoplasia, fundus hypopigmentation, and abnormal decussation of retinal ganglion cell axons at the optic chiasm.

Piebaldism causes the same skin problems as albinism, but there are no ocular features. In both conditions, the changes are present from birth, unlike vitiligo.

Localisation

Albinism: the absence of skin pigmentation is usually generalised, but more localised forms (i.e. periorificial) exist. In some subtypes, the scalp hair may be a yellow colour and the leg hairs dark.

Piebaldism: A characteristic white forelock of hair is almost always seen in the mid forehead. Depigmented skin is commonly patchy, with typical sites including mid extremities and central trunk.

Classification

Albinism: this is according to the particular defect in melanin synthesis resulting from mutations in the tyrosinase protein genes.

Piebaldism: no classification.

Laboratory & other workups

Differentiating different types of albinism is not usually of clinical relevance and such tests are not routinely available apart from in specialised centres. One particular test is to incubate a hair bulb with tyrosinase. This test may differentiate tyrosinase positive and negative forms of albinism. Regular ophthalmologic examination is necessary.

Dermatopathology

This is not required and is not generally helpful, unless to exclude other conditions.

Course

The conditions are lifelong.

Complications

The most important cutaneous complication is of skin cancer. The risk of developing a skin cancer is greatly elevated as there is no natural sun protection in albinos. They are most prone to develop squamous cell carcinomas and this may occur at very young ages, particularly in those who live in tropical climates. Decreased quality of life can be observed in both albinism and piebaldism. Ocular symptoms.

Diagnosis

The diagnoses are clinical.

Differential Diagnosis

Vitiligo, post-inflammatory hypopigmentation, idiopathic guttate hypomelanosis, rare genetic syndromes e.g. Waardenburg syndrome. There are several other syndromic disorders that can present with OCA, including Hermansky-Pudlack syndrome and Chediak-Higashi syndrome.

Prevention & Therapy

Camouflage. No known effective treatments for the underlying problem.

Limited surgical procedures (skin transplants) are performed in countries with darker skin.

Effective sun protection (high factor topical sunscreens and clothing, including hats) essential to avoid skin cancers. Ophthalmological review is mandatory in albinism and psychological support should be offered.

Special

In some cultures, body parts from those suffering from albinism are thought to possess magical or medicinal powers. In those situations, albinos may be persecuted and require police protection.

References

- [Ma, E.Z., Zhou, A.E., Hoegler, K.M. et al. \(2023\). Oculocutaneous albinism: epidemiology, genetics, skin manifestation, and psychosocial issues. Arch Dermatol Res315, 107–116. <https://doi.org/10.1007/s00403-022-02335-1>](https://doi.org/10.1007/s00403-022-02335-1)
- [Mosca S, Morrone A. \(2023\). Human Skin Pigmentation: From a Biological Feature to a Social Determinant. Healthcare \(Basel\). Jul 22;11\(14\):2091. doi: 10.3390/healthcare11142091. PMID: 37510532; PMCID: PMC10379278.](https://pubmed.ncbi.nlm.nih.gov/37510532/)

Chapter 7 - Proctologic Disorders and Psychodermatoses

7.1 Proctologic Diseases

7.1.1 Anal fissure

Grading & Level of importance: B

E. Hiltunen-Back, Helsinki; A. Ranki, Helsinki; A. Salava, Helsinki



ICD-11

DB50

Synonyms

Fissure of the anus.

Definition

Painful linear tear in the distal anal canal.

Epidemiology

Anal fissure is the most frequent cause of acute anal pain in Europe. The incidence peak is in young adults. The reported annual incidence in Europe is 0.11 % (1.1 cases per 1,000 person-years), but due to unreported cases, the true incidence is probably much higher. The prevalence ranges widely by age and patient characteristics (e.g. significantly higher in females). Even after operative fissure treatments, there is a notable rate of recurrences (approximately 1-6 %).

Aetiology & Pathogenesis

The exact etiology of anal fissures is unknown, but usually the initiating factor is a trauma caused by hard or forceful defecation. Obesity, low fiber diets, hypothyroidism, anal tumors and chronic constipation have been associated with the development of anal fissures. Regarding pathogenesis, a genetic disposition is recognized. Additional possible abnormalities are spasms, hypertonicity and hypertrophy of the internal anal sphincter that lead to elevated anal canal and sphincter resting pressures. Anal fissures can also occur after trauma during delivery and as a complication of anal surgery. Anal fissures may infrequently be associated with Crohn's disease, HIV infection and tuberculosis.

Signs & Symptoms

The typical symptom is acutely occurring lacerating pain during bowel movements, with the pain lasting even hours after defecation. The pain commonly recurs with every defecation, which may lead to a cycle of worsening constipation, harder stools, and increase of anal pain and discomfort (vicious cycle). Many patients note bright-red blood on the toilet paper or stool. Small amounts of blood may be visible in the toilet bowl, but unlike hemorrhoids, significant bleeding does not usually occur. Thus, anal fissures do not cause anemia. The symptoms of anal fissure are relatively specific, and the diagnosis can often be made on patient history alone.

Localisation

Idiopathic anal fissures are usually localized dorsal in the middle line. If fissures are detected in other localizations, an underlying pathology (e.g. Crohn's disease) should be excluded.

Classification

Not applicable.

Dermatopathology

Not applicable.

Course

Most frequently anal fissures resolve spontaneously. After a duration of 6-8 weeks the anal fissure is regarded as chronic. Anal fissures have a tendency to recur; the recurrence rate with non-surgical treatments is high, whereas that of surgical sphincterectomy is less than 6%.

Complications

A typical complication is a submucous abscess, which impedes wound healing. An abscess can lead to fistulas of the skin or mucosa surface. More rare complications include anal thrombosis, ulceration and incontinence. In immunocompromised patients, the fissure can serve as a port of infection.

Diagnosis

The diagnosis is usually made clinically, based on the typical findings of inspection. Proctoscopic and rectal examination is painful and often not necessary. If the anal fissure is not visible, the tender wound base of the fissure may be recognizable by gentle digital examination.

If symptoms are typical and if the fissure is located in the posterior or anterior midline (idiopathic anal fissure), no further tests (biopsy and endoscopy) are necessary.

Occasionally, fissures are not easily visible and proctoscopy is required to locate them.

Endoscopy (e.g. to exclude Crohn disease) and biopsy (e.g. to exclude malignancy) are needed in the following constellations: fissure located in an untypical location (e.g. laterally), chronic fissures with protracted wound healing, failure to respond to appropriate therapy, or those who have recurrent anal fissures after surgical therapy.

If fissures are located off the midline, if there are multiple fissures or if an underlying illness is conceivable (notably Crohn disease, anal squamous cell cancer, or HIV infection), appropriate tests should be ordered. These may include the following: microbiologic swabs, systemic inflammatory parameters, fecal calprotectin, HIV testing, biopsy.

Differential diagnosis

Relevant differential diagnoses include perianal abscess (pain and palpable fluctuation), perianal fistulas (secret and/or pus draining) and thrombosed hemorrhoids.

Prevention & Therapy

First-line medical therapy includes stool-bulking agents, such as fiber supplementation and stool softeners. Laxatives should be used as needed to maintain regular bowel movements and treat underlying constipation.

Second-line therapy consists of topical medicaments that decrease the muscle tonus of the inner anal sphincter. Nitroglycerin applied in different formulations directly to the internal anal sphincter (e.g. nitroglycerin 0,4% ointment or anal suppositories). Comparable to the use of nitroglycerin ointment, nifedipine ointment is also available in some European countries. The topical treatment should be continued even after the symptoms subside (e.g. 2 months).

In addition to topical treatments, botulinum toxin has been used to treat acute and chronic anal fissures, but poses a small risk of injection site infections. The effect lasts some months, until the regeneration of free nerve endings.

If the anal fissure is unresponsive to conservative treatment and lasts over 2 months surgical intervention should be evaluated. Symptomatic chronic fissures should be treated operatively because they only rarely heal spontaneously.

In chronic fissures, surgical revision with possible skin-subcutaneous flap reconstructions may lead to healing. Other surgical therapies consist of sphincter dilatation or operative sphincterectomy, which pose a small risk of postoperative incontinency (usually concerning gases).

Special

Not applicable.

References

- [Klein JW. Common anal problems. \(2014\). Med Clin North Am. May;98\(3\):609-23. doi: 10.1016/j.mcna.2014.01.011. Epub 2014 Mar 21. PMID: 24758964.](#)
- [Nelson RL. \(2016\). Chronic Anal Fissures. Am Fam Physician. Mar 15;93\(6\):498-9. PMID: 26977835.](#)
- [Stewart DB Sr, Gaertner W, Glasgow S, Migaly J, Feingold D, Steele SR. \(2017\). Clinical Practice Guideline for the Management of Anal Fissures. Dis Colon Rectum. Jan;60\(1\):7-14. doi: 10.1097/DCR.0000000000000735. PMID: 27926552.](#)

7.1.2 Haemorrhoids

Grading & Level of importance: B

E. Hiltunen-Back, Helsinki; A. Ranki, Helsinki; A. Salava, Helsinki; S. Salmenkylä, Helsinki



ICD-11

DB60

Synonyms

Piles.

Definition

Swollen blood vessels in the lower rectum (corpus cavernosum recti). Among the most common causes of anorectal complaints. Haemorrhoids are present in around 70% of adults and are often asymptomatic.

Epidemiology

Hemorrhoids are considered as the most common anorectal pathology diagnosed in clinical practice. The prevalence of symptomatic hemorrhoids is estimated at 4,4%. In adult colorectal cancer screening studies (colonoscopy) the prevalence in Europe have been as high as 30%. As many patients are embarrassed to seek treatment, true figures on prevalence are not known.

Aetiology & Pathogenesis

Hemorrhoidal venous cushions are normal structures of the anorectum. However, based on their rich vascular supply, sensitive location near the anal sphincter and their predisposition to dilate and prolapse, they are common causes of anal problems. Hemorrhoids are of multifactorial origin including decreased venous return (low-fiber diets, small caliber stools), straining during defecation and constipation, pregnancy and more rarely portal hypertension and anorectal varices.

Signs & Symptoms

Symptoms range from mild pruritus to fresh bright rectal bleeding. In addition, sharp pain or burning during and after defaecation, weeping, drainage of mucus, feeling of incomplete bowel movement, faecal urgency may occur. Four degrees of severity: see classification.

Localisation

Most common sites (dorsal lithotomy position): 3, 7 and 11 o'clock on the anal ring.

Classification

Hemorrhoids are classified on clinical grounds.

- Grade I hemorrhoids project into the anal canal and often bleed but do not prolapse
- Grade II hemorrhoids may protrude beyond the anal verge with straining or defecating but reduce spontaneously when straining ceases (i.e., return to their resting point by themselves)
- Grade III hemorrhoids protrude spontaneously or with straining and require manual reduction (i.e., require manual effort for replacement into the anal canal)
- Grade IV hemorrhoids chronically prolapse and cannot be reduced; these lesions usually contain both internal and external components and may present with acute thrombosis or strangulation.

Laboratory & other workups

Proctoscopy and rectoscopy.

Dermatopathology

Hemorrhoids are clusters of vascular tissue (arterioles, venules, arteriolar-venular connections), smooth muscle (parts of the anal sphincter) and connective tissue of the normal epithelium of the anal canal. Hemorrhoidal bleeding is arterial and not venous and usually has a bright red color.

Course

Most resolve spontaneously or with conservative medical therapy alone.

Complications

Complications can include irritative perianal dermatitis, haemorrhoidal vein thrombosis, secondary infection, ulceration, abscess, and incontinence. The recurrence rate with nonsurgical techniques is 10-50%, whereas that of surgical hemorrhoidectomy is less than 5%.

Diagnosis

The diagnosis is usually done by case history, inspection and clinical examination. Proctoscopy should be carried out to evaluate any bright-red rectal bleeding. Colonoscopy should be considered in the evaluation of any new onset rectal bleeding in patients over 50 years of age and in cases that are not typical of hemorrhoids. These include the presence of risk factors for colonic malignancy or in the setting of rectal bleeding with a negative anorectal examination.

Differential Diagnosis

Relevant differential diagnoses include anal fissure (painful, dorsal location typical), perianal abscess (pain and palpable fluctuation), perianal fistulas (secretion and/or pus draining) and anal prolapse (visible radial folds of the rectal mucosa, fecal incontinence).

Tumorous bleeding sources (cancer).

Prevention & Therapy

Prevention: General measures: anal hygiene (soap-free cleansing after defaecation), natural regulation of bowel movements (high roughage/fibre diet), adequate fluids, sufficient physical activity, no straining

with defaecation.

The treatment options for hemorrhoids are usually based on severity and grading:

Grade I hemorrhoids are treated conservatively (topical symptomatic treatment, increasing fiber intake, treatment of constipation) and avoidance of nonsteroidal anti-inflammatory drugs, spicy or fatty foods. Topical treatments include corticosteroids and topical local anesthetics, menthol, astringents (e.g. ichtammol) and Sitz baths.

Grade II or III hemorrhoids are initially treated with nonsurgical procedures (e.g. rubber band ligation, sclerotherapy, infrared coagulation).

Symptomatic grade III and grade IV hemorrhoids are best treated with surgical hemorrhoidectomy.

Treatment of grade IV hemorrhoids or any incarcerated or gangrenous tissue requires prompt surgical consultation.

Special

Severely bleeding haemorrhoids (e.g. due to portal hypertension, coagulopathies) can acutely be treated with rubber band ligation or sclerotherapy.

References

- [van Tol RR, Kleijnen J, Watson AJM, Jongen J, Altomare DF, Qvist N, Higuero T, Muris JWM, Breukink SO. \(2020\). European Society of ColoProctology: guideline for haemorrhoidal disease. Colorectal Dis. Jun;22\(6\):650-662. doi: 10.1111/codi.14975. Epub 2020 Feb 17. PMID: 32067353.](#)
- [Sun Z, Migaly J. \(2016\). Review of Hemorrhoid Disease: Presentation and Management. Clin Colon Rectal Surg. Mar;29\(1\):22-9. doi: 10.1055/s-0035-1568144. PMID: 26929748.](#)

7.1 Psychodermatoses

7.2.1 Trichotillomania

Grading & Level of importance: C
V. del Marmol, Brussels; J. White, Brussels



ICD-11

6B25.0

Synonyms

Hair pulling disorder; compulsive hair pulling.

Definition

This condition is characterised by compulsive self-manipulation of hairs through pulling, twisting and plucking (or other mechanisms), leading to localised areas of alopecia.

Epidemiology

The disease is usually seen in adolescence and is much more commonly seen in women than men (3-10:1). It is present in <1:1000 of the normal population.

Aetiology & Pathogenesis

The aetiology is psychological and the condition may be considered part of the impulse-control disorder spectrum. Individuals with this disease feel compelled to manipulate the hair to an excessive degree. There may be underlying psychological disease such as body dysmorphic disorder, anxiety, depression or psychosis.

Signs & Symptoms

The patient is usually distressed by the hair loss and has some insight into the fact that they are causing the manifestations of the disease. Clinically, solitary (rarely multiple) circumscribed areas of incomplete hair loss with short hairs of varying lengths are seen. Only those hairs reaching 3 mm in length can be removed. The hair shafts often show distal splits and a frayed appearance, especially marked on microscopy. Broken-off hairs may appear as dark dots on the scalp.

Localisation

The most common site is the centro-parietal scalp, because the pain tolerance is higher there. This is known as a tonsure trichotillomania, due to the resemblance with a monastic tonsure.

Classification

An imperfect classification is based on the age of the patient.

The infantile form often results from frustration. The adolescent form may reflect obsessive-compulsive disorder.

Laboratory & other workups

This is only required to exclude other conditions. Other tests may confirm the diagnosis. Trichoscopy may show broken hairs, trichoptilosis (split ends), irregular coiled hairs, empty follicular orifices etc. A trichogram would show an absence of telogen hairs and dystrophic anagen hairs.

Dermatopathology

This is not usually required but would show disrupted follicular anatomy without inflammation and erythrocytes in the hair shaft.

Course

Trichotillomania in young children often resolves spontaneously. In adults, the problem tends to persist.

Complications

Rarely, if the manipulated hair is ingested (a phenomenon known as trichophagia), a trichobezoar (hairball in stomach or intestine) may form. There is a danger of ileus (Rapunzel syndrome) in this situation.

Diagnosis

DSM-5 diagnostic criteria of the American Psychiatric Association for the diagnosis of trichotillomania:

1. Recurrent pulling out of one's hair resulting in noticeable hair loss.
2. An increasing sense of tension immediately before pulling out the hair or when attempting to resist the behaviour.
3. Pleasure, gratification, or relief when pulling out the hair.

4. The disturbance is not better accounted for by another mental disorder and is not due to a general medical condition.
5. The disturbance causes clinically significant distress or impairment in social, occupational, or other important areas of functioning.

Generally, the clinical findings (including trichoscopy) are sufficient for a confident diagnosis, but tests such as a trichogram or biopsy may be required to exclude other conditions. A psychological evaluation is mandatory.

Differential Diagnosis

Alopecia areata, tinea capitis, androgenetic alopecia, adverse effect of medications, post-traumatic.

Prevention & Therapy

Best coordinated by a clinical psychologist or psychiatrist (habit reversal therapy and treatment of any underlying psychological disease). It is unclear whether pharmacological treatment is truly helpful or not.

Special

None.

References

- [Henkel ED, Jaquez SD, Diaz LZ. \(2019\). Pediatric trichotillomania: Review of management. *Pediatr Dermatol.* Nov;36\(6\):803-807. doi: 10.1111/pde.13954. Epub 2019 Oct 6. PMID: 31588617.](#)
- [Mackay CE \(2023\). Trichotillomania: a perspective synthesised from neuroscience and lived experience *BMJ Ment Health*;26:e300795.](#)

7.2.2 Dermatitis Artefacta

Grading & Level of importance: C
V. del Marmol, Brussels; J. White, Brussels



ICD-11

ED00

Synonyms

Artefactual dermatitis; self-inflicted skin disorder.

Definition

A skin condition with no underlying organic cause where the skin changes are self-inflicted. The patient invariably denies causing the skin problem.

Epidemiology

Data on this condition are scarce and the quoted prevalence in paediatric populations of 1:23,000 is probably an under-estimate. Late adolescence and early adulthood seem to be the commonest times to develop the condition. Females are more commonly affected than males (8:1).

Aetiology & Pathogenesis

Dermatitis artefacta is best considered as a cutaneous manifestation of a primary psychiatric disorder. The skin lesions may convey secondary (unconscious) gain for the patient (e.g. attention-seeking) but are not usually directly linked to personal or financial gain. Patients with dermatitis artefacta frequently do not want to be hospitalised, unlike those with factitious disorder imposed on self (Münchhausen syndrome), however there may be some clinical overlap.

Signs & Symptoms

The symptoms are highly variable, but usually include some form of atypical skin lesion, ranging from excoriation (scratch) to ulcer to extensive skin damage or loss. These features may (sometimes deliberately) mimic organic diseases. The way the lesions are created are heterogeneous and may include self-manipulation, or the use of tools or chemical substances.

Localisation

The disease has a predilection for sites of the body that are easily reached.

Classification

Nil.

Laboratory & other workups

Although medical tests are sometimes required to exclude organic disease (e.g. swab for atypical

organisms), unnecessary tests should be generally avoided.

Dermatopathology

The histological findings are highly variable according to the mechanism of injury to the skin.

Course

The disease has a chronic course, even with psychological treatments.

Complications

Depending on the causative mechanism, various complications may ensue including skin or deep infections and scarring. Unnecessary or inappropriate medical interventions or treatments may cause complications.

Diagnosis

The diagnosis is primarily clinical and the presence of bizarre-looking lesions in easily reached locations should lead the clinician to suspect a diagnosis of dermatitis artefacta. However, potential organic causes always should be considered and excluded first. Careful psychological evaluation is required. It should be noted that patients with psychological disease may also have concurrent organic diseases.

Differential Diagnosis

Many possibilities, depending on appearance. Consider pyoderma gangrenosum (including superficial forms). Also consider factitious disorder imposed on self, where there is a conscious gain in the self-harming behaviour.

Prevention & Therapy

It is unclear whether confronting the patient with the clinical diagnosis is counterproductive or not. A psychological review with therapeutic intervention is often helpful, if the patient will accept it. Occlusive dressings or hospital admission (making further manipulation difficult) may help to confirm the diagnosis or provide treatment.

Special

Analogously to Münchhausen syndrome, dermatitis artefacta may rarely occur by proxy i.e. the lesions on the patient may be induced by someone else.

References

- [Torales J, Malvido K, Vázquez MA, Barrios I, Almirón-Santacruz J, Navarro R, O'higgins M, Casas G, Castaldelli-Maia JM, Ventriglio A, González-Urbieta I. \(2023\). Dermatitis Artefacta: A Practical Guide for Diagnosis and Management. Acta Dermatovenerol Croat. Aug;31\(1\):17-23. PMID: 37843085.](#)
- [Lavery MJ, Stull C, McCaw I, Rachel B, Anolik RB \(2018\). Dermatitis artefacta. Clinics in Dermatology;Nov-Dec;36\(6\):719-722. doi: 10.1016/j.clindermatol.2018.08.003. Epub 2018 Aug 16. PMID: 30446194.](#)

7.2.3 Psychogenic Pruritus

Grading & Level of importance: C



V. del Marmol, Brussels; J. White, Brussels

ICD-11

EC90.4

Synonyms

Somatoform itch/pruritus; psycho-somatic pruritus; non-organic itch, functional itch disorder, or functional pruritus.

Definition

An itch disorder where organic causes have been excluded and where itch is the primary symptom and where psychological factors affect triggering, intensity, aggravation, or persistence of the itch (modified from the French Psycho-Dermatology Group 2018).

Epidemiology

Data of the frequency of this condition are not available. Approximately 6% of dermatology clinic patients suffer with the condition. The frequency in the general population is likely to be lower.

Aetiology & Pathogenesis

The aetiology of this condition is poorly understood but there is an interplay of neurological and psychological factors resulting in the symptoms.

Signs & Symptoms

The itch is persistent and often unbearable. Secondary changes such as erythema and erosions/ulcerations may occur.

Localisation

The condition may be generalised or circumscribed. Localised forms may particularly affect the genitalia or scalp.

Classification

Nil, reclassification in ICD 11 expected.

Laboratory & other workups

The condition can only be diagnosed by excluding other causes, so laboratory tests are mandatory. Systemic conditions to exclude are diabetes mellitus, thyroid dysfunction, iron deficiency, uraemia, cholestasis, Hodgkin lymphoma. Primary skin diseases to exclude by examination or tests include dermatitis herpetiformis, scabies, urticaria, cutaneous lymphoma and atopic dermatitis.

Dermatopathology

Biopsy is seldom necessary, apart from excluding another primary skin condition (e.g. cutaneous lymphoma). Histological findings would be non-specific, with excoriations and potentially prurigo nodules.

Course

Usually chronic.

Complications

Psychogenic pruritus is often accompanied by sleep disturbance, which may further exacerbate the condition. The patient's quality of life is invariably severely reduced. Scarring and secondary infections may also occur.

Diagnosis

Sensitivity should be shown when discussing the diagnosis with the patient.

3 compulsory criteria:

1. Localised or generalised itch without primary skin lesion
2. Rash present for > 6 weeks
3. No somatic cause

7 optional criteria:

1. Temporal relation between symptoms and a life event
2. Variations in intensity with stress
3. Diurnal variation
4. Predominance of symptoms at rest
5. Associated psychological disorder
6. Pruritus improved by psychoactive medications
7. Pruritus improved by psychotherapy

Differential Diagnosis

Symptomatic pruritus associated with systemic or cutaneous diseases including scabies, adverse reaction to medications (especially opioids), neuropathic itch, delusional infestations etc.

Prevention & Therapy

Topical antipruritics e.g. menthol, crotamiton etc.

Systemic antipruritics e.g. antihistamines (hydroxyzine, cetirizine etc.) or antihistamines with other psychotropic effects (doxepin, mirtazepine).

Psychotherapy and psychopharmaceuticals initiated by a psychiatrist e.g. fluoxetine and olanzepine.

Special

None.

References

- [Misery, L., Dutray, S., Chastaing, M. et al. \(2018\). Psychogenic itch. Transl Mar 1;8\(1\):52. doi: 10.1038/s41398-018-0097-7. PMID: 29491364; PMCID: PMC5830411.](#)

- [Schneider G, Grebe A, Bruland P, Heuft G, Ständer S. \(2020\). Criteria Suggestive of Psychological Components of Itch and Soma-toform Itch: Study of a Large Sample of Patients with Chronic Pruritus. Acta Derm Venereol. Mar 12;100\(6\):adv00075. doi: 10.2340/000Schn.](#)

7.2.4 Obsessive-compulsive skin disorders (except 7.2.1./2.)

Grading & Level of importance: C
RM. Pujol, Barcelona



ICD-11

6B20.Z

Synonyms

Obsessive–compulsive neurotic skin disorders.

Definition

Group of dermatoses secondary to a chronic psychiatric disorder characterized by obsessions and compulsions.

- Obsessions: Uncontrollable distressful thoughts.
- Compulsions: Recurrent behaviors or thoughts performed in an attempt to decrease the anxiety of the obsessions.
- Excoriation disorder (neurotic excoriations) or pathological skin picking: repetitive picking of skin resulting in noticeable tissue damage.
- Body-focused repetitive behaviors include: onychophagia (nail biting), dermatophagia, onychotillomania (nail picking), trichotillomania, cheek/lip biting, nose/ear picking, and knuckle cracking.

Epidemiology

The estimated prevalence of obsessive-compulsive disorders among adults in USA is 2.3% with a mean age of onset: 19.5 years (males before and females after the age of 10). The disorder often persists for years (mean of 8.9 years). Some culturally specific variants exist.

Excoriation disorder affects 1% to 5% of the population with a female preponderance. The onset is frequently at childhood, adolescence (most common), or adulthood (30-45 years of age).

Body-focused repetitive behavior disorders: onychophagia has a prevalence of 25-60% with a peak during puberty.

Aetiology & Pathogenesis

Obsessive-compulsive and related disorders is a category of the Diagnostic and Statistical Manual of Mental Disorders (DSM-5).

This category also includes:

- Body dysmorphic disorder (BDD), and conditions such as trichotillomania, excoriation disorder (skin-picking), hoarding disorder, substance/medication-induced obsessive-compulsive and related disorder and other body-focused repetitive behaviors (e.g., cheek chewing, cuticle pulling, among others).
- Body-focused repetitive behaviors are included under “unspecified OCD” in DSM-5.
- Some OC related-skin and hair disorders, such as trichotillomania (see Chapter 7.2.1/2)

Signs & Symptoms

- Excoriation disorders: grouped erosions at easily accessible sites.
Picking over areas of acne, scars, scabs, or insect bites.
Skin lesions and scars show angulated borders.
Acne excoriée: acne lesions are scratched and picked.
- Body-focused repetitive behavior disorder: variable clinical features such as: severe nail biting (may cause paronychia and gingival injuries); rubbing of the proximal nail fold and cuticle may result in nail matrix damage. Chronic biting of the skin can cause localized thickened plaques (lichenification). In cheek biting, transverse whitish ridges in the oral mucosa are noted (morsicatio buccorum).

Repeated attempts to decrease or stop skin picking. Associated psychopathology (depression, anxiety, or stress).

Psychiatric co-morbidities include body dysmorphic disorder, substance use, and borderline personality disorder.

Localisation

Acne excoriée: frequent facial involvement.

Body-focused repetitive behavior disorder: nails, fingers, oral mucosa, lips.

Accessible skin areas.

Laboratory & other workups

No abnormalities.

Dermatopathology

Cutaneous ulceration without or minor associated inflammatory infiltrates. Sometimes a skin biopsy may be useful in order to rule out an underlying excoriated itchy dermatosis.

Course

Chronic and recurrent. Waxing and waning evolution.

Complications

Secondary infection, bleeding, and inflammation.

Diagnosis

DSM-5 diagnostic criteria.

Differential Diagnosis

Psychogenic pruritus. Primary psychiatric disorders with secondary excoriations (e.g. delusional infestation or tactile hallucinations). See chapter 7.2.3.

Skin picking secondary to the physiological effects of a substance (e.g. cocaine) or a medical condition (e.g. scabies)

The differential diagnosis of cheek biting includes oral candidiasis; the differential diagnosis also includes lichen planus and white sponge nevus.

In nail biting: nail dystrophy, nail matrix damage and mycotic infections.

Prevention & Therapy

Cognitive-behavioral therapy (CBT) and habit reversal training (HRT) aims at replacing an old habit with a more desirable one).

Anti-depressive and anti-psychotic agents are helpful in treating underlying anxiety. N-acetylcysteine 1,200 to 3,000 mg/ day may reduce skin picking.

In patients with acne excoriée: Additional appropriate acne treatment.

Special

Approximately 90% of individuals with OCD have other psychiatric co-morbidities. The most common are anxiety disorders, depression, impulse control and substance use disorders. Co-morbidities of OCD and depression significantly increase the risk of suicide.

References

- [Zhu TH, Nakamura M, Farahnik B, Abrouk M, Reichenberg J, Bhutani T, Koo J. Obsessive-compulsive skin disorders: a novel classification based on degree of insight. J Dermatolog Treat. 2017; 28:342- 346.](#)
- [Vythilingum B, Stein DJ. Obsessive-compulsive disorders and dermatologic disease. Dermatol Clin. 2005 ;23: 675-80.](#)

7.2.5 Body dysmorphic disorders

Grading & Level of importance: C
A. Gimenez-Arnau, Barcelona; RM. Pujol, Barcelona



ICD-11

6B21.Z

Synonyms

Dysmorphophobia, Dermatologic hypochondriasis.

Definition

Complex chronic obsessive-compulsive mental disorder characterized by excessive preoccupation with a perceived defect in physical appearance that is not observable or significant to others and results in

repetitive, obsessive behaviors and thoughts.

Epidemiology

No gender differences. Global prevalence: 0.7-2.4%.

Adults - 1.9%; college-aged students - 3,3%; adolescents - 1.7%.

Symptoms most commonly begin during adolescence (12-13 years of age).

Causes severe distress, impairs normal functioning and decreases quality of life.

Aetiology & Pathogenesis

Etiology: unknown.

Psychological: emotional unconscious displacement causing feelings of shame and embarrassment (guilt, inferiority feeling, poor self-image).

Unpleasant childhood experience and dysfunctional family background. Persistent feeling of being unloved, insecurity, and rejection.

Signs & Symptoms

Non-apparent deformities become intrusive thoughts that will lead the patient to compensatory behaviors and to engage in compulsions. Broad spectrum of severity, ranging from obsessional worry to frank delusion.

Firm belief that some aspect of his or her appearance is ugly, abnormal, or deformed. Causes severe distress, impairs normal functioning and decreases quality of life.

Localisation

Complete body contour which includes belly, breast, buttocks, genitalia. Special skin concerns facial contouring, scarring, wrinkles, followed by hair concerns (hair loss, thinning, balding, excessive facial hair or body hair) and nose (e.g. too large or misshapen) and nail concerns.

Presentation

Patients with body dysmorphic disorder constantly seek medical and surgical treatments in order to improve their physical appearance. Distortion of the own physical appearance often leads to psychiatric co-morbidities: anxiety, stress, depression, social phobia and personality disorders.

Classification

Categorized under Obsessive Compulsive and Related Disorders in the Diagnostic and Statistical Manual of Mental Disorders (DSM-5).

Laboratory & other workups

Absence of relevant abnormalities.

Dermatopathology

Non-specific minor or absent histopathological changes.

Course

The condition is chronic, and lifelong. Untreated, the prognosis is poor.

Complications

Overtreatment. Skin picking is seen in one-third of patients and can exacerbate mild acne, causing scarring.

Major depression, severe anxiety disorders or personality disorders. Thoughts of suicide.

Diagnosis

Careful clinical history. Physical exam. Evaluate the impact on the patient's quality of life. DMS-5 diagnostic criteria.

Differential Diagnosis

Real dermatological diseases.

Invisible dermatoses.

Prevention & Therapy

Psychiatric consultation needed. Cognitive behavioral psychotherapy and/or selective serotonin re-uptake-inhibitor family of antidepressants. Symptomatic treatment of cutaneous lesions (if present).

Special

A significant proportion of patients entertain thoughts of suicide.

References

- [U Gieler, T Gieler, EMJ Peters, D Linder \(2020\) Skin and Psychosomatics – Psychodermatology today JDDG 18, 11 :1280-1298](#)
- [Koblenzer CS. Body dysmorphic disorder in the dermatology patient. Clin Dermatol. 2017; 35:298- 301.](#)
- [Herbst I, Jemec G. Body dysmorphic disorder in dermatology: a systematic review. Psychiatr Q 2020; 91:1003–10.](#)

Chapter 8 – Special Conditions, Symptoms and Syndromes

8.1 The red face

Grading & Level of Importance: B
C.C. Zouboulis, Dessau



ICD-11

None.

Synonyms

Facial erythema.

Definition

Acute or persisting red colouring or flushing of the face.

Epidemiology

Common skin symptom of several diseases. Within the spectrum rosacea represents 81% of the patients with red face. Prevalence of rosacea 10% and of seborrheic dermatitis 1-3% (young adults 7%). Others are atopic dermatitis and contact dermatitis, psoriasis, sunburn or autoimmune diseases, systemic diseases.

Aetiology & Pathogenesis

Although regarded as a simple finding, the condition may provide important health information. Everyday causes of minor temporary facial flushing include exogenous physical stimuli (mechanical irritation, heat, cold, sunlight, exercise, sexual act, alcohol, spicy foods or drugs) or endogenous ones (embarrassment, anger). A persistent red face may be:

- a. the major sign of a clinically distinct entity, such as eczema / contact dermatitis (most common), photo-contact dermatitis or long-term use of topical steroids,
- b. a manifestation of a particular skin disease, such as seborrheic dermatitis, rosacea, autoimmune diseases or infections,
- c. a sign of an internal disease, such as carcinoid tumor, cardiac or hematological diseases, sarcoidosis or mast cell diseases or

- d. a sign of a rare disease.

Signs & Symptoms

In addition to erythema, warmth, edema, infiltration, teleangiectasias, scaling, serum exudate, vesicles, crusts, lichenification and/or purple discolouration may occur depending on the etiology.

- Inflammatory skin diseases
 - Facial allergic/toxic/irritant dermatitis: In acute cases ill-defined facial erythema, crusts and vesicles and in chronic cases skin lichenification.
 - Seborrheic dermatitis: Erythematous areas in the nasal folds, easily spread to the surrounding areas, glabella, inner part of the eyebrows and along the frontal hairline (corona seborrheica) with overlying, non-adherent, yellowish greasy scales.
 - Facial psoriasis: Erythema rather than thick erythematous-squamous plaques that characterize this condition elsewhere on the body.
 - Acrodermatitis enteropathica: Centrofacial erythema, scaling.
 - Rosacea: Frequent episodes of flushing followed by persistent erythema and telangiectasia in the center of the face (telangiectatica), which may proceed in a minority of erythrotic patients (19%) to formation of papules and pustules (papulo-pustulosa) and even nodules (rhinophyma; phymatous), conjunctivitis (ophthalmica) and mild facial edema persistent after successful treatment (Morbihan disease).
 - Lichen planus actinicus: occasionally facial erythema.
 - Erythroprosalgia: Flushing erythema with pain.
- Infectious dermatoses
 - Erysipelas: Well defined erythematous swelling without epidermal involvement.
 - Acrodermatitis chronica atrophicans: Occasionally ill-defined livid coloured patches on the face.
 - Mycobacterial infections (lupus vulgaris, leprosy).
 - Lupus vulgaris (commonest form of skin tuberculosis): One or a few well demarcated reddish brown patches containing apple jelly deep seated nodules around the nose and/or on the cheeks, superficial ulceration or verrucous thickening of the skin
 - Lepromatous leprosy: Multiple erythematous nodules commonly affecting the face (extensive involvement: leonine facies), ears.
 - Measles: Patchy erythema involving the face and the mucous membranes.

- Fifth disease: Patchy erythema involving the face, ears and the mucous membranes.
- Tinea faciei (incognito): Occasionally pruritic facial erythema.

- Vascular malformations
 - Nevus flammeus: Well defined red patch of peculiar configuration, which blanches on pressure.
 - Cavernous hemangioma.

- Rare dermatoses
 - Keratosis pilaris atrophicans (ulerythema ophryogenes): Facial erythema (eyebrows, cheeks), follicular hyperkeratosis, lateral eyebrow alopecia.
 - Ichthyoses (bullous and non-bullous ichthyosiform erythrodermas and ichthyosis linearis circumflexa, incl. Netherton's syndrome): Facial erythema, dry skin, lamellar thick or thin scales.
 - KID syndrome (keratitis, ichthyosis and deafness).
 - Photogenodermatoses (xeroderma pigmentosum, Cockayne syndrome, Bloom's syndrome, erythropoietic protoporphyria, Hartnup disease): Early permanent facial erythema.
 - Tuberous sclerosis.

- Sign of internal diseases/disorders/conditions
 - Exercise, embarrassment, anger, stress, anxiety, guilt, pregnancy, peri-menopause, heatstroke, sunburn, x-ray, UVB, wind, cold/heat exposure, sexual act, fever: Temporary/transient erythema
 - Cutaneous T-cell lymphoma (erythroderma): Permanent erythema.
 - Hodgkin's disease, hyperthyroidism, chronic oxygen deprivation, polycythemia, leukemia, pheochromocytoma, carcinoid tumor, carcinoid syndrome,
 - systemic mastocytosis: Flushing erythema.
 - Deaminodesoxidase deficiency: flushing erythema
 - Autoimmune disorders
 - Systemic lupus erythematosus: Butterfly erythema or discrete maculopapular eruption with fine scaling on the butterfly area.
 - Dermatomyositis with or without myositis (dermatomyositis sine myositis): Heliotrope or dusky red facial erythema.

- Maxillary sinusitis, mitral valve stenosis: Livid erythema with plethoric facies.
- Sarcoidosis: Granulomatous centrofacial (nasal) infiltrate (lupus pernio).

- Drugs and toxins
 - Alcohol ingestion: Transient or permanent erythema (with unpleasant feeling after disulfiram administration). Flushing under concomitant intake with cephalosporins, griseofulvin, metronidazole, and sulfonyleureas.
 - Rubeosis diabetorum (alcohol and chlorpropamide): Occasionally periorbital erythema with spreading to the temple.
 - Vancomycin i.v.: Red man syndrome.
 - Ciclosporin: Occasionally flushing with anaphylactic symptoms.
 - Rifampicin overdose: Glowing red face in children.
 - Calcium channel blockers (nifedipine, verapamil, diltiazem), quinidine,
 - vasodilator drugs (nitroglycerine, amyl nitrite, butylnitrite, PDE5 antagonists), opiates, cholinergic drugs, contrastmedia: Flushing.
 - Steroid-induced rosacea: Rebound phenomenon of intense redness, scaling, crusting and sometimes pustulation following discontinuation of steroids after long-term topical use.
 - Steroid-induced Cushing: Permanent erythema after long-term administration of systemic corticosteroids.

- Food ingestion
 - Allergic or pseudoallergic reactions to food allergens (peanuts, egg, fish, walnuts), sulfites, monosodium glutamate, tartrazine, scombroidosis (and other seafood poisoning): Rapid onset (minutes) of flushing, bronchospasm and hypotension (sulfite reaction). Erythema, burning, pressure in the face, neck, and upper chest (monosodium glutamate in chinese food). Facial erythema and swelling (Quincke edema), bronchospasm and urticaria (aspirin intolerance, tartrazine sensitivity). Flushing, urticaria, pruritus, gastrointestinal complaints, or bronchospasm (scombroidosis, ciguatera or other seafood poisoning). Facial erythema, severe headache or hypertension [naturally occurring amines, such as tyramine (cheese, red wine) and phenylethylamine (chocolate)].

Localisation

Entire face or certain pattern.

Classification

- Temporary facial flushing.
- Persistent red face.

Laboratory & other workups

Depending on differential diagnoses: skin biopsy, allergy skin testing, photo-patch testing, RAST, serum zinc, blood leucocytes, blood neutrophils, erythrocyte sedimentation rate, TBC-PCR, herpes simplex virus-PCR, morbillivirus-PCR, human parvovirus B19-PCR, deaminooxidase and histamine. tryptase, alcohol and drugs concentration in serum, dermatophyte culture, Sézary cells in blood, lymphocyte sub-populations. ANA, ENA, complement, ACE, IL2 receptor.

Dermatopathology

Diagnosis-dependent.

Course

Transient, recurrent or permanent facial erythema.

Complications

Persistent facial erythema results in several psychiatric disorders.

Diagnosis

Dependent on the facial localisation and classification of erythema, additional symptoms, case history and results of skin biopsy and clinical and laboratory test.

Prevention & Therapy

Facial flushing often represents a complaint for the patient. However, depending on the course and intensity it requires treatment by dermatologists.

Depending on the pathogenesis of the many different differential diagnoses a causative or symptomatic treatment is possible. Together with the specific treatment of the provoking disease and the avoidance of contact with responsible exogenous agents, the recent widespread use of cosmetics with permanent over the day colouring may be helpful. Avoidance of blood flow and vessel width provoking agents, hyperthermia and other physical and chemical exogenous and endogenous factors a quite successful

prevention is achievable.

Facial erythema can further be symptomatically improved by brimonidine tartrate, an alpha 2-adrenergic receptor antagonist administered topically in a 0.33% gel. The compound is registered for rosacea.

Further, cosmetics based on a green extract of tomatoes reduce the visibility of erythema.

Special

None.

References

- [Clio Dessinioti & Christina Antoniou \(2017\) The “red face”: Not always rosacea. Clinics in Dermatology 35, 201–206](#)

8.2 Erythrodermas

Grading & Level of Importance: B
G. Burg, Zürich



ICD-11

EB10; EH40.2; EH64; EC20.03; EC20.0Y; EC20.02

Synonyms

Red man syndrome. Symptoms. Various diagnoses.

Definition

Inflammatory and scaly or exfoliative skin condition with redness and scaling of >90% of the skin, which either is primarily involved or spreads secondarily from a non-erythrodermic dermatosis.

Epidemiology

See specific diagnoses. See also chapter Red Face.

Aetiology & Pathogenesis

Depends on underlying diagnosis (see classification).

Signs & Symptoms

Almost complete (>90%) redness and different degree of scaling of the skin, with or without itch. Sparing of the skin in the axilla and abdominal folds or on the trunk (nappes claires). Swelling of lymph nodes as a consequence of pruritus scratching, erosions and superinfections. Due to loss of albumin and electrolytes via the exfoliative scaling edema develops. Sometimes temperature dysregulation and/or fever. Cachexia in some cases.

Localisation

Total skin, according to definition.

Classification

Primary erythrodermas

- Sézary syndrome
- Erythrodermic mycosis fungoides
- Staphylococcal scalded skin syndrome (SSSS)
- Erythroderma due to secondary loss of function of the skin (deficiency of vitamins, electrolytes; malabsorption due to alcohol excess with exsiccation)
- Senile-(melano-) erythroderma (with cachexia)
- Congenital ichthyosiform erythroderma
- Severe generalised sunburn
- Ofuji Disease

Secondary erythrodermas

- Psoriatic erythroderma
- Pityriasis rubra pilaris
- Atopic eczema

- Drug reaction
- Food reaction
- Paraneoplastic
- Generalised cutaneous mastocytosis and mast cell activation syndrome
- Generalised urticaria

Laboratory & other workups

Depending on diagnosis (mostly full blood count, electrolytes, liver enzymes, lymphocyte sub-populations, histamine, tryptase, IgE).

Dermatopathology

Depending on diagnosis.

Course

Can be acute, sub-acute and chronic.

Complications

Loss of fluid (exsiccation), of proteins and electrolytes (scaling), cardiac insufficiency; thermal loss.

Diagnosis

Redness with and without scaling of the total integument. Specific diagnosis of the underlying disorder is based on the dynamic and follow up of the dermatosis and the histologic features.

Differential Diagnosis

See classification.

Prevention & Therapy

Depending on diagnosis. Because of emergency situations, there is often a necessity of an acute intervention.

References

- [Rothe, M. J., Bialy, T. L., & Grant-Kels, J. M. \(2000\). Erythroderma. *Dermatol Clin*, 18\(3\), 405-415.](#)
- [Inamadar, A. C., & Rangunatha, S. \(2019\). The rash that becomes an erythroderma. *Clin Dermatol*, 37\(2\), 88-98.](#)
- [Thestrup-Pedersen, K., S. L. Halkier, H. Sogaard and H. Zachariae \(1988\). "The red man syndrome. Exfoliative dermatitis of unknown etiology: a description and follow-up of 38 patients." *J Am Acad Dermatol* 18\(6\): 1307-1312.](#)
- [Tso, S., F. Satchwell, H. Moiz, T. Hari, S. Dhariwal, R. Barlow, E. Forbat, H. Randeve, Y. T. Tan, A. Ilchyshyn, M. M. Kwok, T. M. Barber, C. Thind and A. C. Y. Tso \(2021\). "Erythroderma \(exfoliative dermatitis\). Part 1: underlying causes, clinical presentation and pathogenesis." *Clin Exp Dermatol* 46\(6\): 1001-1010.](#)
- [Tso, S., H. Moiz, F. Satchwell, T. Hari, S. Dhariwal, R. Barlow, E. Forbat, I. C. Blee, Y. T. Tan, C. Thind, A. Ilchyshyn, H. Randeve, M. M. Kwok, A. C. Y. Tso and T. M. Barber \(2021\). "Erythroderma \(exfoliative dermatitis\). Part 2: energy homeostasis and dietetic management strategies." *Clin Exp Dermatol* 46\(6\): 1011-1015.](#)
- [Cuperus, E., A. Bygum, L. Boeckmann, C. Bodemer, M. C. Bolling, M. Caproni, A. Diociaiuti, S. Emmert, J. Fischer, A. Gostynski, S. Guez, M. E. van Gijn, K. Hannulla-Jouppi, C. Has, A. Hernandez-Martin, A. E. Martinez, J. Mazereeuw-Hautier, M. Medvez, I. Neri, V. Sigurdsson, K. Suessmuth, H. Traupe, V. Oji and S. Pasmans \(2022\). "Proposal for a 6-step approach for differential diagnosis of neonatal erythroderma." *J Eur Acad Dermatol Venereol* 36\(7\): 973-986.](#)
- [Lee, H. \(2023\). "Mycosis fungoides and Sezary syndrome." *Blood Res* 58\(S1\): 66-82.](#)

8.3 Dry Skin

Grading & Level of Importance: B

A. Giménez-Arnau, Barcelona; H. Gollnick, Magdeburg; RM. Pujol, Barcelona



ICD-11

ED 54 (ICD-10: L85.3)

Synonyms

Xeroderma, xerodermia, asteatosis cutis, xerosis cutis, exsiccosis, sebstasis.

Definition

Skin presenting a decreased quantity and/ or quality of lipids and/or hydrophilic substances (natural moisturizing factor) with increase of water loss, clinically manifested as a scaly, rough, cracked, and fissured skin surface often accompanied by pruritus. An ichthyosis like pattern may develop.

Dry skin may be either a diagnosis or a clinical symptom present in several cutaneous and non-cutaneous disorders (disease-related dry skin). One differentiates between generalized and localized dry skin.

Epidemiology

Dry skin is one of the most common dermatological diagnoses and a symptom present in many dermatological and non-dermatological diseases (prevalence ranging from 35% to 85%). A study in a population of 48,600 employees the prevalence was 29% with a range from the 2nd life decade with 17% to the 7th life decade with 39%. The majority of people worldwide will experience dry skin at some stage in their lives.

There is no gender predilection. The prevalence increases with increasing age. Dry skin is one of the most prevalent skin conditions in the aged population worldwide, affecting over 50% of individuals aged ≥ 65 years.

Frequent symptom in dermatoses characterized by dysfunction of the skin barrier (atopic dermatitis, psoriasis, ichthyoses). Commonly seen in individuals with underlying diseases (i.e., diabetes mellitus, renal failure, hypothyroidism, paraneoplastic, etc.) or taking associated medications reducing the lipid precursors or acting in the lipid composition of the skin directly.

Aetiology & Pathogenesis

The onset of dry skin is thought to be mediated by genetics, environmental factors, ageing and other factors such as ethnicity. A so-called physiologic type of dry skin is to be seen in childhood with age related reduced function of sebaceous glands lipids and in the very elderly with atrophy of the skin (epidermis, dermis) and loss of function of sebaceous glands.

There are two main elements important for the maintenance of the epidermal stratum corneum humidity: intercellular lipids, which form the main barrier against diffusion of water across the stratum corneum, and a so-called natural moisturizing factor (NMF / formed in the Malpighian layer), which has a key role in the absorption of water in the stratum corneum. Filaggrin is a key player and genetically disturbed content and function leads to impaired skin barrier in particular in atopic dermatitis. The enzymatic proteolytic degradation of filaggrin leads to the natural moisturizing factor (NMF). An intercellular lipidic cement like composition of substances is produced by the keratinocytes and stored in keratinosomes of the corneal layer. These are ceramides, essential fatty acids and cholesterol. A water content of 10-15% is necessary to stay intact and supple.

Internal causes

In particular, during ageing of the skin and for example in atopic dermatitis dry skin the ceramide levels in the upper epidermis are reduced and ceramidase activity is increased, which lead to reduced functionality of the lamellar structure. A reduction of intercellular lipids in the stratum corneum and an altered ratio of fatty acids esterified to ceramide, along with persistence of corneodesmosomes, premature expression of involucrin and formation of the cornified envelope results in corneocyte retention and marked impairment of barrier recovery. However, in aged skin the synthesis of ceramides 1-6 in contrast to AD is reduced. In AD skin the sebaceous lipids are not reduced in dry skin areas, but in aged skin. Structural changes go in parallel with a significant increase in pH values and stratum corneum hydration decreases with increasing dryness and skin roughness. Disturbed function of profilaggrin/filaggrin leads to reduced function of the NMF. Reduced activity of the sebaceous glands after menopause and andropause is an additional factor of loss of function for lipidization of the skin surface. Epidermal atrophy (senile) or hyperplasia (ichthyosis types, psoriasis, lichenification in chronic eczema), both coexist with dry skin.

Multifactorial aetiology:

External Causes

Intense skin cleansing/overwashing: Taking frequent, long, hot showers, hot bathing, using harsh, alkaline soaps, cultural washings.

Environmental factors: cold weather, low humidity, dry indoor heat, intense exposure to sunlight. Irritant garns in clothes.

Occupational factors: "Wet work", contact with irritant agents (i.e., chemicals used in hair dressing or housekeeping, soaps, surfactants).

Endogenous Causes

- Ageing.
- menopause.
- andropause

Skin diseases

Inflammatory skin disorders: atopic dermatitis, allergic contact dermatitis, irritant contact dermatitis, dyshidrotic eczema, asteatotic eczema ("eczema craquelé"), nummular eczema, seborrheic dermatitis, psoriasis, etc.

Infectious skin disorders (in the chronic phase): scabies, bacterial, or fungal infections

Genodermatoses: Ichthyoses, xeroderma pigmentosum.

Neoplasms: Cutaneous T-cell lymphoma.

Internal/Systemic diseases

Endocrine or metabolic: diabetes mellitus, hypothyroidism, hyperthyroidism, primary biliary cholangitis, cholestasis, hyperparathyroidism, renal failure and hemodialysis.

Inflammatory: Crohn's disease, ulcerative colitis.

Infections: human immunodeficiency virus (HIV), hepatitis B or C virus.

Hormonal: pregnancy, menopause, hyperthyreosis.

Hematologic: myeloproliferative disorders, multiple myeloma, Hodgkin's and Non-Hodgkin's lymphoma, GVHD,

Paraneoplastic.

Neurologic: Autonomic neuropathy.

Psychiatric diseases

Obsessive-compulsive disorders: excess skinwashing.

Eating disorders: anorexia with nutrition deficiencies.

Addictions: alcohol or drug abuse, nicotine excess.

Dietary

Dehydration: excess perspiration, insufficient water intake.

Malnutrition: Marasmus, vitamin A or vitamin D deficiency, zinc, potassium or iron deficiency.

Medication-related

Drugs: Diuretics, beta-blockers, contraceptives, retinoids, long-term use of topical steroids, lipid-lowering agents (statins),

Radiation therapy, artificial tanning etc.

Signs & Symptoms

Dry skin is characterized by a scaly, rough, cracked, and fissured surface. Skin dullness with decreased elasticity, texture coarsening and wrinkling. Often associated with pruritus, that may lead to excoriations and haemorrhage.

Occasionally, erythema may be present. Rubbing and scratching of the skin can lead to eczematous changes with a reticulate, cracked, or crazy-paving appearance (“eczema craquelé”). Lichenification may occur.

Signs and symptoms of dry skin depend on age, health status, ambient humidity, and other environmental factors.

Localisation

Two types are differentiated: localized and generalized. Dry skin is more frequently present at the lower legs, dorsal forearms, sides of abdomen and hands and feet with low or missing activity of sebaceous glands, although any area of the body may be affected.

Classification

Dry skin can develop acutely or be a chronic condition of varying intensity (mild, moderate or severe dry skin).

Can be classified as:

1. Constitutional dry skin or xerosis cutis triggered by exogenous factors
2. Dermatoses that present with primary skin lesions such as atopic dermatitis, psoriasis, irritant contact dermatitis, or the various types of ichthyosis.
3. Dry skin associated with systemic diseases (e.g., diabetes, renal and biliary disorders, HIV)
4. Drug-induced dry skin

Laboratory & other workups

Assessment of possible underlying causes: Renal function tests, thyroid hormone levels, vitamin levels, etc. Measurement of transepidermal water loss (TEWL) and sebum secretion rate, corneometry, pH, skin roughness.

Dermatopathology

Skin biopsy can be performed in rare instances when needed to distinguish from conditions mimicking dry skin (ichthyosiform dermatoses), verifying reasons of atrophies or hyperplasia.

Course

Variable. Although dry skin is often experienced in the winter, in certain individuals may be a lifelong concern. Can be aggravated by environmental factors such as frequent washing, use of harsh detergents and exposure to low-humidity (e.g. air-conditioned) environments. Development into an asteatotic eczema/eczema craqule and/or irritative eczema.

Complications

Increased risk of skin infections (via breaches in the skin surface), skin breakdown from maceration (skin folds), and from pressure in weight-bearing and pressure-prone surfaces. Chronic pruritus and scratching vicious cycle.

Sensitization: Allergic contact dermatitis (due to compromised skin barrier function).

Diagnosis

Clinical diagnosis with a thorough history and physical examination.

A careful and detailed clinical history including age, duration and localization of symptoms, timing, potential triggers, history of atopy, exposure to external factors, comorbidities (renal, thyroid disease, diabetes) and drugs (statins, retinoids, diuretics).

Differential Diagnosis

Depending on the cause and course (see above).

Prevention & Therapy

Prevention: Avoidance of possible trigger factors, including aggressive skin washing and hot water harsh, soaps/detergents, extreme climate, rough/tight clothing. Controllable environmental causes of dry skin should be corrected. Comorbidities should be adequately treated. Excessive bathing or the use of hot baths or showers should be discouraged. In childhood/adulthood, frequency of bathing/showering to be reduced.

Therapy: Most cases can be managed conservatively with gentle cleansing and adequate moisturization with at least 4 % urea and/or lactic acid.

Use of mild cleansers: synthetic detergent cleansers or syndet cleansers. Avoid traditional alkaline soaps.

Skin moisturizers: Oil-based creams better than water-based lotions. Ointments are useful for preventing transepidermal water loss. May include humectants (glycerin, urea 10%, ammonium lactate, hyaluronic acid, gelatin), occlusives (lanolin, paraffin, petrolatum, cholesterol, stearyl alcohol) and emollients (petrolatum, dimethicone). Application immediately after bathing/shower.

Choice of ingredients is based on a patient's symptoms, such as scaling (e.g., urea), fissures/rhagades (e.g., urea or dexpanthenol), erythema (e.g., licochalcone A) and pruritus (e.g., polidocanol).

In cases with intense itch or associated dermatitis, oral antihistamines, topical corticosteroids or calcineurin inhibitors may be prescribed. In some cases, room humidifiers, especially during the winter months may be useful.

Prognosis

Dry skin is a benign symptom that can be resolved with avoidance of triggers and incorporating adequate skincare. However, be aware of paraneoplastic or HIV related dry skin. Some cases may persist or recur for years. When associated with pruritus, may lead to a considerable impairment in patients' quality of life.

Special

None.

References

- [Tonicic RJ, Kezic S, Hadzavdic SL, Marinovic B. Skin barrier and dry skin in the mature patient. Clin Dermatol 2018; 36: 109–115.](#)
- [Yosipovitch G, Misery L, Proksch E, Metz M, Ständer S, Schmelz M. Skin Barrier Damage and Itch: Review of Mechanisms, Topical Management and Future Directions. Acta Derm Venereol. 2019 ;99:1201- 1209.](#)

8.4 Itching

Grading & Level of Importance: B

G. Girolomoni, Verona; P. Gisondi, Verona; M. Maurelli, Verona



ICD-11

ME65.1; EC90.6

Synonyms

Pruritus.

Definition

Unpleasant sensation of the skin leading to the desire to scratch.

Epidemiology

Prevalence: The most common symptom in dermatology. Chronic itch 12-20% of general population. In particular, about 60% of the elderly complain of chronic itch.

Aetiology & Pathogenesis

Purpose: to provoke scratching in order to remove a pruritogen, a response likely to have originated when most pruritogens were parasites. Dedicated neural pathway (pruritoceptors) similar but different compared to those dedicated to pain, including unmyelinated C fibers and small myelinated A δ fibers. Primary sensory neurons have cell bodies in the dorsal root ganglions and project primary afferents to the skin, and they send projections to the dorsal horn of the spinal cord, where they synapse with second- or third-order neurons, which come together to form part of the spinothalamic tract projecting through the thalamus to the somatosensory and the anterior cingulate cortex. Second- and third-order neurons in the spinal cord may have either excitatory or inhibitory functions. Itch mediators released by resident skin cells and inflammatory cells include histamine, IL-2, TNF- α , IL-4, IL-13, IL-31, thymic stromal lymphoprotein, proteases, neuropeptides (substance P) and opioid peptides.

Signs & Symptoms

Desire to scratch. Quality of itch: burning, painful, stinging, prickling.

Localisation

Localized pruritus: usually caused by itchy dermatoses, associated with inflamed skin, such as in atopic dermatitis, psoriasis, lichen simplex chronicus, tinea, insect bite reactions.

Generalized pruritus: can be caused by itchy dermatosis even if the inflamed skin does not show generalized spread, or can be caused by extracutaneous disorders.

Classification

Acute or chronic: Itching lasting 6 or more weeks. Localized or generalized.

- Pruritus with underlying dermatosis (specific skin lesions): atopic dermatitis, eczema, psoriasis, urticaria, scabies, pemphigoid, drug eruptions, cutaneous T-cell lymphoma, insect bite reactions.
- Pruritus associated with excoriated nodules and/or lichenification: prurigo nodularis, lichen simplex chronicus.
- Pruritus in patients with normal skin or minimal scratched lesions (pruritus of unknown origin):
 - Neurologic diseases: multiple sclerosis, brain tumors, small fiber neuropathies, post-herpetic neuralgia, brachioradial pruritus, nostalgia paresthetica.
 - Hematological disorders: polycythemia vera, myeloproliferative disease, lymphoma.
 - Endocrine diseases: hyper- and hypothyroidism, hyperparathyroidism, diabetes mellitus.
 - Infectious diseases: viral hepatitis, parasitoses including helminthosis, HIV/AIDS.
 - Uremic. Cholestatic.
 - Metabolic diseases: chronic kidney disease, iron deficiency/overload, hepatobiliary diseases and/or cholestasis.
 - Neoplastic.
 - Drug induced.
 - Psychiatric diseases: depression, anxiety, delusion disorders, eating disorders.
 - Mixed.

Laboratory & other workups

Recommended in patients with pruritus of unknown origin: full blood count, ferritin, urea, electrolytes, liver function test, erythrocyte sedimentation rate (ESR), PCR; chest X-ray. Optional screening test: blood loss investigations, serum bile acids, LDH, beta-2 microglobulin, thyroid function test, fasting glucose HbA1c, calcium, potassium, PTH, vitamin D, HIV, HCV, HAV, HBV, malaria, strongyloidiasis, schistosomiasis; CT scan, magnetic resonance, skin biopsy.

Dermatopathology

It depends on the type of skin lesions present.

Course

Itch negatively impacts on the quality of life. Severe itch may be devastating.

Complications

Secondary skin lesions caused by scratching. Usually, secondary skin lesions encompass excoriations, ulcerations, crusts, papules, nodules, lichenification, atrophy and scars, hyper- and hypopigmentation.

Diagnosis

Accurate anamnesis, physical examination, assessment of itch severity, screening lab and instrumental tests.

Differential Diagnosis

Diagnosis of primary skin disorders. Understanding the etiology of pruritus not associated with specific skin lesions.

Prevention & Therapy

Symptomatic therapy and treatment of underlying disease (were present). Topical treatments: local anaesthetics, topical corticosteroids, topical calcineurin inhibitors. Systemic treatments: antihistamines, short term corticosteroids, ciclosporin. Opioid κ receptor agonists (nalfurafine, difelikefalin) and μ receptor antagonists (nalmefene, naltrexone), antiepileptics (gabapentin, pregabalin). Antidepressants (paroxetine, fluvoxamine, sertraline, amitriptyline, mirtazapine), neurokinin antagonists (aprepitant, serlopitant), anti-IL-4/IL-13 antibodies (dupilumab), anti-IL31R (nemolizumab). Ultraviolet phototherapy.

Special

None.

References

- [Yosipovitch G, Rosen JD, Hashimoto T. \(2018\) Itch: From mechanism to \(novel\) therapeutic approaches. J Allergy Clin Immunol. Nov;142\(5\):1375-1390. doi: 10.1016/j.jaci.2018.09.005. PMID: 30409247.](#)
- [Garcovich S, Maurelli M, Gisondi P, Peris K, Yosipovitch G, Girolomoni G. \(2021\) Pruritus as a distinctive feature of type 2 inflammation. Vaccines \(Basel\) Mar 23;9\(3\):303. doi: 10.3390/vaccines9030303. PMID: 33807098; PMCID: PMC8005108.](#)
- [Yosipovitch G, Misery L, Proksch E, Metz M, Ständer S, Schmelz M. \(2019\). Skin barrier damage and itch: review of mechanisms, topical management and future directions. Acta Derm Venereol. Dec 1;99\(13\):1201-1209. doi: 10.2340/00015555-3296. PMID: 31454051.](#)
- [Yosipovitch G, Berger T, Fassett MS. \(2020\) Neuroimmune interactions in chronic itch of atopic dermatitis. J Eur Acad Dermatol Venereol. Feb;34\(2\):239-250. doi: 10.1111/jdv.15973. Epub 2019 Nov 12. PMID: 31566796; PMCID: PMC7027518.](#)

8.5 Urticarial syndromes

Grading & Level of Importance: B
AM Giménez- Arnau, Barcelona



ICD-11

EB03

Synonyms

Urticarial eruptions, urticarial rash.

Definition

There are many dermatoses with an urticarial appearance. In contrast to “urticaria sensu strictu”, “urticarial syndromes” are not specific diagnoses, but they resemble skin lesions that look like weals or hives. “Urticarial” refers to skin lesions that look like weals, but are not.

Aetiology & Pathogenesis

There are many dermatoses with an urticarial appearance that correspond to different pathogenic mechanisms such as type 1 or 3 immune reactions or are non–allergic (pharmacologic, toxic, chemical)

most of them with an unknown aetiology.

Signs & Symptoms

Urticarial lesions last days, itch is variable, sometimes leave a mark with persisting erythema, blood extravasation, hematoma-like or small pigmentation. Sometimes they show scaling. Rarely angioedema is associated; fever is sometimes present and is possible that systemic disturbances are key diagnostic features.

Localisation

Urticarial lesions can develop at any body location.

Classification

Dermatoses that present with “urticaria-like” lesions include: insect bites (papular urticaria), acute dermatitis (early stage of contact dermatitis, atopic dermatitis), urticarial vasculitis (normo- and hypocomplementemic), urticaria pigmentosa (Darier’s sign in cutaneous mastocytosis), systemic infections (prodromal rash of viral infections), immunobullous diseases (e.g. premonitory pemphigoid, dermatitis herpetiformis), auto-inflammatory syndromes (e.g. CAPS; Schnitzler syndrome), neutrophilic dermatosis (e.g. Sweet syndrome), and autoimmune disorders (e.g. progesterone hypersensitivity).

Laboratory & other workups

There are no specific general laboratory requirements. Some of the diseases need specific diagnostic tests and genetic approach.

Dermatopathology

A skin biopsy may be helpful in order to exclude other causative underlying dermatoses. There may be a normal or abnormal looking dermis with interstitial and/or peri-vascular edema, sometimes lymphocytic infiltrates or perivascular granulocytes with nuclear dust in the case of leucocytoclastic vasculitis. Depending on pathogenesis, eosinophils may be present.

Course

Depends on the underlying disorder: acute, subacute or chronic persistent or relapsing.

Complications

Depends on the underlying disorder.

Diagnosis

The clinico-pathological correlation of lesions is nearly always essential for the diagnosis of urticarial syndromes. Urticaria is a clinical diagnosis made on the history and examination. For certain types, special diagnostic tools are necessary. In case of autoinflammatory syndromes, further investigations are required: C reactive protein, NLRP-3 genotyping in cryopyrin syndrome, high ferritin in adult Still's disease, electrophoresis (immunoglobulin and paraproteins e.g IgM in Schnitzler Syndrome).

Differential Diagnosis

The main differential diagnosis is with Urticaria itself. Urticaria is an illness characterized by itchy wheals with or without angioedema, that can be acute or chronic (spontaneous or inducible). The differences between "Urticaria" and "urticarial" are as follows. In urticaria, weals last for hours, itch is usually intense, are not scaly and never leave residual pigmentation. Urticaria is commonly associated with angioedema, fever is not present and rarely may show associated systemic disturbances e.g. arthralgias.

Different urticarial rashes have their own differential diagnosis.

Papular urticaria, also known as lichen urticatus, is the result of hypersensitivity to bites from certain insects. Itchy edematous papules and papulovesicles are usually excoriated. Histopathology: Epidermal intercellular and intracellular edema (spongiosis). Chronic dermal perivascular inflammatory infiltrate often extending to the deep dermis containing a significant admixture of eosinophils. Further investigations are not necessary.

Acute dermatitis. Macules, papules and vesicles. If macules coalesce, they form patches of erythema that may be edematous. Papules may coalesce to form plaques. Histopathology: Spongiotic microvesicles or macrovesicles with oozing in acute dermatitis. Showing acanthosis with parakeratosis in chronic dermatitis and a combination of both (subacute dermatitis). Further investigations: Patch testing, IgE sensitization.

Urticarial vasculitis. Recurrent episodes of urticarial lesions often associated with arthralgia and abdominal pain among other systemic symptoms. The individual lesions tend to persist 1 to 3 days and may result in purpura and hyperpigmentation. Histopathology: The dermis shows a leucocytoclastic vasculitis characterized by fibrinoid deposits in the blood vessel walls, and neutrophilic infiltrate with nuclear fragmentation (leukocytoclasia), and slight to moderate extravasation of erythrocytes.

Five types of cutaneous lesions in cutaneous mastocytosis (urticaria pigmentosa) are seen: maculo/papules, nodules/plaques, solitary large cutaneous nodule, diffuse erythrodermic type, and telangiectasia macularis eruptive perstans. Histopathology: Infiltrate composed chiefly of mast cells, which are characterized by the presence of metachromatic granules in their cytoplasm. These granules are visible after staining with Giemsa stain or toluidine blue. By immunohistochemistry mast cells are cKit positive. Further investigations: Blood tryptase, bone marrow biopsy, KIT mutations.

Urticarial rashes, often not itchy can be prodromic or developed during different viral infections. Histology: may be non-specific. If blister formation, degenerative changes in epidermal cells including ballooning and reticular degeneration can be observed. Further investigations: Viral serology.

Occasionally some autoimmune bullous diseases (bullous pemphigoid, dermatitis herpetiformis or Linear IgA bullous dermatosis) are preceded by urticarial reactions. Histopathology: Subepidermal bullae. Direct immunofluorescence; Different patterns of IgG, IgM and IgA binding that help to the histopathologic diagnosis. Further investigations: Indirect immunofluorescence ELISA.

Autoinflammatory syndromes show urticarial rashes and even cold urticaria with systemic involvement, fever and general discomfort. Broad spectrum of familial diseases including e.g Muckle Well syndrome and cryopyrin-associated periodic syndromes (CAPS) and others should be considered.

Neutrophilic dermatosis are included as autoinflammatory conditions often associated with systemic diseases (e.g. Sweet syndrome, acute febrile neutrophilic dermatosis). Histopathology: The histologic finding varies according with the different entities and with different diagnostic relevance. Some show upper epidermal dyskeratosis, increase dermal mucin, and a superficial lymphoid inflammatory infiltrate with occasional neutrophils or eosinophils. Further investigations: C reactive protein, NLRP-3 genotyping in cryopyrin syndrome, high ferritin in adult Still disease, electrophoresis (immunoglobulin and paraproteins) e.g. IgM in Schnitzler Syndrome.

Prevention & Therapy

There is no general approach to such diseases with a common treatment.

Special

The correct diagnosis of urticarial dermatoses is important for an appropriate management with the correct avoidance of triggers and adequate drug administration. The inheritance, prognosis and patient support groups are disease-specific and different from true urticaria.

References

- [Peroni A, Colato C, Schena D, Girolomoni G, et al. Urticarial lesions: if not urticaria, what else? The differential diagnosis of urticaria: part I. Cutaneous diseases. J Am Acad Dermatol. 2010; 62: 541–56.](#)
- [Davis MDP, van der Hilst JCH. Mimickers of Urticaria: Urticarial Vasculitis and Autoinflammatory Diseases. J Allergy Clin Immunol Pract. 2018; 6:1162-1170.](#)

8.6 Pregnancy Dermatoses

Grading & Level of Importance: B
RM. Pujol, Barcelona



ICD-11

JA65.1

Synonyms

Disorders of Pregnancy. There are several synonyms depending on pregnancy dermatoses.

Polymorphic eruption of pregnancy (PEP): Pruritic urticarial papules and plaques of pregnancy, pruritic eruption of pregnancy, toxemic rash of pregnancy.

Pemphigoid gestationis (PG): Gestational pemphigoid, herpes gestationis.

Atopic eruption of pregnancy (AEP): Prurigo gestationis, papular dermatitis of pregnancy, pruritic folliculitis of pregnancy.

Intrahepatic cholestasis of pregnancy (ICP): Pruritus gravidarum, icterus gravidarum.

Pustular psoriasis of pregnancy: Impetigo herpetiformis.

Definition

Dermatoses that are specific to pregnancy, resulting from an interaction of multiple factors in the body during pregnancy. These include various types (see classification).

Epidemiology

Dermatoses of pregnancy are a group of disorders seen throughout the world. They are usually seen more commonly late in pregnancy and in those twin or multiple pregnancies.

Polymorphic eruption of pregnancy (PEP): Represents the most common specific dermatosis of pregnancy. Incidence: 1:160 pregnancies. More frequent in multiple gestation pregnancies (twins or triplets).

Pemphigoid gestationis (PG): 1 in 40-50,000 pregnancies. Worldwide distribution. Association with the haplotypes HLA-DR3 (60-80%) and HLADR4 (50%).

Atopic eruption of pregnancy (AEP) is always causally linked with a personal and/or family atopic background.

Intrahepatic cholestasis of pregnancy (ICP): Geographic pattern: South America (10-30%), Scandinavian countries (2.4%), USA, Europe: 0.1-1.5%. Positive family history > 50% of cases.

Pustular psoriasis of pregnancy: Very Rare. No more than 200 reported cases.

Aetiology & Pathogenesis

Polymorphic eruption of pregnancy (PEP): Pathogenesis unknown, but there are multiple theories: hormonal factors, autoimmune factors, fetal cell microchimerism and atopic background.

Pemphigus gestationis: Autoimmune response against a placental matrix antigen. Possible cross reactivity between placental tissues and skin. Autoantibodies against BP180 (bullous pemphigoid) antigen. Circulating complement-fixing IgG antibodies of the subclass IgG1 ('pemphigoid gestationis factor'). Immune complex deposition, complement activation, chemo-attraction of eosinophils and blister formation. PG is associated with other autoimmune disorders (Graves' disease, pernicious anemia and Hashimoto thyroiditis). Possible occurrence of the disease when using oral contraceptives or during the premenstrual period.

Atopic eruption of pregnancy: May occur in atopic subjects or others without atopy. Etiology: unknown. Possible role of dominant Th2 cytokine production during pregnancy.

Intrahepatic cholestasis of pregnancy: Not a primary dermatosis but a pregnancy-related liver disorder with secondary cutaneous lesions in particular induced by scratching. Pathogenesis: Multifactorial - hormonal (estrogen and progesterone metabolites), genetic and exogenous (environmental).

Pustular psoriasis of pregnancy: Possible peculiar form of ordinary pustular psoriasis.

Signs & Symptoms

Depends on disorder. Skin eruptions usually appear in the third trimester of pregnancy and tend to resolve after delivery.

The severity of symptoms and signs are variable. The lesions may manifest as papules/plaques (PEP, AEP), blisters (PG, PEP), urticarial lesions (PEP, PG), pustules (PPP, PEP), lichenified plaques (AEP, ICP) or eczematous lesions. Sometimes scars may be present (ICP).

Polymorphic eruption of pregnancy (PEP): Benign, self-limited, pruritic, papulo-urticarial inflammatory disorder that usually affects the primigravida in the last trimester of pregnancy or in the immediate post-partum period. Clinically polymorphous intensely itchy erythematous papules and plaques develop within and/or adjacent to striae gravidarum, occasionally macules, papulo-vesicles (eczematous), urticarial, targetoid lesions similar to erythema multiforme; annular or polycyclic wheals may also be present; and rarely, small bullae excoriations and crusts. During the evolution of the disease, other body sites may be involved such as buttocks, proximal thighs, or back.

Pemphigoid gestationis (PG): Autoimmune vesiculobullous disorder. Intensely pruritic. Late pregnancy (second or third trimester) or puerperium. Clinically, erythematous urticarial papules and plaques mostly on the abdomen (peri-umbilical), also limbs, palms, or soles. The lesions progress to tense blisters and bullae. Distribution: Abdomen, trunk and extremities. Face, palms, soles, and mucous membranes usually spared.

Atopic eruption of pregnancy (AEP): Generalized pruritic skin condition. Exacerbation or the first occurrence of eczematous and/or papular skin changes during pregnancy in patients with an atopic diathesis. Most common presentation: Eczematous dermatitis in the classic atopic sites: antecubital and popliteal fossae, face, eyelids, and neck. Non-specific pruritic papules on the neck, trunk, and extremities.

Xerosis, excoriations, and prurigo lesions. Prurigo of pregnancy: Excoriated papules and nodules on the limbs and/or trunk and typical onset in mid-pregnancy. Pruritic folliculitis of pregnancy: Follicular/pustular and papular lesions on the trunk or generalized.

Intrahepatic cholestasis of pregnancy (ICP): Widespread pruritus. No primary skin lesions, Onset: Last trimester of pregnancy. Secondary skin changes due to scratching (excoriations, scratch marks and/or prurigo nodules). Jaundice (10%) due to concomitant extra-hepatic cholestasis.

Pustular psoriasis of pregnancy (PPP): Second half of pregnancy with widespread, tiny, superficial, pustules arranged in herpetiform distribution. Extension with a centrifugal pattern. The eruption is usually associated pain, fever, chills, vomiting, nausea, and malaise.

Localisation

Polymorphic eruption of pregnancy (PEP): striae gravidarum, abdomen, trunk. Pemphigoid gestationis: abdomen (peri-umbilical), trunk, extremities.

Atopic eruption of pregnancy: antecubital popliteal folds.

Intrahepatic cholestasis of pregnancy: shins and lower arms, buttocks or abdomen. Pustular psoriasis of pregnancy: trunk, extremities.

Classification

- Polymorphic eruption of pregnancy (PEP)
- Pemphigoid gestationis (PG)
- Atopic eruption of pregnancy (AEP): encompasses atopic eczema in pregnancy, prurigo of pregnancy, as well as pruritic folliculitis of pregnancy
- Intra-hepatic cholestasis of pregnancy (ICP)
- Pustular psoriasis of pregnancy (PPP)

Laboratory & other workups

Polymorphic eruption of pregnancy (PEP): Routine laboratory: Normal

Pemphigoid gestationis: Eosinophilia. HG factor. Immune serology (BP180 antigen) Atopic eruption of pregnancy: Elevated serum IgE levels.

Intrahepatic cholestasis of pregnancy: Elevation of the total serum bile acid levels.

Mild abnormalities of liver function tests: (elevated ALT, GGT, hyperbilirubinemia).

Pustular psoriasis of pregnancy: Leukocytosis with neutrophilia, elevated erythrocyte sedimentation rate, hypoalbuminemia, and iron deficiency anemia. Pustules are sterile.

Dermatopathology

Polymorphic eruption of pregnancy (PEP): Non-specific histologic features: Spongiosis papillary dermal

edema; superficial, mid-dermal perivascular lymphohistiocytic infiltrate with occasional eosinophils, DIF (direct immunofluorescence) and IIF (indirect immunofluorescence) are negative.

Pemphigoid gestations: Pre-bullous stage: Perivascular inflammatory infiltrate, composed of lymphocytes, histiocytes, and eosinophils. Spongiosis and focal epidermal necrosis. Bullous stage: Subepidermal blister, Eosinophils are seen along the BMZ (basal membrane zone) and in the bullous spaces.

Direct immunofluorescence (IF): Linear deposition of C3 and occasionally IgG along the BMZ. Indirect immunofluorescence/ELISA: Circulating IgG antibodies anti BP180.

Intra-hepatic cholestasis of pregnancy: Skin biopsy: Non-specific changes. DIF and IIF: Negative. Atopic eruption of pregnancy: Histopathology is non-specific (spongiosis) and direct immunofluorescence: negative.

Pustular psoriasis of pregnancy: Subcorneal spongiform pustules similar to pustular psoriasis.

Course

Polymorphic eruption of pregnancy (PEP): The lesions usually resolve within 4-6 weeks.

Pemphigoid gestationis: Self-limiting. Spontaneous remission in weeks to months after delivery. Alternating exacerbations and remissions during pregnancy. Improvement in the third trimester. Flare-up at the time of delivery. Tends to recur in all subsequent pregnancies, usually with an earlier onset and increased severity. Possible exacerbations or recurrences during the premenstrual period or oral contraceptives use.

Resolution after delivery and possible recurrences with subsequent pregnancies in atopic eruption of pregnancy, intrahepatic cholestasis of pregnancy and pustular psoriasis of pregnancy.

Complications

Polymorphic eruption of pregnancy (PEP) and atopic eruption of pregnancy: The fetal and maternal prognoses are excellent in almost all cases.

Pemphigoid gestationis, intrahepatic cholestasis of pregnancy [ICP], and impetigo herpetiformis) are associated with considerable adverse fetal outcomes such as prematurity, fetal distress, or even stillbirth. Intra-hepatic cholestasis of pregnancy: Increased risk of intra- and post-partum hemorrhage.

Pustular psoriasis of pregnancy: Hypocalcemia, lymphadenopathy, seizures, and malaise, severe dehydration.

Diagnosis

Clinical features, onset of eruption, histopathological data and direct and indirect immunofluorescence studies. Immunopathologic tests (DIF/IIF) play an important role in differentiating pemphigoid gestationis from other bullous disorders.

Differential Diagnosis

In many instances should be established with other specific dermatoses of pregnancy and/or different dermatoses appearing during pregnancy

Polymorphic eruption of pregnancy (PEP): Pemphigoid gestationis (pre-bullous) or different papular/plaque/urticarial dermatoses appearing during pregnancy: Drug eruptions, allergic contact dermatitis, scabies, erythema multiforme.

Pemphigoid gestationis: Pre-blistering stage: PEP, Blistering stage: Other autoimmune bullous diseases: bullous pemphigoid, dermatitis herpetiformis, linear IgA disease, bullous systemic lupus erythematosus, erythema multiforme, bullous drug eruptions, or contact dermatitis coincident with pregnancy.

Atopic eruption of pregnancy: Pruritic dermatoses unrelated to and coinciding with gestation (e.g. atopic dermatitis, scabies, drug eruptions, and arthropod bites).

Intra-hepatic cholestasis of pregnancy: Different dermatologic and/or internal conditions that cause pruritus in the absence of primary skin lesions.

Pustular psoriasis of pregnancy: Autoimmune bullous dermatoses that coincide with pregnancy, acute generalized exanthematous pustulosis.

Prevention & Therapy

- Polymorphic eruption of pregnancy (PEP): Symptomatic treatment: topical corticosteroids, topical antipruritic or emollient treatments; Systemic antihistamines (loratadine or cetirizine).
- Pemphigoid gestationis: Dependent on the stage and severity of the disease. Potent topical corticosteroids. Systemic corticosteroids (prednisone, 0.5–2 mg/kg/day), to control blister

formation, tapered and maintained at the lowest effective dose. Immunosuppressive treatments only used after delivery.

- Atopic eruption of pregnancy: Moderately potent topical corticosteroids and oral antihistamines. Emollients or anti-pruritic additives such as menthol or polidocanol.
- Intrahepatic cholestasis of pregnancy: Antipruritic treatments: ursodeoxycholic acid, cholestyramine, antihistamines (non-sedative), anion exchange resins.
- Pustular psoriasis of pregnancy: Systemic corticosteroids, ciclosporin. After pregnancy, other agents used in psoriasis could be prescribed: PUVA, or other systemic agents. If secondary skin infection, antibacterials can be used.

Special

Fetal prognosis:

Pemphigoid gestationis: Increased risk of prematurity and developing small-for-gestational-age babies.

Intrahepatic cholestasis of pregnancy: Risk of premature birth (19-60%), fetal distress (22-33%) and stillbirth (1-2%).

Pustular psoriasis of pregnancy: Increased fetal risk such as stillbirth, neonatal death, and fetal abnormalities.

References

- [Bechtel MA, Plotner A. Dermatoses of pregnancy. Clin Obstet Gynecol. 2015; 58:104-11.](#)
- [Lehrhoff S, Pomeranz MK. Specific dermatoses of pregnancy and their treatment. Dermatol Ther. 2013; 26: 274-84.](#)
- [Xie F, Shruti Agrawal Sh, Johnson EF et al \(2023\) Updates on the dermatopathology of pregnancy-associated skin conditions. Human Pathology 140, 73-195 Barnawi AM, Barnawi GM, Alamri AM. Women's Health: Most Common Physiologic and Pathologic Cutaneous Manifestations During Pregnancy. Cureus. 2021 Jul 21;13\(7\): e16539. doi: 10.7759/cureus.16539. PMID: 34430147; PMCID: PMC8378782.](#)

8.7 Purpuric Rashes

Grading & Level of Importance: B
RM. Pujol, Barcelona



ICD-11

ME62.1

Synonyms

Purpura. Purpuric skin eruptions.

Definition

Cutaneous skin eruption with purpuric lesions.

Purpura is defined as visible hemorrhage (extravasated erythrocytes) into the skin or mucous membranes. Purpura is not a specific nosologic or diagnostic term, but includes a heterogeneous group of benign, purpuric skin eruptions characterized by red to purple macules, patches, and petechiae due to secondary capillary leakage. A broad spectrum of causes including blood clotting, thrombopenia, thrombocyte dysfunction, infections, reactive or autoimmune processes, etc. may give rise to purpuric rashes.

Epidemiology

Variable prevalence depending on the etiology.

Aetiology & Pathogenesis

Purpura is often a symptom indicative of an underlying cause of bleeding (see classification). Purpuric rashes may be primary (when hemorrhage is an integral part of lesion formation) or secondary (hemorrhage takes place in previously established lesions). Increased fragility and permeability of vessels in elderly people or due to treatment (glucocorticosteroids, anticoagulants, drugs, hematological diseases, etc.) may be promoting factors.

According to the etiology different purpuric rashes could be defined:

1. Purpuric rashes secondary to coagulation abnormalities (thrombocytopenic)
Genetic and acquired disorders: Impaired platelet production and function, genetic abnormalities in coagulation factors, excessive platelet destruction such as disseminated intravascular

coagulation, immune thrombocytopenia, etc.

2. Purpuric eruptions secondary to vascular damage (vasculitis) Clinically manifested as purpuric palpable lesions (palpable purpura):

- Leukocytoclastic vasculitis (small-vessels): Perivascular inflammation, vascular damage and erythrocyte extravasation. Multiple etiologies.
- Leukocytoclastic vasculitis + thrombosis: Severe infections (septicaemia, meningococcal infections, measles),

3. Purpuric eruption secondary to vascular occlusion

Clinically manifested as cutaneous purpuric lesions with a retiform (net-like) pattern. May be inflammatory and non-inflammatory.

Different etiologies: Hypercoagulable states, emboli, medium-large sized vasculitis

4. Miscellanea. Secondary to vascular fragility, perivascular inflammation, etc.

Congenital diseases: Connective tissue diseases (Ehlers-Danlos syndrome), congenital infectious disorders (TORCH): cytomegalovirus (CMV), rubella. Drug-induced purpura, age related (senile) purpura, secondary to trauma, factitial, etc.

Signs & Symptoms

Purpura is clinically manifested as non-blanchable red-brown to golden-brown (due to erythrocyte extravasation and hemosiderin deposition) lesions in which the application of external pressure does not lead to disappearance of the red color.

Purpuric non-palpable lesions can be divided according to their size in:

Petechiae (capillary, punctiform hemorrhages with a limit of up to 4 mm).

Macular purpura (sized up to a centimeter)

Macular ecchymoses, (larger amount of extravasation of erythrocytes).

In purpuric rashes skin eruption may be manifested by lesions of variable size, extension and distribution. Occasionally confluent, or associated with edematous plaques, blisters, or pustules. Can be accompanied by gingival or gastrointestinal (GI) bleeding, hematuria, or by internal hemorrhage according to the etiology.

In some disorders fever and a toxic syndrome may be present. Tenderness may suggest an inflammatory process.

Localisation

Purpuric rashes could be localized or generalized. Variable localization. May be present in acral areas,

or in dependent areas often on the lower extremities.

Classification

Depending on the association of a febrile illness or constitutional/toxic symptoms.

Purpuric rashes can be classified as:

1. Non-palpable and afebrile rash

Frequently associated with:

- Coagulation disorders
 - Platelet-related disorders, thrombocytopenic purpura (idiopathic or secondary). Coagulation factor deficiencies.
- Entities presenting erythrocyte extravasation secondary to perivascular inflammatory infiltrates (without vasculitis)
 - Pigmented purpuric eruptions: Group of disorders manifested as petechiae and pigmentary macules. Include:
 - Purpura pigmentosa progressiva (Schamberg disease): Multiple patches with pinpoint petechiae on the lower limbs
 - Purpura annularis telangiectodes (Majocchi): Annular plaques
 - Lichenoid purpura (Gougerot-Blum): Lichenoid purpuric papules/plaques
 - Eczematoid-like purpura: Pruritic scaly petechial plaques
 - Lichen aureus: Localized, persistent, purpuric golden-brown macules.
- Diseases associated with non-inflammatory vessel wall dysfunction or fragility:
 - Scurvy, genetic conditions (Ehlers-Danlos, Marfan's syndrome etc.), senile purpura (severe dermatoporosis with stasis), amyloidosis and Cushing's disease, physical/mechanical by pressure (vomiting, strangulation, coughing)

2. Non-palpable and febrile rash

- Infectious coagulopathies:
 - Tropical viral hemorrhagic fevers (dengue, yellow fever, Ebola)
 - Cocci (Purpura fulminans)

3. Palpable and afebrile rash.

- Leukocytoclastic vasculitis
 - Cutaneous small-vessels vasculitis, including IgA vasculitis (Henoch-Schönlein purpura), cryoglobulinemic vasculitis, urticarial vasculitis, ANCA-related vasculitis (microscopic polyangiitis, granulomatosis with polyangiitis, eosinophilic granulomatosis with polyangiitis [Churg-Strauss disease])

4. Palpable and febrile.

- **Infectious** disorders. Potentially life-threatening conditions.
 - Meningococemia, bacterial endocarditis, rickettsiosis, disseminated gonococcal infection, purpuric viral exanthems.
- **Non-infectious**: Systemic vasculitis, ANCA-related vasculitis.

5. Retiform and afebrile.

- Embolic conditions. Hypercoagulable states.
 - Nicolau syndrome; anticoagulant induced necrosis; calciphylaxis, vasculopathies; anticardiolipin syndrome.

6. Retiform and febrile.

- Vasculitis + thrombosis.
 - Septic vasculitis, post-infectious purpura fulminans, HELLP syndrome.

Thrombotic thrombocytopenic purpura.

Laboratory & other workups

Glass spatula and Rumpel-Leede test. Complete hematological survey. Platelet count and coagulation tests. Biochemistry (liver and renal functional tests, plasma electrophoresis) immunological serum tests, stool guaiac, urinalysis may be performed according to the suspected underlying diagnoses. Specific microbiological cultures: in cases of suspected underlying infectious disease.

Dermatopathology

The hallmark of purpuric lesions is extravasation of erythrocytes around the capillaries and venules and interstitial with or without vasculitis signs. Skin biopsy in cases of palpable purpuric rash or febrile purpuric eruptions

Diagnosis

- Clinical evaluation: Age: Some purpuric rashes are almost exclusively observed in children (Henoch-Schönlein purpura) or in elder patients (senile purpura)
- Clinical history. Acute or prolonged evolution of lesions. Possible precipitating events (sick contacts, drugs)
- Physical examination: Skin and mucous membranes. Rash distribution (symmetrical or asymmetrical) and progression.
- Associated general bruising or systemic symptoms (fever, hypotension). In selected cases hepatomegaly/splenomegaly or neurological signs.

Course

Depending on the underlying etiology. Acute, subacute or chronic.

Complications

Depending on the underlying etiology from self-limited to lethal outcome.

Differential Diagnosis

Exclude secondary hemorrhagic variants of common diseases (hemorrhagic zoster, cellulitis etc.). Exclude minor conditions with hemorrhagic lesion (senile purpura, skin areas treated with topical corticosteroids, petechial facial purpura due to vomiting or coughing).

Prevention & Therapy

Depending on the underlying etiology.

Special

None.

References

- [Antonov D, Kamarashev J, Kazandjieva J, Neykova T, Tsankov N. The rash that becomes purpuric, petechial, hemorrhagic, or ecchymotic. Clin Dermatol. 2020; 38:3-18.](#)
- [Katsambas A, Stefanaki C. Life-threatening purpura and vasculitis. Clin Dermatol. 2005; 23:227- 37.](#)

- [Georges C, Fox LP, Harp J. Retiform purpura: A diagnostic approach. J Am Acad Dermatol. 2020; 82: 783-796.](#)
- [Lutze S, Westphal T, Jünger M, Arnold A. Microcirculation disorders of the skin. JDDG: Journal der Deutschen Dermatologischen Gesellschaft. 2023;1-27. <https://doi.org/10.1111/ddg.15242>](#)

8.8 Red swollen legs

Grading & Level of Importance: B

G. Girolomoni, Verona; P. Gisondi, Verona; M. Maurelli, Verona



ICD-11

None.

Synonyms

None.

Definition

Red swollen legs (RSL) are characterized by inflammatory erythema and edema. Reasons behind these symptoms are several underlying disorders. RSL can be either acute or chronic.

Epidemiology

Depends on the underlying condition, the most frequent are:

- Erysipelas: incidence around 1100/100.000 per year.
- Deep vein thrombosis: incidence 80/100.000 per year, prevalence 1/1.000.
- Superficial thrombophlebitis: 125.000 cases/year, with an increased incidence from the third to the eighth decade in men and a preponderance among women of 55-70% approximately.

Aetiology & Pathogenesis

- Erysipelas: see chapter 2.2.3
- Deep vein thrombosis (DVT): manifests with leg pain, swelling, tenderness, increased temperature, pitting oedema, and prominent superficial veins. DVT occurs in association with several risk factors, including postoperative immobilization, long-haul travel and age, male

gender, genetic or acquired thrombophilia, obesity, acute medical illness, cancer, and pregnancy.

- Superficial thrombophlebitis: inflammation of a superficial vein due to a blood clot; it is believed that the cause is a disequilibrium of the haemostasis. Chronic disorders include cardiovascular disease (CVD) where venous hypertension results in localised oedema that traps leukocytes and neutrophils in the tissues. Tissue damage eventually results in the development of dermatitis, fibrosis, and ulceration.
- Contact dermatitis: acute onset allergic contact dermatitis is common, especially in the setting of stasis dermatitis and is often related to hypersensitivity reactions to topical medications. Dermatitis manifests with an acute eczematous reaction with erythema and vesiculation followed by desquamation. Itch may be severe.
- Borreliosis: associated with and without fever.

Increasing age and compounding morbidity, such as reduced mobility following a stroke, arthritic changes, obesity, and generalised frailty are promoting factors. Predisposing factors include potential site of pathogen entry (e.g., ulceration, tinea pedis, and traumatic wounds), chronic oedema in liver cirrhosis, cardiac or renal insufficiency, acute and chronic lymphoedema, CVD, diabetes mellitus and obesity.

Predisposing factors: prolonged standing or sitting with the ankle and calf-muscle pump inactive, female gender, obesity, older age, post-thrombotic syndrome.

Localisation & Symptoms

Redness and swelling due to oedema or fibrosis that affects one or both legs and/or feet up to the thighs, accompanied by warmth and tenderness in the area, depending on the underlying condition. Superficial and deep vein thrombosis as well as erysipelas are painful, whereas contact dermatitis is itchy. Chronic late stage borreliosis may be symptomless.

Classification

The classification is based on the occurrence of an acute or a chronic disorder.

- Acute disorders: erysipelas, necrotizing fasciitis, superficial thrombophlebitis, DVT, stasis and contact dermatitis, traumas and septic arthritis.
- Chronic disorders: chronic oedema, lymphoedema, pretibial myxedema, CVD manifesting with stasis eczema, venous leg ulcers and lipodermatosclerosis.

Laboratory & other workups

Inflammatory markers, such as the erythrocyte sedimentation rate (ESR), C-reactive protein (CRP), D-dimer and white cell count may be helpful in diagnosing and monitoring for vein thrombosis. Microbiology of any skin injury location should be considered before antibiotics are started. It is important to test the Wells score, which stratifies DVT risk into low-, moderate-, or high-risk categories. Ultrasound with echocolor Doppler is important to confirm or exclude vein thrombosis. Measure of circumference at different marker points to follow up course for progress or improvement.

Dermatopathology

Is based on the underlying disorder.

Course

Red swollen legs can be an acute or a chronic disorder depending on the pathological process.

Complications

Age-related poly-morbidity is increasing as people are living longer and adopting prolonged unhealthy lifestyles. Complications may result from bacterial or fungal infections ulceration, traumatic wounds, stage III lymphedema, venous insufficiency and obesity.

Diagnosis & Differential diagnosis

- Acute disorders include skin infections (erysipelas, stage II and stage III borreliosis, septic panniculitis, and necrotizing fasciitis), joint infections (arthritis) all of which are associated with fever. The most crucial early characteristic symptom is a disproportionate level of pain compared with the presenting symptoms. Other acute disorders to consider include DVT, superficial thrombophlebitis and acute onset allergic contact dermatitis:
- Chronic disorders include lipodermatosclerosis and stasis eczema. Lipodermatosclerosis is an inflammation of subcutaneous fat, and presents as fibrosed, rigid, red or brown skin, typically affecting the medial aspect of the calf. The subcutaneous tissues may become firm and depressed, and if circumferential damage occurs, could eventually result in an 'inverted champagne bottle' effect. Stasis eczema is a consequence of CVD, with skin becoming itchy, red, swollen, dry and flaky, scaly or crusty, and weeping. Chronic lymphedema due to lymphatic vessel occlusion is firm and permanent. Oedema due to liver cirrhosis, nephrotic syndrome and heart insufficiency or imbalance of protein metabolism fluctuate between periods of improvement and periods of increased severity.

Prevention & Therapy

See the respective diagnoses.

Special

None.

References

- [Ngwanya RM, Spengane Z, Michael O. \(2019\) Tender nodules and swollen red legs: answer. Am J Dermatopathol. Nov;41\(11\):858-859. doi: 10.1097/DAD.0000000000001223. PMID: 31633551. Moore Z, O'Brien G, Collier M et al \(2022\) Patients presenting with 'red legs': Differential diagnosis and the role of compression. London: Wounds International. Available online at: \[www.woundsinternational.com\]\(http://www.woundsinternational.com\)](#)

8.9 Infantile skin



Grading & Level of Importance: B

K. Hannula-Jouppi, Helsinki; A. Ranki, Helsinki; A. Salava, Helsinki

Definition

The term “newborn” refers to a baby from birth to ca. 2 months of age and the term “infant” denotes children from birth to 1-year old. Children from 1 year to the age of 4 years old are called toddlers.

Infant skin occurs after the newborn child’s transition from the in-utero environment to the status of self-sufficiency. Healthy full-term newborn skin is well-developed with a thick epidermis and complete stratum corneum and can already function properly.

Development

Skin maturation starts during embryogenesis. The epidermis begins to stratify at the end of the first trimester, and shows definitive layers towards the end of the second trimester. The structural maturation of the skin is complete at 34 weeks of gestational age but pre-term neonates have decreased epidermal and stratum corneum thickness. After birth, human skin undergoes a maturation process with adaptation of the skin to a relatively dry environment compared with the in-utero situation. In newborns, dehydration and hypothermia, as well as percutaneous absorption of toxic agents, can have serious consequences. Transepidermal water loss (TEWL) decreases along with gestational and postnatal age and TEWL is a good marker of gestational age at birth.

Defects of different origin (genetic, traumatic) or interruptions in the maturation process by nutrition deficiency or drugs or infections may partly explain propensities to different skin problems of neonates and infants. Neonates and infants have a characteristic spectrum of skin problems and associated skin diseases.

Structure & Physiology

In the course of skin maturation cell-to-cell connections and the number of cells in the epidermis increase and hereby rete ridges and dermal papillae are formed. In preterm neonates the dermoepidermal junction is looser and the anchoring structures are decreased being more susceptible to traumatic or infectious blister formation. Thus, the skin of newborns is much more permeable than the skin of older children. The external genitalia have especially thin skin. Various excipients used in skin care products may have greater toxicity in newborns than adults. Characteristically, the ratio of body surface to body mass is more than two times greater in newborns compared to adults, and newborns also lack functionally mature metabolic systems. Particular attention should be paid to products that are not rinsed off due to the risk of accumulation of potentially harmful excipients.

In newborn the superficial blood vessels have developed a horizontal plexus with an immaturely organized capillary network. The development of a fully organized capillary bed is usually accomplished by the age of 3-4 months. Many transient skin changes in newborn are based on the immature superficial microvasculature.

Based on a strong androgenic stimulation (mostly maternal androgens) the amount of sebum production is relatively high in the first weeks of life. Seborrhea subsequently decreases during the first months of life. Infants have lower amounts of melanin in the epidermis compared to adults. The adaptive increase of melanin begins with the first UV exposures. Frequent sunburns and exposure to sunlight in childhood are related to melanoma development and effective UV protection is warranted.

Biochemistry

In term babies, surface skin acidity (pH) is neutral at birth but decreases during the first one to four days, and continues to drop during the first months, so that an infant's skin pH level is usually between 5 and 5.5, which is higher than in the adult skin. The acid mantle plays an important role in skin defense and the composition of the microbiome. The vernix caseosa, which develops during the last trimester of gestation and is a complex mixture of water, protein and sebaceous lipids (barrier lipids such as hydrocarbons, wax esters, cholesteryl esters, diol diesters and triacylglycerols, with a characteristic sex diversity), is a protective covering. In addition to the immature epidermal barrier, preterm neonates lack the protective coating of vernix caseosa, thus having an increased risk of skin infections and hypothermia. In addition to the natural moisturizing functions, vernix is antimicrobial while containing lysozyme and lactoferrin and antimicrobial agents. In addition, vernix increases wound healing and contains anti-inflammatory molecules such as linoleic acid. Due to the important function of the vernix,

bathing of the newborn during the first six hours of life is no longer recommended by the World Health Organization.

Microbiome

Immediately postpartum, skin microbiota are homogeneously distributed across the human body regardless of delivery method or gestational age. The skin of vaginally delivered newborns is colonized by vaginal *Prevotella* and *Lactobacillus* species, while the skin of neonates born by Caesarean section show a diverse community of cutibacteria, corynebacteria and micrococcae. However, at sites such as the nares and oral cavity, neonates born vaginally have bacterial communities equally similar to both maternal skin and vaginal flora. The similarity between mother and infant microbiota decreases over the first year of life, and becomes replaced by strains from close contacts and the environment. The early skin microbiome does not show anatomically site-specific composition, which starts to develop between 1-3 months of life, but still differs significantly from the adult skin microbiome until late adolescence.

Data on the fungal components of the infantile cutaneous microbiome (the mycobiome) is sparse. It is known that *Malassezia* colonization and diversity increase with age, becoming adult-like by the first month of life.

Immunology

As a barrier surface, the skin plays an important role as the first defense line and site of pathogen exposure of the innate and adaptive immune system. The abundant skin-associated immune tissue orchestrates the defense against pathogens, responds to environmental changes, and has also functions in homeostasis. The newborn is working with an innate immune system that is supported by the adaptive immune system. In newborn skin the amount of antimicrobial proteins, lysozyme and lactoferrin are higher than in adults. However, newborn skin contains fewer immune cells than adult skin but typically anti-inflammatory regulatory T-cells (Tregs) occur at higher density than in adult skin. The cellular and chemical environment of the infantile skin is skewed toward keeping the immune cells in an immunosuppressed or immunologically inert state. However, the early life skin environment is important in fostering the development of adaptive lymphocytes and immune cell differentiation.

Sensitivity (Nerves)

The neural network develops early in the fetus and organizes with increasing postnatal age and consist of both somatic sensory and autonomic sympathetic fibers. Neurocutaneous responses and sensitivity to touch are important for overall development and skin function but also skin-skin contact and bonding with caregivers.

Risk for Diseases

Due to the immaturity of the innate and adaptive cellular immunity, neonates and infants have a greater risk of skin infections.

Traumatization

The thin skin of a preterm infant is most vulnerable and skin injuries are common in preterm infants admitted to a neonatal intensive care unit (NICU). The first stage of managing skin injuries is prevention based on the skin physiology at the given age of life. During admission to NICU, skin assessment is an essential part of care to reduce the risk of acquired skin injuries. The main types of injuries are bruises, blistering, excoriation, erythema and pressure injuries. The most common cause to bruises at a hospital setting are equipment used for blood sampling.

Prevention

Full-term newborns tolerate early bathing in terms of temperature regulation but the WHO does not recommend early bathing. Full-term newborns may receive tub baths while for preterm infants swaddle baths are recommended and daily cleansing of preterm infant skin is not recommended. For most topical agents used in neonatology, there are alternatives that have fewer excipients. Particular attention should be devoted to topical agents due to the risk of accumulation of potentially harmful excipients. Due to the increased permeability of neonatal and infant skin, several topical agents should be used with caution in infants e.g. alcohol, ammonium lactate, glycerin, urea, salicylic acid, neomycin, lidocaine, prilocaine, povidone, calcipotriol, tacrolimus, pimecrolimus and corticosteroids.

Spectrum of skin diseases in neonates and infants

Most skin problems in the newborn period and infancy are benign and transient. Eczematous eruptions (e.g. atopic dermatitis (AD) and seborrheic dermatitis (SD)), reactive pustular rashes (e.g. erythema toxicum neonatorum) and acne (acne infantum) are among the most frequent in newborns and small infants. Erythema toxicum neonatorum is relative common but its etiology is unknown. Barrier dysfunction, inflammation, and microbes contribute to the pathogenesis of AD, while the exact etiology of infantile SD affecting the face, ears, neck, and diaper area is unknown, but a relationship with the lipophilic yeast *Malassezia* is implicated (pustulosis cephalica neonatorum). The eczematous eruptions during infancy are discussed more in detail in connection of the specific types of eczema in the respective chapters.

Nevertheless, skin infections (e.g. bullous impetigo, staphylococcal scaled skin syndrome) and rare systemic diseases (e.g. Langerhans cell histiocytosis, cutaneous mastocytosis, Hyper IgE-syndrome) can also cause skin rashes. Also neonatal lupus erythematosus caused by trans-placental maternal autoantibodies should be recognized to rule out permanent cardiac abnormalities.

Common benign and transient skin changes in newborn

Milia and miliaria in newborn and small infants are based on the immaturity of adnexal structures of the still developing skin. Milia are frequent on newborn skin and are characterized by 1-2 mm sized white to yellow papules commonly on the face. Miliaria are usually red 1-2 mm sized papules concentrated on the trunk and are aggravated by high ambient temperatures. Both skin changes do not need treatment. Sebaceous hyperplasia on the nose and upper lip, as well as neonatal cephalic pustulosis with a facial papulopustular eruption during the first weeks or up to 6-8 weeks are common and transient.

Reactive pustular rashes are relatively frequent in the neonatal period. The most common transient pustular rash is erythema toxicum neonatorum, which usually is clinically diagnosed during the first week and disappears within 1-2 weeks after birth. Differential diagnoses include neonatal bullous impetigo and severe neonatal candida and herpes infections (sepsis).

Cutis marmorata is the most common transient skin change in newborn. It consists of a symmetric reticular erythema resulting from a physiological response to cold exposure (vasoconstriction of superficial dermal vessels). The phenomenon usually disappears during infancy.

Neonatal jaundice (icterus) is common and physiological and typically peaks at 3-4 days of age or in preterm infants. It is caused by tissue deposition of bilirubin.

Genodermatoses

Most genodermatoses manifest neonatally or during infancy. Genetic mutations in proteins associated with the dermoepidermal junction and the dermal anchoring cause different genetic blistering diseases (Epidermolysis bullosa). Incontinentia pigmenti manifests neonatally with linear blistering following the lines of Blaschko, turning into linear plaques on the trunk and extremities. X-linked dominant inheritance of NEMO- mutations renders females affected with multisystem involvement frequently also the eyes, central nervous system and teeth.

Ichthyoses are group of cornification disorders, where the skin thickens, scales and is inflamed at variable levels but may also pose a severe barrier defect. A collodion membrane may encase newborn, who later develop different, mostly severe, forms of ichthyoses e.g. lamellar ichthyosis, congenital ichthyosiform erythroderma or self-improving ichthyosis. Milder forms such as ichthyosis vulgaris and X-linked ichthyosis manifest typically during infancy, but boys with X-linked ichthyosis are usually born post-term and after prolonged labor. Some ichthyoses are part of syndrome with extracutaneous features. Acrodermatitis enteropathica is a very rare disorder of infancy associated with zinc deficiency (inherited zinc transporter defect). It presents with the classic triad of peri-acral and periorificial dermatitis often mimicking atopic or seborrheic dermatitis, diarrhea and alopecia. The therapy consists of life-long zinc substitution.

Café-au-lait macules indicative of neurofibromatosis and hypopigmented macules associated with tuberous sclerosis become increasingly evident neonatally and throughout infancy. Some palmoplantar keratodermas (PPK), especially diffuse PPKs manifest during infancy.

Laboratory & other workups

Laboratory investigations are rarely needed in skin diseases of infancy. In severe seborrheic dermatitis with periorificial distribution, zinc deficiency has to be excluded (serum zinc concentration). Microbiologic swabs may be needed if a skin infection with bacterial resistance problems is suspected (e.g. bullous impetigo due to MRSA). In newborns with pustular eruptions and systemic illness the exclusion (skin and blood specimens) of candida and herpes simplex sepsis is necessary.

A skin biopsy is warranted if systemic diseases (e.g. Langerhans cell histiocytosis, mastocytosis) are contemplated. In erythrodermic and cases of severe ichthyoses and epidermolysis bullosa blood tests for e.g. full blood count, IgE, CRP, electrolytes and albumin and possible other specific test based on diagnosis should be conducted. Genetic tests are usually carried out if a specific genodermatosis is suspected (e.g. epidermolysis bullosa or ichthyoses).

Diagnosis

The diagnosis of skin problems in newborns and infants is usually based on the clinical findings and a thorough history and evaluations of symptoms. A detailed examination of the skin, hair, nails and the mucous membranes (status) is essential.

Investigations (laboratory, microbiology, histology) are needed in rare cases and are guided by clinical differential diagnoses. Genetic diseases are often suspected based on clinical findings but the definitive confirmation and classification is done with genetic profiling.

References

- [Fluhr JW, Darlenski R, Lachmann N, Baudouin C, Msika P, De Belilovsky C, Hachem JP. \(2012\). Infant epidermal skin physiology: adaptation after birth. Br J Dermatol. 2012 Mar;166\(3\):483-90. doi: 10.1111/j.1365-2133.2011.10659.x. Epub 2012 Jan 19. PMID: 21967466.](#)
- [Hulsmann AR, Oranje AP. Educational paper: neonatal skin lesions. \(2014\). Eur J Pediatr. May;173\(5\):557-66. doi: 10.1007/s00431-013-1956-0. Epub 2013 Feb 6. PMID: 23385854.](#)
- [Sethuraman G, Bhari N. Common skin problems in children. \(2014\). Indian J Pediatr. Apr;81\(4\):381-90. doi: 10.1007/s12098-013-1271-9. Epub 2013 Dec 22. PMID: 24362956.](#)

8.10 Aging skin

Grading & Level of Importance: B
C.C. Zouboulis, Dessau



ICD-11

EE40.Y

Synonyms

Dermatoporosis (aged skin).

Definition

Aged skin is characterized by a natural process of biochemical events, leading to gradual cell damage accumulation and development of various benign or malignant skin diseases.

Development

Gradually disturbance of biological processes including lipid barrier, angiogenesis, sweat production, deterioration of the epidermal immune response, wound healing, and production of calcitriol, but also development of cellular heterogeneity. Endogenous variables such as genetic predisposition, impairment of cellular metabolic pathways, qualitative and quantitative hormonal alterations (intrinsic ageing) and exogenous factors, such as ultraviolet irradiation, chemicals and toxins, pollution and smoking (extrinsic aging).

Structure and Physiology

Ethnicity-specific ageing characteristics.

Caucasians: greater skin wrinkle formation and sagging with an earlier onset. More prone to skin desquamation.

Afro-American and Caucasian women: higher prevalence of age-related dryness.

Asian women: Later wrinkling in the facial area, more sensitive to mechanical stimuli and exogenous chemicals, pigment spot intensity as cardinal skin ageing sign.

Intrinsically (genetically/hormonally) aged skin: macroscopically thin and atrophic, exhibits fine

wrinkles, subcutaneous fat loss, prominent dryness and reduced elasticity in areas which are not light (sun)-exposed inner side of the upper arm and the gluteal region.

Extrinsically (photo-) aged skin: deeper wrinkles, thickening of the epidermis, dullness, roughness and mottled discoloration in constantly UV-exposed skin regions, facial skin, hand skin. Telangiectasias and pigmentary discoloration might also be observed in advanced and severe degrees of photoaging.

Biochemistry

Aged skin exhibits increase of oxidative stress-inducing molecules as well as reduction of niacin, vitamins C and E, co-enzyme Q10, α -lipoic acid, growth hormone, sexual hormones.

Immunology

With advanced age the number of the antigen-presenting Langerhans cells (LCs) significantly decreases. The cells undergo morphologic alterations, reduced antigen-trapping capacity, and diminished cutaneous immune function. In photoprotected skin, TNF- α -induced LC migration is significantly affected, and LCs exhibit reduced response to TNF- α stimulation, leading to limited TNF- α -induced perivascular polymorphonuclear infiltrates in inflammatory reaction, making aged skin susceptible to infections.

Course and Risk of Diseases

Gradual development in healthy individuals. In women, rapid progression in approx. 10 years after menopause. Quick development in progeria syndromes.

Aged skin risks the development of common skin lesions (e.g., dry skin, pruritus, telangiectasias, senile purpura, freckling, lentiginos, guttate hypomelanosis, stellate pseudoscars, solar comedones, colloid milia, lichen sclerosus et atrophicus).

It is also prone to

- Benign tumors (e.g. seborrheic keratoses, cherry angiomas).
- Premalignant tumors (e.g. actinic keratosis, Morbus Bowen, lentigo maligna).
- Malignant tumors (e.g., basal cell carcinoma, squamous cell carcinoma, malignant melanoma, cutaneous lymphomas, angiosarcoma, Merkel cell carcinoma, Kaposi sarcoma, atypical fibroxanthoma, sebaceous carcinoma, cutaneous metastases).
- Infectious diseases (e.g. dermatophytosis, cellulitis, zoster).
- Bullous dermatoses (e.g. bullous pemphigoid, pemphigus vulgaris).

- Autoimmune diseases (e.g., contact dermatitis, atopic dermatitis, vitiligo, psoriasis, lupus erythematosus).
- Lichen simplex chronicus.
- Pressure ulcers, lower extremity ulcers.
- Vulvodynia, glossodynia, atrophic balanitis.

Diagnosis

Clinical signs, photographic severity scales and other imaging methods assess the severity of skin ageing features. Fluorescent detection of Advanced Glycosylated Elements (AGEs) at the frontal forearm area.

Dermatopathology

Light-protected skin: Epidermal thinning (10-50%), atrophy of the stratum spinosum, increased heterogeneity in size of basal cells, decreased mitotic activity, flattening of the dermoepidermal junction decrease and heterogeneity of melanocytes, decrease of Langerhans cells, reduction of dermal thickness, atrophy of the extracellular matrix, reduction and disintegration of collagen and elastic fibers, reduction of cutaneous microvasculature, decrease of skin appendages, thinning of subcutaneous fat. Light-exposed skin: Epidermal thickening, impaired proliferation, and differentiation of keratinocytes, sparse distribution of collagen fibers, stellate phenotype of fibroblasts increases in mast cells and neutrophils, flattening of the dermoepidermal junction, thickening of the vascular walls of arterial and venous capillaries, marked regression and disorganization of small blood vessels.

Differential Diagnosis

Metabolic disturbances (internal diseases), hormonal deficiencies, Progeria syndromes.

Prevention & Therapy

Consequent avoidance of overexposure to extrinsic factors, diagnosis and treatment of underlying internal diseases (the skin is mirror of the body), regular topical care and systemic and nutritional uptake of antioxidants (vitamins D, C, E, carotenoids).

Moderate to severe skin ageing: skin anti-aging cosmetics, camouflage (make-up), chemical peelings, dermabrasion, ultrasound energy devices, LASER resurfacing.

Deeper, severe aging: injection of botulinum toxin or fillers, collagen or hyaluronic acid injections, own fat, Gore-Tex implants.

References

- [Kohl E, Steinbauer J, Landthaler M, Szeimies RM. Skin ageing. J Eur Acad Dermatol Venereol 2011; 25\(8\):873-884.](#)
- [Wong, Q.Y.A., Chew, F.T. Defining skin aging and its risk factors: a systematic review and meta-analysis. Sci Rep 11, 22075 \(2021\). <https://doi.org/10.1038/s41598-021-01573-z>](#)
- [Shin SH, Lee YH, Rho N-K and Park KY \(2023\) Skin aging from mechanisms to interventions: focusing on dermal aging. Front. Physiol. Sec.Skin Physiology. Vol. 14:1195272. <https://doi.org/10.3389/fphys.2023.1195272>](#)

8.11 Progeria syndromes

Grading & Level of Importance: B
C.C. Zouboulis, Dessau



ICD-11

LD2B

Synonyms

Progeroid syndrome(s), premature aging syndromes, segmental progeroid syndromes, laminopathies (Lamin A gene mutation syndromes).

Definition

Syndromes characterized by premature aging signs, namely hair loss and alopecia, skin atrophy, sclerotic skin changes, teleangiectasias, poikiloderma and increased prevalence of skin tumors may occur. Premature aging only affects certain types of tissues in each syndrome.

Epidemiology

Laminopathies are extremely rare disorders. Hutchinson–Gilford progeria syndrome only affects one child per 4.000.000 births worldwide.

The prevalence of atypical Werner syndrome is 0.1-0.2 out of 100.000 live births.

Cutis laxa syndromes are a heterogeneous group of rare (incidence < 1:1,000,000) connective tissue disorders.

Wiedemann–Rautenstrauch syndrome is a newly identified progeroid syndrome with approx. 50

patients described to date.

Werner syndrome is estimated to occur in 0.5-1 out of 100.000 live births worldwide. It has a high prevalence in Japan, where the frequency has been reported to be as high as 2,5-5 in 100.000 live births.

Classification

More than 100 syndromes with clinical signs of premature aging have so far been described in the scientific literature, but only in recent years the genetic defects causing these syndromes have been identified by analyses performed on very few patients, using high-throughput sequencing (next-generation sequencing). The list of the most prominent progeria syndromes includes:

A. Congenital progeroid syndromes

I. Laminopathies

Hutchinson–Gilford progeria syndrome (commonly called progeria) Restrictive dermopathy

Mandibuloacral dysplasia

LEMD2-associated progeroid syndrome

Atypical Werner syndrome (atypical progeroid syndrome)

II. Other progeroid syndromes

Wiedemann–Rautenstrauch syndrome (neonatal progeroid syndrome) CAV1-associated neonatal progeroid syndrome

PYCR1-related Cutis laxa syndrome

B. Juvenile/adult progeroid syndromes

Werner syndrome (adult progeria)

Myotonic dystrophy type 1 Cockayne syndrome

Néstor–Guillermo syndrome

Ruijs–Aalfs syndrome

Lessel-Kubisch syndrome (MDM2-associated progeroid syndrome)

Aetiology & Pathogenesis

The majority of progeria syndromes are rare autosomal recessive genetic conditions and show gene defects in DNA replication, recombination, repair and transcription as well as mitochondrial function. Several of these syndromes are laminopathies, namely diseases caused by mutations in components of the nuclear lamina due to Lamin A (LMNA) gene mutations.

- Hutchinson-Gilford progeria syndrome: Its main cause is a sporadic autosomal dominant point mutation in LMNA gene resulting in differently spliced lamin A protein known as progerin. Accumulation of progerin under nuclear lamina and activation of its downstream effectors cause perturbation in cellular morphology and physiology which leads to a systemic disorder that mainly impairs the cardiovascular system, bones, skin, and overall growth.
- Restrictive dermopathy: Neonatal lethal disease caused by a LMNA or ZMPSTE24 gene mutation.
- Mandibuloacral dysplasia (types A and B) is caused by a LMNA (type A) or ZMPSTE24 (type B) gene mutation.
- LEMD2-associated progeroid syndrome is caused by a de novo mutation in LEMD2 gene, which encodes the nuclear envelope protein LEM domain-containing protein 2.
- Atypical Werner syndrome: Roughly 20% of patients clinically diagnosed with Werner syndrome do not carry WRN mutations, but harbour mutations in the LMNA gene. 24 such LMNA mutations have been identified to date and these patients are classified as atypical Werner syndrome.
- The Wiedemann–Rautenstrauch syndrome is caused by mutations in the RNA polymerase III subunit A (POLR3A) gene.
- CAV1-associated neonatal progeroid syndrome is caused by a de novo, heterozygous, frame-shift mutation in the Caveolin 1 (CAV1) gene.
- PYCR1-related Cutis laxa syndrome is a pyrroline-5 carboxylate reductase-1 (PYCR1) gene-related disorder. Werner syndrome is caused by a truncating mutation in the WRN gene due to the production of a stop codon from a nonsense or frameshift mutation. The WRN gene encodes a 142 amino acid protein that is part of the Rec Q DNA helicase family. Its function is to unwind the 2 DNA strands and act as an exonuclease. The WRN gene plays a role in maintaining proper DNA replication and repair through base excision repair, non-homologous end-joining, and homologous recombination. It is also involved in maintaining telomere stability, which is pivotal for genomic stability. Gene expression comparisons of patient skin cells vs skin cells of aged and young healthy donors exhibited a 91% homology, indicating that the defect skin cell function in Werner syndrome is similar with the defect cell function in aged skin. In progeria syndromes, a disturbed ribosomal biogenesis is considered as the major reason for the observed accelerated ageing signs. It is postulated that epigenetic changes to histones can contribute to the pathogenesis of Werner syndrome, but there is not enough data to support this theory.

- The Cockayne syndrome is caused by mutations in either the ERCC8 (type A) or ERCC6 (type B) genes. Néstor-Guillermo progeria syndrome is caused by a Barrier to Autointegration Factor 1 (BNF1) gene mutation.
- The Ruijs–Aalfs syndrome has been associated with mutations in the Spartan (SPRTN) gene. SPRTN encodes the DNA dependent metalloprotease Spartan, which is intimately involved in the repair of protein-linked DNA breaks.
- Lessel-Kubisch syndrome is caused by mutations at the MDM2 gene, which encodes the E3 ubiquitin ligase.

Signs & Symptoms

Among the typical signs of premature ageing in progeria syndromes the premature onset of the following symptoms or disorders occur:

- Graying/loss of hair
- Hearing loss
- Cataract
- Scleroderma-like skin changes
- Type 2 diabetes mellitus
- Osteoporosis
- Atherosclerosis and coronary heart disease
- Various malignant tumors

Hutchinson–Gilford progeria syndrome is a systemic disorder that affects the majority of the organs of the body including the skin, bone, skeletal muscle, adipose tissues, heart, and large and small arteries. Certain tissues and organs like bones, joints, and the blood vascular system are more prominently affected. The children affected start exhibiting the symptoms of the disease at the age of 1-2. They present growth reduction, alopecia, loss of hairs of eyebrows and eyelashes, prominent scalp veins, sclerodermatous skin, loss of subcutaneous fat, high pitched voice, horseman stance, protruding ears, lacking ear lobes, reduction in hearing capability, sharp nose, cyanotic face, micrognathia, retarded and aberrant dentition, increased platelet number, prolonged prothrombin time, lean body, absence of puberty, alteration in metabolic pathways, extra-skeletal calcification, short dystrophic clavicles, pyriform thorax, thin legs, and stiff joints. In addition, patients experience angina, hypertension, and hip dislocation. Mental and cognitive abilities of the patients remain unaffected.

Restrictive dermopathy is a very severe lethal neonatal disease characterized by tightly adherent and translucent skin, dermal thinning, disorganized collagen fibers and an almost complete loss of elastic fibers in the dermis. The first signs appear during gestation and include severe intrauterine growth defects, reduced fetal movement and pre-term delivery.

Mandibuloacral dysplasia type A: Onset 4-5 years after birth, partial lipodystrophy, thin and rigid skin, aberrant skin pigmentation, bone and growth defects, insulin resistance.

Mandibuloacral dysplasia type B: Onset at 2 years of age, lipodystrophy, altered skin pigmentation, alopecia, severe bone and growth defects, insulin resistance.

Patients with atypical Werner syndrome exhibit a late onset at mid to late 30's, occurring with sclerotic skin, hair greying and alopecia, loss of subcutaneous fat, altered skin pigmentation, cardiovascular disease.

The Wiedemann–Rautenstrauch syndrome patients show prenatal growth retardation, resulting in reduced weight and length at birth. Typical clinical features include sparse hair, prominent scalp veins, triangular shape of face, sunken eyes, microstomia with maxillary hypoplasia, natal teeth, and a prominent chin. Perinatal respiratory problems are common among these patients.

CAV1-associated neonatal progeroid syndrome patients present lipodystrophy, pulmonary hypertension, cutis marmorata, feeding disorder and failure to thrive.

Clinical signs of PYRC1-related cutis laxa syndrome patients that typically manifest in the first 2 years after birth include osteopenia or osteoporosis, finger contractures, cataract, corneal opacity, and movement disorders. Significant progression of these signs is rare in children older than 2 years of age. Patients typically show prenatal growth retardation. In addition, many patients present with poor sucking ability, sparse hair, thin and transparent skin with prominent veins, mandibular hypoplasia, and lipodystrophy.

Patients with Werner syndrome develop skin ulcers, cataracts, graying or even loss of their hair, and hypogonadism. The loss of subcutaneous fat and dermal atrophy produces a scleroderma-like appearance. They typically have a bird-like face with short stature, high pitched voice, dental abnormalities, decreased body weight, and body mass index (BMI). Patients also experience a rapid loss of muscle mass, most notably in the limbs with sparing of the trunk. They also have a decrease in their grip strength and skeletal muscle index, reaching the level of sarcopenia before the age of 40.

They have impaired mobility and suffer from osteoporosis of the distal limb bones more so than the vertebral column. Soft tissue calcifications can occur, most commonly in the Achilles tendon. Pes planus, hallux valgus, and flexion contractures can occur in the feet with subsequent development of ulceration,

osteitis, and osteomyelitis. Metabolic abnormalities also occur, including the development of type 2 diabetes mellitus and an increase in visceral fat accumulation. Cardiovascular abnormalities develop as well, which can include atherosclerosis, mitral regurgitation, and aortic stenosis. Werner syndrome patients are at an increased risk of tumor formation, with up to 10% of patients developing a malignancy. However, the types of tumors that develop are unusual compared to the aging population. Up to 50% of the malignancies reported are soft tissue sarcomas, such as schwannoma, rhabdomyosarcoma, malignant fibrous histiocytoma, leiomyosarcoma, and osteosarcoma of the upper extremities. Patients have also been reported to develop meningiomas, malignant melanoma, and thyroid carcinomas.

Myotonic dystrophy type 1 is a progressive multisystem disorder, which typically manifests no earlier than about the age of 20 years and is primarily characterized by muscular dystrophy. Although there is a very rare congenital form—characterized by muscular hypotonia and very poor sucking ability, global developmental delay (frequently associated with respiratory insufficiency) are the first clinical signs. The Cockayne syndrome causes short stature, premature ageing, severe photosensitivity and moderate to severe learning delay. This syndrome also includes failure to thrive in the newborn, microcephaly and impaired nervous system development. Other symptoms may include hearing loss, tooth decay, vision problems, and bone abnormalities. There are three subtypes according to the severity of the disease and the onset of the symptoms: Cockayne syndrome type 1 (type A), sometimes called “classic” or “moderate” Cockayne syndrome, diagnosed during early childhood; Cockayne syndrome type 2 (type B), sometimes referred to as the “severe” or “early-onset” type, presenting with growth and developmental abnormalities at birth; Cockayne syndrome type 3 (type C), a milder form of the disorder.

Néstor-Guillermo progeria syndrome: Onset at 2 years of age, altered skin pigmentation, lipodystrophy, growth and severe bone defects, alopecia. Lack of cardiovascular complications.

The main features of Ruijs–Aalfs syndrome are evident in skeleton and face (triangular face). Patients develop hepatoma in the teens.

Lessel-Kubisch syndrome is characterized by short stature and progeroid features, including prematurely gray hair, pinched facies, and scleroderma-like skin changes. Renal failure-associated hypertension and hypogonadism have also been observed.

Laboratory & other workups

Genetic testing: multigene panel that includes LMNA, ZMPSTE24, and other genes of interest. Patients diagnosed with Werner syndrome should undergo regular screening tests for hyperlipidemia, breast and colorectal cancer, diabetes, and thyroid abnormalities. Given the number of musculoskeletal abnormalities and high prevalence of soft tissue sarcomas in Werner syndrome patients, clinicians

should perform an X-ray, CT, or MRI studies in the appropriate clinical scenario to evaluate for underlying disorders, infections or tumors thoroughly. DEXA scans should also be performed regularly to evaluate and monitor osteoporosis.

Dermatopathology

A common characteristic among laminopathies is that many are caused by an accumulation of unprocessed pre-lamin A. Skin biopsies from patients carrying LMNA or ZMPSTE24 mutations reveal increased nuclear size and an atrophic epidermis with focal hyperkeratosis and hypoplastic sebaceous glands. Patient cells exhibit nuclear abnormalities that become worse with extended in vitro culture and a mislocalization of other lamina-associated proteins.

Course

Hutchinson-Gilford progeria syndrome is characterized by accelerated ageing in affected children leading to premature death at an average age of 14.5 years due to cardiovascular complications.

Wiedemann–Rautenstrauch syndrome: The further course of the disease is characterized by growth delays, thin and atrophic skin, generalized lipodystrophy with local fat pads, joint contractures, progressive ataxia and tremor, as well as a global developmental delay. Clinical signs of premature ageing include thin and atrophic skin, progressive ataxia and tremor, as well as lipodystrophy with associated cachectic appearance. The life expectancy in patients with Wiedemann–Rautenstrauch syndrome is not yet known, but it is likely to be strongly associated with the severity of perinatal respiratory problems.

Patients with PYRC1-related cutis laxa syndrome may show with increasing age a global developmental delay (in some cases with cerebral malformations) with mild to moderate intellectual disability, microcephaly, and muscular hypotonia. In addition, characteristics of wrinkled, redundant and inelastic skin may become prevalent, resulting in a progeroid appearance. The life expectancy remains unknown to date.

Werner syndrome patients appear unaffected at birth and develop normally until the adolescent period or second decade of life when they start to exhibit signs and symptoms of accelerated aging. Patients develop skin ulcers, cataracts, graying or even loss of their hair, and hypogonadism. The loss of subcutaneous fat and dermal atrophy produces a scleroderma-like appearance. They typically have a bird-like face with short stature, high pitched voice, dental abnormalities, decreased body weight, and body mass index (BMI). Werner syndrome patients typically live into the fifth decade of life. Patients usually die of malignancy or cardiovascular disease.

Patients with myotonic dystrophy type 1 may additionally develop primarily frontal alopecia, cataract,

sensorineural hearing loss, dysarthria and dysphagia, cardiac arrhythmia, hypogonadism, type 2 diabetes, and hypothyroidism. The average life expectation is 48 to 55 years.

Néstor-Guillermo progeria syndrome progresses more slowly, patients do not exhibit cardiovascular complications and have a relatively longer lifespan.

Complications

Werner syndrome patients develop characteristic physical and metabolic abnormalities that result in severe complications more commonly seen in the elderly, including diabetes, hypertension, osteoporosis, myocardial infarction, stroke, and cancer. Caution should be exercised with Werner syndrome patients and chemotherapy treatments. They are at an increased risk of chemotoxicity due to their impaired ability in DNA repair mechanisms.

Diagnosis

Classic Hutchinson-Gilford progeria syndrome is identified on the basis of clinical symptoms and the medical history of the patient. Also, its presence can be confirmed by genetic testing for the mutation (c.1824C>T) in the Lamin A gene. However, there is no kit available for its early detection. Atypical Hutchinson-Gilford progeria syndrome is diagnosed on the basis of clinical features similar to the classic syndrome, resulting from a mutation in intron 11 (c.1968+1G>A, c.1968+2T>A, c.1968+2T>C, and c.1968+5G>C) of Lamin A gene. It can also be identified on the basis of c.1822G>A (p. Gly608Ser) variation in exon 11 of the Lamin A gene.

Werner syndrome: Genetic testing through nuclear sequencing by reverse transcription-polymerase chain reaction (PCR) with western blot protein analysis can confirm the diagnosis of Werner syndrome. Prenatal testing with amniocentesis and chorionic villus sampling can be performed in patients at high risk for having infants with this disorder.

Differential Diagnosis

All syndromes: Normal ageing, hormonal deficiencies, metabolic disturbances (internal diseases).
Werner syndrome: systemic sclerosis, dermatomyositis, and other premature aging syndromes.

Prevention & Therapy

Hutchinson-Gilford progeria syndrome: No cure has been found for this catastrophic disorder. In several clinical studies, lonafarnib, a farnesyl transferase inhibitor, demonstrated remarkable improvement in weight gain, vascular architecture and bone structure along with a decreased frequency of headaches and strokes; improvement in the life span; improvement in bone mineral density (in combination with pravastatin and zoledronic acid); and reduction of the prevalence of stroke, transitory ischemic attacks and headache.

Werner syndrome: Treatment is aimed at symptomatic relief and control of the secondary organ dysfunction. Treatment of atherosclerosis, hypertension, diabetes, and other diseases is achieved through standard conventional monitoring and medical therapy, but the disorder will continue to progress. It has been reported that bosentan, an endothelin receptor antagonist, can be used to treat severe cutaneous ulcers. Sodium etidronate can help improve symptomatic calcifications in the soft tissue. Orthotics can be used to manage complications with feet deformities. Cataracts should be managed surgically. Sarcopenia can be treated with diets rich in branched amino acids, exercise, vitamin D supplementation, and hormone therapy, although this is controversial given the increased risk of malignancy.

Cockayne syndrome: Treatment is supportive and may include educational programs for developmental delay, physical therapy, gastrostomy tube placement as needed; medications for spasticity and tremor as needed; use of sunscreens and sunglasses; treatment of hearing loss and cataracts; and other forms of treatment, as needed.

Special

For patients with the different progeria syndromes best care is given in specialized centers on an interdisciplinary team basis.

References

- [Ahmed MS, Ikram S, Bibi N, Mir A. Hutchinson-Gilford Progeria Syndrome: A Premature Aging Disease. Mol Neurobiol. 2018 May;55\(5\):4417-4427.](#)
- [Benedicto A, Chen X, Martin O Bergo MO & Andrés V \(2022\) Progeria: a perspective on potential drug targets and treatment strategies EXPERT OPINION ON THERAPEUTIC TARGETS 2022, VOL. 26, NO. 5, 393–399 <https://doi.org/10.1080/14728222.2022.2078699>](#)

8.12 Nutrition Disorders of the Skin

Grading & Level of Importance: B
H. Gollnick, Magdeburg



ICD-11

EB9Y / 5C3Y

Synonyms

Skin nutrition deficiency.

Definition

Skin disorders which include dermatoses resulting either from disturbed metabolic processes or from defective nutrition. Primary disorders of the skin which may be provoked or maintained by nutrition deficiencies.

Epidemiology

Nutritional deficiency is a global problem not only in developing countries or at war times and climate catastrophies. Despite being uncommon in developed areas of the world, it has become an increasing problem in these countries as well. It belongs to the large group of non-communicable diseases (NCDs), also known as chronic diseases, which tend to have of long duration and are the result of a combination of genetic, physiological, environmental and behavioural factors. Whereas in developing countries, nutritional deficiency mainly results from insufficient food supply, in industrialized countries alcoholism, gastrointestinal disorders and unhealthy and long-duration weight loss diets are the main drivers of nutritional deficiencies. However, poverty and loss to access of food is closely linked with nutritional deficiency.

Aetiology & Pathogenesis & Symptoms

Disorders of essential deficient supply of minerals and/or vitamins or their metabolism affecting the skin. Early clinical signs of nutrition deficiency are often visible at the skin, nails and/or hairs first. Although some signs are characteristic for a specific nutrient deficiency, often an overlap of skin manifestations is observed in multiple deficiency states.

Vitamin deficiencies:

Vitamin A is major factor in the maintenance of epithelial tissues. Deficiency occurs mainly from an inadequate intake, liver disorders and fat malabsorption. Disturbed keratinization of epidermis and follicles. Phrynoderma is a maximal clinical feature with follicular plugging. Sandpaper comedo pattern in acne can be associated with disturbed retinol metabolism.

Vitamin B₃ (niacin) deficiency (pellagra) arises most commonly in areas where corn is a substantial part of the food intake. Cutaneous manifestations of pellagra include dermatitis, sunlight sensitivity and hair loss.

Supplementation with niacin has a UV light damage protective effect (prevention of actinic keratoses).

Vitamin B₆ (pyridoxine) plays a key role as a co-factor in many enzymatic reactions in different metabolic

pathways. At the skin, vitamin B6 deficiency leads to seborrheic dermatitis-like eruptions, angular cheilitis, anemia and atrophic glossitis.

Vitamin B₁₂ (cyanocobalmin) is involved in many metabolic pathways especially the development of red blood cells and function of the nervous system. Vitamin B12 deficiency becomes an increasing problem in people under strict vegan diet without additional vitamin B12 substitution in Europe. Trichodynia may be associated with B12 deficiency.

Vitamin C (ascorbic acid) is one of the major anti-oxidative factors and plays an important role in collagen synthesis. Skin manifestations of vitamin C deficiency includes rough skin, follicular hyperkeratosis, perifollicular hemorrhagia, petechial bleeding, coiled hair and impaired wound healing. Scurvy represents the zenith of disease manifestation.

Vitamin D and its active metabolite 1,25(OH)₂D₃ are decreased when insufficient UVB exposure occurs. Skin types 5 and 6 living in North European latitudes are in danger of insufficient sun exposure for conversion of 7-dehydrocholesterol in the epidermis. Some evidence exists to link low D₃ levels and skin aging and xerosis of the skin.

Vitamin H (Biotin) as a co-enzyme of carboxylases and acting in signal transduction can be found reduced in pregnancy, long-term parenteral nutrition and biotinidase deficiency. Hair loss, brittle nails, periorificial dermatitis of mouth, nostrils, anus or vulva may appear.

Trace elements deficiency:

Iron deficiency resulting from reduced delivery via iron-containing food (meat, vegetables) can lead to pale skin due to anemia and via reduced oxygen supply disturbed skin and hair and nail growth (brittle nails). Itchy skin can be another symptom including urticaria.

Selenium is present in various selenoproteins, including phospholipid hydroperoxide glutathione peroxidase (PHGPx) and thioredoxin reductase (TDR). TDR is associated with keratinocyte cell membranes and its levels appear to correlate with susceptibility to UVB-induced damage (oxygen radical scavenger). Enzymes that convert the thyroid hormone thyroxine (T₄) to tri-iodothyronine (T₃) are selenium- dependent. Hair loss and some skin immune functions are disturbed in deficiency.

Zinc deficiency most commonly results from an inadequate dietary intake, imbalanced parenteral nutrition but also from a reduced absorption or increased loss. It is important for protein synthesis and plays a role in wound healing and the mucosal barrier. It is needed for constructing keratin and for the formation of the structural protein, collagen. In acrodermatitis enteropathica, zinc cannot be absorbed and after breast feeding is stopped, the first signs occur on the skin. Erosive inflammatory skin occurs with elevated desquamative margins in the anogenital area, fingers and feet and perioral areas.

Potassium deficiency (hypokalemia) most commonly results from an inadequate dietary intake, imbalanced parenteral nutrition but also from a reduced absorption or increased loss i.e. diuretics. It keeps cells in the epidermis hydrated and parallels skin dryness (xerosis) and reduced cell renewal. Foods high in potassium include all meats, potato skins, banana and broccoli.

Localisation

See above symptoms.

Classification

Vitamin and trace elements.

Laboratory & other workups

Laboratory analysis of blood and urine vitamin and trace element levels can be misleading because of the poor correlation with tissue vitamin concentrations. Sometimes genetic counselling is necessary because of rare enzymatic deficiency disorders.

Dermatopathology

Depending on the individual nutritional disorder.

Course

Depending on type of vitamin or trace elements either alone or in combination.

Complications

Depending on severity of malnutrition. Most severe course Morbus Kwashiorkor, one of the severe forms of protein-energy malnutrition (PEM). Skin lesions usually first occur where friction or pressure takes place: groin, knees, buttocks and elbows; in advanced cases, the dermatosis may be almost anywhere on the body trunk, limbs, or head. Darkly pigmented patches with desquamation and feature of old painting paper.

Diagnosis

The dermatologist is often the first physician who recognize nutritional deficiencies because mucocutaneous changes are visible and can be diagnostic in malnutrition. However, sometimes no clear diagnosis can be made in early stages of the deficiency. Although some signs are characteristic of a specific nutrient deficiency, an overlap of skin manifestations is observed in multiple deficiency states.

Often, patients present with more than one deficiency. Fully developed clinical signs such as acrodermatitis in zinc deficiency, phrynodema in vitamin A deficiency, vitamin H (biotin) and folic acid in seborrhoeic dermatitis or hair loss and brittle nails in iron deficiency, xeroderma in hypokalemia and combination of several vitamins and trace elements are diagnostic clues.

Differential Diagnosis

Nutritional deficiency disorders of the skin can mimic several dermatoses.

Prevention & Therapy

Although nutritional deficiencies are relatively uncommon in the general population, certain groups have a higher risk, including infants, pregnant women, alcoholics, vegetarians, persons of poor socio-economic status, poverty, and patients on dialysis, on certain medications (especially polypharmacy), or with a history of malabsorption or gastrointestinal surgery. Individual supplementation via the oral or parenteral route depending on the cause of deficiency has to be selected. Whereas substitution of water-soluble vitamins is not problematic, the treatment with fat-soluble vitamins (E-D-K-A) and zinc or selenium should be carefully controlled because of overdosage risk. Rapid clinical improvement following vitamin and trace element substitution frequently confirms the clinical diagnosis.

Special

Diet and supplementation should be verified by patients according to National or European recommendations by official scientific society or Government websites.

References

- [Jen M, Yan AC. Syndromes associated with nutritional deficiency and excess. Clin Dermatol. 2010; 28:669-85.](#)
- [Alana Deutsch & Jamie Manning \(2020\) Dermatologic Manifestations of Nutritional Deficiency. Current Geriatrics Reports \(2020\) 9:210–218. <https://doi.org/10.1007/s13670-020-00331-9>](#)
- [Krautheim A, Gollnick H \(2005\) Vitamins and skin. In: Lodèn M, Maibach HI ed.: Dry skin and moisturizers: chemistry and function, 2 nd. ed. 2005 Taylor & Francis Group, Broken S. 375-390](#)
- [Hans K. Biesalski \(2016\) Nutrition meets the microbiome: micronutrients and the microbiota Ann. N.Y. Acad. Sci. 1372 \(2016\) 53–64](#)
- [Wong ChY & Chu DH \(2021\) Cutaneous signs of nutritional disorders .International Journal of Women's Dermatology Vol 7, 5, Part A, December 2021, Pages 647-652](#)

8.13 Disorders with primary and secondary deposition in the skin

Grading & Level of Importance: B

M. Bagot, Paris; G. Dobos, Paris; A. de Masson, Paris;

ICD-11

5D00.Z

Synonyms

Amyloidosis, Mucinosis, Myxoedema, Hyalinosis, Xanthoma/Xanthelasma, Gout/Hyperuricaemia, Calciphylaxis, localized hypergammaglobulinemia deposition, Tattoo.

Definition

Disorders with primary and secondary deposition in the skin are a heterogenous group of diseases, characterized by the pathological accumulation of materials in the extracellular matrix of the dermis or subcutis. Primary cutaneous deposition disorders are limited to the skin, while secondary deposition disorders are the consequence of systemic diseases. These disorders can generally be diagnosed by histology. Systemic diseases associated with depositional disorders include myeloma, plasmacytoma or other lymphoma (amyloidosis), lymphoma (mucinosis, gammaglobulins), hyperuricaemia or leukaemia (gout), hypercalcaemia or renal failure (calciphylaxis), metabolic disorders (xanthoma/xanthelesma).

Epidemiology

These are rare diseases.

AL amyloidosis occurs in about 3-13 per million people per year.

Aetiology & Pathogenesis

Primary localized cutaneous amyloidosis can be caused by mutations in the OSMR or IL31RA gene. In primary localized cutaneous amyloidosis (lichen and macular amyloidosis), scratching the itchy skin is believed to induce keratinocyte necrosis, releasing proteins that abnormally clump together and form amyloids. Secondary (AL) amyloidosis is a consequence of light chain deposits that are produced by malignant plasma cells. Mucinosis may be triggered by thyreotic disorders (myxoedema), lymphomas, be associated with inflammatory skin diseases (such as lupus erythematosus) or be idiopathic. Uric acid deposits (gout) may be idiopathic or linked to an excessive alcohol and/or food (especially red meat) intake (majority of cases), be genetic (rare) or linked to drugs (diuretics), haematological disorders or chronic kidney disease. Calciphylaxis is caused by chronic, terminal renal failure. Skin calcinosis may also

be associated with connective tissue diseases (systemic sclerosis, lupus erythematosus, dermatomyositis). Tattoo is a consequence of trauma, or may be a voluntary intradermal pigment injection or a deposition of dust and burnt substances after an explosion in the immediate proximity.

Symptoms

- Primary localized cutaneous amyloidosis may be characterized by severely itchy patches of thickened, scaly and reddish-brown skin with multiple small bumps (lichen amyloidosis) or flat and dark brown patches (macular amyloidosis).
- Secondary (AL) amyloidosis is characterized by vessel fragility with pinch purpura and periorbital purpura, unexplained bleeding or macroglossia.
- Mucinosis presents as flat, shiny erythematous plaques.
- Progressive lipo-lymphedema associated with monoclonal gammopathy with diffuse plaque-like infiltrates
- Myxoedema presents with skin-coloured flexible plaques, “orange peel” surface often on pretibial areas. These lesions may rarely be hyperkeratotic.
- Xanthoma/xanthelasma is characterized by small yellowish, grouped soft nodules.
- Connective tissue disorders-associated calcinosis is defined by rock hard subcutaneous nodules that may fistulate.
- Calciophylaxis presents with skin necrosis with accompanying erythematous network like maculae (livedo), these are extremely painful.
- Pathological tattoo is characterized by localized black, grey or brown macules of millimetric size.

Localisation

- Primary localized cutaneous amyloidosis – lichen amyloidosis is more frequent on the extensor faces of the limbs, and macular amyloidosis is often interscapular.
- Secondary (AL) amyloidosis is more frequent on periorbital skin or at skin sites that are exposed to tear/physical trauma.
- For mucinosis and gammopathy, the localisation depends on the etiology.
- Myxoedema is frequently pretibial.
- Xanthelasma is periorbital.
- Xanthoma are frequently located over pressure points.
- Calciophylaxis is frequently found in fatty areas of the body (abdomen, flanks, buttocks, thighs, breasts in women).

- Tattoos may be found anywhere.
- Gout deposits predominate on hallux (also called podagra) or fingers (also called tophus).

Classification

No special classification, see other chapters for underlying diseases

Laboratory & other workups

For secondary amyloidosis, blood count, serum electrophoresis and immunofixation, kappa/lambda light chain measurement in blood, eventually bone marrow aspiration are useful to diagnose multiple myeloma. Gammopathy by peripheral gammaglobulins to check.

Myxoedema should lead to measure thyroid hormones.

Xanthoma/xanthelasma should lead to measure serum lipids (triglycerides and cholesterol).

For calciphylaxis, serum calcium, phosphore, albumin, and renal function must be investigated.

Dermatopathology

Dermatopathology is essential in the diagnosis of most depositional disorders. In **amyloidosis** congo red stain shows a green birefringence, frequently located in the vessel walls. Immunohistochemistry for discrimination of cutaneous and systemic amyloidosis. In gout aspirates from the tophus or histology may show cristal depositions. In xanthoma and xanthelasma lipid deposits are visible. In mucinosis and myxoedema mucopolysacharids can be found.

Course

The clinical course is characterized by a slow progression followed by a stabilisation. The treatment remains difficult in most depositional skin disorders.

Complications

These diseases may progress if the underlying disease is not treated.

Diagnosis

The diagnosis is based on the clinical and histological features.

Differential Diagnosis

Depositional disorders can resemble each other.

Prevention & Therapy

The treatment is the treatment of the underlying disease

Special

None.

References

- [Hamie L, Haddad I, Nasser N, Kurban M, Abbas O. \(2021\) Primary Localized Cutaneous Amyloidosis of Keratinocyte Origin: An Update with Emphasis on Atypical Clinical Variants. Am J Clin Dermatol.Sep;22\(5\):667-680.](#)
- [Rongioletti F. \(2022\) New and emerging conditions of acquired cutaneous mucinoses in adults. J Eur Acad Dermatol Venereol. Jul;36\(7\):1016-1024.](#)

8.14 Tropical dermatoses and travel medicine

Grading & Level of Importance: B
A. Gimenez-Arnau Barcelona; RM. Pujol



ICD-11

None.

Synonyms

Tropical skin diseases.

Definition

Tropical skin diseases are all communicable and non-communicable cutaneous diseases that occur principally in tropical and subtropical regions.

Travelers' Tropical Skin Diseases: Skin diseases present in travelers returning from the tropics. Disabling infections that dominate health care in the tropics are known as Neglected Tropical Diseases or NTDs.

World Health Organisation has focused on a strategy of integrating preventive, investigative, curative and supportive care for NTDs.

Epidemiology

Dermatologic and venerologic diseases that are acquired in areas that lie between, and alongside, the Tropic of Cancer and Tropic of Capricorn belts. Not restricted to the tropics. In non-tropical countries, these diseases are diagnosed most often in immigrants and travelers.

In the tropics, up to 50% of the local population is estimated to be affected by a skin disease. Variable incidence and prevalence for each disease. The majority are infections or infestations. Geographic differences in the distribution and intensity.

Skin diseases may affect up to 8% of travelers returning from tropical or subtropical climate regions. Frequently common dermatoses such as eczema, acne, psoriasis or a pre-existing skin infection. A small proportion contract a tropical or exotic skin disease by first exposure.

Climate change and global warming may facilitate tropical diseases and vectors to spread to non-tropical areas.

Aetiology & Pathogenesis

A significant burden caused by different microorganisms, parasites, land and sea animals, and arthropods. Other skin diseases caused by environmental (such as heat, humidity, and altitude), and nutritional conditions. Hot humid conditions, overcrowding, and poverty facilitate reproduction of causal agents and vectors leading to a high frequency and recurrences of skin diseases. Specific and common tropical skin diseases include:

1. Infectious disorders

- Fungal infections: mycetoma, chromoblastomycosis, deep fungal infections, tinea capitis, tineacorporis, tinea imbricata
- Bacterial infections: Staphylococcus aureus, Group A streptococcal infections
- Viral Infections: yellow fever, Zika disease, dengue, chikungunya
- Treponematoses: yaws
- Mycobacterial disorders: leprosy, Buruli ulcer, cutaneous tuberculosis, atypical mycobacterial infections
- Protozoan disorders: leishmaniasis, trypanosomiasis
- Parasitic diseases: schistosomiasis, strongyloidiasis, onchocerciasis, tapeworm, trichuriasis, filariasis, tunguiasis, larva migrans
- STI (Sexually transmitted infections): HIV infection, chancroid, lymphogranuloma venereum,

granuloma inguinale.

2. Non-infectious disorders:

- Insect bite reactions. Arthropods, jellyfish

Major skin NTDs defined by the World Health Organisation are:

- Buruli ulcer
- Cutaneous leishmaniasis
- Post kala-azar dermal leishmaniasis
- Leprosy
- Lymphatic filariasis
- Mycetoma, chromoblastomycosis and other deep fungal infections
- Onchocerciasis
- Scabies and other parasitic infections of the skin
- Yaws (endemic treponematosi)

Symptoms

A wide spectrum of clinical manifestations depending on the etiology. Extremely variable.

Tropical dermatoses may show some distinctive clinical patterns:

- Cutaneous rashes associated with fever
- Itchy rashes
- Migratory rashes
- Nodular lesions
- Muco-cutaneous ulcers
- Persistent edema of the extremities
- Papular eruptions, maculo-plaques
- Eschars

The lesions may cause pruritus, loss of sensation (hypoesthesia or anesthesia, or changes of the skin pigmentation (hypo or hyperpigmentation).

Common dermatoses occurring worldwide may show in tropical countries different clinical presentations (e.g. acne, eczema, tinea, insect bites).

Localisation

Variable. Localized lesions or generalized eruptions. Most of the tropical skin diseases are infectious and the lesions are often located on exposed areas (face and extremities).

Laboratory & other workups

Complete blood cell count. Presence of peripheral blood eosinophilia. Complete biochemical survey. Specific serologies in selected cases. Parasitological studies (blood, smears, skin, and stools).

Dermatopathology

Variable patterns depending on the etiology. An inflammatory granulomatous tissue reaction is frequently observed. Identification (visualization) of the responsible agent. Conventional histology. Specific stains besides HE, i.e. Giemsa, PAS, Fite, specific antibodies.

Course

Variable depending on the etiology.

Complications

Variable depending on the etiology.

Diagnosis

Travel and developed activities, exposure to fresh or sea water, animals, arthropods, plants, history of previous trauma.

Past medical history: immune status of the host, vaccinations, drugs and prophylaxis.

Clinical history: time of onset of skin lesions, evolution, and associated symptoms (itching, pain, fever). Depending on the clinical context: histopathological evaluation (cutaneous biopsy), bacilloscopy (leprosy), microbiological cultures (swabs and/or skin biopsies), parasitological evaluation, specific serologies, microorganisms PCR amplification.

Prevention & Therapy

Preventive measures are required to reduce the risks

Tropical diseases: health improvement in developing countries. Most conditions respond to specific recommended treatments. Variable prognosis: depending on the disease and social context.

Special

Pre-travel counseling. Recommended immunization for specific tropical infections.

Prevention: Proper clothing, shoes, insect repellents, insecticides, barrier measures, bed netting. Avoiding contaminated water or eating raw or undercooked food.

During the trip, travelers should always have a first-aid kit with them and utilize means of protection from insect bites. Early diagnosis and management plan.

References

- [G Monsef, MD, E Caumes. What's New in Travel-Associated Dermatology? , JTravel Med. 2015 ; 22: 221–224.](#)
- [Cunha PR, Flora TB, Kroumpouzos G. Travelers' tropical skin diseases: Challenges and interventions. Dermatol Ther. 2019; 32: e12665.](#)

Chapter 9 – General Dermatology

9.1 Basic Functions of the Skin

9.1.1 Cutaneous Anatomy and Physiology

M. Bagot, Paris; G. Dobos, Paris; A. de Masson, Paris



Anatomy

The skin is the largest organ of the body. It protects against external biological, chemical and physical assaults, and plays a role in thermic and water loss regulation, endocrine function, sensory perceptions and immunosurveillance. The human skin can be divided into three layers; the epidermis, the dermis and the subcutis with fascia.

The uppermost layer of the skin, the epidermis, is an organized, stratified epithelium with appendages (hair follicles, sweat and sebaceous glands) which project deep into the dermis.

The Epidermis is placed on the basal membrane, and is built up by continuously dividing cells, that mature, undergo a special form of apoptosis and migrate towards the exterior. The epidermis can be subdivided into the basal membrane, a germinative pool of keratinocytes in stratum basale (dividing stem cells), stratum spinosum, stratum granulosum and stratum corneum where keratinocytes lose their nucleus and finally desquamate invisible.

The epidermis is a perpetually regenerating tissue, that must maintain a constant number of cells. It is expressing a range of pathogen-associated molecular pattern (PAMP) receptors and cytokine receptors. This maintenance depends on the ability of keratinocytes to undergo terminal differentiation and programmed apoptosis. Stem cells located in the skin are responsible for continual regeneration, wound healing, and differentiation of different cell lineages of the skin.

It forms the barrier layer of the skin, that prevents entrance of toxic and allergic substances and microorganisms, but also prevents the loss of water and electrolytes.

Keratinocytes synthesize keratin, a fibrous intermediate filament arranged in an alpha-helical coil pattern. Bundles of keratin filaments converge and terminate at the plasma membrane forming intercellular attachment plates known as desmosomes. Each epidermis layer has distinct morphologic and biochemical features, suggesting different roles in skin barrier function. Keratinocytes in the basal layer are responsible for the regeneration of the epidermis and are characterized by expression of keratins 5 and 14 (KRT5 and KRT14). KRT1 and KRT10 are more prominently expressed in the spinous

layer. Gap junctions are another type of junction between keratinocytes.

Basal layer (stratum basale) is composed of keratinocytes attaching to the basal membrane with their long axis perpendicular to the dermis. These cells form a single layer. Some of them have the potential to divide and to migrate upstream to the external part of the epidermis.

Squamous cell layer (stratum spinosum) is composed of keratinocytes that become flatter as they move to the surface. They contain lamellar granules, membrane bound organelles containing glycolipids, phospholipids, sterols and acid hydrolases. The name comes from the spine-like aspect of the numerous desmosomes.

Granular layer (stratum granulosum) is composed of flattening cells with keratohyalin in their cytoplasm. Keratohyalin granules are basophilic and irregular. They play an important role for the formation of the interfibrillary matrix that holds keratin filaments together.

Cornified layer (stratum corneum) is composed of corneocytes, large, flat horny cells that have lost their nuclei during terminal differentiation. They are rich in proteins and low in lipids and provide mechanical protection and a barrier for foreign substances and to prevent water loss.

The same layers as in the epidermis can be found in the hair follicle, but these shafts penetrate the deeper dermis. The nails are also skin appendages, and have a similar structure to the hair follicles.

Epidermis also harbours melanocytes, Langerhans cells and Merkel cells.

Melanocytes reside in the basal layer of the epidermis where they form the epidermal melanin units as a result of the relationship between one melanocyte and 30-40 associated keratinocytes. The ratio of melanocytes to keratinocytes is 1: 7-10 in the epidermal basal layer (average melanocyte density is about 1.500 cells/mm²). Recent Research has shown no obvious differences in melanocyte density between the sexes or among people of different colors or races, but the melanocyte density can differ according to age, body part, and UV irradiation.

Melanocytes are dendritic cells that synthesize and secrete the pigment melanin. They are derived from neural crest cells and typically migrate to the *epidermal-dermal* junction during embryonic development, although a few can be *found in the dermis*. Dendritic extensions of the melanocytes are in contact with keratinocytes. *Melanocytes produce melanin in rounded, membrane-bound organelles known as melanosomes, and transfer it to keratinocytes. Darker skin is related to the greater production of melanosomes, their larger size and slower rate of degradation.* According to a recent Nature Communication specific miRNAs associated with exosomes released from keratinocyte modulate human

melanocyte pigmentation by enhancing the expression of proteins associated with melanosome maturation and trafficking. Caveolae in melanocytes are modulated by ultraviolet radiations and keratinocytes-released factors, like miRNAs. Preventing caveolae formation in melanocytes increases melanin pigment synthesis through upregulation of cAMP signaling and decreases cell protrusions, cell-cell contacts, pigment transfer and epidermis pigmentation. Increased ultra violet light exposure induces an increase in melanogenesis and in melanosome transfer to keratinocytes. Melanosomes aggregate above the nucleus and protects genetic information from radiation damage.

Merkel cells are mechanoreceptors attached to basal keratinocytes by desmosomal junctions. They are found in sites of high tactile sensitivity such as digits and lips.

Langerhans cells are dendritic cells deriving from the bone marrow that migrate to a suprabasal position in embryonic development and recirculate throughout life. They represent 3-7% of epidermal cells. Langerhans cells recognize and process antigens encountered in the epidermis. These cells then undergo maturation that stimulates their migration capacities. They can migrate to the local lymphnode to present antigens.

Dermis is located below the epidermis. It is composed mainly of fibroblasts, producing a rich extracellular matrix of proteoglycans, glycosaminoglycans, collagen, elastic fibres, vessels, glands and nerves, adnexal structure associated muscles, dermal dendritic cells, mast cells, Merkel cells, upper and lower vessel pool, apocrine and eccrine glands and different nerve types.

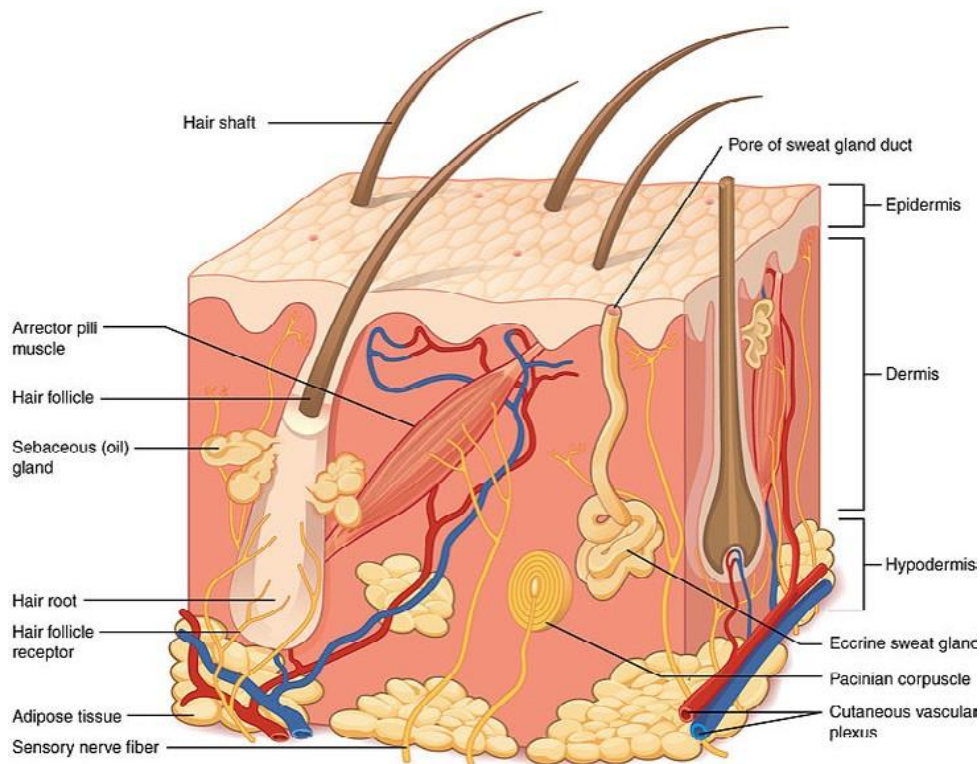
Dermis is composed of two layers, the papillary layer with papillae extending into the epidermis, and below the reticular layer constituted of looser connective tissue.

The subcutis or hypodermis is built up by connective tissue and fat, vessels and immune surveillance cells, and reaches the muscle fascia. It harbors adipose tissue for fat storage and protection.

The human skin has different kinds of glands.

Eccrine sweat glands consist of long curved secretory and excretory tubules and can be found almost everywhere on the body, very densely on the palms and soles.

Apocrine sweat glands are mostly found in the axillae, areola and nipples, perianal region and genitalia. Their orifice is at the uppermost part of the hair follicle canal. Pheromones are released to the surface of the skin. The lactiferous (breast) glands are modified apocrine glands. Sexual hormones influence the function.



Sebaceous glands are an endocrine organ by itself. Smaller sebaceous glands are also associated to the hair follicles with terminal hair and vellus hair follicles. They produce a variety of lipids and by a regulated form of apoptosis they release the sebum to the infundibulum that oils the hair and contribute to the lipid content of the stratum corneum. Androgens and growth factors regulate the glands.

Hair follicle density varies according to the location on the surface of the body. The highest hair follicle density and percentage of follicular orifices on the skin surface are found on the forehead, whereas the highest average size of the follicular orifices is found in the calf region, although the calf region shows the lowest hair follicle density. Every body region shows its own hair follicle characteristics. Terminal hair follicles are at the scalp, beard, axillary and pubic region or trunk and differ according to gender, age, hormone receptors and isoenzyme distribution.

The dermal vasculature is composed of two intercommunicating plexuses: the subpapillary or superficial plexus, at the junction of papillary and reticular dermis, and the lower plexus at the dermal-subcutaneous interface.

Thermal regulation

Skin vasculature plays a key role in the thermal regulation. Glomus cells help to regulate the diameter of the vessels and the communication between these plexuses (Suquet-Hoyer-anastomosis), so that the higher or lower amount of blood can heat or cool down the skin. The eccrine glands produce sweat when stimulated by cholinergic nerves, (stress reaction, temperature down cooling of the skin), which cools the skin physically by evaporation. Even in thinner hair follicles, an anchoring muscle (musculus arrector

pili) can produce some heat by moving the follicle upward.

Physical protection

The subcutis, containing fat tissue can absorb and distribute physical harm.

The dermis, thanks to its dense collagen network, plays an essential role by protecting the skin against tears and shear forces and provides an elastic structure to keep the shape of the skin.

The epidermis, especially the stratum corneum, builds the outermost layer of the skin, providing protection from evaporation of water and physical stress, but also helps to keep the roughness of the skin. The stratum corneum is particularly thicker on the palms and soles, where it is exposed to more physical usage and thinner on the lips or periorbital region.

Protection against chemical injury

The stratum corneum consists of dead cells, “keratinocyte envelopes” that consist mainly of filaggrin, keratin protein and amino acids. Between the keratinocytes, the sebum, a lipophilic material fills the space, similarly to a wall that consists of bricks and mortar. This mixture of hydrophobic and hydrophilic substances helps the skin to resist against various kinds of chemical injuries and water.

This explains also why skin care products containing both lipidic and hydrophilic structures should be used.

Photoprotection

Melanocytes, located on the basal membrane, produce melanin and transfer them in vesicles to the surrounding keratinocytes. The keratinocytes phagocytose these vesicles (granules) and group them around their nucleus. The two kinds of melanin, eumelanin and pheomelanin absorb ultraviolet (UV)-radiation but also visible light and protect thereby the genetic material that may be damaged by UV radiation. Although the melanin production is genetically determined it can be induced by external (UV, light) or internal (hormones, inflammation) stimuli. KC produce ROS absorbers and repair enzymes against DNA damage.

Sensory function

The skin is one of the most important sensory organs. Various kinds of nerves reach up to the upper dermis. Sensing nerves are organized by dermatomes, which can be observed in Herpes zoster infections. Receptors of the skin include nociceptors (pain and itch receptors) or free nerve endings, that are responsible for the sensing of heat, cold, pain, touch, itch and motion. Cutaneous mechanoreceptors include Ruffini's end organ (skin stretch), end-bulbs of Krause (cold), Meissner's corpuscle (changes in

texture, slow vibrations). Pacinian corpuscles are onion-shaped deeper mechanoreceptors responsible for the sensation of vibration. Other types of receptors are thermoreceptors and chemoreceptors. Merkel cells are neuroendocrine cells that interact with the mechanoreceptors in complexes called hair disks.

Immune function (see also respective chapter)

The skin is more than a physical barrier: it is an active immune organ. Immune responses in the skin involve different immune-competent cells and soluble molecules including cytokines. The dermis contains lymphatic and blood vessels and most of the lymphocytes in the skin, other leukocytes, dermal dendritic cells, mast cells, and macrophages. Although the epidermis has no direct access to the blood or lymphatic circulation, it contains immune-competent cells:

Langerhans cells (antigen-presenting cells); keratinocytes (epithelial cells with immune properties), dendritic epidermal T lymphocytes, resident memory T-cells that may serve as a primitive T-cell immune surveillance system; and melanocytes (pigment cells with immune properties). Langerhans cells are able to detect antigens and migrate to the surrounding lymph nodes to present these antigens to T-cells, which activates the T-cells and stimulates their migration to the skin.

The subcutis is a reservoir for immune surveillance cells and for progenitor cells for wound healing. Melanocytes are immunogenic due to the contents of their melanosomes, generating the complex radical scavenging molecule melanin in a process that involves melanogenic enzymes and structural components, including tyrosinase, MART-1, gp100, TRP-2 and TRP-1. These molecules are also targets of the immune response in both vitiligo and melanoma. The immunogenicity of melanosomal proteins can be explained by the dual role of melanosomes, involved both in melanin synthesis and processing of exogenous antigens. Melanocytes are also capable of presenting antigens in the context of MHC class II.

References

- [Sun, Kai-Lv; Liu, Wan; Gao, Xiao-Man; Yang, Min; Chang, Jian-Min*. A Study of Normal Epidermal Melanocyte Distribution. International Journal of Dermatology and Venereology 4\(1\):p 32-35, March 2021. | DOI: 10.1097/JD9.000000000000125](#)
- [Domingues, L., Hurbain, I., Gilles-Marsens, F. et al. Coupling of melanocyte signaling and mechanics by caveolae is required for human skin pigmentation. Nat Commun 11, 2988 \(2020\). <https://doi.org/10.1038/s41467-020-16738-z>](#)
- [Jiang Y, Tsoi LC, Billi AC, Ward NL, Harms PW, Zeng C, Maverakis E, Kahlenberg JM, Gudjonsson JE. Cytokines: the diverse contribution of keratinocytes to immune responses in skin. JCI Insight. 2020 Oct 15;5\(20\):e142067. doi: 10.1172/jci.insight.142067. PMID: 33055429](#)

9.1.2 Biochemistry

C.C. Zouboulis, Dessau



Biochemistry of the epidermis

Keratin intermediate filament (KIF): Keratinocytes contain filaments (8-15 nm) of the KIF family that contribute to the cell cytoskeleton. KIF are constructed by proteins called keratins (K). The different layers of the epidermis contain varying K amounts; ranging from approximately 30% in the stratum basale to 80% in the stratum corneum. KIFs are elongated α -helix-enriched proteins that form dynamic coiled-coils, which are fashioned into filament collections called tonofilaments. The latter are only soluble in denaturants like urea and sodium dodecyl sulfate and reducing reagents like mercaptoethanol and dithiothreitol. Epithelial K are grouped as acidic (type I) and neutral-basic (type II) with sharing sequence homology in each group. Each epithelial cell/tissue type expresses at least one K pair, a type I K together with its preferred type II K partner. The K pair is regulated concomitantly. K5 and K14 are associated with normal cell proliferation and K6 and 16 with hyperproliferation in the epidermis (normally expressed in epithelial cells of the outer root sheath of hair follicles, nail beds and epithelium of oral mucosa), while terminal keratinocyte differentiation (maturation) is associated with expression of K1 and K10 as well as K2 and K11.

Biochemistry of keratinocyte differentiation: Major proteins involved in keratinocyte differentiation include involucrin, which can be extensively cross-linked to other proteins by transglutaminase (TGase). Integrins induce the synthesis of involucrin in keratinocytes, leading to their detachment from the basement membrane and interruption of proliferation. The transition of keratinocytes from the stratum spinosum to stratum granulosum is mediated by protein kinase C via suppression of K1 and K10 gene expression and the associated induction of the late differentiation markers loricrin and profilaggrin. Stratum granulosum keratinocytes contain protein- and lipid-rich granules. These structures (former known as keratohyalin granules) are irregularly shaped profilaggrin-containing granules that coalesce in the stratum granulosum and thereafter disperse in the stratum corneum upon dephosphorylation and subsequent maturation via proteolysis to filaggrin. These granules are lipid-rich lamellar structures (Odland granules), exist as lipid bilayers and fuse with the cell membranes to contribute lipids to the extracellular space of the stratum corneum. The lipids form the sheets of the lipid epidermal permeability barrier (EPB).

EPB function in human epidermis depends on TGase-mediated cross-linking of structural proteins and lipids during the terminal stages of keratinocyte differentiation. Several mutations in genes that encode for the EPB structural components and its enzymes and lipid processing can result in skin disease. Associated pathologies result from relevant mutations, such as in SPINK5 serine proteinase inhibitor (Netherton syndrome) and cathepsin C (Papillon-Lefevre syndrome).

EPB quality also depends on the presence of epidermal lipids, such as ceramides, cholesterol and free fatty acids. Ceramides account for approximately 50% of stratum corneum lipids followed by cholesterol and free fatty acids. Changes in the concentration of any of these can affect EPB quality. Aged and photo-aged skin exhibit a cholesterol-dominant barrier, atopic dermatitis with ceramide-dominance and psoriasis with a dominance of free fatty acids. EPB repair may be initiated by loss of Ca^{2+} and K^{+} , which are important regulators of barrier function, during water influx in the damaged epidermis. These ions synergistically inhibit barrier repair via blocking the return of lipids to the stratum corneum. There is a 4-fold increase in extracellular Ca^{2+} from basal layer to the stratum corneum. An acid pH maintains EPB homeostasis by providing optimal pH for the enzymes involved in extracellular processing bilayer lipids. Topical application of solvents to the skin removes lipids from the stratum corneum and increases trans-epidermal water loss (TEWL), followed by induction of a rapid barrier repair through epidermal metabolic changes. The lipid-rich cornified envelope (CE) that surrounds individual corneocytes is organized into lipid-rich lamellar bilayers. Aqueous pores interrupt the hydrophobic nature of this lipid-rich matrix representing potential routes of topical entry for water-soluble therapeutic compounds.

Skin fatty acids: The permeability of human skin is largely based on the quality and quantity of the lamellar lipids packed between corneocytes. Endogenously-produced fatty acids can be found in epidermal cell membranes and in the lipids located between corneocyte layers, which construct the hydro-lipid film at the skin surface. Fatty acids are involved in the end stages of epidermal cell life, participate in signaling events during keratinocyte proliferation and differentiation deep in the epidermis and even dermis, and are implicated in the skin immune response.

Modification of skin fatty acids can lead to disease. Atopic dermatitis is associated with abnormally reduced $\omega 6$ fatty acids, decreased ceramide content and increased TEWL. UV irradiation of skin can lead to increased casual skin surface lipid (CSL) levels leading to improved EPB performance. In contrast, photo-aged and intrinsically aged epidermis exhibit abnormal EPB homeostasis, CSL reduction and a dramatic fall of cholesterol synthesis.

Epidermal fatty acids can also derive from the diet. The skin is an active metabolizer of polyunsaturated fatty acids (PUFA). PUFA-deficient diets (e.g. linoleic acid) can result in both increased TEWL and scaly skin. Arachidonic acid, a 20-carbon PUFA, can be metabolized by the cyclooxygenase or lipoxygenase pathways in the skin producing prostaglandins and hydroxyeicosatetraenoic acids, which interact with signaling systems in the proliferating and differentiating epidermal cells.

Skin absorption of xenobiotics: Xenobiotics are foreign to the biological system chemical substances (natural compounds, drugs, environmental agents), which can be transported across the stratum corneum. The skin is constantly exposed to xenobiotics through occupational, environmental, therapeutic and systemic exposures. Human epidermis and sebaceous glands express cytochrome P450 (CYP) enzymes (capable of metabolizing drugs and chemicals), some of which are specific to skin

epithelial cells. Especially relevant to skin is the role of CYPs in mediating photosensitivity, and reactions to drugs, such as sulfonamides, tetracyclines, retinoids. The observed pharmacogenetic polymorphisms in members of the CYP family explain inter-individual responses to drug therapy and determine individual absorption, disposition, metabolism, and excretion of xenobiotics.

Keratinocyte differentiation can be modulated by hormones and vitamins (retinoic acid, vitamin A/retinol from diet), vitamin D₃, thyroid hormone and steroid hormones. These act as ligands of cell receptors localized in cell nuclei (nuclear receptors). Nuclear receptors influence the expression of multiple genes involved in cell differentiation. The skin has nuclear receptors for several steroid hormones, including glucocorticoids, estrogen, androgen and progesterone, and can produce active sex steroids through metabolism of adrenal C₁₉ precursor steroids.

Defensins and other antimicrobial peptides are produced by keratinocytes of inflamed epidermis following proinflammatory cytokine release (IL-1) or bacterial infection.

Biochemistry of the dermis

The main cell type of the dermis is the fibroblast that produces and degrades extracellular matrix (ECM) components. Several other cell types are hosted in the dermis, including multi-functional cells of the immune system (macrophages and mast cells), whereas mast cells can trigger allergic reactions by secreting bioactive mediators such as histamine.

Dermal functionality is mediated through the ECM, which is a highly complex mixture of bioactive macromolecules produced by dermal cells and then either secreted intact or alternatively assembled later outside the cells. Collagens are the principal ECM component; other members include elastin, fibrillins, latent TGF- β -binding proteins, fibulins, laminins, proteoglycans, integrins, and the enzymes involved in their processing. ECM mutations can result in a broad range of human disorders.

Collagen: About 90% of total dermal protein consists of the collagen macromolecule, accounting for about 75% of skin total dry weight. At least 25 collagens exist, half are present in skin; consisting predominantly of collagen type I (85-90%), III (8-11%), and V (2-4%). Collagen type VII forms part of the so-called anchoring fibrils that attach the basement membrane to the ECM of the upper dermis. Collagen type XVII contributes to the so-called anchoring filaments that link the basal keratinocytes with the basement membrane. Collagen provides tissue integrity and facilitates tissue morphogenesis and platelet aggregation. Most skin collagens are dermal cell-derived but endothelial cells of dermal blood vessels also produce epidermal collagens.

Collagens share a 3 α -polypeptide (homotrimers or heterotrimers) chain format folded into a **collagen triple helix**. Every third amino acid in the chain is a glycine and the other two positions are over-represented by prolines or hydroxyprolines, with hydrogen bonding between hydroxyl groups on

adjacent chains contributing to helix stability. Collagen biosynthesis involves the synthesis of **procollagen polypeptides** followed by both their intracellular and extracellular processing to generate a mature and functional collagen fibre. Procollagen molecules are aggregated into granules for secretion purposes from the cells. A battery of enzymes is involved in collagen biosynthesis and these require a diverse range of cofactors including O₂, Fe²⁺ and ascorbate. Certain genetic syndromes are due to lacking cleavage at either or both procollagen polypeptide ends.

Elasticity of skin: The other major ECM fibrous protein is elastin, which provides the skin with its elasticity. Elastin is stretchable by more than its full resting length. There are three different classes of elastin fibers: Oxytalan fibers, elaunin fibers and elastic fibers. The elasticity of the fibers derive from the amorphous portion, which contains the highly cross-linked protein called elastin. Elastin molecules form cross-links that confer both elasticity and insolubility to them. The microfibrillar part of the elastic fiber is composed of fibrillin-1.

Extracellular matrix: Extracellular matrix, the dermal material lying outside the cells, not consisting of either collagen or elastic fibers, is an amorphous and hydroscopic material consisting of proteoglycans, glycoproteins, water and hyaluronic acid. Proteoglycans are formed by the binding of negatively charged, water/ion-binding and sulfated/ acetylated polysaccharides called glycosaminoglycans (GAGs) to a protein. Hyaluronic acid is protein-free GAG.

Biochemistry of Adnexal Structures

Eccrine sweat glands: They produce a watery perspiration that serves principally to cool and maintain the body core temperature at 37.5°C. At maximal output the eccrine glands of an adult human can excrete up to 3 litres sweat per hour. Osmotic force appears enough to move the sweat up to the skin surface. Eccrine gland activity is regulated via neural stimulation using sympathetic nerve fibres distributed around the gland. These use the neurotransmitter acetylcholine. Sweat is a clear, odour-free, colorless, slightly acidic fluid that is almost fully water (99.0-99.5%) with the remainder consisting of the electrolytes NaCl, K⁺ and HCO₃⁻, as well as lactate, urea, ammonia, calcium, heavy metals. There are significant regional variations in the composition of sweat. The composition of sweat can be modulated by psycho-emotional and environmental factors. The sweat gland is also known to concentrate xenobiotics. Organophosphorus compounds (in insecticides and chemical warfare agents) can induce eccrine gland sweating. Raised NaCl levels in sweat are a reliable diagnostic feature of cystic fibrosis.

Sweat forms initially as an isotonic primary fluid in the secretory tubule that then passes through the duct for NaCl resorption, to yield a final hypotonic sweat. The steroid aldosterone is thought to regulate the reabsorption of Na⁺, as sweating is increased in Addison disease where aldosterone is reduced.

Apocrine sweat glands: They secrete their sterile, odour-free, weakly acidic product via exocytosis from secretory cells. Its viscous, milky consistency is due to its high content of lipids (fatty acids, cholesterol, squalene, triglycerides), androgens, ammonia, sugars, Fe²⁺. Some of these are odoriferous, especially so after their decomposition on the skin surface by bacteria. Human apocrine glands are not responsive to heat, although psycho-emotional stimuli are implicated in stimulating secretory activity.

Sebaceous glands: Their product, sebum, is released after sebocytes active DNA degradation burst and die (holocrine secretion) due to programmed cell death. There is a remarkable variation in the composition of sebum through human life and human sebum is unique, with no similarity to other species. Human sebaceous glands not only produce sebum but also regulate steroidogenesis, local androgen synthesis, skin barrier function, interaction with neuropeptides, potential production of both anti- and pro-inflammatory compounds and synthesis of anti-microbial lipids (sapienic acid, oleic acid).

The sebaceous gland contains all enzymes needed for transformation of cholesterol to steroids. Moreover, it expresses 5 α -reductase isoenzymes, needed for the intracellular conversion of testosterone, or even the adrenal androgen dehydroepiandrosterone directly, to the more potent 5 α -dihydrotestosterone. Sebaceous glands are part of the skin neuroendocrine system as they produce and release corticotropin-releasing hormone in response to systemic or local stress. Exogenous glutamine is required for sebocyte division and lipogenesis, though it can be replaced by spermidine.

Sebum is a yellowish viscous fluid containing lipids, such as triglycerides, free sterols and sterol esters, squalene, wax and free fatty acids, and cell debris. Sebaceous glands can synthesize considerable amounts of free fatty acids. Approximately half of the fatty acids in sebum are monosaturated with some unusually positioned double bonds ($\Delta 6$ unsaturation) unique to humans. Sebum is the only body secretion with a high squalene content, a lipid that cannot be crystalized. The composition of sebaceous gland lipids, including the relative proportions of different types of branched-chain fatty acids, is under both genetic and hormonal control and while significant inter-individual and inter-ethnic differences in sebum production exist, a common secretion rate of 0.3 mg sebum/10 cm³/h is detected.

Hair follicle: Hair fiber growth occurs in a highly time-resolved manner. Glucose (and glutamine) is the principal energy source. The hair follicle can react to most hormones of the human body and produces for itself a wide range of hormones, such as sex steroid hormones, proopiomelanocortin peptides, corticotropin-releasing hormone, prolactin. Neuropeptides, neurotransmitters and neurohormones are implicated in mediating hair follicle events particularly those related to stress. The observation that men castrated before puberty do not go bald nor grow beards, but they do so after treatment with testosterone, indicated a major role of androgens in hair growth. However, hair follicles in different regions of the body respond differently to different androgens. Drug-induced inhibition of the testosterone-metabolizing enzyme to 5 α -dihydrotestosterone, 5 α -reductase type II, induces hair regrowth in some balding men.

The hair fiber includes “hard” K, water, lipids, pigment, and trace elements (in order of decreasing amount). The biosynthesis of hair proteins begins in the bulb of the growing (anagen) hair follicle and it ceases approximately 500 µm above the zone of maximal keratinocyte proliferation in scalp terminal hair follicles. Neither the chemical composition of hair proteins nor its amino acid composition shows any difference across the ethnicities.

The “hard” K of the hair can be distinguished from epidermal “soft” K by their lack of extended glycine runs. “Hard” hair K contain many cysteine residues. Moreover, the dynamics of KIF assembly in epidermis and hair fibers are very different. Whereas these filaments disassemble during epidermal keratinocyte division, they are the product of non-viable K-producing cortical keratinocytes in the hair follicle. Abundant cysteine residues of the hair K are extensively cross-linked by disulfide bonds facilitated by more than 20 different K-associated proteins.

Hair fibers have a coating of long-chain fatty acids bonded covalently to the protein membrane of the epicuticle. Hair lipids contain a large amount (58%) of a hair-specific methyl-branched saturated 21-carbon fatty acid (18-methyl-eicosanoic acid) and provide a hydrophobic interface protecting the hair cortex from a hostile wet/dry environment. In humans the major fatty acids in hair fiber lipids include 16:0 (17%), 18:0 (10%), 18:1 (5%) 21:0 (48%). Hair fiber lipids are highly conserved, in marked contrast to the high inter-species variability in sebaceous gland lipids.

Nails: Corneocytes of the nail plate (onychocytes) are also filled with K filaments. Low-sulfur K form filaments running parallel to the nail surface and these are embedded in a non-K matrix material of high sulfur, high glycine, high tyrosine proteins. Up to 90% of nail K are of the hard “hair” K type. Water, lipids and trace elements including iron, zinc, and calcium are present in the nail plate. Overall, the nail contains much less lipid and water than the epidermis and becomes brittle at less than 7% water and soft at more than 30%. The nail low lipid content contributes to their 1.000-fold greater water permeability than the epidermis.

Skin endocrinology

Vitamin D production: Vitamin D₃ (cholecalciferol) belongs to the group of fat-soluble secosteroids, which has an important impact in the intestinal absorption of calcium, magnesium, and phosphate. Besides oral ingestion it is photochemically in the epidermis through UVB radiation. Through radiation with UVB (290-315 nm) (sun exposure to face, arms and legs for 30 minutes twice per week, or approximately 25% Minimal Erythema Dose (MED)), 7-dehydrocholesterol is photochemically transformed into cholecalciferol (vitamin D₃).

Steroidogenesis and neurohormones: Skin and its appendages respond to central hormone regulation but also act as an endocrine organ in a manner largely independent of body central control systems. The

skin occupies a strategic location between the external and internal environments and so it can contribute to preserving body homeostasis. In addition, the cutaneous neuroendocrine system provides a capacity for stress sensing, been an equivalent of the central hypothalamic–pituitary–adrenal axis. The latter principal constituent activities include the production of corticotropin-releasing hormone and downstream proopiomelanocortin peptides, including endorphins and steroidogenesis (synthesis, metabolism and targeting of androgens and estrogens).

Pigmentation of skin and hair follicle: Despite the variations in skin and hair color, skin and hair pigmentation is derived from the pigment melanin, synthesized via a phylogenetically ancient biochemical process termed melanogenesis. Synthesis occurs within melanosomes, which are specialized organelles unique to highly dendritic, neural crest-derived, cells called melanocytes. Follicular melanocytes are derived from epidermal melanocytes during hair follicle development. Activity of the hair bulb melanocytes only occurs during the anagen phase of the hair growth cycle, that of epidermal melanogenesis is continuous.

Melanogenesis starts by the formation of the melanosome in which melanogenesis occurs and continues through the biochemical pathway that converts L-tyrosine into melanin. Both processes are under complex genetic control. Eumelanogenesis (brown-black melanin production) is critically dependent on the velocity of the tyrosinase reaction. For pheomelanogenesis (red/yellow melanin production), cysteinyl-DOPA is oxidized in multiple complex steps that may involve tyrosinase-dependent or independent reactions as well as glutathione reductase and peroxidase activities, in order to form pheomelanin. Mixed melanins (containing both eumelanin and pheomelanins) and neuromelanin are additional melanin types.

Both eu- and pheomelanin can be produced within the same melanocyte. Pheomelanins are photolabile with photolysis products including superoxide, hydroxyl radicals and hydrogen peroxide.

The biosynthesis of melanins is based on the conversion of the amino acid L-tyrosine (additionally via L-phenylalanine) into a complex and heterogeneous group of compounds. This reaction follows three steps:

a) hydroxylation of L-phenylalanine/L-tyrosine to L-dihydroxy-phenylalanine (L-DOPA), b) The dehydrogenation/oxidation of L-DOPA to dopaquinone, which is the precursor for both eu/ pheomelanins and the limiting step in melanogenesis. c) The dehydrogenation of dihydroxyindole to yield melanin pigment. Both eumelanogenesis and pheomelanogenesis require the oxidation of DOPA to dopaquinone. Thereafter, the conversion of dopaquinone to leuko-dopachrome signals eumelanin production, while the addition of cysteine to dopaquinone to yield cysteinyl-DOPA occurs in pheomelanin production. For eumelanogenesis (brown/black), L-DOPA needs to be oxidized by tyrosinase to L-dopaquinone and again by tyrosinase from dihydroxyindole to indole-5,6-quinone.

Despite the broad association of eumelanin with brown/black hair and pheomelanins with red/blonde hair, relatively minor differences in melanin content can have significant effects on visible hair color. Melanin in hair is tightly bound to the keratin and its isolation requires degradation of keratin by strong chemicals (NaOH, HCl).

Eumelanins are polymorphous nitrogenous biopolymers (mostly co-polymers of dihydroxyindole and dihydroxyindole carboxylic acid). They are insoluble in most solvents and are tightly associated with proteins through covalent bonds. Eumelanins exhibit unique stable paramagnetic states. Unlike eumelanin, pheomelanins are photo-labile with photolysis products including superoxide, hydroxyl radicals and hydrogen peroxide.

9.1.3 Cutaneous Immunology

E. Gaffal, Magdeburg



In addition to being a physical barrier that protects the body against external insults, the skin also forms an immunological barrier which is crucial for host defense as well as tissue homeostasis. The cutaneous immune system contains a network of immune cells of the innate and adaptive immune system. Besides skin-resident immune cells there is also a constant circulation of immune cells between the skin, lymph nodes and blood stream. It is also referred to as skin associated lymphoid tissue (SALT).

Innate immune cells of the skin

Several cells in the skin are part of the innate (unspecific, native) immune system.

Keratinocytes

Keratinocytes are the prominent cell type of the epidermis. They form the outermost barrier against potential infection. Damage to the skin leads to the secretion of numerous cytokines and chemokines (e.g., TNF, IL1, CXCL2, CXCL10) by keratinocytes which activate local immune cells and endothelial cells, initiate antigen-specific immune responses, and recruit various immune cells into the skin including T-cells and Natural killer cells. In addition, keratinocytes secrete antimicrobial peptides (AMPs), such as beta-defensins and cathelicidin, which prevent the invasion of microbes by direct killing of pathogens, and activation of the innate immune system. Keratinocytes recognize invading viruses, parasites, bacteria, and fungi in the skin through Toll-like (TLR) and nucleotide-binding oligomerization domain-(NOD)-like receptors.

Perturbations in the physical and immunological functions of keratinocytes are e.g., of major importance for the development of allergic inflammatory responses in the skin.

Epidermal and dermal dendritic cells

Epidermal dendritic cells (Langerhans cells) are important to maintain tissue homeostasis and immune tolerance. In the case of an insult, they can sense microbial antigens via Toll-like receptors. Langerhans cells process and present antigens to naïve T-cells thereby inducing an antigen-specific immune response. Dermal dendritic cells are professional antigen-presenting cells (APC, plasmacytoid and myeloid subtypes) that are also crucial for the induction of adaptive immune responses. For example, in contact allergy, they take up haptenized proteins (allergen) and migrate to the draining lymph nodes. Here, they present the allergen to antigen-specific naïve CD8⁺ and CD4⁺ T-lymphocytes which then get activated and differentiate toward Th1/Th17 phenotypes (see below). Repeated exposure to the allergen then induces the recruitment of allergen-specific T lymphocytes in the skin.

Mast cells

Mast cells are mostly located in the dermis and around vessels and adnexal structures. They are of major importance for the induction and regulation of immune responses against various allergens as well as bacterial and parasitic infections. Additionally, they are involved in wound healing and angiogenesis. Mast cells express a variety of receptors on their surface including e.g., FcεRI receptors for binding of IgE, Toll-like receptors, IL-4 and IL-5 receptors. Upon stimulation they release a plethora of immune-activating mediators including histamine, heparin and serine proteases like tryptase and chymase. Other mediators are serotonin, lipid mediators (leukotriene C₄, prostaglandin D₂), cytokines (TNFα, IL-4, stem cell factor) and reactive oxygen species. Consequences of mast cell activation are e.g., pruritic wheals, vasodilatation, and edema. Mast cells are the major cells in driving allergic disease or anaphylaxis.

Macrophages

Macrophages are the most abundant cell type of skin resident immune cells. They maintain and restore homeostasis of the skin by eliminating invading pathogens (phagocytosis), sometimes resulting in granuloma formation with multinucleated giant cells (sarcoidosis, foreign body granuloma, rheumatism, erythema nodosum). Activated macrophages present antigens to naïve T-cells and release cytokines (TNFα, IL1β, IL-6) which further drive inflammation and attract neutrophils to the site of insult. Macrophages are involved in many other diseases including atherosclerosis, inflammatory bowel disease or cancer.

Eosinophils and neutrophils

Upon the release of inflammatory cytokines and chemokines from e.g., keratinocytes or macrophages, neutrophils and eosinophils are recruited to the site of inflammation. Neutrophils release NETs

(Neutrophil Extracellular Traps) to immobilize pathogens and directly phagocyte invading microorganisms (NETosis). They also release chemoattractants to recruit more neutrophils into the skin.

Eosinophils are of major importance in the defense against parasites. Eosinophilia of the skin also is a typical feature of atopic dermatitis. Besides pro-inflammatory mediators they are also attracted to immunoglobulins such as IgE. Upon stimulation eosinophils release a wide range of immunomodulatory factors including more than 35 cytokines, growth factors, and chemokines and cytotoxic granules. For example, reactive oxygen species, lipid mediators (leukotrienes, prostaglandins), growth factors (TGF β , vascular endothelial growth factor (VEGF), platelet derived growth factor (PDGF), cytokines (IL-1, IL-2, IL-4, IL-5, IL-6, IL-8) and TNF α . Thereby they kill parasites and promote Th2 helper T cell differentiation. Like mast cells, eosinophils are important mediators of allergic disease, asthma, and parasitic infections. Eosinophils are also recruited in skin cancer and have been identified as a prognostic marker in immunotherapy of melanoma and contribute to anti-tumor host defense.

Immune cell compartment of the subcutaneous adipose tissue

Besides being a mechanical barrier, the subcutaneous white adipose tissue (SWAT) also acts as an immunological barrier. It contains mainly macrophages and T lymphocytes which help to secure tissue homeostasis and integrity.

Adaptive immune cells

The adaptive immune response takes longer to develop, and it is highly specific to particular pathogens. It includes both cell-mediated and humoral immunity.

T-cells originate from bone-marrow derived hematopoietic stem cells which differentiate into multipotent progenitors. In the process of differentiation developing T-cells migrate to the thymus gland to mature. Here, the precursor cells mature into several distinct types of T cells with different functions in the initiation and regulation of immune responses (see below).

CD8+ and CD4+ T-cells

Cell-mediated immunity is mediated by T cells. Antigen-presenting cells like dendritic cells or macrophages present foreign peptides to naïve T-cells which then differentiate into cytotoxic CD8+ T-cells or CD4+ T helper (Th) cells. These then antigen-specific T-cells migrate into the skin to the site of inflammation. For example, allergic contact dermatitis.

- Cytotoxic CD8+ T-cells are of major importance in attacking virally infected cells or cancer cells.
- CD4+ T helper cells are central for activating B cells thereby inducing humoral immunity. T helper

cells can be subdivided in Th1, Th2, Th17 and Th22 cells, with every subtype having a specific cytokine profile and different role in skin immunity.

1. Th1 cells produce IFN- γ , activate e.g., macrophages and induce cell-mediated immune response to kill intracellular pathogens. They play a role in the course of psoriasis.
2. Th2 cells produce e.g., IL-4, IL-5, IL-6 or IL-10, and activate B cells as well as eosinophils. They play a role in atopic eczema.
3. Th17 cells produce IL-17 and IL-22. They regulate bacterial and fungal infections.
4. Th22 cells secrete pro-inflammatory mediators like IL-22 and TNF α . Th17 and Th22 cells are important in the pathogenesis of psoriasis.

Regulatory T-cells

Regulatory T-cells (Tregs) are one of the largest immune cell subsets in skin. They play a critical role in regulating the inflammatory immune response, prevent autoimmunity and support local tissue repair.

Memory T-cells

Memory T-cells (TRM) circulate between skin and blood stream or reside in the skin (tissue resident TRM). They are important for mediating a long-lasting protective immunity. See also chapter drug reactions, herpes induced erythema multiforme.

B-cells

Like T-cells, B cells originate from bone-marrow derived hematopoietic stem cells. B lymphocytes migrate into the spleen and lymph nodes where they become activated by e.g., antigen contact. B lymphocytes are central for humoral immunity. Upon activation through cytokines and stimulatory signals from T- cells they produce immunoglobulins that can bind to specific antigens. B-cells also present antigens and produce pro- and anti-inflammatory cytokines themselves.

9.1.4 Cutaneous Microbiology

H. Gollnick, Magdeburg



Definition

Microbes of the skin belong to the microbial ecosystem of the body.

The terms microbiom and microbiota are used interchangeably, however, there are differences:

Cutaneous microbiota: all different micro-organisms as a population living on the skin. Refers to the taxonomy. Subcategories i.e. arm pit, feet, groin, nose etc.

Cutaneous microbiome: all micro-organisms and their genetic material on the skin. Refers to the bacteria first and their genes secondary.

Metagenome: these are the genes of cutaneous microbes in a specific environment. Refers to collective functions of microbial genes.

Metatranscriptome: transcriptomes induced by microbiota.

Development

The cutaneous microbiome encompasses the microbes that live in and on the skin, including bacteria, fungi and viruses. Archeae and mites (acari group) do not play primarily a significant role. Like many aspects in the development of infant physiology, the cutaneous microbiome is dynamic, continuously evolving and diversifying with age, environment (height, latitude, temperature, clothes, skin moisture, pH, sebum), personal hygiene, different forms of stress, nutritional status, culture, exposure to skin irritating or protecting agents, UV- light, antibiotics and/or genetic and epigenetic factors (barrier function, innate and adaptive immune system).

At time of delivery, the neonatal skin is ad hoc exposed to a new environment outside the uterus with a microbe rich world.

The mode of delivery determines the newborn's cutaneous microbiome composition. Bacteria on the skin of newborns delivered vaginally are similar to their mothers' vaginal flora, containing predominantly Lactobacilla. The skin of newborns delivered via cesarean section is colonized by bacteria most similar to those on their mothers' skin, in particular *Staphylococci*, *Streptococci*, *Corynebacteria* and *Cutibacteria*. In contrast to the microbiome of adults, the early skin microbiome does not differ significantly in composition based on anatomic location.

[\(figure 1\)](#)

Between the 3rd week up to the 3rd month of life, infants begin to develop the anatomic site-specific bacterial profiles similar to adults. Colonization takes place in interfollicular, intrafollicular and acrosyringal areas. Around the 6th week of life, infant skin and nares become colonized by *Staphylococcus* and *Corynebacterium* quite similar to adults but still differs significantly from the adult skin microbiome until late adolescence. *Malassezia* colonization increases with age, becoming adult-like by 1 month of life. The strain sequence identity of *Malassezia* colonizing neonates and their mothers

are very similar, suggesting transmission from mother to infant. During the time of infancy, Firmicutes (specifically genera *Staphylococcus* and *Streptococcus*) are the predominant bacteria on the skin, followed by bacteria from the phyla Actinobacteria, Proteobacteria, and Bacteroidetes. In adults, Actinobacteria, Firmicutes, Proteobacteria, and Bacteroidetes are the predominant phyla, and *Corynebacterium*, Cutibacteria, and *Streptococcus* and *Staphylococcus* are the predominant genera.

Microbiome and Microbiota

An average healthy human body possesses 10^{14} microorganisms – 10-fold the number of human cells.

A single square centimetre of the human skin can contain up to one billion microorganisms. These diverse communities of bacteria, fungi, mites and viruses can provide protection against disease, but can also exacerbate skin lesions, promote disease and delay wound healing. Microbial diversity is the degree of heterogeneity, the more the healthier for the host.

It is now known that according to localisation and temporal diversity of a healthy, adult skin microbiome from 20 different skin sites 19 bacterial phyla were detected, but the most prominent sequences were assigned to four phyla: Actinobacteria (52%), Firmicutes (24%), Proteobacteria (17%), and Bacteroidetes (7%). Within these phyla Cutibacteria and Staphylococci species dominate sebaceous areas (glabella, alar area, external auditory canal, neck, sternum and back). In moist sites, Corynebacteria species predominate (nare, axilla, antecubital and popliteal fossa, interdigital spaces, inguinal and gluteal creases and umbilicus). Staphylococcal species were also identified here. In dry skin sites, such as the volar forearm, hypothenar, palms and buttocks, a mixed population of bacteria resides ([figure 2](#)).

Immunology

Depending on commensal or pathogenic microbes living on the skin, the local and systemic immune response is different. Whereas commensal microbes live in homeostatic balance with the host, a disruption occurs when pathogenic microbes come to the scene or those are overgrowing normally suppressed by the host cells (epidermal and dermal compartments) or commensal microbe defense mechanisms.

Therefore, an important challenge faced by the host's skin immune system is to distinguish between beneficial and pathogenic microbes, which can share very similar molecular patterns that are first recognized by the innate immune system (such as lipopolysaccharide, peptidoglycans, lipoproteins and flagellin). Discrimination between acquired microbes during delivery and infancy may be a feature of the developing adaptive immune system, which can recognize discrete molecular sequences, and, depending on the development of the immune system respond with both pro- and anti-inflammatory mediators and activation of cells depending on the nature of the antigen. For example, *S. epidermidis* induces AMPs such as beta defensins 2 and 3 enhancing the host response to *S. aureus*, activates mast

cell-mediated antiviral reactions, can suppress inflammatory reactions during wound healing, and stimulates resident cutaneous T-cells for maturation. Stress can modulate the composition of the microbiome in general. On the skin, the function of Staph. epidermidis is disturbed and can in turn influence the Staph.aureus nasal colonization and can reduce the lipoteichoic acid production by Staph. epidermidis which in turn influences via miR 143 TLR-2 production and growth of C.acnes. An infection by intracellular pathogens initiates the development of T helper 1 (TH1) cells, whereas extra cellular pathogens induce the differentiation of TH2 and TH17 subsets (atopic dermatitis, acne). These are proinflammatory cells which coordinate many aspects of the innate and adaptive immune response to clear microbial invaders.

At the beginning of life, in the late in utero status and after delivery, the vernix caseosa is a key player in the development of early cutaneous innate immunity. It contains LL-37 and lysozyme, two antimicrobial substances that work synergistically, as well as lactoferrin, alpha-defensins, and other antimicrobial peptides. Vernix appears to selectively inhibit some bacteria (Klebsiella, Bacillus megaterium, Listeria monocytogenes, Group B Streptococcus, and Candida albicans), but not Pseudomonas aeruginosa, coagulase-negative Staphylococcus, or Serratia marcescens. This selective inhibition may be mediated, in part, by the role of vernix in the development of the acid mantle.

Risk for Diseases

First of all, the understanding of the differences in the microbiome in healthy children and in healthy adolescents as well as in adults and in the aged population is necessary for changes that occur in a disease. The unique structure of the skin of newborns is influenced by and influences itself cutaneous microbial colonization vice versa (skin barrier function and genetic failures of skin structures, vaginal or cesarean delivery) and a possible settlement by non-commensal microbes. A dysbiosis occurs when the skin microbiome is altered from the status of a normal “healthy” microbiome. Dysbiosis is present in many changes of the skin physiology (overwashing, humidity, clothes, antimicrobials) leading to pathologies including for example erythema toxicum neonatorum, superficial folliculitis, body or feet odor, atopic dermatitis, and acne.

Spectrum of primary and secondary skin diseases with change of microbiota(Examples)

In general, we differentiate primary infections of the skin, skin diseases which become secondary superinfected (impetiginized) and skin diseases in which changes of the microbiota drive in addition the course of the individual disease.

([figure 3](#) and [4](#))

Erythema toxicum neonatorum

It is seen early in life in neonates with macular erythema, papules and pustules, mostly self-limited. It is almost always localized at hair follicle bearing skin (in newborns higher density than in adults) and most

probably related to coccal microbes entering the opening of the follicle. A strong eosinophilic infiltrate is seen by histology but no evidence for allergic reactions are given. A reaction of the adaptive immune system in an early development stage is discussed.

Superficial and Deep Folliculitis

In both situations an overgrowth of staphylococcal species takes place in the follicular acro – and infrainfundibulum showing superficial pustules, infiltrated lesions with papules and finally abscesses leading to furuncle or carbuncle if not appropriately treated in time. All of these are primary infections of the skin. Primary skin infections may have acute (streptococcal erysipelas) or delayed onset (borreliosis, tuberculosis) (see chapter 2.2.4 Folliculitis).

Impetigo contagiosa

Two types of impetigo are differentiated, the staphylococcal and the streptococcal types. Impetigo staphylogenes is located at the intrafollicular epidermis and bacteria settle in and on the Stratum corneum. Impetigo streptogenes is located at the interfollicular epidermis. Both are mostly seen in the first life decade, in particular in small children who often touch lesions and transfer the bacteria to other parts of the face and body. Impetigo is highly contagious, as its name implies. Topical disinfectants and antimicrobials are preferred as topical treatment in contrast to topical antibiotics. Evaluation of smears from the nares for resistant strains is recommended (see chapter 2.2.2 Impetigo contagiosa).

Pityriasis versicolor

Superficial infection with *Malassezia furfur* species is common and shows multiple asymptomatic scaly macules and patches, presenting in color from white to tanned to brown to pink skin. A follicular variant is *M. furfur* folliculitis on the trunk and Pityriasis folliculitis of the scalp. Seborrhoeic dermatitis is related to *M. furfur* superinfection, which is an important trigger. Fourteen different species are recognized of which *M. furfur*, *M. globosa* and *M. sympodialis* are the clinically important ones. The yeast *M. furfur* is almost found in about >80% of adults as a commensal without pathologic manifestation. However, conditions with warm and humid environments, clothes with low air circulation and increased sweating, immunosuppression, malnutrition, pregnancy, or Cushing disease are trigger factors. Scratching of lesions material on a glass slide and staining with methylene blue or Wood light examination help to diagnose the presence and amount of the yeast. Topical treatment includes selenium sulfide, zinc-pyrithione, ciclopirox olamine, azole and allylamine antifungals. In relapsing and widespread cases, oral treatment is preferred (see chapter 2.3.3 Pityriasis versicolor).

Atopic Dermatitis

Barrier dysfunction (reduced very-long chain epidermal lipids, filaggrin dysfunction), inflammation and microbes (itch-scratch cycle with autoantigen development) contribute to the pathogenesis of AD (see chapter 1.1.2.1 Atopic dermatitis). *S. aureus* clumping factor B binds to loricrin and cytokeratin 10 and promotes adhesion of *S. aureus* to the str. corneum also via fibronectin. Antimicrobial peptides (AMPs) such as beta-defensins and cathelicidins are also reduced in AD lesions. The interleukins IL-4 and IL-13 of the Th2 cell pathway play a major role and drive inflammation in AD. Th2 cytokines reduce expression of important skin barrier proteins: filaggrin, loricrin and involucrin. While healthy individuals are less colonized with *Staphylococcus aureus*, 70% of patients with AD are colonized at lesional sites. Bacterial virulence factors, such as superantigens, proteases and cytolytic phenol-soluble modulins (PSMs) secreted by *S. aureus*, cause additional skin inflammation and may also contribute to bacterial persistence and /or epithelial penetration via scratching and, in the worst case, superinfection. When sampling skin swabs during flares of AD the cutaneous microbial diversity has been shown to decrease remarkably, with predominance of *S. epidermidis*, *S. aureus*, and *Malassezia* species. Infants already showing features of AD at 1 year of age have significantly less commensal *Staphylococci* in the antecubital fossa compared with the age of 2 months and when compared with unaffected infants. Early exposure to *Staphylococcus* may reduce the development of AD (adaptive immune response). In addition, AD patients are more prone to suffer from herpes (eczema herpeticum) or malassezia infections. However, topical treatment with antibiotics is not the solution, but the interruption of the inflammatory cascade by the itch-scratch cycle and downregulating of Th2 cell mediators as well as the stabilization of the skin barrier. In general, one has to differentiate between a proinflammatory associated status and progressive change of microbiota in AD and a real superinfection.

Acne

Acne vulgaris originates in the pilosebaceous unit of the skin starting in (pre)puberty. Increased and modified sebum production, disturbance of follicular keratinocyte differentiation and release of inflammatory mediators are the primary driving forces of acne. The second step in the pathogenic cascade is colonization of this unit by *Cutibacterium acnes*, a commensal bacterium followed by additional triggering of inflammation. It is not a primary infection per se, as for example a folliculitis with overgrowth of *Staph.aureus*. The environment and biochemistry of the pilosebaceous unit is unique and the intrafollicular microbial colonization does not correlate with the interfollicular epiderma I surface composition. *C. acnes* has the metabolic potential to substantially alter its local environment. It produces numerous enzymes and proteinases including lipases that all together alter the sebaceous lipid composition and contribute to the production and release of antimicrobial and immunomodulatory molecules (i.e upregulation of Toll-like receptor 2 on follicular keratinocytes or macrophages, acquisition of Th4 and Th17 cells). However, there are multiple strains of *C.acnes* in the follicular canal and on the skin responsible for different courses and severity of the disease. Via multi locus sequence typing (MLST), a standard method today of analyzing and subtyping bacteria, one differentiates the clade of subtypes

IA1, IA2, IB, and IC responsible for the disease course. In particular, topical antibiotic treatment with erythromycin, clindamycin, nadifloxacin or tetracyclines lead to development of resistance. Therefore, microbial killing substances such as benzoylperoxide or azelaic acid and stabilizers of the intrafollicular keratinization such as retinoids are preferred. New therapeutic advances are the transplantation of enzymatic differently armoured *C.acnes* strains which compete with the pathologic ones which may lead to improvement of the disease.

([Figure 5](#))

Psoriasis

Psoriasis is characterized by hyperproliferation of keratinocytes with increased desquamation and increased inflammation. One should expect that the high epidermal turnover does not allow a settlement of pathologic microbiota, but the disturbed barrier function of psoriasis gives rise to an altered microbiome. Moreover, throat and nasal Streptococcal infection have been shown to trigger initiation and exacerbation of psoriasis suggesting a microbial contribution to the disease.

At first, psoriasis-associated skin microbiota displays a higher diversity and more heterogeneity compared to healthy skin bacterial communities. So called specific microbial signatures are associated with lesional and non-lesional psoriatic skin compared to healthy skin. A relative enrichment of *Staph. aureus* and *Staph. pettenkofferi* was strongly associated with both lesional and non-lesional psoriatic skin. In contrast, *Staphylococcus epidermidis* and *Cutibacterium acnes* were underrepresented in psoriatic lesions in particular on the arm, gluteal fold, and trunk. However, both were normal in non-lesional skin. The *Staph.aureus* overgrowth in certain lesion types and anatomic sites drives Th 17 cell response and release of cytokines of IL-17 but also IL-23R and IL-22 types. This more or less drives additional inflammation but it is not an infection per se.

Skin aging

There is a now more evidence about skin aging and the skin microbiome. Recently, it was found out a negative relationship between microbiome diversity and transepidermal water loss, and a positive association between microbiome diversity and age.

Laboratory & other workups

Standard procedures in cutaneous microbiology are swabs from visible altered skin sites or nares or fluids. In addition, extraction of follicular material by pressure or by a needle or cyanoacrylate stripes is possible. Material can also be taken by nail cutting (mycosis, *pseudomonas*) or hair plugging (bacteria or intratrachal or extratrachal mycosis) and, finally, deeper scratching to extract parasites from skin

lesions (scabies, larva migrans). For mycoses with yeasts the Wood light can be used. For discrimination of deeper dermal infections such as MOTT or classical tuberculosis, Borrelia, deep mycoses (coccidiomycosis) or parasites (worms) a punch or spindle biopsy is necessary for immunohistochemistry or gene sequencing.

Usually, a standard identification of the microbe is performed. Resistance patterns for antibiotic systemic treatment are necessary when a relevant deeper infection or pathological virulent microbe is apparent. Subtyping of phylae, subspecies and clades are reserved for research purposes at the moment. Those current implemented methods are next generation 16S sequencing and shotgun metagenomics sequencing.

Special

Currently, there is emerging research on the skin microbiome and its connection with the gut, referred to as the gut-skin axis and its effects on dermatologic conditions including the response to immune targeted therapy in melanoma.

References

- [Allyson L. Byrd Yasmine Belkaid & Julia A. Segre \(2018\) The human skin microbiome. Nature Reviews | Microbiology 16 :143- 155](#)
- [Sinha S, Lin G, Ferenczi K \(2021\) The skin microbiome and the gut-skin axis. Clinics in Dermatology 39,5 :829-839](#)
- [Eisenstein, M \(2020\) The skin microbiome outline a second skin Nature 588 S 211](#)
- [Brüggemann H, Salar-Vidal L, Gollnick HPM, Lood R \(2021\) A Janus-Faced Bacterium: Host-Beneficial and -Detrimental Roles of Cutibacterium acnes. Frontiers in Microbiology 12: 673845.](#)
- [Myers T. \(2024\) A multi-study analysis enables the identification of potential microbial features associated with skin aging signs. Front. Aging 2024, 4:1304705. doi: 10.3389/fragi.2023.1304705. https://www.frontiersin.org/articles/10.3389/fragi.2023.1304705/full](#)
- [Santiago-Rodriguez TM, Le François B, Macklaim JM, Doukhanine E, Hollister EB. The Skin Microbiome: Current Techniques, Challenges, and Future Directions. Microorganisms. 2023 May 6;11\(5\):1222. doi: 10.3390/microorganisms11051222. PMID: 37317196; PMCID: PMC10223452](#)

9.2 Diagnostic Procedures

9.2.1 Bedside Tests

Z. Bukvic Mokos, Zagreb; B. Marinović, Zagreb

At the dermatologic examination, several simple bedside tests may help to narrow the differential diagnosis. The most commonly performed bedside tests are listed below. For functional and imaging tests, dermatopathology and other tests see chapters 9.2.2. and 9.2.3.

Nikolsky sign

Nikolsky sign is shearing away the epidermis after gentle lateral or tangential pressure or rubbing the peribullous skin. It is positive in patients with pemphigus, staphylococcal scalded skin syndrome (SSSS), and toxic epidermal necrolysis (Lyell's disease).

Indirect Nikolsky (Nikolsky II) is elicited by the gentle pressure on an intact bulla that results in the spread of fluid in the epidermis away from the site of pressure (the "bulla-spread phenomenon").

Darier sign

Darier sign designates the rapid appearance of a wheal or an acute or late persisting erythema when the lesion is stroked. It typically occurs in patients with cutaneous mastocytosis or urticaria factitia.

Auspitz sign

Auspitz sign is the appearance of punctate bleeding after removing the scales from plaques in psoriasis. The erythematous-squamous plaque is gently scraped with a tongue depressor or a glass slide, resulting in the removal of silvery scales. After scraping off all the scales, a glistening transparent membrane (Buckley's membrane) appears. On removing the membrane, punctate bleeding points are observed. Bleeding comes from the capillaries of the papillary layer beneath a thinner epidermis between broad rete ridges.

Skin scraping for diagnosing fungal infections and scabies

For diagnosing fungal infections, scales (squamae) are taken with a glass slide or a metal blade from the border of the lesion and placed onto a glass slide. Afterward, a drop of 10 to 20% potassium hydroxide (KOH) is added. The fungal infection is confirmed if hyphae or yeast cells are detected.

For diagnosing scabies, scrapings are taken from suspected burrows or inflammatory papules using a metal blade previously dipped into the mineral oil. Scrapings are placed on a glass slide. Scabies is confirmed if mites, feces (scybala), or eggs are seen in the microscopic examination. Dermoscopy can also help prediagnosing and guiding the site of scraping.

Diascopy

Diascopy is performed by pressing a glass slide on a lesion, causing the compression of small vessels. On diascopy, hemorrhagic lesions (petechiae or purpura) do not blanch; but inflammatory and vascular lesions do. Diascopy may be used in detecting granulomatous diseases such as lupus vulgaris or sarcoidosis, which turn an “apple jelly” color on diascopy.

Köbner phenomenon

Köbner phenomenon denotes the development of new skin lesions of a pre-existing dermatosis within the areas of physical trauma in otherwise healthy skin. Physical trauma includes scratching, friction, rubbing, pressure, incision, laceration, insect bites, etc. Köbner phenomenon may appear 10 to 20 days (with a range from 3 days to 2 years) after the injury. It is most commonly seen in psoriasis and lichen planus.

Tzanck smear

Tzanck smear is a very simple and rapid cytologic test that is most commonly used to diagnose viral infections such as herpes simplex and herpes zoster and may help diagnose intraepidermal autoimmune blistering diseases such as pemphigus vulgaris. The blister roof is removed with a sharp blade, and the base is gently scraped with a scalpel or the edge of a spatula. At scraping the base, bleeding should not be provoked, as the inclusion of blood may disable the interpretation of results. The scraping is transferred onto a glass slide, air dry, and stained with Giemsa stain.

In herpes simplex and herpes zoster, ballooning multinucleated giant cells and eosinophilic inclusion bodies are detected, whereas in pemphigus vulgaris acantholytic cells may be seen.

Dermoscopy

Dermoscopy is a non-invasive diagnostic technique that evaluates colors and microstructures of the skin that are not visible to the naked eye, using a hand-held dermatoscope (mostly used), a stereomicroscope, or a videodermatoscope. The magnification of these instruments may be from 6x up to even 100x. Dermoscopy is mainly used for the assessment of pigmented lesions, i.e., differentiation between melanocytic and non-melanocytic lesions and then evaluation of benign and malignant features of melanocytic nevi and melanoma (see also chapter Imaging techniques). However, it is

routinely used in the differentiation of non-melanoma skin cancer in particular basal carcinoma, actinic keratoses or others such as seborrheic keratosis and epidermal lesions of rare origin.

Dark-field microscopy

Dark-field microscopy (both optical and electron microscopy) excludes the unscattered beam from the image. Consequently, the field around the specimen becomes generally dark. A darkfield condenser lens with a numerical aperture of less than 1.0 should be used when performing optical microscopy. Oil immersion is needed.

This procedure is most commonly used for diagnosing primary syphilis (less commonly for secondary syphilis) by demonstrating the presence of motile *Treponema pallidum* in lesions (chancre).

Serous exudate from the chancre is placed on the slide and examined within 20 minutes of collection.

Wood's lamp examination

Wood's lamp is a low-output mercury arc lamp, filtered by barium silicate and a 9% nickel oxide filter, emitting UV light of 320-450 nm (peak 365 nm). It provokes fluorescence of the skin.

Wood's lamp examination is most commonly used in detecting fungal infections, including pityriasis versicolor (yellowish or orange fluorescence) and *Malassezia* folliculitis (bluish-white fluorescence); bacterial infections such as erythrasma (coral-red fluorescence); and pigmentary disorders including vitiligo (bright bluish-white fluorescence) and melasma (dark brown fluorescence).

The procedure requires an entirely dark environment (the room lights should be turned off, and the shades should be closed). In addition, the examined skin should be clean, free from cream, makeup, or deodorants.

9.2.2 Non-invasive imaging methods in Dermatology

V. del Marmol, Brussels; P. Pasquali, Barcelona; J. White, Brussels.



Although many diagnoses in dermatology are made clinically, sometimes extra help is required. Skin biopsies are still the gold standard if by macroscopy or dermatoscopy a proper diagnosis cannot be made; however, the area and lesion have to be selected carefully to be representative of the whole lesion. Various non-invasive techniques have therefore been developed to close the gap between macroscopy

and biopsy to visualize the skin in certain situations. Some of these techniques will not be available in all centres.

1. Clinical Photography and imaging with different light sources

Photography is a powerful tool for teaching and learning medicine. In dermatology, it is very helpful in diagnosing skin diseases which may not be present on the day of clinical review, e.g. intermittent urticaria. Serial photographs can be very helpful in tracking pigmented lesions to assess the chance of malignant change. This is done with Total Body Photography. In store-and-forward telemedical settings, clinical and dermoscopic pictures are pivotal for diagnosing and monitoring skin diseases. Ultraviolet imaging can help visualize bacterial porphyrins.

UVA imaging helps visualize areas covered by sunscreen and it is used to teach patients how to correctly apply their products; infrared imaging is used to see vessels underneath the skin.

2. Dermoscopy and digital dermoscopy

Examining the skin, hair, follicles or nails under a magnifying, polarized (x10-20 the size of normal) or non-polarized light can give additional information for pigmented and non-pigmented lesions and some forms of inflammatory dermatoses, as well as vascular lesions. Digital images (or serial images) may be stored from dermoscopic examination and either reviewed by a clinician, or by artificial intelligence. The original term “dermatoscopy” is still used synonymously with the internationally consented term “dermoscopy”. Trichoscopy is the dermoscopy of hair and scalp and it enables visualizing and identifying distinctive signs and structures for diagnosing hair and scalp conditions. Nails dermoscopy is also a relevant field for diagnoses and monitoring. The use of dermoscopy in the diagnosis and management of parasitic and infectious skin disorders has been defined as entodermoscopy.

Light Microscopy

The light microscope is an instrument for visualizing fine detail of an object. In dermatology it is of great value to confirm presence of parasites (lice, mites), fungi (yeast, ringworms); in cytologic examination of skin conditions (skin cancer, bullous diseases); and in bacterial infections (gonorrhoea, syphilis).

3. Diaphanoscopy

Producing anemia of inflamed skin by pressure with a glass spatula may reveal the typical apple yellow colour of granulomatous infiltrates e.g. in sarcoidosis.

4. Spectrophotometric intracutaneous analysis

This machine provides input about the content of melanin, haemoglobin and collagen in the epidermis and papillary dermis. This technique may be useful especially for non-experts to calculate risk of melanoma in a clinically atypical pigmented lesion.

5. Nevi sense

This technology relies on the fact that there may be a difference in impedance in skin cancers compared with normal skin and that this can be elicited by a sensitive electrode, such as in the Nevisense machine. It may be a useful adjunct to the clinician prior to a biopsy.

6. Ultrasound

High-frequency ultrasound (HFUS) is regularly used in dermatology for measuring depth, length and width of lesions, from benign and malignant tumors, follow up of lymph nodes and to evaluate possible complications of cosmetic fillers. Vessel blood flow is diagnosed with equipments that include Doppler-technique. Duplex-sonography is used for the assessment of deep thrombosis and requires transducers that reach deeper structures. Another aspect that has recently been used is elastography of tissue structures.

7. X-ray/Computerised tomography (CT) scan

Sometimes X-ray of other organs may be required for the work-up of certain dermatological conditions (e.g. chest X-ray for cutaneous sarcoidosis). X-ray may be helpful to evaluate some skin problems e.g. calcinosis cutis. CT or PET-CT (see below) scanning is a mandatory investigation of advanced skin tumours which may have metastasized. It may also be useful for hunting any underlying tumours in conditions such as dermatomyositis or paraneoplastic pemphigus.

8. Positron Emission Tomography (PET)

PET scans involve a radioactive tracer being visualized in vascular or metabolic processes. It may identify neoplasms earlier than other techniques such as CT, and can be used to seek an underlying (clinically undisclosed) malignancy, i.e. sentinel lymph node metastasis in malignant melanoma. It may be combined with CT (PET-CT) to enhance sensitivity.

9. Magnetic resonance imaging (MRI)

Similar to CT scanning, MRI can be helpful in certain situations in dermatological diseases, e.g. investigation of neurofibromatosis or Sturge-Weber syndrome.

10. Reflectance confocal microscopy (RCM)

This technique focuses light at sequential levels with a spatial pinhole and provides a horizontal image of the skin with high lateral resolution of 1µm. The maximal penetration of the skin is around 250 µm, which does not allow examination of the deeper part of the dermis at all and does not deliver clear results of the papillary dermis. It is frequently used for assessment of epidermal manifestations of skin

malignancies, but may also be useful in inflammatory skin conditions.

11. Vertical Laser Microscopy

This vertical laser technique provides deep penetration in the dermis and can help to close the gap between dermatopathology and reflectance confocal microscopy.

12. Optical Coherence Tomography (OCT)

Conventional OCT provided both horizontal and vertical sections of the skin and penetrates around 2mm, with a lateral resolution of around 7.5 μ m. High-definition OCT penetrates the skin deeper, but linefield-confocal OCT is the best, with a penetration of 500 μ m and a lateral resolution of 1 μ m. This can be very useful to delineate margins of tumours in vivo and confirm or exclude malignancy without the need for a skin biopsy.

Line-field confocal optical coherence tomography (LC-OCT) combines the principles of time-domain optical coherence tomography and confocal microscopy (OCT+RCM) which gives cellular and volumetric diagnosis at the same time.

Special

For other skin test methods, refer to the chapter on Cutaneous physiology and 9.2.4.

9.2.3 Basics in Dermatopathology

G. Burg, Zurich; F. Rongioletti, Milan.



Subchapter of 9.2 General Dermatology

Basics in Dermatopathology

See also: Chapter 9.3.3 on Basics of dermatology-surgery techniques

Chapter 9.1.1 Basics in anatomy and physiology

The most efficient method in the diagnosis of skin diseases is the combined validation of clinical and histopathological features, i.e., clinico-pathologic correlation. The diagnostic impact of histopathology may be decisive or just confirmative of one or more clinical differential diagnoses. The majority of skin biopsies can have a specific diagnosis and the remainder can be classified into a particular group of disorders. However, there are some dermatoses in which a biopsy is not indicated because typical histopathologic features are lacking.

The process of interpretation of skin biopsies starts with the differentiation of an inflammatory disorder from a neoplastic condition. As for inflammatory conditions, the interpretation consists into the integration of 2 morphological features: the tissue reaction pattern and the composition of the infiltrate. There are at least 6 major tissue reaction patterns: psoriasiform, spongiotic, lichenoid, vesiculo-bullous, granulomatous, vasculopathic/vasculitic.

1. Taking a biopsy

1.1. [When](#)

When considering clinicopathologic considerations in approaching a diagnosis there basically are four scenarios, in which the diagnostic impact of histopathology may be high, moderate, low or none.

1.2. Where

In inflammatory processes, infectious or non-infectious, the biopsy should be taken from the border of the lesion, where the initial changes without regenerative, necrotic, fibrous or secondary granulomatous reactions are found.

In tumors, however, the biopsy should be taken from the center of the lesion or in some cases from the border, including both normal and neoplastic tissue. In very large lesions one from the center and one from the margin is recommended.

1.3. [How](#)

It is fundamentally important, that the dermatopathologist, to whom the specimen is referred for microscopic evaluation, is able to describe his findings in the context of the clinical features the clinician has written down on the application form when sending in. The specimen must include the critical tissue levels and must show the pathologic changes. One of the most frequent mistakes is a superficial biopsy, missing the pathologic changes in the deep dermis or subcutaneous tissue.

In addition, the clinician should provide the pathologist with clinical differential diagnoses, too.

Depending on the size and the depth of the lesion, it can be either completely excised-especially small tumors- (by intention excisional biopsy) or a spindle- or wedge-shaped biopsy is taken from the border (incisional biopsy).

In tumorous lesions reaching to the surface of the skin, a flat slice can be removed horizontally with a scalpel (shave biopsy).

Punch biopsies can be applied for homogeneous tumor lesions (size of diameter between 4 to 8mm).

Fragmented material from superficial curettage may be sufficient in special situations for confirming infectious (warts, mollusca contagiosa) or neoplastic origin (actinic keratosis), when the morphology of a small cluster of tumor cells is sufficient for making a diagnosis. Swabs from the nostril area or from the superficially scratched earlobe may provide material for microbiologic investigations under the microscope or in appropriate culture media.

Tape strips for diagnosing mycotic infections from the body sites (M.furfur) with a mythelene stain is

easy to perform and confirms fast a diagnosis within minutes.

Electrocaustic retrieval of a specimen should be avoided, since important tissue structures may be boiled.

1.4. 3-D dermatopathology (Mohs-technique)

The basic idea of the micrographic¹ controlled surgery (MCS), as invented originally by Frederic Mohs in Madison/Wi, USA, was to confirm by 3-dimensional sectioning that the borders of the excised specimens were tumor free towards the periphery and towards the depth and by serial surgical procedures to completely remove the tumor and saving uninvolved tissue. This technique, originally as pre-fixed, later on as fresh tissue and finally today mostly as post-fixed procedure is indicated for solid tumors with superficially undetermined, “subclinical” borders; not for inflammatory dermatoses. Today, in addition, immunostaining can be done immediately on a Moh’s section to identify specifically tumor cells to be more precise when evaluating the section border.

2. Sample processing

The biopsy is trimmed to an optimal size of 1x2x2 cm and fixed in buffered formalin (4% aqueous solution) for several hours before embedded into a paraffin block. These procedures today can run automatically.

Sections of 2-4 microns perpendicularly from the epidermis to the subcutis are cut with a microtome on to a glass slide, which is transferred to an automatic staining device.

3. Staining

3.1. Routine

Ha(e)matoxylin and Eosin (HE): blue and red

3.2. Special stains

Alcian blue: blue. Acid glycosamines

Berlin Blue: blue. Hemosiderin (iron)

Elastica: black. Elastic fibres

Fite-Faraco: red. Mycobacterium leprae

Giemsa: violet blue. Mast cells, amastigotes in leishmaniasis

Gram: blue (Gram positive bacteriae) or red (Gram negative bacteriae)

¹This hybrid expression refers to the procedure, in which the microscopic investigation of a histologic specimen is guided by colored margins depicted also in a corresponding macroscopic mapping of the specimens.

Grocott: black. Fungi

Congo red: pink or green in polarized light. Amyloid

Kossa: black. Calcium

Masson-Fontana: black. Melanin

Naphthol-AS-D Chloroacetate esterase: (Leder's stain) red.

Mast cells Periodic Acid Schiff (PAS): violet, purple. Stains glycogen, fungi, basal lamina

Sudan (cryosection): orange or yellow. Lipids

Toluidine Blue: bluish granules. Mast cells

Van Gieson-Elastica: red (collagen), black (elastic fibres), muscle fibres (yellow)

Warthin-Starry: black. Spirochetes, fungi

Ziehl-Neelsen: red. Acid fast bacteria (tubercle bacilli, leishmania)

3.3. Molecular Morphology²

Immune histochemistry and immune phenotyping: Labelling of antigens (epithelial, mesenchymal, vascular, melanocytic, neural, lymphocytic, dendritic, histiocytic, bacterial, fungal and proliferation markers), membrane markers or cell-to-cell contacts with specific mono- or polyclonal antibodies, which often stain specific or several epitopes of different cells or structures.

Direct Immunofluorescence (DIF): Use of antibodies labelled with a fluorochrome. The most important applications include autoimmune-bullous dermatoses, vasculitis and lupus erythematosus. Double labelling or labelling with up to 50 markers is possible today (multi epitop ligand cartography).

In-situ-Hybridization (ISH): Detection of microorganisms and confirmation of clonality of i.e. in lymphoproliferative disorders (lymphomas).

Fluorescence-in-Situ Hybridization (FISH): Detection of chromosomal aberrations, i.e. in neoplasia.

Polymerase-Chain-Reaction (PCR): extremely sensitive for detection of i.e. microorganisms, clonality (receptor rearrangement), mutations, oncogenes.

4. Structure of normal skin: <https://www.cyberderm.net/en/learn/structure-of-the-skin>

There are striking regional differences with respect to thickness of the skin-layers, sensory receptors, vessels, connective tissue, subcutaneous fat and adnexae.

²Cryocuts from unfixed tissue or from samples fixed in special Michel's solution needed for many antibodies. The results always have to be interpreted in conjunction with clinical and histological findings.

4.1. Epidermis

Multilayer squamous epithelium of 0.3-0.8 mm thick. From the outside to the inside, the following layers are distinguished:

- 4.1.1. *Stratum corneum* consists of flat, plate-like, interlocking coreless keratinocytes, which are held together by intercellular “barrier lipids” (e.g. ceramides). Since it is the outermost protective layer of the body, it exerts a mechanical barrier function, prevents excessive water loss and protects from penetration of microorganisms, chemicals or allergens.
 - 4.1.2. *Stratum granulosum* exhibits moisturizing and UV-protective (pyrrolidone carboxylic acid) functions. The granules contain lipids and enzymes, which are released into the intercellular space and lead to the formation of a water-resistant putty substance in the stratum corneum.
 - 4.1.3. *Stratum spinosum* together with the stratum basale forms the stratum germinativum (stratum germinativum). The histologic processing of skin samples results in shrinking of the sections, which accentuates their intercellular desmosomal contacts (spiny cell layer). The keratinization process begins in this layer. During their migration to the outermost layer of the epidermis, the cells become flattened and cease to divide, keeping a delicate balance between gain and loss of cells by peeling off the skin surface.
 - 4.1.4. *Stratum basale* (stratum germinativum). Cells of this layer exhibit qualities of determined stem cells. Following division one cell migrates to the skin surface within the next 4 weeks, whereas the other remains and divides again.
 - 4.1.5. Up to 8% of the cells basal layer of the epidermis are melanocytes which produce melanin, a dark pigment blocking UV rays. Ethnic different skin colors are due to the packaging and distribution pattern of the pigment grains (loose fine granules in black people or packed in melanosomes in Caucasians).
 - 4.1.6. Langerhans cells are another type of dendritic cells in the germinative layers of the epidermis and also present as dendritic reticulum cells (DRC) in the dermis. They derive from the bone marrow and play a pivotal role in the immunological defense and in the recognition of antigens.
 - 4.1.7. Merkel cells are a third type of dendritic cells in the epidermis. Localized in the basal layer they fulfill sensory receptor functions (pressure).
- 4.2. The Dermo-epidermal junction (grenz-zone) comprises a complex PAS positive basal membrane, which is anchored to the dermis by hemidesmosomes. Metabolic products, dendritic immune cells and lymphocytes are exchanged between the two compartments. Under the electron microscope the complex structure of the junction zone is revealed, comprising of (1) the cytoskeleton of the basal keratinocytes with intermediate filaments composed of keratin 5 and 14; (2) the anchorfilaments of the hemidesmosomes (Lamina

lucida), consisting of various molecular structures; (3) lamina densa with collagen IV as the main component besides other components; (4) the sublamina densa, which is directly adjacent to the lamina densa and consists of collagen type I, III, IV and type VII, anchoring to the papillary dermis. These structural proteins and their antigenic determinants play an important role in the pathophysiology of some autoimmuno- and geno- dermatoses.

4.3. Dermis

4.3.1. The Papillary dermis is the upper part of the dermis, protruding as rete ridges between the epidermal papillae. The capillary loops provide optimal nutrition for the epidermis and fine nerve endings give sensory protection.

4.3.2. The Reticular dermis shows a texture of collagen fibres, which is more compact than in the papillary dermis. Moreover, it harbors vascular, nervous and adnexal elements between fibroblasts, histiocytes, macrophages, dendritic and other cells, permanently migrating through the skin.

4.4. The Subcutis consists of fat lobuli separated by sepal fibres, connecting it to both the dermis and the deeper tissue. It serves as energy and heat storage, and as mechanical protective pad.

4.5. Adnexal structures

4.5.1. Hairs are found on almost all body surfaces except for soles and palms. They consist of dead, fish-scale-like horn cells produced in the hair follicles of the dermis. The hair follicle consists of an epithelial layer that surrounds the hair root. The lower part of the hair follicle, the hair bulb, is embedded in a net of nerve endings and capillaries. Hair growth occurs in a cycle: (1) anagen (growth) phase (2-6 years; 0.3 mm per day) in which 85% of our head hairs are; (2) 2-week catagen (transition) phase; and (3) telogen (resting) phase (3-4 months) in which 50-100 hairs per day are lost.

Sebaceous gland follicles are endocrine adnexal organs per se and smaller glands are linked to the terminal and vellus hair follicles. They are under control of androgens, growth factors and other mediators and produce a high number of different lipids (sebum), which protect skin and hair from drying out, water loss and growth of pathogenic bacteria.

4.5.2. Sweat glands.

4.5.2.1. The eccrine sweat glands are spread over almost the entire body surface. The twisted part in the deep dermis with a secretory and an excretory part which leads via a straight dermal duct directly to the epidermis where it is coiling and reaching the skin surface and produces an aqueous secretion, which is rich in urea, uric acid, ammonia, salts and other substances. They are used for temperature regulation and the excretion of metabolic products.

4.5.2.2. The apocrine sweat glands are found in the axilla, the groin, the anogenital area and the beard hair in men. The secretory portion lies mainly in the subcutis with the excretory duct flowing into the upper hair follicle canal.

5. Pathologic changes

5.1. Epidermis.

- 5.1.1. Orthokeratosis: Basket weave stratum corneum in the fixed tissue section

Example: Normal skin

- 5.1.2. Hyperkeratosis: Thickening of the stratum corneum due to increased epidermal proliferation or retention of horny cells by reduced scaling

Example: Ichthyosis

- 5.1.3. Parakeratosis: Remnants of nuclei remain in the stratum corneum due to disturbance of the keratinization process (dyskeratosis)

Example: Eczema

- 5.1.4. Atrophy: Reduced spinal layer and flattening of the basal undulation

Examples: Aged skin; lichen sclerosus et atrophicus

- 5.1.5. Acanthosis: Thickening of the epidermis to due broadening of the spinal layer following increased proliferation and turnover of keratinocytes

Example: Chronic eczema; psoriasis

- 5.1.6. Papillomatosis: Hyperplasia of epidermis with resulting dermal papillae forming an undulating wave like basal lamina

Example: Psoriasis

- 5.1.7. Hypergranulosis: Broadening of the stratum granulosum due to disturbances in the keratinization process or hyperproliferation

Example: Lichen planus

Hypogranulosis: reduced or absent stratum granulosum

Example: psoriasis, ichthyosis

- 5.1.8. Spongiosis: Dehiscence of keratinocytes with intercellular edema up to intraepidermal blister formation; desmosome bridges may be preserved

Example: Acute eczema

- 5.1.9. Acantholysis: Loss of intercellular connections (desmosomes, desmogleins, desmoplakins) between keratinocytes, resulting in blister formation

Example: Pemphigus vulgaris

- 5.1.10. Dyskeratosis: Premature or altered (abnormal) keratinocyte differentiation with preservation of nuclei in the stratum corneum

Example: Dyskeratosis follicularis Darier

5.1.11. **Ballooning**: Intracellular edema, blowing up the cell size

Examples: Herpes virus infections

5.1.12. **Necrolysis**: Complete damage and lysis of the cellular structure and substance

Example: Toxic epidermal necrolysis (TEN)

5.1.13. Apoptosis: programmed cell death by regulating different events to the epidermal cells (physiologic or in response to premalignant or malignant processes)

Examples: UV light damage, immuno surveillance, Herpes virus infections

5.2. Dermo-epidermal junction (grenz-zone)

5.2.1. **Interface dermatitis**: Obscuring of the border between epidermis and papillary dermis due to edema (vacuolation), epidermotropism of inflammatory cells or to cellular infiltrate in the papillary zone (lichenoid type)

Examples: Lupus erythematosus; lichen planus

5.2.2. **Subepidermal blistering**: Supra- or infrabasal blistering separation of epidermis and the papillary dermis

Example: Bullous pemphigoid

5.2.3. **Subepidermal edema**: Edema in the papillary dermis without blister formation

Example: Erythema exsudativum multiforme

5.3. Dermis

5.3.1. **Fibrosis**: Increased numbers and activity of fibroblasts

Examples: Fibroma; histiocytoma

5.3.2. **Sclerosis**: Compact densely packed collagen fibres usually paucicellular (reduced number of connective tissue cells)

Example: Scleroderma

5.3.3. **Elastosis**: Degenerative changes of collagen and elastic tissue with development of coarse fibres

Example: Actinic elastosis

5.4. Vessels

5.4.1. **Vasculitis**: Swelling of endothelia, extravasation of fibrin and erythrocytes, leuco- or lymphocytic perivascular inflammation, leucocytoclasia;

Example: Vasculitis allergica

Thrombotic vasculopathy: occlusion of vessels by thrombi in the absence of inflammatory infiltrate

5.4.2. **Calcification**: Calcium deposits in and around (elastica) vascular endothelial cells

Example: Calciphylaxis

5.4.3. **Proliferation**: Endothelial cells and vascular spaces

Examples: benign (hemangioma), "semimalignant" (Kaposi) or malignant processes (hemangiosarcoma)

5.5. Deposits and Storage

5.5.1. **Foreign bodies**: Inorganic material (pigment) inserted from outside intentionally (tattoo), or accidentally, into the dermis is ingested by macrophages or -if the particles are too big- leads to enclosure by a granulomatous inflammatory infiltrate with various types of multinucleated giant cells

Examples: Tattoo; foreign body granuloma

5.5.2. Other deposits: Melanin, lipids, urate, mucin, iron (hemosiderin), porphyrins, calcium, amyloid and other organic or inorganic substances, produced during pathologic disease processes may be deposited intracellularly (macrophages) or extracellularly between or attached to collagen bundles in the dermis.

Examples: Nevi; xanthoma; gout; mucinosis; pilomatricoma (Malherbe)

References

- [Jartarkar SR, Cockerell CJ, Patil A, Kassir M, Babaei M, Weidenthaler-Barth B, Grabbe S, Goldust M. \(2023\). Artificial intelligence in Dermatopathology. J Cosmet Dermatol. Apr;22\(4\):1163-1167. doi: 10.1111/jocd.15565. Epub 2022 Dec 22. PMID: 36548174](#)
- [Latriglia F, Ogien J, Tavernier C, Fischman S, Suppa M, Perrot JL, Dubois A. \(2023\). Line-Field Confocal Optical Coherence Tomography \(LC-OCT\) for Skin Imaging in Dermatology. Life \(Basel\). 13\(12\):2268. doi: 10.3390/life13122268. PMID: 38137869](#)
- [Gallay C, Ventéjou S, Gaide O, Christen-Zaech S. \(2021\). \[Cutaneous visualization by different non-invasive skin imaging methods\]. Rev Med Suisse. 17\(732\):624-629. PMID: 33793099](#)
- [G. Burg, H.Kutzner, W.Kempf, J Feit and O. O. Sanguenza. \(2021\). Atlas of Clinical Dermatopathology, Vol III: Infectious and Parasitic Dermatoses. Oxford, Wiley Publisher.](#)
- [Burg, G., H. Kutzner, W. Kempf, J. Feit and B. Smoller \(2019\). Atlas of Clinical Dermatopathology, Vol. II: Tumors, Nevi, and Cysts, Oxford 2019, Oxford Wiley Publisher.](#)
- [Liersch, J., von Köckritz, A., & Schaller, J. \(2017\). Dermatopathology 101: Part 1 - Inflammatory skin diseases. J Dtsch Dermatol Ges, 15\(1\), 9-30. doi: 10.1111/ddg.13176. PMID: 28140531.](#)
- [Liersch, J., von Köckritz, A., & Schaller, J. \(2017\). Dermatopathology 101. Part 2 - Skin tumors. J Dtsch Dermatol Ges, 15\(9\), 906-929. doi: 10.1111/ddg.13320. Epub 2017 Aug 25. PMID: 28841778.](#)

- [Burg, G., W. Kempf, H. Kutzner, J. Feit and L. Karai \(2015\). Atlas of Clinical Dermatopathology, Vol. I: Practical Differentialdiagnosis of Inflammatory Dermatoses by Clinicopathologic Pattern. Vol.I. Oxford, Wiley Publisher.](#)

9.2.4 Non-invasive Methods in Dermatology: Functional Tests



H. Gollnick, Magdeburg

A great part of dermato-venereological diseases can be diagnosed by the naked eye, the palpating finger and the appropriate long-term experience and expertise in the clinical setting. However, several situations in diagnosing diseases and monitoring treatment efficiently need invasive techniques such as the gold standard of dermatopathology (see chapter 9.2.3) and / or non-invasivetechniques such as imaging technology (see chapter 9.2.2). In addition to these, functional tests have been developed over decades to give measurable objective data of the skin and its appendages in health and disease. Some tests are easy to perform, others require more advanced technology, material, time and energy.

Tests of the epidermal function

Tests for epidermal function include in particular those measuring desquamation, hydration and transepidermal water loss, pH and colour including pigmentation which together with some other more specific ones are a common test set. Several stand alone or computer assisted devices are on the market. For other methods see chapters mentioned above.

The epidermal barrier function is composed of a multifunctional physical and biochemical structure and different set of functional tests of the skin exist (see also chapter 9.1.1 to 9.1.4). Its measurement includes methods such as those written below. Several methods used together deliver a good overview on the current status of function of the skin.

Str.corneum cell desquamation is a permanent and essential physiologic part of normal skin. Different factors may influence via outer and inner environmental signals the degree of desquamation (hyperproliferation of basal layer, dryness, repair signals, wounding, cytokine signals, genetic factors, clothes, profession). There are for example dermatoses characterized by high degree of turnover of cells, such as psoriasis, and others such as some ichthyoses with low degree of turnover by retention hyperkeratosis. Aging of the skin mostly has a low turnover.

Instruments to measure the desquamation are chamber techniques with a device to include the loose scales of the upper skin layer. One can measure serial tape strippings to evaluate the recovery function

of the epidermis. Densitometric and light reflectance analysis of the adherent scales together with a specialized software calculates the desquamation index.

Epidermal hydration is essential for skin integrity. If skin becomes dehydrated by increased loss or by decreased supply, function is disturbed and the barrier breaks off.

Hydration of the skin can be measured by electrical conductance, impedance or capacitance. Corneometers (Evaporimeter/Tewameter) are used to measure for example the loss of hydration due to mechanical stress of the hands in occupational diseases such as hand eczema or the success of external rehydration via a moisturizer. Trans-Epidermal Water Loss (TEWL) is measured in g/h/cm². The system measures the water vapour flow density: $JV = g / (m \times h)$ (mass of water vapour (in g) per area (in cm²) and time (in h)).

The pH value is a biomarker for the skin's natural acid mantle (around pH 5). Not only the hydration from the pressure of water from the inside via capillaries and take up by the epidermal cells but the amount of sweat from eccrine and apocrine glands, lipids from the epidermal and the sebaceous cells are important. A neutral pH value can lead to lower resistance to infections, barrier function disorders and the spread of skin diseases.

Oxygen tension can be measured as a function of capillary oxygen supply to the epidermis which is reduced during aging, loss of capillary network in diabetes, chronic renal failure, sclero- and pseudoscleroderma but may increase to vasodilatation in inflammation or drug related.

Skin pigmentation is roughly related to the skin types I to VI. However, those are not helpful in measuring the individual persons skin pigmentation and changes due to UV light exposure or chemical or other physical stimuli acting on melanocytes. For testing the efficacy of light protection factors in sunscreens for example the use of Colorimetry (reflectance methods via chromameter) is ideal. The method helps to identify not only the degree of melanin but also the other physical colour components which contributes to skin colouring (CIE colour system / L*a*b* system). For example, inflammation redness or colour of skin deposition materials can be measured.

Tape stripping can be used to measure the recovery time of epidermal basal cells or for allergen testing (see below). A simple technique to evaluate if *Malassezia* spores or hyphae are on the skin surface is to make a tape strip (5-10 x) and to glue it on a glass slide. With a droplet of methylene blue, the microbe can be visualized under the microscope.

Tests of the dermal function

Mechanical properties of the skin are in particular influenced by the function of the dermis. The function of elasticity in skin aging, in scleroderma or the adherence of the epidermal-dermal connection at the basal membrane are targets for twistometry, indentometry, ballistometry or suction blister techniques.

Twistometry is used via a disk glued to the skin which is rotated via a small motor thereby measuring the twisting capacity to a given force. An indirect measurement of strength and vitality of elastic fiber and collagen matrix in healthy and diseased skin is possible. Another technique is Levarometry.

Indentometry most used instrument is the Cutometer working with a light source and negative air pressure giving results on the elasticity of the dermis. The light intensity depends on the penetration depth into the skin. The resistance of the skin to the negative pressure (firmness) and its ability to return into its original position (elasticity) display the functional capacity.

Frictometry is a method using a constant pressure on the skin by the weight of a rotating disk which is incorporated in handhold device. It gives results on the elasticity and friction related return to normal and disturbances (loss of elastic fibers, atrophy, sclerosis).

Skin temperature is related to body temperature and blood flow as well as fever signals (cytokines, HSP neuroregulation and others). Thermoregulation detected by thermal imaging devices gives an exact overview on different areas of the body surface. Skin functions as a thermal interface between body and environment. The temperature or heat flow can be measured by conduction (contact thermometry), convection (Schlieren's photography) or radiation imaging (thermal infrared cameras).

Tests for sebaceous gland function

Follicular biopsies are performed to measure the content of the follicular infundibulum and, in particular, to count the number of microcomedones per area. A droplet of cyanoacrylate is applied on a glass slide, then placed with light pressure for example on the forehead and removed after 30–60 seconds. Under the microscope one can count on the surface of the glass slide the number of microcomedones important in acne. It is also used for counting demodex mites in rosacea. The follicular cast can also be used for measuring the number and types of other microbes, content of drugs and lipids produced by the gland.

Sebumetry is the method to measure the temporary composition of surface lipids and amount of lipids coming from the follicular canal of the gland in quantity and quality and for monitoring over time. Different methods are used. Sebutapes are microporous adherent tapes applied on defatted skin. The lipids are absorbed and can be measured by image analysis. The gravimetric technique is of much higher

precision. It uses absorbent paper after defatting of the forehead skin, left there over three hours and then under given conditions regarding air pressure and humidity the amount is measured according to mcg of sebum weight per area and time.

Test for sweat gland function

Sweat gland activity can be reduced or increased in several local or systemic conditions on the body in eccrine and/or apocrine gland rich areas. For example, emotional stress, thermoregulation, paraneoplastic related or endocrine driven, drug induced or idiopathic reasons may stimulate its activity. Diseases such as cystic fibrosis, scleroderma, GvHD, congenital ectodermal dysplasia, sympathectomy or alcohol and diabetes induced neuropathy can go along with reduced sweating or even anhidrosis (primary autonomic disorders with acquired anhidrosis).

Methods to measure: filter paper collection, the quantitative sudomotor axon reflex test (QSART), silastic mold or iodine-impregnated paper imprint after pilocarpine stimulation. Sweat is visualized by a topical indicator such as iodinated starch or sodium alizarin sulfonate (alizarin Red S).

The iodinated starch powder test is prepared by adding 0.5-1.0 g of iodine crystals to 500 g of soluble starch. For smaller body areas, a Minor's starch-iodine test for excessive sweating may be performed by applying betadine on Q-tips to the affected area. Once the iodine solution has dried, cornstarch can be lightly sprinkled on the area. Deep purple color change will develop over time in the areas affected with hyperhidrosis. The amount of sweat secretion per minute and cm² is practicable for definition of hyperhidrosis. Those areas demarcated can be used for injection of botulinum toxin (hands, axillae) or for sweat gland subcutaneous curettage (axillae).

A new customized camera device designed to quantify secretions of individual sweat glands (SGs) after sweating was stimulated on a 2.25 cm² skin area by iontophoresis of pilocarpine can be used the camera imaged sweat from 50 to 400 sweat ducts. One calculates secretion rate of individual SGs, total sweat volume, and number of secreting SGs of different body sites.

Tests for hair function

Different methods exist for evaluation of hair loss and hair growth or the strength and elasticity of hair. Several diseases affecting the hair growth need a biopsy for histological evaluation.

Trichogram is a classical method to study the proportion of anagen, catagen and telogen hairs and its proportion. In addition, dysplastic and dystrophic or broken hairs can be counted. For example, to study the degree of hair loss in androgenetic or androgenic alopecia one samples a bundle of hair from the frontal or parietal and from the occipital hair line after 5 days non washing the hair. With forceps, the

hair is pulled out of its roots and moved to a glass slide, imbedded in Corbit balsam and evaluated under the microscope.

Phototrichogram is a non-invasive and reproducible method to quantify hair density and hair growth parameters. The hairs at a selected site are trimmed for the applied diagnostic optical equipment (0.8-1.5cm). With a syringe with insulin needle or with a tattoo apparatus basically invisible by bare eye tattoo marks are set. The test area is covered with a coverslip glass to allow the positioning of the trichoscope lens. An image is analyzed by special computer program evaluation. The program will calculate the total number of hairs /cm² as well as the number of terminal and vellus-like, anagen and telogen hairs.

Tests for blood vessel functions

For methods see chapters 5.1.2 and 9.2.2 (ultrasound imaging, laser flow assessment).

Glassplate/glass slide

A simple glassplate/glass slide can be used to evaluate if a bleeding like lesion of the skin is a vessel dilatation or a permanent capillary defect with erythrocytes outside the vessel wall. Small pressure to the lesion followed by diminishing or complete abolishing of the erythema speaks towards functional reasons. If the erythematous lesions (petechia, purpura) stay a capillary leakage of different origin can be supposed.

The glassplate can also be used to test the capillary reflex related to pressure and friction followed by erythema or whealing. Paradoxical whitening of the provoked skin area for example can be seen in atopy constitution. Whealing is a sign of dermographism of acute and persisting type and needs further evaluation of the skin or other organs (mastocytosis, physical urticaria, deaminoxidase deficiency). See also chapter urticaria/physical urticaria.

Tests for skin immune functions

Test techniques for different test procedures and protocols regarding allergies are highly standardized in Europe. Irritant patch testing, standard epicutaneous patch testing and photo-patch testing or prick testing are the most widely used ones.

Epicutaneous contact allergy testing is used to evaluate amount and degree of and to differentiate allergic and irritant factors behind eczemas. Standardized or in some cases individualized substances in appropriate vehicles are applied via for example Finn chambers with occlusive protection to the back of a patient. It is left there for 48 hrs and removed for first reading according to a grading protocol. Additional readings follow after 72 and 96 hrs. Some substances require reading after 120 hrs or one

week. A record is to be written and a test protocol handed out to the patient.

Photopatchtesting is performed if suspicious agents/allergens need photoactivation to become immunologic. In addition to the standard test one set of suspicious allergens is additionally irradiated with UVA light and the read out follows the same protocol.

Prick Testing is used for evaluating type I allergy. Standardized solutions of allergens compared to a NaCl and a histamine control field are applied to the skin in a droplet. Each individual droplet is then separately pierced with a lancet, transporting the substance in the epidermis and papillary and mid dermis. Reading of positive wheals according to standardized reading protocols follows continuously and after 20 minutes it is recorded. Sometimes reactions appear later. A record is to be written and a test protocol handed out to the patient.

Other tests not mentioned here in detail are scratch -, rubber-, prick-to-prick or intradermal test. Systemic provocation tests for drugs, food, preservatives and colouring of food allergies are mentioned in the chapters on special diseases.

Tests for peripheral nerves

Sensation tests are done in the peripheral nervous system first in a dermatomal pattern. Tests for light touch, sharp/blunt, temperature and often two-point discrimination are the most common bedside tests (small vs large diameter nerve fibres).

Electromyography and nerve conduction tests are performed by neurologists to evaluate paresthesias and peripheral neuropathy. This concerns in particular dermatologic diseases such as leprosy or scleroderma, chronic graft versus host disease at the skin, late borreliosis or late-stage syphilis. Patients with neurotrophic ulcers or diabetes mellitus, deposition disorders such as amyloidosis and traumatic nerve damage are other indications for testing.

Alloknesis is a specific test of peripheral nerve endings for evaluating itch signals. With a small brush one strikes over the skin. It is a primarily physiological and non-pruritogenic stimulus which leads in predisposed patients to different reactions of prickling, burning and/or itching to be measured on a score.

References

- [Lutze S, Westphal T, Jünger M, Arnold A. \(2023\) Microcirculation disorders of the skin. JDDG;1-27.https://doi.org/10.1111/ddg.15242](https://doi.org/10.1111/ddg.15242)

- [Mahler V, Nast A, Bauer A et al \(2019\) S3 Guidelines: Epicutaneous patch testing with contact allergens and drugs. JDDG 1187-1207 https://doi.org/10.1111/ddg.13971](#)
- [Jartarkar Sh R , Patil A | Wollina U,Gold M H, Stege H, Grabbe St & Goldust M \(2021\) New diagnostic and imaging technologies in dermatology. J Cosmet Dermatol. 20:3782–3787.](#)
- [Koseki K, Kawasaki H, Atsugi T et al \(2020\) Assessment of skin barrier function using skin images with topological data analysis. npj Systems Biology and Applications 6:40 ; https://doi.org/10.1038/s41540-020-00160-8](#)
- [John S W & Schwanitz HJ \(†\) \(2006\) Functional Skin Testing: the SMART Proedures. In Chew&Maibach Irritant Dermatitis chapt. 25 211-220- 211](#)
- [McKay M et al \(1990\) Office Techniques for Dermatologic Diagnosis. In: Clinical Methods: The History, Physical, and Laboratory Examinations. 3rd edition. Chapter 109](#)

9.3 Therapy

9.3.1 Principles of galenic formulations for topical drugs



Z. Bukvić Mokus, Zagreb; B. Marinović, Zagreb

Definition

Topical therapies are a mainstay in treatment in dermatology. They involve the external application of a drug on the affected skin. Topical agents consist of one or more active ingredients in a vehicle (non-active base). In topical therapy, choosing a proper vehicle can be as important as choosing the appropriate active ingredient.

Main principles

When using topical therapy, the following factors should be considered:

- active ingredients,
- vehicle, preservatives and stabilizers
- correct mode of application
- condition of the skin to be treated (acute, subacute, chronic).

The goal of most topical drugs is penetration through stratum corneum (SC) and upper dermis with

direct action to the skin. Penetration through the SC is accomplished by transepidermal or transappendageal pathways. There are several steps in this process. In each step, it is essential that the active ingredient is more soluble or driven by concentration gradient, enabling the active substance to penetrate the skin.

Glossary of important terms

Liberation – the release of the active ingredient from the vehicle.

Adsorption – binding of the active ingredient to skin structures (i.e. stratum corneum) Absorption – uptake of the active ingredient from the vehicle.

Penetration – passage through the stratum corneum

Permeation – transepidermal and transfollicular passage of active substances throughout the skin.

Resorption – the uptake of topically applied substances with transfer to blood vessels or lymphatics

Factors that affect percutaneous absorption

These include

- the thickness and integrity of the SC (a thicker SC decreases absorption),
- anatomic location (the absorption is highest on mucous membranes, scrotum, and eyelids, and lowest on palms and soles),
- skin hydration (increased hydration increases absorption),
- patient's age (higher absorption in neonates because of their suboptimal skin barrier), and
- occlusion with airtight dressings and greasy ointment bases, which increase percutaneous absorption.

Ingredients of topical drugs

Topical medications consist of one or more active ingredients combined with a vehicle. The vehicle contains a base to which have been added preservatives, stabilizers, emulsifiers, fragrances and other products.

Vehicles

The vehicle's choice is one of the critical tasks in topical prescribing, as it is very important for determining the pharmacokinetics (i.e. the active ingredient must be more soluble in the outer layer of SC than in the vehicle, or diffusion will not start).

Vehicles are divided into two groups:

- liquid (solutions, emulsions, shake lotions)
- semi-solid vehicles (gels, creams, ointments and paste)

Most commonly used types of vehicles:

- Cream – two forms: oil in water and water in oil
- Lotion – thin cream, easier to apply
- Solution – alcoholic vehicle
- Ointment – greasy and occlusive
- Gel – semi-solid – converts to liquid when rubbed into the skin
- Paste – ointment + powder – protective
- Shake lotion – water and powder
- Ambiphilic creams – topical preparations which retain water miscible properties of a cream but also comprise the high lipid content of an ointment
- Nanotechnology (nanoparticles and nanofibers) may be used in order to increase drug concentration in the carrier and change the pharmacological properties of the drug (slow release, selectivity, special route of internalization, selectivity)
- Cold cream - an emulsion of water and certain fats, including beeswax and certain scent substances. The name of the cream comes from the cool feeling that it leaves on the skin.

Ointments are used for dry skin; creams are most commonly used; gels and lotions are used when an easy application is preferred and for the scalp and hairy parts of the body.

Active therapy

Active ingredients are added to the vehicle. Ideally, the product should contain only one active ingredient, but in some cases, two or more active ingredients can be combined. The most commonly used active substances in dermatotherapy are:

- Antiseptics - used against different microbes (Polyvidone iodide, chlorhexidine, isopropyl alcohol)
- Antibiotics (mupirocin, clindamycin, erythromycin, fusidic acid, gentamycin, nadifloxacin) – used against superficial bacterial infections. As resistance to antibiotics is increasing in recent years, topical antibiotics are not always effective in the treatment of superficial bacterial infections and not for chronic wounds)
- Antifungals (azoles, pyridone derivatives, allylamine derivatives) – act by attaching to the cellular walls of fungi, inhibiting biosynthesis

- Antivirals (aciclovir, valaciclovir, penciclovir)
- Antiparasitics (permethrin, ivermectin, benzyl benzoate)
- Corticosteroids – very commonly used in dermatology to reduce inflammation, by vasoconstriction, diminution of membrane permeability, inhibition of inflammatory chemical mediators, immunosuppression, and inhibition of cell division. Topical steroids are classified by strength from high potency steroids to the mild ones. They should be given carefully to avoid side effects i.e. skin atrophy, striae distensae, steroid acne, rosacea-like dermatitis, hypertrichosis etc.
- Topical hormonal treatments
- Calcineurin inhibitors (tacrolimus, pimecrolimus)
- Immunosuppressants (cyclosporin A)
- Immunomodulators (imiquimod)
- Cytostatics (5-fluorouracil, podophyllotoxin)
- Retinoids (tretinoin, isotretinoin, adapalene, trifarotene, tazarotene)
- Vitamin D analogues (calcipotriol)
- Keratolytics (salicylic acid, α -hydroxy acids)
- Agents that affect hair growth (minoxidil)
- Skin lightening agents (hydroquinone)

Prescribing

Today there are many different commercially available products with standard, fixed combination of active ingredient(s) and vehicle. Still, some dermatologists prescribe compound prescriptions which may have some advantage for individual needs of the patient. An advantage of this is the individualized adjustment of dosage and vehicle.

Application of topical drugs

Topical preparations are applied to the skin most commonly once or twice daily. The patient should be prescribed an adequate quantity of the topical drug to be able to follow recommendations. For the entire body, about 30 g of the cream is needed. It can be easily quantified using the measure of “fingertip unit” (the amount of ointment or cream expressed from a tube with a 5 mm diameter nozzle, applied from the distal skin-crease to the tip of the index finger of an adult) which is equal to ca. 0.5 g.

Future directions

Several new topical JAK inhibitors have been examined in the treatment of alopecia areata, atopic dermatitis, vitiligo and psoriasis. Topical phosphodiesterase 4 (PDE4) inhibitors have shown promising results in the treatment of mild to moderate atopic dermatitis. [Agonist of Arylhydrocarbon-Rezeptor](#) (Tapinarof) is indicated in psoriasis.

References

- [Wohlrab J. Topical preparations and their use in dermatology. J Dtsch Dermatol Ges 2016; 14\(11\):1061-1070.](#)
- [Sideris N, Paschou E, Bakirtzi K, Kiritsi D, Papadimitriou I, Tsentemeidou A, Sotiriou E, Vakirlis E. New and Upcoming Topical Treatments for Atopic Dermatitis: A Review of the Literature. J Clin Med. 2022 Aug 24;11\(17\):4974. doi: 10.3390/jcm11174974. PMID: 36078904; PMCID: PMC9456375.](#)
- [Monteiro AY, et al. Understanding Your Creams: Principles of Dermatological Formulation Clin Exp Dermatol Ther 7: 190. www.doi.org/10.29011/2575-8268.100190](#)

9.3.2 Pharmacologic Basics of Systemic Therapy in Dermatology

B. Marinović; Z. Bukvić Mokos, Zagreb

Introduction

Systemic therapy is required in many dermatological, allergic, and venereal diseases when topical treatment is not sufficient. Use of systemic therapy is increasing in the last decades, especially after introducing new agents in dermatological therapy (i.e. biologicals, small molecules). Before introducing therapy, it is mandatory to establish a correct diagnosis, evaluate potential contraindications, and consider possible side effects including drug interactions during the treatment.

Antibiotics

Antibiotics are used to treat infectious skin and venereal diseases and some other diseases due to their antimicrobial, anti-inflammatory, and immunomodulatory effects. In infectious diseases, antibiotics should be prescribed according to the infection type (resistance patterns) and according to the spectrum of action. Antimicrobial resistance development should be avoided whenever possible (definite indication, avoid broad-spectrum antibiotics). Indications: primary (i.e. disseminated impetigo contagiosa, Lyme disease) and secondary (i.e. severely impetiginized eczema), deep bacterial infections

of the skin as well as venereal diseases (i.e. syphilis, gonorrhoea), primarily non-infectious, but pathogen-associated diseases (i.e. severe acne), primarily non-pathogen-associated skin diseases (i.e. nodular rosacea).

Antihistamines

Antihistamines are competitive antagonists acting on the histamine receptor. In dermatology, most commonly used are H1 blockers as they are indicated for the treatment and the prophylaxis of allergic and pseudoallergic reactions. First-generation H1 blockers (e.g. diphenhydramine, hydroxyzine) have sedative side-effects, which have been avoided in the second-generation and new third generation antihistamines (e.g. cetirizine, loratadine, and fexofenadine/rupatadine and bilastine) that do not cross the blood-brain barrier. Indications include urticaria, allergic rhinitis and conjunctivitis; intravenously administered antihistamines are the mainstay of the initial treatment of anaphylaxis.

Antimycotics

Systemic antimycotics are used in the treatment of widespread or deep localised dermatomycoses as well as mycotic infections that affect hair and nails. Most commonly used groups of antimycotics are azole-type antifungals (i.e. fluconazole, itraconazole for the treatment of dermatophytes and yeasts) and allylamine derivatives (i.e. terbinafine for the treatment of dermatophytoses). Griseofulvin is still used in the treatment of dermatophytoses.

Glucocorticoids

Glucocorticoids are the most widely used drugs in dermatology. Their main mode of action are anti-inflammatory, immunosuppressive and antiproliferative. Glucocorticosteroids are indicated in the therapy of inflammatory dermatoses, autoimmune dermatoses, granulomatous dermatoses, and other diseases that are not classified in one of these three groups. They are absolutely contraindicated in active untreated tuberculosis, systemic mycoses and ocular herpes simplex. The list of relative contraindications is much broader, including chronic gastritis, esophagitis and gastrointestinal bleeding, severe osteoporosis, glaucoma, depression etc.; in these patients, glucocorticosteroids can be introduced if needed but with special prophylactic measures. The most common side effects are diabetes mellitus, hypertension, increased susceptibility to infections, osteoporosis, aseptic bone necrosis, gastrointestinal bleeding etc.

Common side effects of systemic glucocorticoids:

- Hyperglycemia (diabetes)
- Arterial hypertension (secondary)

- Susceptibility to infections (e.g. herpes zoster)
- Gastrointestinal bleeding and ulcers
- Osteopenia and osteoporosis
- Aseptic bone necrosis (e.g. aseptic femur head necrosis)

Retinoids

Retinoids include derivatives of vitamin A acid and substances with different chemical structures but related biological activities. They belong to the steroid superfamily.

Five groups of retinoids are available for the oral use in dermatology:

- acitretin
- alitretinoin
- bexarotene
- isotretinoin
- tretinoin

Most common indications for the use are psoriasis, palmoplantar hyperkeratosis, PRP (pityriasis rubra pilaris), lichen planus for acitretin; refractory hand eczema for alitretinoin; cutaneous T-cell lymphomas for bexarotene; and severe and refractory forms of acne for isotretinoin. Contraindications include familial and clinically relevant acquired lipid metabolic disorders, simultaneous administration of tetracyclines, severe diabetes, pregnancy or planning the pregnancy and breastfeeding due to the teratogenicity. Contraceptive care measures should be followed strictly. Most common side effects are cheilitis and xerosis cutis. Hair loss may occur during acitretin therapy. Increased transaminases and serum lipids are possible. Arthralgia, myalgia, headache and increased intracranial pressure are. Most side effects are dose dependent and reversible.

Antimetabolites

Two most essential antimetabolites in systemic dermatological therapy are methotrexate and azathioprine.

- Methotrexate has a cytotoxic and immunomodulatory function. It is indicated in severe psoriasis, psoriatic arthritis, dermatomyositis, morphea, and some other dermatoses. It is usually prescribed once a week orally or subcutaneously. Contraindications for the therapy are pregnancy and lactation, acute infection, bone marrow depression and liver diseases. To avoid MTX overdose, folic acid should be given orally in parallel.
- Azathioprine is a cytotoxic agent used as an immunosuppressant. Main indications are

autoimmune blistering diseases (in combination with glucocorticoids – as steroid-sparing agent). Other indications include vasculitis, lupus erythematosus, and pyoderma gangrenosum.

Antimalarials

Chloroquine and hydroxychloroquine are most commonly given in dermatology for the treatment of cutaneous and systemic lupus erythematosus. Glucose-6-phosphate dehydrogenase deficiency should be excluded before introducing therapy. Contraindications for introducing the drugs are retinopathy, visual field restrictions, pregnancy and lactation. Ophthalmological consultations should be done before starting the treatment and in most patients after five years, in risk groups every year.

Dapsone

Dapsone is an antibacterial and anti-inflammatory drug, in dermatology most commonly used to treat dermatitis herpetiformis and linear IgA dermatosis, and nodular vasculitis. Glucose-6-phosphate dehydrogenase deficiency should be excluded before introducing therapy. Methemoglobin should be checked regularly; hemolytic anaemia and agranulocytosis can occur.

Biologics and small molecules

Biologics are monoclonal antibodies which target specific proteins involved in the pathogenesis of various dermatological diseases, including psoriasis, psoriatic arthritis, metastatic melanoma, atopic dermatitis, hidradenitis suppurativa, pemphigus vulgaris, chronic urticaria, and cutaneous B-cell lymphomas. Biologics comprise tumor necrosis factor alpha (TNF α) inhibitors (adalimumab, infliximab, etanercept), interleukin (IL)-12/IL-23 inhibitors (ustekinumab), IL-17 inhibitors (secukinumab, ixekizumab, brodalumab), IL-4/IL-13 inhibitor (dupilumab, tralokimumab, baricitinib, upadacitinib), IL-1 antagonists (anakinra, canakinumab, rilonacept), CD20 inhibitor (rituximab).

TNF α inhibitors, IL-12/IL-23 inhibitors and IL-17 inhibitors are indicated in the treatment of psoriasis and psoriatic arthritis. Adalimumab is approved for the treatment of moderate and severe hidradenitis suppurativa, whereas other TNF α inhibitors (infliximab, etanercept) and anakinra are used off-label in this indication. Dupilumab and Baricitinib are registered for the treatment of severe atopic eczema. Rituximab is indicated in the treatment of cutaneous B-cell lymphoma and pemphigus vulgaris. Omalizumab is an anti-IgE recombinant humanized monoclonal antibody that is indicated in the treatment of chronic spontaneous urticaria. In the treatment of advanced (non-resectable or metastatic) melanoma several biologics are approved, including ipilimumab (anti-cytotoxic T lymphocyte antigen-4 (anti-CTLA-4)) and PD-1 (programmed cell death protein-1) inhibitors nivolumab and pembrolizumab.

Small molecules (e.g. apremilast, an inhibitor of phosphodiesterase 4) are agents with a low molecular

weight that can pass through cell membranes to modulate intracellular targets. They are most commonly used in the treatment of psoriatic arthritis and psoriasis. Small molecules are administered orally.

References

- [Caplan A, Fett N, Rosenbach M, Werth VP, Micheletti RG. Prevention and management of glucocorticoid-induced side effects: A comprehensive review: A review of glucocorticoid pharmacology and bone health. J Am Acad Dermatol 2017; 76\(1\):1-9.](#)
- [Schreml St & Gollnick H \(2022\) Systemic Therapy. In: Braun-Falco`s Dermatology 4th edition. Chapter 117 pp2037- 2074 Springer](#)

9.3.3 Basics of Dermato-Surgery Techniques

L. Martos-Cabrera, Madrid; S. Koskenmies, Helsinki; A. Ranki, Helsinki; A. Salava, Helsinki
(see also Chapter 9.2.2 on Basic Dermatopathology)



Definition

Dermato-surgery refers to surgical procedures involving mainly the skin, its appendages and the underlying subcutaneous fat and fascia. These may be performed in outpatient or inpatient settings and are mostly performed using local anaesthesia.

Indications for dermato-surgery

Dermato-surgery is indicated for obtaining a skin biopsy for histopathological analysis, for excisional removal of malignant tumours of the skin or for excisional removal of benign skin lesions. Those procedures are done because of local symptoms they produce (example irritating or growing congenital nevi, dermatofibromas, bleeding angioma or hidradenitis supp. sinuses) or sweat gland removal because of hyperhidrosis or for therapy of varicosis (stripping), for wound care (transplantation) and for hair and skin transplantation (example androgenic alopecia or scarring alopecia, vitiligo). Dermatologic surgeons also perform cosmetic surgeries like face lifts, blepharoplasty (eyelid surgery), laser skin resurfacing, dermal fillers, and botulinum toxin injections to improve aesthetics.

Different types of procedures (dermato- surgery techniques)

Different techniques are used in the surgical management of benign and malignant skin lesions. The most frequently used techniques include incisional biopsy, punch biopsy, shave biopsy, excisional biopsy or excision with primary closure, shave excision, curettage, electrosurgery (e.g. diathermy, coagulation,

cautery). In addition, more advanced techniques comprise Mohs' micrographic surgery, complex reconstruction using flap procedures and skin grafting are belonging to the dermato-surgical repertoire. A combination of different techniques is often necessary.

The choice of technique depends primarily on purpose (e.g. diagnostic or therapeutic), the diagnosis (benign or malignant), local spread and growth (superficial or infiltrating) and the size and anatomical site of the lesion. Patient profile (age, co-morbidity, drugs) and preference combined with the expertise of the surgeon are also very important factors.

Incisional biopsy (including punch biopsy, [Fig. 1](#))

The object is to obtain a diagnostic full-thickness skin specimen for histopathology. It may involve the use of a scalpel (elliptic excisional biopsy, see below) or a cylindrical blade attached to a handle (i.e. punch biopsy). It is best to choose a lesion of recent onset, or the most abnormal-looking edge of an enlarging lesion for a diagnostic biopsy.

Skin lesions suitable for punch biopsy include all kinds of skin tumors and precancerous lesions. It should however not be used for larger melanocytic lesions or those which are showing clinical atypia, which should be excised. The chosen site should be marked and infiltrated with a local anesthetic. Stretch the skin perpendicular to the skin tension lines so that the punch defect will have an elliptical shape. The punch is held vertically over the skin and rotated down until the subcutaneous tissue (visible fat tissue). The specimen is then removed and gently handled to prevent crush artefacts. A separate punch biopsy may be taken from perilesional skin for direct immunofluorescence (e.g. to diagnose autoimmune blistering diseases). Wound closure is usually accomplished by using a single interrupted suture and hemostasis is ensured by pressure and bandage. Skin specimens should always be sent to histopathologic evaluation.

Shave biopsy

The technique is similar to shave excision (see below) with the difference that the main purpose is to obtain a specimen for histopathology.

Shave excision and curettage ([Fig. 3](#))

Lesions growing mainly above the skin surface can be shaved off as a tangential excision using a scalpel blade or razor blade. Curettage refers to the use of a sharp spoon-shaped instrument to scrape off a superficial skin lesion. Light cautery or other methods of hemostasis (e.g. iron nitrate solution) is used and the wound is left to heal by secondary intention. Examples of skin lesions that may be removed this way include skin tags, filiform viral warts and seborrheic keratosis. The technique may result in unsightly scars and lesions may recur. In some cases, curettage may be followed by cryotherapy or photodynamic therapy.

Excisional biopsy with primary closure (Fig. 2)

Firstly, it is important to identify the margins of the lesion in good light and to mark out with a surgical pen a fusiform or elliptical shape around the lesion. Its form should be 2-3 times as long as it is wide and follow the skin tension lines (Langer lines). There after inject a local anesthetic, (usually 1% lidocaine with adrenaline) using a fine needle into the deep dermis. Wash the surgical area with an antiseptic solution (e.g. alcohol) and apply surgical guards for an aseptic technique. It is important to stabilize the incision area by traction with the fingers. By applying controlled pressure on the scalpel, carry out the cut along marked lines vertically with the angle of the blade. It is usually necessary to cut until the subcutaneous tissue, and remove the specimen. The specimen should be placed entirely in a labelled specimen container bottle with formalin mixture and clearly numbered. It may be necessary to use the scalpel or scissors to undermine the skin edge below the dermis. This will loosen the overlying skin and decrease tension.

Complex reconstruction using flap procedure

Complex reconstructions using different flap techniques are used in situations where primary closure is not possible, e.g. due to large excisions or anatomical sites where tension may cause functional impairment. Local, regional or distant flaps can be used and there are many different techniques available (advancement flap, rotation flap, transposition flap). The basic principle is to reconstruct a skin defect with a lifted skin flap from a donor site and move it to a recipient site with an intact blood supply.

Skin grafting

Comparable to complex reconstructions using flaps, skin grafts are used to cover large or complex excisional defects. Skin grafting involves the transplantation of full or subcutaneous fat denuded skin, usually from the same patient but from another anatomical site. Typical donor sites are the preauricular region or the lateral thigh. The transplanted tissue does not have an intact blood supply and therefore relies on growth of new blood vessels. Principally, there are two types of skin grafts: split thickness skin graft (removal of a thin layer of skin from donor site to close a defect) and full-thickness skin graft (punching or cutting whole skin away from the donor site to close small defects or to treat vitiligo or to transplant hair).

Mohs' micrographic surgery

Mohs' micrographic surgery is a surgical technique in which the complete excision of skin cancer is controlled by stepwise microscopically controlled margins. The technique is used in situations where high cure rates with maximizing preservation of healthy tissue is needed, e.g. high-risk basal cell carcinomas on the face. Here, the skin cancer is gradually removed in stepwise phases. After each phase of excision, the margins are immediately microscopically examined for remaining cancer cells and this process is repeated until full removal of all cancer cells. Several other techniques are used for the removal of tissue (fresh versus fixed tissue technique).

Electrosurgery

Electrosurgery is used for hemostasis and desiccation of tissue using high frequency (0.1-1 MHz currents). Methods include electrodesiccation (cautery, contact of electrode with skin, deeper tissue injury), electrocoagulation (diathermy, bipolar forceps, mostly hemostasis) and electrosection (undamped wave, cutting without haemostasis or adjacent tissue injury). Benign lesions can easily be scraped off when light electrodesiccation is used first. Electrosurgery destroys tissue and prevents accurate histopathological examination. Cave: Ask about the presence of a cardiac pacemaker.

Local anesthesia

Local anesthesia involves the use of topical anesthetics and injections of local anesthetics directly into the tissue (infiltration) or into the vicinity of peripheral nerves (nerve blocks). Topical anesthesia may be useful for small procedures, e.g. scissor snipping of skin tags. The anesthetic cream is applied 1-2 h before the procedure (e.g. eutectic mixture of prilocaine and lidocaine, cream or plaster). Most skin procedures require a subdermal anesthetic, such as lidocaine (xylocaine). After injection the onset of action is rapid in a few minutes and lasts one to three hours. The addition of adrenaline 1:100.000 extends duration and may control bleeding (but avoid adrenalin in acral lesions).

Hemostasis

Methods of hemostasis for superficial bleedings include local pressure and hemostatic solutions (e.g. iron or aluminum chloride) applied with cotton tips. In deeper bleeding, typically after excisions with primary closure or more complex reconstructions using flap procedures, pinpoint diathermy is used.

Suturing

For wound closure there are several techniques. The most used is a single layer closure using simple interrupted sutures tied using the needle holder. The stitches should be arranged equally on each side including at the least the whole dermis. The surgical knot is tightened so that the edges of the wound are lightly in contact to avoid scarring. In some sites a continuous suture may provide more satisfactory cosmetic results. Deeper and larger wounds may require subcutaneous sutures to eliminate dead space (e.g. hematoma and infection risk).

After suturing, light pressure should be applied to ensure that the bleeding has completely stopped. Thereafter the wound should be cleaned and dressings should be applied. In most cases the first dressing should be removed after 1-2 days. Sutures should be removed after the procedure depending on body site, the size of the wound and the amount of tension on it (e.g. face 5-7 days, arms and trunk 7-10 days, lower legs 10-14 days).

Complications

Typical complications after skin surgery are wound infections, hematoma formation, flap or graft necrosis following repair, wound dehiscence and scarring. Scar formation can cause cosmetic problems but also have functional impairments (contractures of joints, ectropion of the eye lid). In rare cases peripheral nerve damage may lead to paresthesia and impairment of motoric innervation (eye lid ptosis).

Prevention of complications

Procedures should be performed in aseptic circumstances to avoid wound infections. Based on patient risk factors, prophylactic systemic antibiotics are sometimes administered. Hematoma formation can be prevented by meticulous hemostasis and risk management of possible anticoagulant drugs. Flap or graft necrosis would be prevent by performing a proper design and keeping a precise surgical technique. Wound dehiscence and scarring is best prevented by minimizing tension of the excisional defect and adequate suturing techniques.

Scarring

To reduce scarring after dermato-surgery excisions should be performed in right angles to the muscle pull directions or parallel to skin tension lines (Langer lines). Scars are at first red and firm, but usually after some months the induration and erythema reduce leaving a softer scar that is paler than the nearby skin. Scars may stretch if there is wound tension. There is an increased risk of scarring if the patient has had prior hypertrophic scars or keloids (consider ethnic susceptibility), if the direction of the scar is not parallel to natural lines and in some high-risk anatomical sites (upper sternum, shoulders, joints). Visible scarring may also be evident if complications like hematoma formation, wound infection or wound dehiscence occur after the procedure.

References

- [Zuber TJ. \(2003\). Fusiform excision. Am Fam Physician. Apr 1;67\(7\):1539-44, 1547-8, 1550. PMID: 12722855.](#)
- [Starkman SJ, Williams CT, Sherris DA. \(2017\). Flap Basics I: Rotation and Transposition Flaps. Facial Plast Surg Clin North Am. Aug;25\(3\):313-321. doi: 10.1016/j.fsc.2017.03.004. Epub 2017 May 30. PMID: 28676159.](#)
- [Bolognia J, Schaffer J, Cerroni L. \(2017\). Dermatology: 2-volume set. 4th Edition. Elsevier; 2431-2529](#)

- [Strickler AG, Shah P, Bajaj S, Mizuguchi R, Nijhawan RI, Oduyungbo M, Rossi A, Ratner D. \(2021\). Preventing complications in dermatologic surgery: Presurgical concerns. J Am Acad Dermatol. Apr;84\(4\):883-892. doi: 10.1016/j.jaad.2020.10.099. Epub 2021 Jan 23. Erratum in: J Am Acad Dermatol. 2021 Aug;85\(2\):535. PMID: 33497750. Kantor J. Dermatologists perform more reconstructive surgery in the Medicare population than any other specialist group: A cross-sectional individual-level analysis of Medicare volume and specialist type in cutaneous and reconstructive surgery. J Am Acad Dermatol 2018; 78\(1\): 171–173](#)

9.3.4 Basics of ultraviolet radiation therapy and lasers

G. Girolomoni, Verona; P. Gisondi, Verona; M. Maurelli, Verona;



Synonyms

Ultraviolet (UV) radiation therapy: phototherapy. Photochemotherapy (PUVA).

Photodynamic therapy: photoradiation therapy Extracorporeal photopheresis.

Laser (light amplification by stimulated emission of radiation).

Definition

The following physical radiation methods should be reserved for medical specialists frequently dealing with the diseases described below.

UV radiation therapy (phototherapy) consists in the use of UVB/A light in the treatment of skin diseases.

Photochemotherapy consists in the use of UVA light and oral or topical photosensitizer of the psoralen type.

Photodynamic therapy consists in a photochemical reaction, which requires the presence of a photosensitizing molecule, photoactivating wavelengths of light and tissue oxygen.

Extracorporeal photopheresis consists of extracorporeal exposure of the patient's blood immune cells with psoralens and UVA.

Laser therapy consists in the emission of coherent radiations using unique light sources rooted in the process of stimulated emission. Laser works by precise tissue heating, which occurs when optical energy is absorbed within the skin. Different laser types with different wave lengths emissions.

Radiofrequency consists in an oscillation rate of an alternating electric current or voltage or of a magnetic, electric or electromagnetic field or mechanical system in the frequency range 20 kHz-300 GHz.

Soft and hard X-rays are X-rays with high photon energies (above 5-10 keV, below 0.2-0.1 nm wavelength) defines hard X-rays and while those with lower energy and longer wavelength, soft X-rays. Hard X-rays are widely used to image the inside of objects for their penetrating ability in medical radiography. Soft x-ray irradiation is usually used to treat skin-related diseases (including non-melanoma skin cancer and cutaneous lymphomas).

Modes of action

UVB phototherapy (broadband: 290-320 nm; narrowband TL-01-: 311-313 nm; excimer laser: 308 nm) refers to the use of artificial UVB radiation without the addition of exogenous photosensitizers. The radiation is absorbed by endogenous chromophores and the subsequent photochemical reactions cause a variety of biologic effects, ultimately leading to the therapeutic effects. The most important chromophore for UVB is DNA photoproducts, in particular pyrimidine dimers. UVB exposure reduces DNA synthesis and induces the expression of the tumor suppressor gene p53, with a subsequent cell cycle arrest or apoptosis of keratinocytes if the damage is too severe to be repaired. In addition, UV radiation exerts immunomodulatory activities.

UVA phototherapy (320-400 nm) is subdivided in UVA1 (340-400 nm) and UVA2 (320-340 nm). UVA2 is similar to UVB in the ability to cause erythema as well as immunomodulation and photocarcinogenesis. UVA1 radiation, because of the longer wavelength, penetrates more deeply into the skin layers, and consequently not only the epidermis, but also dermis and blood vessels.

Photochemotherapy with psoralens (PUVA) combines the use of psoralens (P) and long-wave radiation (UVA). Psoralens can be administered orally or topically in solutions, creams or baths, with subsequent UVA exposure. This combination results in a therapeutic phototoxic and immunomodulating effect.

Extracorporeal photochemotherapy (photopheresis) consists in the induction of an immune response against malignant cells (for example, circulating cutaneous T-cell lymphoma cells), downregulation of Graft vs Host reaction on host immune cells and solid organ transplantation reactions. This acts throughout the induction of the generation of antigen-specific regulatory T-cells.

Photodynamic therapy is a photochemical reaction throughout the use of a photosensitizing molecule, which may be administered systemically as intact macrocycles or topically as pro-photosensitizers, which are metabolized to photoactive molecules (protoporphyrin).

Laser therapies can be delivered in continuous and pulsed waves. The specificity of each laser is characterized by destruction of specific target structured of the skin, with limited damage of

surrounding tissues, via utilization of a wavelength of light preferentially absorbed by the target.

Non-ablative radiofrequency is a procedure commonly used in skin aging for the treatment of skin laxity and wrinkles from an increase in tissue temperature. The main physiological effect is to induce thermal damage to thus stimulate neo-collagenesis in deep layers of the skin and subcutaneous tissues.

Soft and hard X-rays: hard X-rays are widely used to image the inside of objects for their penetrating ability in medical radiography. Soft x-ray irradiation is usually used to treat skin-related diseases (including non-melanoma skin cancer and cutaneous lymphomas).

Main indications

nbUVB: psoriasis, mycosis fungoides, vitiligo, atopic dermatitis, graft-versus-host-disease (GVHD), pityriasis lichenoides, lymphomatoid papulosis, seborrheic dermatitis.

UVA1: localized scleroderma, chronic sclerodermoid GVHD, urticaria pigmentosa, cutaneous T-cell lymphoma (CTCL).

PUVA: psoriasis, mycosis fungoides, atopic dermatitis, lichen planus, GVHD, miscellaneous dermatoses.

Photopheresis: Sezary syndrome, erythrodermic CTCL, acute and chronic GVHD after allogeneic bone marrow transplantation.

Photodynamic therapy: neoplasias, such as actinic keratosis, actinic cheilitis, in situ and invasive squamous cell carcinoma, basal cell carcinoma, mycosis fungoides, Paget's disease, port-wine stains; acne, porokeratosis, leishmanias, photodamage.

Laser therapy: Vascular lesions: pulsed dye, variable-pulsed potassium titanyl phosphate (Nd:YAG), long-pulsed alexandrite, long-pulsed diode, long-pulsed Nd:YAG, intense pulsed light; endovascular application throughout diode laser, Nd:YAG, radiofrequency energy source. Pigmented lesions and tattoo removal: Q-switched lasers such as Q-switched Nd:YAG, frequency-doubled, Q-switched ruby, Q-switched alexandrite, Q-switched Nd:YAG; long-pulsed lasers and intense pulsed light such as long-pulsed ruby, diode, Nd:YAG, intense pulsed light source. Laser hair removal with long-pulsed lasers such as ruby, alexandrite, Nd:YAG (moderate efficacy) and diode (high efficacy); with intense pulsed light source (low efficacy). Laser skin resurfacing superficial (non-ablative): vascular lasers such as pulse dye and pulsed potassium-titanyl-phosphate laser; mid dermis with infrared lasers or intense pulsed light; deep dermis (ablative lasers): carbon dioxide lasers (pulsed and scanned-continuous wave) and erbium:YAG laser.

Adverse effects

UV light: depending on UVB range, erythema peak with 313 nm. Acute: itchy or painful erythema, burns with blistering, increased recurrence of herpes simplex viral infections.

UVA and UVB can induce persisting cell mutations, skin cancer risk. Chronic: xerosis, photoaging, carcinomas (basal-cell carcinoma).

PUVA therapy: long term risk of skin cancer, PUVA freckles, gastrointestinal intolerance for psoralens. Photodynamic therapy and laser therapy may be painful.

References

- [Bolognia J, Schaffer J, Cerroni L. \(2017\) Dermatology: 2-volume set. 4th Edition. Elsevier, 2880.](#)
- [Hölzle, E., Lehmann, P. \(2022\). Physical Therapy: Light. In: Plewig, G., French, L., Ruzicka, T., Kaufmann, R., Hertl, M. \(eds\) Braun-Falco's Dermatology. Springer, Berlin, Heidelberg. \[https://doi.org/10.1007/978-3-662-63709-8_117\]\(https://doi.org/10.1007/978-3-662-63709-8_117\)](#)
- [Victoria Goulden, Tsui C. Ling, Parastoo Babakinejad, Robert Dawe, Ewan Eadie, Hiva Fassihi, Adam Fityan, Trish Garibaldinos, Sally H. Ibbotson, Ljuba Novakovic, Emma Rush, Sophie C. Weatherhead, Heather Whitehouse, Maria Hashme, M. Firouz Mohd Mustapa, Lesley S. Exton, on behalf of the British Association of Dermatologists' Clinical Standards Unit, British Association of Dermatologists and British Photodermatology Group guidelines for narrowband ultraviolet B phototherapy 2022, British Journal of Dermatology, Volume 187, Issue 3, 1 September 2022, Pages 295–308, <https://doi.org/10.1111/bjd.21669>](#)
- [El Saftawy E, Sarhan R, Hamed A, Elhawary E, Sameh A. Lasers for cutaneous lesions: An update. Dermatologic Therapy. 2022; 35\(8\):e15647. doi:10.1111/dth.15647](#)
- [Cho A, Jantschitsch C, Knobler R. Extracorporeal Photopheresis-An Overview. Front Med \(Lausanne\). 2018 Aug 27;5:236. doi: 10.3389/fmed.2018.00236. PMID: 30211164; PMCID: PMC6119964.](#)

Chapter 10

10.1 Primary lesions

Definition

International nomenclature for the description of cutaneous lesions. The international nomenclature includes 8 basic terms and over hundred descriptive additional terms. The unifying nomenclature serves as a crucial communication skill between dermato-venerologists and all medical disciplines which are confronted with skin problems or take care of the skin.

Skin and skin diseases present with signs and lesions that have distinct characteristics. The original lesions are defined as primary lesions, and the identification of such lesions is the most important aspect of the dermatologic physical examination. They tend to have a greater diagnostic impact compared to secondary lesions. They may be stable or be modified by progression or regression, trauma or other local or systemic factors, producing the secondary lesions. The four most important features in concisely describing dermatological findings are description of the lesions, and then their localisation, distribution and evolution.

10.1.1 Macule



Synonyms

Macule; patch.

Definition / Description

A flat, non-palpable, localized change in color of skin. Usually sharp borders. If larger than 1 cm: patch.

Colors: red, brown, black, white, blue, yellow.

Size: several millimeters.

Special

Petechia (punctate bleeding into skin), purpura (small areas of bleeding), hematoma (larger areas of bleeding), deposition of pigmented material of different origin.

Localization

Can appear anywhere on skin; for example, macula exanthema.

On mucosa: enanthem.

Course

May develop into hive or a papule.

May over time develop additional scaling.

Often associated with papules, vesicles and pustules.

Comment / Explanation

Large red patch = erythema.

Erythroderma (generalized redness, often infiltrated).

Flush (acute transient facial erythema).

Pathophysiology

Vascular dilation, either because of aberrant vessels or inflammatory mediators (red): endogenous or exogenous pigment, for example melanin (brown-black, blue-gray), hemoglobin (red-blue), hemosiderin (brown) lipids (yellow), loss of pigment (white), external deposition of foreign body material (trauma, tattoo).

Typical Dermatoses

Drug induced eruption, macular lentigo, viral exanthema, vitiligo, pityriasis versicolor.

10.1.2 Urtica



Synonyms

Wheal, hive.

Definition / Description

Wheal: localized transient flattened sub-epidermal edema with initial complete later peripheral

erythema; can be red or pale pink.

Angioedema: localized edema in the deeper dermis, less sharply defined, firm but compressible swelling.

Special

Urticaria: usually associated with marked pruritus (itching).

Angioedema: feeling of pressure, if on mucous membranes sensation of stricture.

Localization

Urticaria: can appear anywhere on body, especially on trunk and extremities, less often on face and scalp.

Deep seated wheals are localized in the subcutaneous fat.

Angioedema: most common on cheeks, eyelids, lips, oral and genital mucosa.

Course

Transient, lesions change over minutes to hours, finally annular figured flattening.

Associated with macules, erythema and flushing.

Resolves completely without scarring or other changes.

Comment / Explanation

An individual hive typically never lasts more than 24 hours, although a case of hives may last days to weeks. Other diseases may cause persistent urticated lesions (vasculitis, lupus erythematosus).

Usually intense pruritus.

Many causes: physical factors, infections, allergic reactions, medications, mastocytosis.

Angioedema: deep edema after the lower dermis (pale, firm swelling).

Pathophysiology

Mast cells, basophils; release histamine and other inflammatory mediators (prostaglandins, leukotrienes). Triple response to histamine: pruritus, macular erythema, hive.

Typical Dermatoses

Acute, spontaneous urticaria, chronic urticaria, urticarial exanthema of other reasons.

Angioedema.

10.1.3 Papule



Synonyms

Papule.

Definition / Description

Focal, elevated, solid, circumscribed, palpable increase in substance of skin, sharp borders, surface usually smooth.

Colors: if caused by inflammation, red; if secondary to other deposits: red, brown or yellow. Size: ≤ 1 cm.

Localization

May appear on entire body, for example maculo-papular exanthem.

Course

Papules may coalesce to form plaque.

Papule may enlarge to form nodule. May develop scales, crusts or erosion.

May be associated with: macule (maculo-papular), vesicle (papulo-vesicular) or pustule (papulo-pustular).

Comment / Explanation

Distinguish from nodule which is >0.5 cm.

Inflammatory papules often pruritic.

Pathophysiology

Inflammatory infiltrate, deposits of lipids, proliferations of cells.

Typical Dermatoses

Multiple lesions: Drug exanthema, lichen planus, scabies, syphilis, acne.

Single lesions: Melanocytic nevus, tumors such as early nodular basal cell carcinoma.

10.1.4 Plaque



Synonyms

Plaque.

Definition / Description

A palpable, flat-topped, firm, rough, superficial lesion elevated above the skin surface, larger than a papule; papules can coalesce to form plaques.

Colors: if caused by inflammation, then red; if secondary to other deposits, then red, brown or yellow.

Size: > 1 cm (up to 10-20cm).

Localization

May appear anywhere on body.

Course

May develop scale or crusts, or ulcerate.

Comment / Explanation

Inflammatory plaques often pruritic.

Pathophysiology

Inflammatory infiltrate, proliferations of cells, deposition of material.

Typical Dermatoses

Psoriasis, sarcoidosis, plaque stage of mycosis fungoides (cutaneous T-cell lymphoma).

10.1.5 Nodule



Synonyms

Node.

Definition / Description

Nodule: a firm, elevated, circumscribed, easily palpable and indurate lesion, usually with sharp borders, that is thicker or deeper than the average papule and > 1 cm or plaque; it can involve all skin layers.

More extensive increase in substance of skin.

Colors: skin-colored, brown, red, yellow.

Localization

May appear anywhere on body; can be solitary, localized or disseminated.

Course

May progress to necrosis, ulcer or scar.

Comment / Explanation

Distinction between papule and nodule is by size.

Larger nodule = tumor (benign or malignant cell proliferation).

Pathophysiology

Benign and malignant cell proliferations (granuloma, tumor).

Inflammation (furuncle, abscess).

Typical Dermatoses

Tumor: nodular basal cell carcinoma, nodular melanoma. Infection: furuncle, abscess.

Inflammatory disease: prurigo, erythema nodosum, sarcoidosis.

10.1.6 Vesicle and bulla



Synonyms

Blister.

Definition / Description

Elevated, circumscribed, superficial, intra- or subepidermal fluid-filled lesion that contains clear fluid. Color: clear with transparent contents, may be haemorrhagic or purulent.

Vesicle \leq 1 cm, bulla $>$ 1 cm.

Course

Often develop erosions and crusts.

May heal with pigmentation, atrophy or rarely scarring. Associated with macules, secondary clouding = pustule. Bleeding = hemorrhagic vesicle or blister.

Comment / Explanation

Nikolsky sign may be positive with intraepidermal blisters.

Widespread blistering may be an emergency situation.

Pathophysiology

Loss of adhesion of epidermal keratinocytes.

Loss of adhesion in basement membrane zone through physical trauma (burns, mechanical pressure).

Genetic defect (adhesion defects in epidermolysis bullosa).

Inflammation (autoimmune disorders, infections).

Typical Dermatoses

Infections: herpes simplex, varicella-zoster infection.

Many diseases may become bullous: erysipelas, bullous impetigo, phototoxic reactions, phytophotodermatitis, acute contact dermatitis, dyshidrosis and pompholyx.

Genetic disorders: epidermolysis bullosa group.

Inflammatory disorders: Stevens-Johnson syndrome, toxic epidermal necrolysis. Autoimmune diseases:

pemphigus vulgaris, bullous pemphigoid, Duhring's disease.

10.1.7 Pustula (Pustule)



Synonyms

Pustule.

Definition / Description

Superficial intraepidermal collection of cloudy or pus-laden fluid in the epidermis, follicular or acrosyringal opening.

Color: yellow. Size: < 5 mm.

Localization

May appear anywhere on body, often associated with hair follicle. Disseminated involvement of hair follicles = folliculitis.

Disseminated involvement of acrosyringia.

Course

May develop crusts or erosions.

Associated with vesicles and bullae.

Comment / Explanation

Sterile pustule (neutrophilic collections in pustular psoriasis), purulent contents (staphylococcal folliculitis).

Pathophysiology

Loss of adhesion of epidermal keratinocytes caused by infectious agents (herpes simplex virus, Staphylococcus aureus) inflammation or autoimmune mediated reactions.

Typical Dermatoses

Pustular skin manifestations of viral, bacterial and fungal diseases.

- Psoriasis: there are different forms of pustular psoriasis (see chapter on psoriasis): psoriasis vulgaris with pustulation (cum pustulatione); annular or circinate psoriasis; exanthematic pustular psoriasis and palmo-plantar pustular psoriasis (PPPP/ Königsbeck-Barber) and the acral variant acrodermatitis continua suppurativa (Hallopeau), and transitional forms.
- Generalized pustular psoriasis (von Zumbusch) is currently reclassified if a distinct variant of psoriasis per se. The disease has a genetically fixed germline mutation in the IL-36 RN function.
- Erythema anulare centrifugum with and without pustulation (EACP).
- Subcorneal pustulosis.
- Acute generalized exanthematous pustulosis (AGEP): severe cutaneous adverse reaction, mostly due to antibiotic drugs. It is characterized by the rapid development of nonfollicular, sterile pustules on an erythematous base. Acute onset of fever and pustulosis with leukocytosis within 24 hours. Mucous membranes and internal organs may be involved. Dermatopathology shows intracorneal, subcorneal, and/or intraepidermal pustules with papillary dermal edema containing neutrophils and eosinophils. Treatment besides cessation of the causative drug includes topical or systemic glucocorticosteroids.
- SAPHO (synovitis, acne, pustulosis, hyperostosis, and osteitis) syndrome is an autoinflammatory syndrome showing osteoarticular and dermatological manifestations, characterized by mainly by palmoplantar pustulosis and severe acne.
- Treatment with nonsteroidal anti-inflammatory and antirheumatic drugs.
- Pustulosis palmaris et plantaris (PPP) is a distinct entity of unclear pathomechanism, occurring preferentially in Japan. It shows vesicles, pustules and erythema. Its pathomechanism is not clear. Monoclonal antibody against interleukin (IL)-23 has been employed for treatment.
- Miliaria crystallina, rubra, or profunda are caused by blocked eccrine sweat glands and ducts on different levels. They result in self-limited rashes with vesicles.
- Erythema toxicum neonatorum and the transient neonatal pustular melanosis (TNPM, more common in black newborn) probably are different clinical expressions of the same entity. They are self-limiting and do not need a specific treatment.
- Diaper dermatitis (see 1.1.2.6 Napkin dermatitis).
- Various forms of pustular acne (see 4.1.1 Acne).

10.1.8 Cyst



Synonyms

None.

Definition / Description

Cyst: a nodule consisting of liquid or semi-solid material surrounded by a capsule located in the dermis. Pseudocyst is different due to lack of capsule/epithelial wall.

Localization

May appear anywhere on body; can be solitary, localized or disseminated.

Course

May progress to infection, necrosis, ulcer or scar.

Pathophysiology

Retention of secretions (epidermoid cyst/trichilemmal cyst).

Typical Dermatoses

Epidermoid cyst, trichilemmal cyst, hidradenitis suppurativa, severe acne.

10.2 Secondary lesions

10.2.1 Scales



Synonyms

Scales.

Definition / Description

Excessive thickening of stratum corneum with desquamation. Fine scales (pityriasiform) to coarse (psoriasis).

Color: white, gray, yellow. Size: mm to cm.

Special

Desquamation refers to diffuse shedding of scales. Special form: collerette with the scaling at the border of the lesion.

Localization

May appear anywhere on body surface: when localized often favours the palms and soles; may be generalized as in ichthyosis.

Course

May develop erosions or crusts. Associated with papules, pustules and plaques.

Comment / Explanation

Localized keratosis with excessive scales such as cutaneous horn.

Lichenification (thickened, scaly epidermis).

Palmoplantar keratoderma.

Pathophysiology

Excessive hyperproliferation of epidermal layers, loss of adhesion of keratinocytes.

Typical Dermatoses

Infection: tinea.

Inflammation: psoriasis, atopic dermatitis. Ichthyosis, xeroderma (dry skin), keratoderma.

10.2.2 Crust



Synonyms

Crust.

Definition / Description

Surface deposits of dried secretions (serum, pus or blood), usually mixed with epithelial and sometimes bacterial debris.

Color: yellow (serum, pus), brown-black (blood).

Size: several mm to cm.

Localization

May appear anywhere on body, usually localized.

Course

May develop into erosion or ulcer. Associated with vesicle or pustule.

When crusts become detached, the base may be dry or red and moist.

Pathophysiology

Exudation of serum; leakage of blood following trauma, lesion type following papule, pustule, plaque, vesicle and bulla.

Typical Dermatoses

All diagnoses associated with exudation of fluids.

10.2.3 Necrosis

Synonyms

Eschar.

Definition / Description

Superficial epithelial necrosis ranging toward full-thickness tissue destruction.

Color: brown, black.

Size: mm to cm.

Localization

May involve any area of skin.

Favours areas served by a terminal vessel with few collaterals.

Course

May develop into ulcer.

Heals with atrophy or scarring.

Comment / Explanation

Secondary infections possible.

Pathophysiology

Massive tissue destruction through: tumor outgrowing its vascular supply, infection, obstructive vascular disease, late-stage Raynaud.

Trauma: extensive damage.

Exogenous noxious agents: chemicals (acids or bases), burns, frost bite.

Typical Dermatoses

May follow: venous leg ulcer, peripheral arterial occlusion, diabetic foot ulcer, deep thermal or chemical burn (3°), deep infections, tumors, autoimmune vasculitis, cryoglobulinemia and cold agglutinins.

Site of entry for anthrax, rickettsial diseases (eschar).

10.2.4 Erosion

Synonyms

None.

Definition / Description

Superficial epidermal defect with loss usually extending no further than papillary dermis.

Color: red.

Size: mm to cm.

Localization

Location depends on etiology; may be isolated or localized. Mucosal erosions.

Course

Often covered with crust, on rare occasions may heal with dyspigmentation. Associated with vesicles, bullae, pustules.

Comment / Explanation

Superficial lesion which heals without atrophy or scarring because epidermis is capable of completely regenerating.

Pathophysiology

Inflammation, infection, trauma (scratching).

Typical Dermatoses

Impetigo, herpes simplex.

Epidermolysis bullosa simplex.

Pemphigus.

Bullous pemphigoid.

10.2.5 Excoriation



Synonyms

None.

Definition / Description

Traumatic tissue defect reaching deep into papillary dermis, usually with sharp borders.

Color: red.

Size: mm to cm.

Localization

Depending on etiology, usually localized or solitary, often linear.

Course

May develop with crusts or necrosis. Heals with scarring.

Associated with papules, nodules, erosions and superinfection.

Comment / Explanation

Excoriations are caused by scratching due to severe itching. Excoriations may provide access for pyogenic micro-organisms and the formation of crusts, pustules or cellulitis.

Artefacts.

Pathophysiology

Tissue removed by trauma, usually scratching.

Typical Dermatoses

Prurigo simplex, prurigo nodularis, artefact dermatitis, dystrophic epidermolysis bullosa.

10.2.6 Ulcer

Synonyms

Deep wound.

Definition / Description

Round or irregular deeper defect extending through dermis to subcutis, fascia or bone.

Color: red, often pale yellow, yellow or gray-yellow.

Peripheral erythema, sometimes necrosis.

Localization

Depends on etiology, skin and mucosal membranes.

Course

May develop crusts or necrosis. Always heals with scar.

Comment / Explanation

Nosologic entity, like venous ulcer.

Aphthae on mucous membranes (mm or cm).

Pathophysiology

Vascular obstruction: reduced perfusion, infection, tumor.

Tissue destruction through trauma, burns or frost bites.

Typical Dermatoses

Ulcus cruris, peripheral occlusive disease, burn, decubital ulcer, ulcerating tumours.

10.2.7 Fissure



Synonyms

Rhagade.

Definition / Description

Painful, fine or narrow tear extending into dermis, sharply defined, sometimes peripheral erythema.

Rhagades are generally deeper and larger than fissures.

Localization

Usually around an orifice, joint or interdigital site.

Fissures common on palms and soles.

Fissure at corner of mouth is perlèche.

Course

Associated with scales, hyperkeratosis and dry skin.

They may be dry or moist, red, straight, curved, irregular or branching.

Comment / Explanation

Very painful.

In most cases they occur when the skin is dry, atrophic, inflammatory, thickened and sclerotic.

Pathophysiology

Dry, brittle skin.

Mechanical or physical stress.

Common with chronic lichenified dermatitis.

Typical Dermatoses

Chronic hand and foot dermatitis (often described as hyperkeratotic/rhagadiform), palmoplantar keratoderma, psoriasis, chronic lichenoid atopic dermatitis.

Fissures in dry skin.

10.2.8 Atrophy

Synonyms

None.

Definition / Description

Loss or reduction of individual structures. affecting epidermis, dermis and/or subcutaneous tissue.

Color: white, blue, pale yellow.

Underlying vessels often seen.

In sclerosis, often a smooth, white, tight epidermis.

Localization

Depends on etiology.

Course

Terminal condition following a variety of processes.

Atrophic scars.

Mucosal atrophy (hormone deficiency, iron deficiency).

Sclerosis, congenital defects.

Comment / Explanation

Atrophoderma; rarely congenital atrophy of skin (i.e. aplasia cutis congenitalis).

Poikiloderma: atrophy, hyper- and depigmentation, telangiectasias.

Pathophysiology

Intrinsic and extrinsic cutaneous aging.

Striae distensae (stretch marks of pregnancy).

Post-traumatic atrophy.

Post-inflammatory atrophy.

Cachexia in patients with terminal illnesses.

Infectious (Borreliosis).

Typical Dermatoses

Age-related atrophy (dermatoporosis).

Atrophic scars.

Sclerosis: scleroderma, lichen sclerosus, lupus.

Poikiloderma: radiation dermatitis.

Systemic and topical corticosteroids.

10.8.9 Scar



Synonyms

Cicatrix.

Definition / Description

Repair process of skin and/or subcutaneous tissue following injury.

Special

Striae distensae (also known as stretch marks of pregnancy).

Localization

Depends on etiology. Mucosa.

Course

May develop into hypertrophic scar or keloid. They are persistent.

Comment / Explanation

Scars can be atrophic or hypertrophic.

Keloid is a scar, which proliferates beyond the bounds of the initial injury.

Spontaneous keloids develop without trauma.

Sclerosis is the result of spontaneous connective tissue proliferation (as in scleroderma).

Mucosa: synechia or symblepharon.

Mutilation in dystrophic epidermolysis bullosa.

Pathophysiology

Final result after wound healing or deep cutaneous inflammation.

Typical Dermatoses

Surgical scars.

Burn scars.

Healed venous leg ulcers.

Dystrophic epidermolysis bullosa.